



# Psoriasiform Eruption Clearance Following Psychiatric Treatment



Reza Bidaki<sup>1,2</sup> , Farzaneh Dehghani<sup>1\*</sup> , Mansoore Mozafari<sup>1</sup>

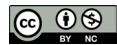1. Department of Psychiatry, Research Center of Addiction and Behavioral Sciences, Shahid Sadoughi University of Medical Sciences, Yazd, Iran.

2. Diabetes Research Center, Shahid Sadoughi University of Medical Sciences, Yazd, Iran.



**Citation** Bidaki R, Dehghani F, Mozafari M. Psoriasiform Eruption Clearance Following Psychiatric Treatment. Case Reports in Clinical Practice. 2018; 3(3):65-68.

**Running Title** Psoriasiform Eruption.



**Funding:** See Page 63

## Article info:

**Received:** 18 June 2018

**Revised:** 11 July 2018

**Accepted:** 31 July 2018

## Keywords:

Psoriasis, Psychiatric disorder, Delusion, Anxiety

## ABSTRACT

The occurrence of psoriasis vulgaris could be associated with higher psychiatric morbidity. In this case report, we present a patient with bipolar mood disorder and psychotic features whose dermatological signs recovered after the psychiatric disorder partial treatment. Dermatological diseases could be associated with psychiatric disorders, and recurrence of psychiatric symptoms might be associated with the recurrence of the skin lesions.

## Introduction

**P**soriasis, a psychocutaneous disorder [1] affects approximately 2% to 3% of the population [2]. Psoriasis clinical features, which are mostly characterized by erythematous papules and silver scale plaques [3], are

strongly affected by psychological stress [4]. Although the disease might trigger depression, observations indicate that psychiatric disorders could influence the course as well as outbreak of psoriasis [5]. Thus, alternative treatment with psychotherapy and or medication could be a valuable option in patients suffering from psoriasis [6]. In this case

\* Corresponding Author:

Farzaneh Dehghani, MD.

Address: Department of Psychiatry, Research Center of Addiction and Behavioral Sciences, Shahid Sadoughi University of Medical Sciences, Yazd, Iran.

E-mail: [dehghanifarzane@yahoo.com](mailto:dehghanifarzane@yahoo.com)

report, we present a patient with bipolar mood disorder and psychotic features whose dermatological signs recovered after partial psychiatric treatment.

### Case Presentation

A 36-year-old man with low socioeconomic status from a border region in the Southeast of Iran was referred to our emergency psychiatric department in November 2017. His brother reported that the patient had become excessively talkative, irritable, and restless. His first episode of psychiatric disorder was described as overspending and grandiosity delusion which ended in his hospitalization at the age of 15. Since then he had frequent admissions to a psychiatric center near his residence. During the course of disorder, the patient's brother reported symptoms-free intervals which recently had become shorter with more severe features. Because of the symptoms exacerbation, the patient could not work anymore and developed dermatological lesions on his knees since 2016. Therefore, the family decided to attend a better place for hospitalization and came to our hospital.

On admission, his brother reported that the patient had become much more irritable and angry than before; he had also become elated in mood, were awake at night but sleepy during the day. He was hyper-talkative and overspend lots of money aimlessly. Moreover, he had suicidal and homicidal thoughts without any plans or attempts regarding this matter. On assessing his mental condition, the patient showed no evidence of hallucinations, but he did have pressured speech, circumstantiality, and delusion of persecutory, poisoning and grandiosity. More precisely, the patient believed that he was a

superhuman and had extraordinary powers due to his special talent in reading the Quran. He demonstrated partial insights into his decreased functions due to his disorder.

### Past history

The patient's symptoms started from 23 years ago with manic episode. In more detail, his anxiety, cardiac palpitation, talkativeness and reduction in the need for sleep developed while his NAS (a kind of weak opioid substance) consumption highly increased at the same time. The stressors that targeted his psychiatric symptoms included familial and educational problems as well as his mother illness, frequent divorces, unemployment and the history of head injury. Besides, the patient's defense mechanism was definitely low towards problem solving.

### Course of treatment

The patient was admitted to our hospital with the diagnosis of bipolar mood disorder I manic episode with psychotic feature and received antipsychotic and mood stabilizers medication as follows: Tranqopine tablet 25 mg Hs, ranitidine tablet 150 mg daily, Na-valproate 200mg tablet TDS, clidinium-C tablet BD, thioridazine 25 mg tablet Hs, carbamazepine 200mg II tablet Hs, olanzapine 5 mg tablet TDS, zinc oxid topical oint. TDS, and pantoprazole 40 mg tablet daily.

After seven days of receiving treatment, his mood, behavior and psychomotor activity, hyper-talkativeness and vegetative state improved significantly and his delusions turned to be shaky although there were still present.

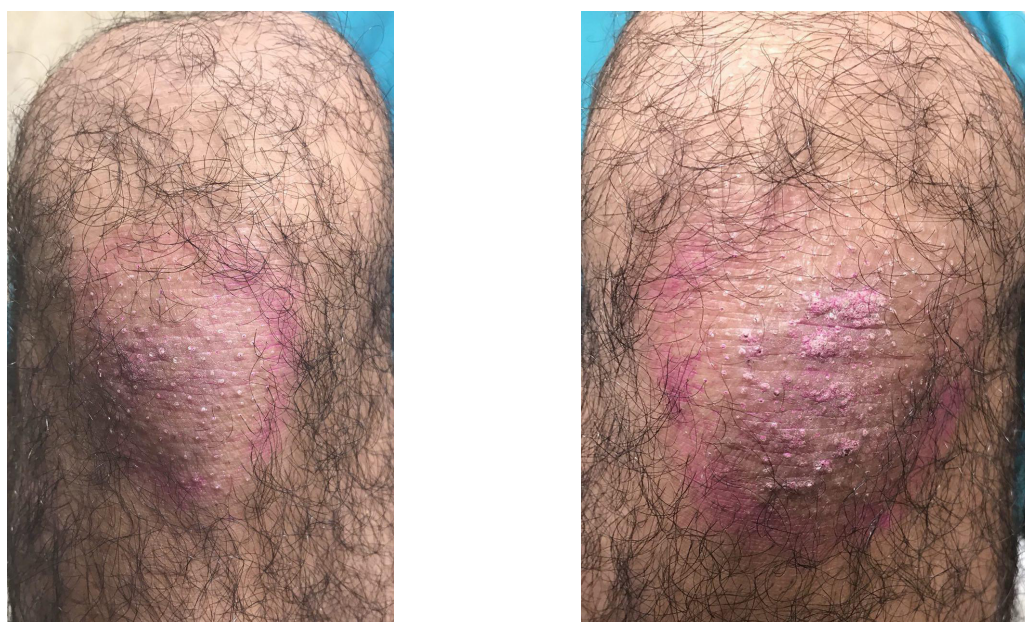


Figure 1. Erythematous plaques with a marked margin on extensor surfaces of both knees

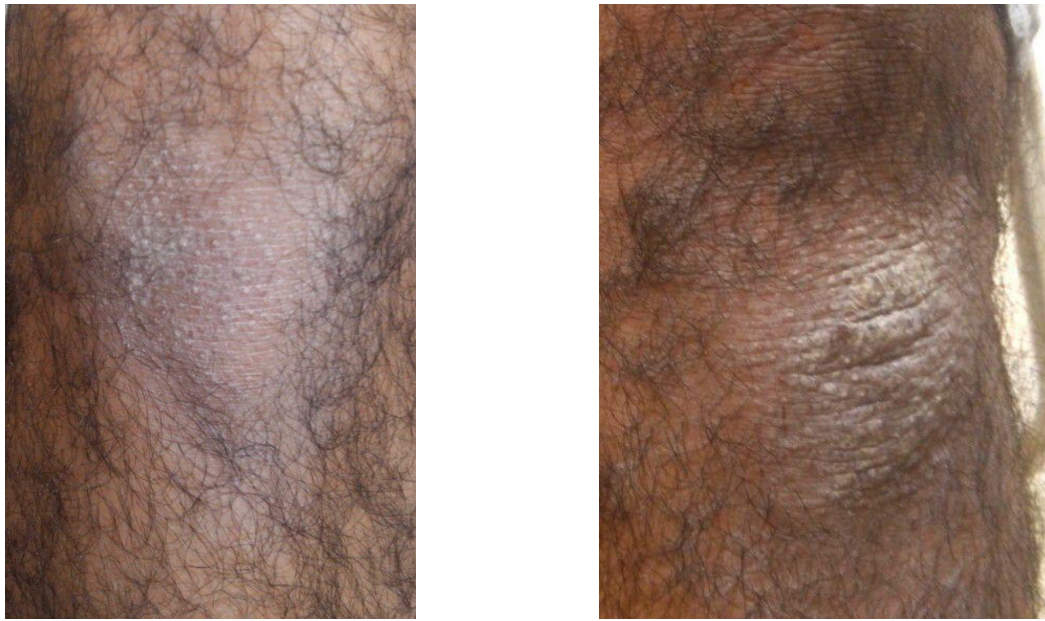


Figure 2. Patient's knee surface after receiving psychiatric treatment



### Dermatological lesions

On dermatologic examination, he had erythematous plaques with a diameter of 4×3 cm with a marked margin on extensor surfaces of both knees (Figure 1). According to the telemedicine consultation with dermatologist, the morphology of the lesions was suggestive of psoriasiform eruption. The patient's skin cleared within one week of receiving psychiatric treatment. Except for applying an emollient (i.e. ointment zinc oxide) no other specific oral or topical treatment for the psoriasiform lesions were prescribed (Figure 2).

These eruptions had begun to develop over a year ago as his psychiatric condition aggravated. Meanwhile, he tried different medications but never visited a dermatologist because of his poor financial situation. His families added that during this period the patient's adherence to medical treatment was very low. After 6 months follow-up, the patient noted that his psychiatric condition as well as psoriasiform eruptions was worse as long as he deliberately changed his medical routine to what he was addicted to (perphenazine and trihexyphenidyl).

### Discussion

Development of psoriasiform eruption with the exacerbation of psychiatric disorder and subsequent remission of the lesions by controlling the disorders clearly suggests a causal relation between psychiatric disorders and skin lesions. Therefore, early detection of these cases has clinical applications since the diagnosis and control of the underlying psychiatric condition are essential for successful treatment.

### Ethical Considerations

#### Compliance with ethical guidelines

All ethical principles were considered in this article. The participant was informed about the purpose of the research and its implementation stages.

#### Funding

This research did not receive any specific grant from funding agencies in the public, commercial, or not-for-profit sectors.

#### Conflict of interest

The authors declare no conflict of interest.

#### Acknowledgements

We would like to thank the patient for his cooperation.

### References

- [1] Jafferany M. Psychodermatology: A guide to understanding common psychocutaneous disorders. *Primary Care Companion to the Journal of Clinical Psychiatry*. 2007; 9(3):203-13. [PMID] [PMCID]

- [2] National Psoriasis Foundation. Statistics [Internet]. 2018 [Cited 2018 June 2]. Available from: <https://www.psoriasis.org/content/statistics>
- [3] UpToDate. Treatment of psoriasis in adults [Internet]. 2018 [cited 2018 June 2]. Available from: <https://www.uptodate.com/contents/treatment-of-psoriasis-in-adults>
- [4] Fortune DG, Richards HL, Griffiths CEM. Psychologic factors in psoriasis: Consequences, mechanisms, and interventions. *Dermatologic Clinics*. 2005; 23(4):681-94. [DOI:10.1016/j.det.2005.05.022] [PMID]
- [5] Szumański J, Kokoszka A. [Psychological factors in psoriasis: review of literature (Polish)]. *Psychiatria Polska*. 2001; 35(5):831-8.
- [6] Shafii M, Shafii SL. Exploratory psychotherapy in the treatment of psoriasis: Twelve hundred years ago. *Archives of General Psychiatry*. 1979; 36(11):1242-5. [DOI:10.1001/archpsyc.1979.01780110096012]