



Case Reports

Journal Homepage: <http://crp.tums.ac.ir>

Amyloidosis With Periorbital Rash

Morteza Daraei¹, Goli Siri², Seyed Farshad Allameh¹, Masryam Lotfi³, Samira Alesaeidi^{4,5*}

1. Department of Internal Medicine, Imam Khomeini Hospital, Tehran University of Medical Sciences, Tehran, Iran.
2. Department of Internal Medicine, School of Medicine, Tehran University of Medical Sciences, Tehran, Iran.
3. Department of Pathology, Amir Alam Hospital, Tehran University of Medical Sciences, Tehran, Iran.
4. Rheumatology Research Center, Tehran University of Medical Sciences, Tehran, Iran.
5. Department of Rheumatology, Amir Alam Research Center, Amir Alam Hospital, Tehran University of Medical Sciences, Tehran, Iran.



Citation Daraei M, Siri G, Allameh SF, Lotfi M, Alesaeidi S. Amyloidosis With Periorbital Rash. Case Reports in Clinical Practice. 2018; 3(3):79-82.

Running Title Amyloidosis With Periorbital Rash.



Funding: See Page 78

Article info:

Received: 10 July 2018

Revised: 20 August 2018

Accepted: 08 September 2018

Keywords:

Amyloidosis, Congo red,
Duodenal biopsy

ABSTRACT

We presented a middle-aged woman with nonspecific signs and symptoms, including dyspnea, lower limb edema, and elevated jugular venous pressure. Among these, the skin changes including nail changes, macroglossia and periorbital rash were the most important clues to suspect primary amyloidosis. Paraclinical studies were anemia, proteinuria and restricted cardiomyopathy. Abdominal fat pad biopsy is usually the first step to confirm the amyloidosis. However, despite the negative histologic result of fat-pad biopsy, we performed duodenal biopsy that confirmed amyloidosis. This case report demonstrates the important value of duodenal tissue in order to conform the diagnosis of amyloidosis.

Introduction

A

L amyloidosis is the most common type of amyloidosis in developed countries which is estimated to have an incidence

of 9 cases per million person-years [1]. As it is a clinicopathologic syndrome, besides noticing clinical signs, choosing the appropriate site of biopsy is important [2]. In this article, we demonstrate the importance of duodenal biopsy for diagnosis of amyloidosis.

* Corresponding Author:

Samira Alesaeidi, PhD.

Address: Rheumatology Research Center, Tehran University of Medical Sciences, Tehran, Iran.

E-mail: dr.saeidi62@yahoo.com

Case Presentation

A 49-year-old woman referred to the outpatient clinic because of dyspnea and lower limbs edema. She reported gradually exacerbating dyspnea on exertion since one year ago that recently crippled her of doing daily living. She did not complain of chest pain, cough, orthopnea or other respiratory symptoms.

She was well since three years earlier when she developed recurrent bilateral temporary ecchymotic plaques over eyelids. An image of these rashes was taken by her daughter and is shown in [Figure 1](#). These rashes emerged spontaneously and faded over 2-3 weeks. One month before this evaluation, she had an episode of generalized tonic-clonic seizure. Brain magnetic resonance imaging was normal but electroencephalography showed abnormal spike waves. Valporic acid was prescribed and seizure did not recur.

She admitted for further evaluations. On examination, her blood pressure was 100/65 mm Hg, pulse rate 72 beats/minute, respiratory rate 16 breaths/minute with normal oxygen saturation and she was afebrile. At the time of examination, there were not rashes in periorbital area, but mild macroglossia was noted. Lung exam was normal. There was audible S3 sound on cardiac auscultation and her jugular venous pressure was also elevated. No lymphadenopathy or organomegaly was detected. Musculoskeletal and neurologic exams were normal. Distal and proximal forces and also tendon reflexes were all symmetrically normal. Bilateral mild +1 lower limb edema was evident. The nails were atrophic and had longitudinal ridges ([Figure 2](#)).

Initial laboratory tests showed normocytic normochromic anemia (hemoglobin level was 10.9 g/dL), serum iron level was 33 µg/dL (reference range: 50-170 µg/dL), ferritin 78 ng/mL (10-120 ng/mL), total iron binding capacity of 365 µg/dL (250-450 µg/dL) and urinary protein excretion was 324 mg/24 hours. Fasting blood sugar, prothrombin and partial thromboplastin times, serum electrolytes, creatinine and creatinine kinase lev-

els were normal and serologic tests for alphabetic viral hepatitis and human immunodeficiency viruses were all negative. Antiphospholipid panel, rheumatoid factor, antinuclear antibody, antineutrophil cytoplasmic auto-antibodies were all undetectable. Immunoglobulin assay showed elevated IgG (28 g/L), IgA (6 g/L) and IgM (4 g/L) levels.

Electrocardiography showed low voltage sinus rhythm with left anterior hemi-block and chest radiography revealed cardiomegaly. Left ventricular dysfunction, mild pericardial effusion and restricted cardiomyopathic pattern were detected on echocardiography. We suspected amyloidosis as the most probable diagnosis and performed abdominal fat pad biopsy which did not show evidence of amyloid deposition. As amyloidosis was the first priority in our differentials, upper endoscopy was performed and a specimen from D₂ segment of duodenum confirmed amyloid deposition in thickened vascular wall stained with Congo-red ([Figure 3](#)). Bone marrow examination and serum protein electrophoresis showed no evidence of concomitant multiple myeloma.

Discussion

Our case is a middle-aged woman presenting with dyspnea due to restricted cardiomyopathy, non-nephrotic range proteinuria, hyperimmunoglobulinemia with characteristic periorbital rash. All aforementioned evidence may suggest amyloidosis. To make a correct diagnosis, as in any field of diagnostic medicine, a high index of suspicion is essential. Knowing the sensitivity of different diagnostic tools is vital for proper clinical decisions and as in this case, in the presence of indicative clinical signs and symptoms, a negative screening test result should not deviate a clinician from correct diagnosis and sometimes more tests are required.

Amyloidosis are heterogeneous group of diseases characterized by fibrillar protein deposition in extracellular tissues. Different kinds of amyloidosis are classified depending on the misfolded proteins types and their mani-

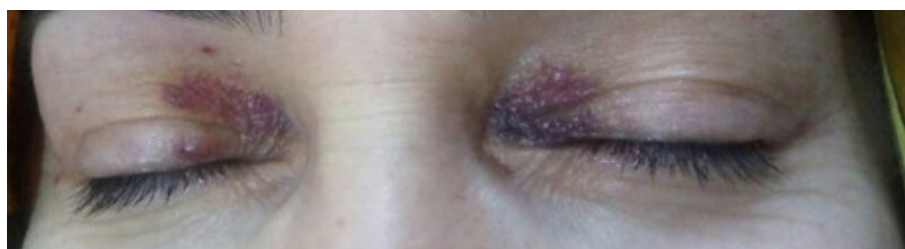

Figure 1. Bilateral ecchymotic purple plaques over upper eyelids

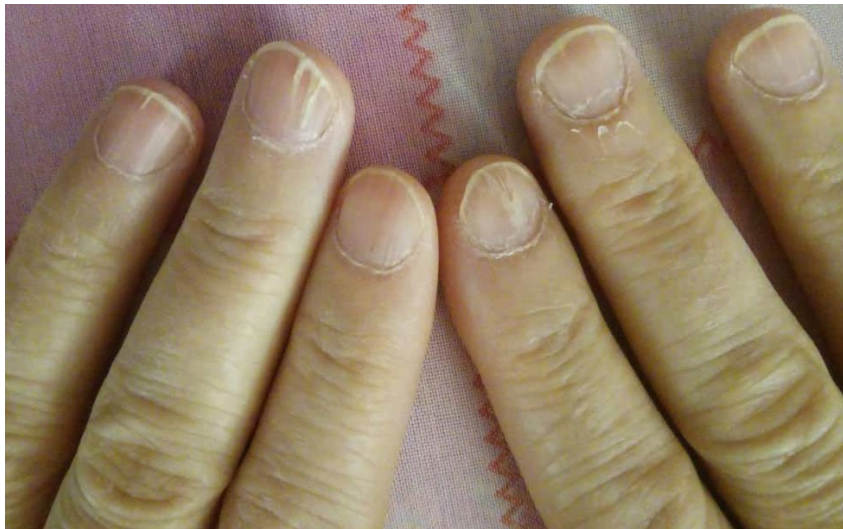

Figure 2. Longitudinal ridges over nails



festations depends on type, site, and amounts of these fibrils [3].

AL (primary) amyloidosis is one of the most common types of amyloidosis [4]. In which immunoglobulin light chain fibrils are culprit and is associated with plasma cell dyscrasias. Almost any organ can be affected except central nervous system which is rarely involved in AL amyloidosis [3, 5, 6]. We don't know whether our patient's seizure is associated with amyloidosis or it is just an irrelevant finding.

Renal and cardiac involvement are the most common organ dysfunction in amyloidosis. Renal deposits results in proteinuria usually with normal serum creatinine level. Cardiac involvement results from myocardial infiltrations that induce restrictive cardiomyopathy, heart failure and or conduction abnormalities. Signs of right sided hear failure are dominated. Cardiac involvement

is responsible for about half of mortality rates in these patients [3, 7].

The definite diagnosis of amyloidosis requires an appropriate clinical setting and confirmation with histologic examination. The Mayo Clinic and the International Myeloma Working Group introduced diagnostic criteria for AL amyloidosis, including "all" these entities: 1. Presence of at least an amyloid-related systemic syndrome; 2. Congo-red staining of the amyloid deposits; 3. Evidence that the amyloid is light chain-related; and 4. Evidence of a monoclonal plasma cell proliferative disorder (But rare cases of AL amyloidosis do not meet this criteria) [2].

Choosing an appropriate site for biopsy is an important decision. Although biopsy of an involved organ can be diagnostic but because there is always concern about risk of bleeding, due to mechanisms such as acquired coagu-

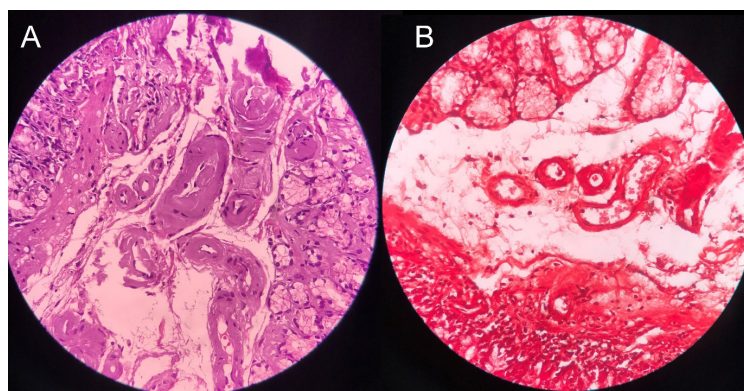


Figure 3. Duodenal D₂ segment biopsy

Duodenal biopsy examined with by hematoxylin & eosin (panel A) and Congo red staining (panel B) showing an abnormally thickened vascular walls with amorphous amyloid deposition.



lation factors deficiency especially factor X, less invasive procedures are preferred. The abdominal fat pad biopsy is simple, safe, sensitive and first choice for screening. However, because of 80% sensitivity of abdominal fat aspirate, negative results do not exclude the diagnosis [8-10], hence if the clinical setting is still in favor of amyloidosis other sites should be selected for biopsy.

Duodenal specimen has a high sensitivity for detecting amyloid deposits and in a study 100% of cases were diagnosed by this method [11]. As AL amyloidosis is associated with other plasma dyscrasias [3], the bone marrow biopsy could be examined both for evaluating associated multiple myeloma and also staining with Congo red. Staining of bone marrow specimen has about 60% sensitivity for detecting amyloidosis [12]. This case implies the valuable examination of duodenal biopsy in order to confirm amyloidosis. Because of similarity of AL amyloidosis and multiple myeloma, chemotherapy with drugs such as melphalan and glucocorticoid is suggested for treatment [3], so the patient was referred to an expert oncologist for treatment. As she had heart failure, she was not candidate for bone marrow transplantation and chemotherapy was started for her.

Ethical Considerations

Compliance with ethical guidelines

All ethical principles were considered in this article. The participants were informed about the purpose of the research and its implementation stages and the pictures were taken with patient's consent.

Funding

This research did not receive any specific grant from funding agencies in the public, commercial, or not-for-profit sectors.

Conflict of interest

The authors declare no conflict of interest.

Acknowledgements

We kindly thank Dr. Mohsen Esfandbod, Hematologist- Oncologist, who accepted to start chemotherapy for the patient.

References

- [1] Real de Asúa D, Costa R, Galván JM, Filigheddu MT, Trujillo D, Cadiñanos J. Systemic AA amyloidosis: Epidemiology, diagnosis, and management. *Clinical Epidemiology*. 2014; 6:369-77. [DOI:10.2147/CLEP.S39981] [PMID] [PMCID]
- [2] Rajkumar SV, Dimopoulos MA, Palumbo A, Blade J, Merlini G, Mateos MV, et al. International myeloma working group updated criteria for the diagnosis of multiple myeloma. *The Lancet Oncology*. 2014; 15(12):e538-e48. [DOI:10.1016/S1470-2045(14)70442-5]
- [3] Falk RH, Comenzo RL, Skinner M. The systemic amyloidoses. *New England Journal of Medicine*. 1997; 337(13):898-909. [DOI:10.1056/NEJM199709253371306] [PMID]
- [4] Hazenberg BP. Amyloidosis: A clinical overview. *Rheumatic Diseases Clinics of North America*. 2013; 39(2):323-45. [DOI:10.1016/j.rdc.2013.02.012] [PMID]
- [5] Benson M, Witt T, Bonnin J, Matthews B, Abonour R. Light chain (AL) amyloidosis in the Central Nervous System (CNS). *Amyloid*. 2011; 18(suppl1):112-3. [DOI: 10.3109/13506129.2011.574354041] [PMID]
- [6] Huang X, Wang Q, Jiang S, Chen W, Zeng C, Liu Z. The clinical features and outcomes of systemic AL amyloidosis: A cohort of 231 Chinese patients. *Clinical Kidney Journal*. 2014; 8(1):120-6. [DOI:10.1093/ckj/sfu117] [PMID] [PMCID]
- [7] Shah KB, Inoue Y, Mehra MR. Amyloidosis and the heart: A comprehensive review. *Archives of Internal Medicine*. 2006; 166(17):1805-13. [DOI:10.1001/archinte.166.17.1805] [PMID]
- [8] Sucker C, Hetzel GR, Grabensee B, Stockschlaeder M, Scharf RE. Amyloidosis and bleeding: Pathophysiology, diagnosis, and therapy. *American Journal of Kidney Diseases*. 2006; 47(6):947-55. [DOI:10.1053/j.ajkd.2006.03.036] [PMID]
- [9] Caldas CAM, de Carvalho JF. Diagnosis of amyloidosis. Tehran: InTech; 2013. [DOI: 10.5772/52901]
- [10] Gameraen IIV, Hazenberg BP, Bijzet J, Rijswijk MHV. Diagnostic accuracy of subcutaneous abdominal fat tissue aspiration for detecting systemic amyloidosis and its utility in clinical practice. *Arthritis & Rheumatology*. 2006; 54(6):2015-21. [DOI:10.1002/art.21902] [PMID]
- [11] Tada S, Iwashita A, Matsui T, Fuchigami T, Yamamoto T, Yao T, et al. Endoscopic and biopsy findings of the upper digestive tract in patients with amyloidosis. *Gastrointestinal Endoscopy*. 1990; 36(1):10-4. [DOI:10.1016/S0016-5107(90)70913-3]
- [12] Swan N, Skinner M, O'hara CJ. Bone marrow core biopsy specimens in AL (primary) amyloidosis: A morphologic and immunohistochemical study of 100 cases. *American Journal of Clinical Pathology*. 2003; 120(4):610-6. [DOI:10.1309/PFUGHBX0TY20E08U] [PMID]