



Case Reports

Journal Homepage: <http://crp.tums.ac.ir>

Limb Cutis Aplasia With Brain Thrombosis

Saeid Jedary Attary¹, Raziieh Sangsari^{1*}, Maliheh Kadivar^{1,2}

1. Department of Pediatrics, Division of Neonatology, School of Medicine, Tehran University of Medical Sciences, Tehran, Iran.

2. Children's Medical Center, Tehran University of Medical Sciences, Tehran, Iran.

**Citation** Jedary Attary S, Sangsari R, Kadivar M. Limb Cutis Aplasia With Brain Thrombosis. Case Reports in Clinical Practice. 2018; 3(3):83-86.**Running Title** Cutis Asplasia.**Funding:** See Page 81**Article info:****Received:** 23 June 2018**Revised:** 19 July 2018**Accepted:** 02 August 2018**Keywords:**

Skin, Thrombosis, Brain ischemia

ABSTRACT

Cutis aplasia is a rare, benign, congenital, and localized skin defect disorder with multiple underlying causes. Vascular events are one of the underlying causes. However, they are not a common cause. Small cutis aplasia without bony defect gradually heals without any complication. Rare complications are seen in scalp aplasia with bony defect like hemorrhage, meningitis and thrombosis. We reported a neonate with limb skin aplasia of 4×3 cm size and normal other physical signs and symptoms. Gradually he developed overriding of skull sutures near his discharge time. We found a similar picture of the brain ischemia in imaging on the 24th day of his birth. This case and the similar cases may suggest an association between the vascular events and the cause of the disease. Thus, it is important to consider thrombosis and other vascular events in every patient with cutis aplasia even in a neonate with normal examination in the first day. We recommend that physicians should not judge that the disease always has a good prognosis and follow up the patients' condition anyway.

Introduction

Cutis aplasia is a benign skin defect that are usually observed in scalp but it can be rarely detected in every site of body [1]. Although the midline lesions are common feature, symmetric aplasia has been reported, too [2, 3]. It is usually isolated without any

malformations and gradually heals [1] without special treatment except cleaning care [3].

Rarely, few complications are observed in full-thickness defect, especially in scalp defects and along bony defects like hemorrhage, thrombosis and meningitis [1]. These complications worsen the patient's prognosis [4]. These types of full-thickness skin and bony defects

* Corresponding Author:

Raziieh Sangsari, MD.

Address: Department of Pediatrics, Division of Neonatology, School of Medicine, Tehran University of Medical Sciences, Tehran, Iran.

E-mail: raz3532@yahoo.com

need surgical interventions [5]. Sometimes, it may be associated with chromosomal disorders and syndromes. Some comorbidities are reported in these patients like persistence of the ductus arteriosus, tracheoesophageal fistula, epidermolysis bullosa; limbs, renal, craniofacial malformations; and cleft lip and palate; but all of them are rare [3, 6]. Regarding these studies and explanations, a neonate with normal physical examination and a small limb cutis aplasia seems to have a benign outcome and does not need additional diagnostic and therapeutic measures. However, we report a normal boy neonate with a limb skin aplasia. We expected his normal discharge with good outcome, but he showed overriding of skull sutures and probably brain ischemia in follow up.

Case Presentation

A preterm male newborn 36 weeks and 7 days old, with a circular skin defect, 4×3 cm in size in right forearm was referred to the Neonatal Intensive Care Unit of Children's Hospital Medical Center of Tehran on September 19th, 2017. The newborn had 2.4 kg weight and 33.5 cm head circumference. The skin defect had yellow discharge with mild edema in distal fingers. Two small ecchymosis were seen on tip of two fingers distal to skin defect. Pulses and capillary filling in distal wrists were normal and symmetric.

Other physical examinations and limbs' movements were normal except in distal right hand. He had right wrist drop and absent grasp in right hand. Other neurological examinations were normal. His mother was 28 years old, gravid 2, para 2, live 2, abort 0 and had not experienced any disorder or medication before and during her pregnancy. Her first trimester sonography was

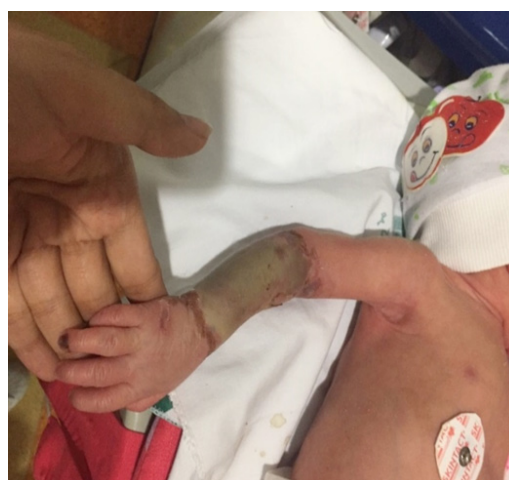

Figure 1. Cutis aplasia skin defect with two small fingers ecchymosis

normal, another sonography was missed. Preterm labor was due to thick meconium. She had gotten varicella infection in childhood and she had not suffered from any infection during her pregnancy. The infant's parents were not consanguineous.

Cutis aplasia with secondary infection was the first diagnosis. Then we treated the baby with antibiotic (cloxacillin and amikacin) after sending cultures. We did orthopedic and dermatologic care, too. In electromyogram and nerve conduction velocity test, severe axonal type lesions of right ulnar and median nerve were detected, which could have been due to full-thickness skin defect. The cardiac examination revealed normal structure. Laboratory data such as complete blood count, biochemistry, prothrombin time, partial thromboplastin time, C-reac-

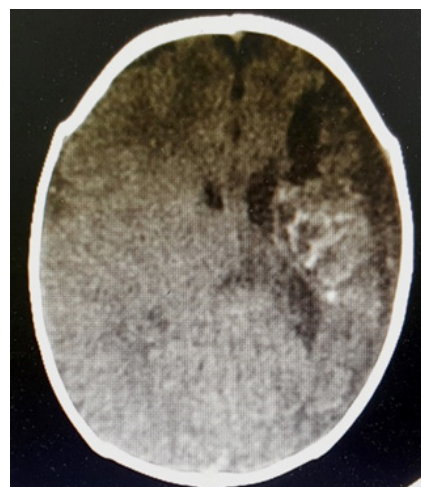
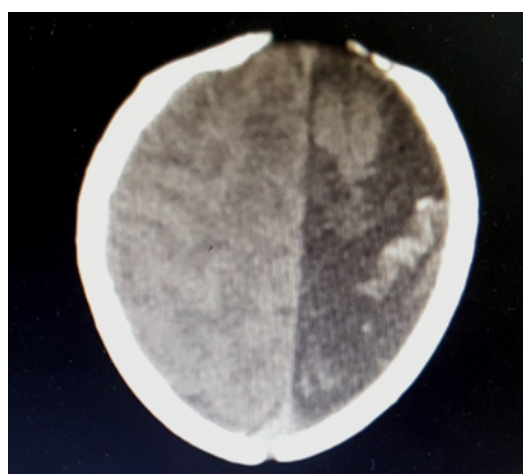


Figure 2. Brain computed tomography scan, old infarction and calcium deposition around the left mid-cerebral artery

tive protein, blood culture, skin culture, and toxoplasmosis, rubella, cytomegalovirus, herpes simplex, and HIV (TORCH) study were normal. In color Doppler ultrasonography of hand, normal flow was observed, too.

After antibiotic treatment, skin discharge and edema improved and a skin defect according to cutis aplasia remained. Two small fingers ecchymosis decreased but remained (Figure 1). After few days along with the improvement of the disease and close to the discharge time, at 22 days, the neonate did not show any head circumference growth (HC=34) and overriding of skull sutures were found in physical examination. So more studies were done. In brain sonography on the 23rd day, germinal matrix hemorrhage in right caudothalamic groove, periventricular leukomalacia, and left ventricle dilatation secondary to ischemia were observed. In brain computed tomography scan on the 24th day, prominent parenchymal atrophy was detected. Around left mid-cerebral artery, old infarction and calcium deposition were noted. Right cerebral hemisphere was normal (Figure 2).

Protein C, S, anti-thrombin 3, homocysteine, antiphospholipid antibodies, and prothrombin gene *G2021* PCR were performed to rule out thrombotic diseases, however the test results were in normal ranges, too. We recommended Magnetic Resonance Angiography (MRA) for studying the vessels and confirming brain ischemia but his parents did not agree. The baby was discharged with the parents' consent. Although his parents gave us verbal consent for reporting this case before discharge but they refused any further diagnostic and therapeutic procedure for the baby who died 3 month later at home.

Discussion

Cutis aplasia is a benign skin defect that is usually isolated and is repaired gradually with supportive treatment such as cleaning care. It usually heals without any important complications [1, 2]. Some cases of large and full-thickness scalp cutis aplasia have been reported with sagittal sinus hemorrhage or thrombosis, especially in full-thickness skin defect with bony defect [7]. Of course, it may be a complication of scalp skin defect [1]. It is wise to think about sagittal sinus hemorrhage or thrombosis in these patients.

Small skin defects in trunk and limbs heal gradually and they will have a good prognosis [1]. However, we reported a neonate with limb cutis aplasia and normal other physical examination in admission time. It showed a picture like brain ischemia in discharge time despite our previous impression of good outcome. While we ex-

pect brain complication along with scalp skin defect and not limb defect. Then even a small cutis aplasia does not always have a good outcome or a benign disorder and needs follow up.

Multiple causes are reported for cutis aplasia such as genetic, skin tension, teratogens exposure, placental infarcts and vascular insufficiency, and so on [5]. In addition, vascular events may be a primary cause of the skin defect. In this case, if this cause is correct, then in other patients, vascular events should be more seriously considered as a cause of the defect. Of course we cannot prove our claim with one patient, but there may be an association. Thus, we should consider the association of thrombosis with cutis aplasia, too. However, even if this association exist, a normal neonate with small cutis aplasia does not always have good prognosis and must be followed up for finding causes and other possible complications.

Cutis aplasia does not always have a good prognosis. It may be associated with other malformations and therefore produce many complications. Then, complete examination and follow-up is necessary in every baby with the skin defect, even in trunk and limb areas.

Ethical Considerations

Compliance with ethical guidelines

All ethical principles were considered in this article and his parents gave us consent for reporting this case.

Funding

This research did not receive any specific grant from funding agencies in the public, commercial, or not-for-profit sectors.

Conflict of interest

The authors declare no conflict of interest.

Acknowledgements

We would like to thank the assistance of Dr. S. Sotudeh and Dr. B. Panjavi in the dermatologic and orthopedic care of this patient.

References

- [1] Burkhead A, Poindexter G, Morrell DS. A case of extensive aplasia cutis congenita with underlying skull defect and central nervous system malformation: Discussion of large skin

- defects, complications, treatment and outcome. *Perinatol.* 2009; 29(8):582-4. [[doi:10.1038/jp.2008.250](https://doi.org/10.1038/jp.2008.250)] [PMID]
- [2] Dahmardehei MA. Rare case of aplasia cutis congenita. *Acta Medica Iranica.* 2013; 51(5):341-4. [PMID]
- [3] Abulezz TA, Shalkamy MA. Aplasia cutis congenita: Two cases of non-scalp lesions. *Indian Journal of Plastic Surgery.* 2009; 42(2):261-4. [[DOI:10.4103/0970-0358.59297](https://doi.org/10.4103/0970-0358.59297)] [PMID] [PMCID]
- [4] Brzezinski P, Pinteala T, Chiriac AE, Foia L, Chiriac A. Aplasia cutis congenita of the scalp- what are the steps to be followed? *An Bras Dermatol.* 2015; 90(1):100-3. [[DOI:10.1590/abd1806-4841.20153078](https://doi.org/10.1590/abd1806-4841.20153078)] [PMID] [PMCID]
- [5] Bharti G, Groves L, Lisa RD, Sanger C. Aplasia cutis congenita: Clinical management of a rare congenital anomaly. *Journal of Craniofacial Surgery.* 2011; 22(1):159-65. [[DOI:10.1097/SCS.0b013e3181f73937](https://doi.org/10.1097/SCS.0b013e3181f73937)]
- [6] O'Neill JK, Carter M, Warr RP. Aplasia cutis congenita. A case of scalp defect repair using two opposing bipediced local flaps. *Journal of Plastic, Reconstructive & Aesthetic Surgery.* 2010; 63(3):e242-4. [[DOI:10.1016/j.bjps.2009.06.005](https://doi.org/10.1016/j.bjps.2009.06.005)] [PMID]
- [7] Kantor J, Yan AC, Hivnor CM. Extensive aplasia cutis congenita and the risk of sagittal Sinus Thrombosis. *Arch Dermatol.* 2005; 141(5):554-6. [[DOI: 10.1001/archderm.141.5.554](https://doi.org/10.1001/archderm.141.5.554)] [PMID]