



## Case Report

Journal Homepage: <http://crp.tums.ac.ir>

# Concomitant Acute Motor Sensory Axonal Neuropathy and Squamous Lung Cancer-Induced Intramedullary Spinal Cord Metastasis



Hamid Reza Fateh<sup>1</sup>, Alireza Khoshnevisan<sup>2\*</sup>, Mina Meshkini<sup>1</sup>, Aidin Heidari<sup>3</sup>

1. Department of Physical Medicine and Rehabilitation, School of Medicine, Shariati Hospital, Tehran University of Medical Sciences, Tehran, Iran.

2. Department of Neurosurgery, School of Medicine, Shariati Hospital, Tehran University of Medical Sciences, Tehran, Iran.

3. Department of Physical Medicine & Rehabilitation, School of Medicine, Isfahan University of Medical Sciences, Isfahan, Iran.



**Citation** Fateh HR, Khoshnevisan A, Meshkini M, Heidari A. Concomitant Acute Motor Sensory Axonal Neuropathy and Squamous Lung Cancer-Induced Intramedullary Spinal Cord Metastasis. Case Reports in Clinical Practice .2019; 4(2):29-34.

**Running Title:** AMSAN and Squamous Lung Cancer-Induced ISCMs

**Article info:**

**Received:** 25 March 2019

**Revised:** 05 May 2019

**Accepted:** 07 June 2019

**Keywords:**

Acute motor sensory axonal polyneuropathy; Lung cancer; Spinal cord metastasis; Acute flaccid paralysis; Paraneoplastic syndromes

**ABSTRACT**

Intramedullary Spinal Cord Metastases (ISCMs) are rare, especially in squamous non-small cell lung cancer simultaneous with Acute Motor and Sensory Axonal Neuropathy (AMSAN); diagnosing these phenomena may be challenging. We report a 56-year-old man presenting with rapidly symmetrical progressive ascending weakness and paresthesia, especially in lower extremities, urinary and fecal incontinence, without any pain or respiratory symptoms. Thoracic spine MRI with and without gadolinium revealed an enhancing intramedullary lesion at the T3-T5 level. Chest CT discovered subpleural pulmonary lesion. The result lung biopsy was consistent with poorly differentiated squamous cell carcinoma, and electrodiagnosis noted severe axonal loss in motor and sensory studies with significant membrane instability and neurogenic findings in electromyography. After 8 months, the patient received just one cycle of chemotherapy and died 6 months later. AMSAN was associated with ISCM of non-small cell lung cancer in this case, who has not been previously reported in the literature.

\* Corresponding Author:

Alireza Khoshnevisan, MD.

Address: Department of Physical Medicine and Rehabilitation, School of Medicine, Shariati Hospital, Tehran University of Medical Sciences, Tehran, Iran.

E-mail: [akhoshnevisan@tums.ac.ir](mailto:akhoshnevisan@tums.ac.ir)

## Introduction

Intramedullary Spinal Cord Metastases (ISCMs) are rare, especially in squamous non-small cell lung cancer and can demonstrate even as the first manifestation of lung cancer with pain and neurological deficits; nevertheless, ISCM has poor prognosis and no standard treatment. Intramedullary spinal cord accounts for 4.2-8.5% of central nervous system metastases and 1-3% of all intramedullary tumors [1-3].

Acute Motor and Sensory Axonal Neuropathy (AMSAN) is defined as a rare and severe subtype of Guillain-Barre Syndrome (GBS) with acute onset and rapid progression of distal weakness and sensory symptoms, absence of Muscle Stretch Reflexes (MSR), significant reduction in the amplitude of the sensory and motor nerve conduction, and a prominent active neurogenic pattern in Electromyography (EMG) [4, 5]. GBS is also known as a Paraneoplastic Neurological Syndrome (PNS) activated by an abnormal immune system response to malignancies [6]. We present an adult patient of concomitant AMSAN and single ISCM of squamous cell lung cancer with Acute Flaccid Paralysis (AFP). This case with overlapping acute axonal polyneuropathy and ISCM can be considered a diagnostic challenge.

## Case Presentation

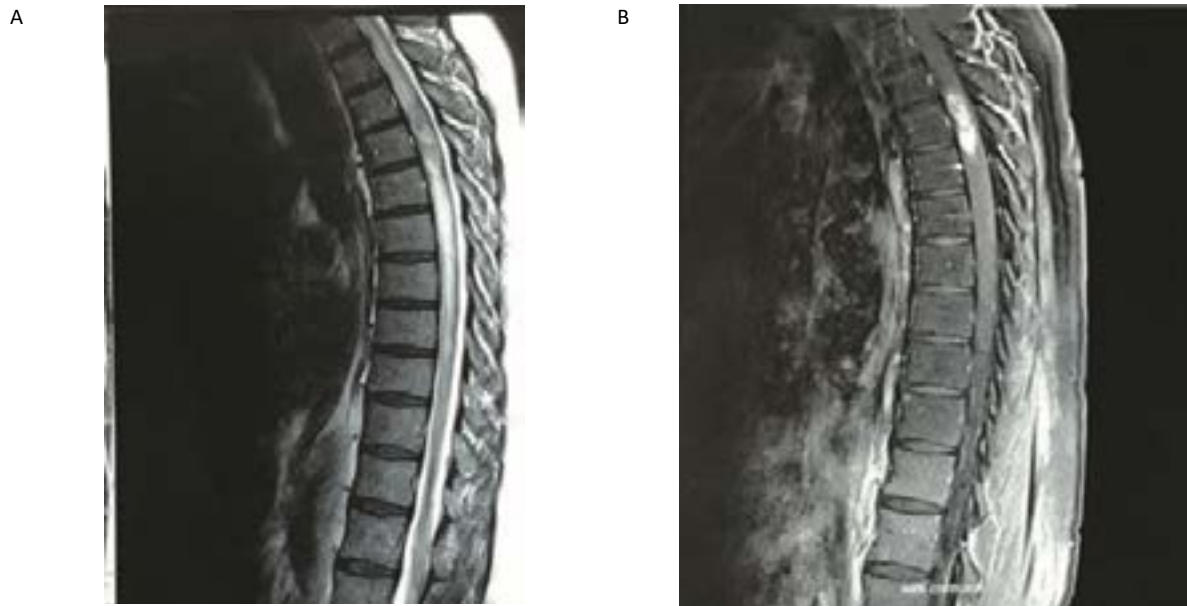
A 56-year-old male smoker with a history of chronic cough was admitted to a local hospital with acute gait and balance disturbances. His symptoms had been initiated as rapidly progressive and ascending weakness, especially in lower extremities, followed by urinary and fecal incontinence without any pain and respiratory distress. Thoracic spine Magnetic Resonance Imaging (MRI) with and without gadolinium revealed an enhancing intramedullary lesion at the T3-T5 level (Figure 1). Lumbosacral and brain MRI and viral antibody tests (Figure 2) revealed no significant abnormal findings. With initial diagnosis of Transverse Myelitis (TM), the patient was treated with one course of Intravenous Immuno-Globulin (IVIg). Despite partial response to IVIG therapy, his symptoms returned after few days.

After 2 weeks, the patient with general areflexia, partial weakness in upper extremities, flaccid lower extremities without any active contraction, and positive signs of upper motor neuron syndrome referred to a major university hospital. Considering an incongruity among neurological findings, progressive symptoms, and probable mass compression effect on thoracic cord, the patient underwent an electrophysiological evaluation, Cerebrospinal Fluid (CSF) analysis, and an excisional biopsy of the mentioned lesion. Nerve Conduc-

**Table 1.** Nerve conduction studies

NCS	Latency (ms)	Amplitude	Velocity (m/s)	
Sensory nerve conduction study	Rt median nerve	3.6	21	45
	Rt ulnar nerve	3.4	16	42
	Rt superficial peroneal nerve	NE	NE	NE
	Rt sural nerve	NE	NE	NE
	Lt median nerve	3.5	18.2	48
	Lt sural nerve	NE	NE	NE
Motor nerve conduction study	Rt median nerve	3.9	7.2	48
	Rt ulnar nerve	4.1	4.2	43
	Rt deep peroneal nerve	NE	NE	NE
	Rt tibial nerve	NE	NE	NE
	Lt median nerve	4.0	8.4	43
	Lt tibial nerve	NE	NE	NE

Amplitudes are measured in millivolt (mV, motor) and in microvolt ( $\mu$ V, sensory); NE: Not Evoked (abnormal data)

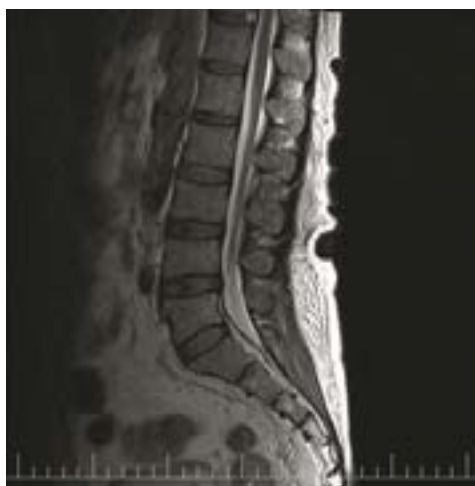

**Figure 1.** Sagittal section spinal Magnetic Resonance Images (MRI) of the Thoracic spine.

A. T2-weighted without contrast; B. Post-gadolinium MRI. There is an intramedullary mass in thoracic cord at the level of T3-T4, measuring about 30\*12\*11mm with intense contrast enhancement.

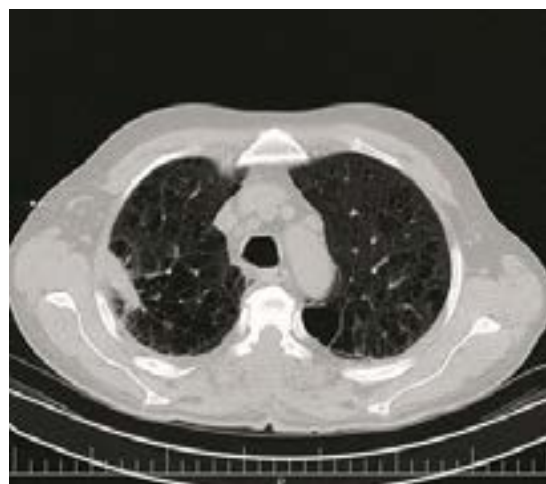tion Study (NCS) and needle EMG showed absence of Compound Muscle Action Potentials (CMAP) and Sensory Nerve Action Potentials (SNAP) of tibial, peroneal, and sural nerves, as well as polyphasic motor unit action potentials and significant active denervation sign, respectively (Table 1).

CSF analysis revealed no abnormal findings. Histomorphologic study and IHC staining of spinal cord mass revealed metastatic carcinoma probably from upper gastrointestinal and pancreaticobiliary tract. However, in gastrointestinal studies no finding had been reported related to tumor and malignancy. Eventually, contrary to radiography findings, chest Computed Tomography



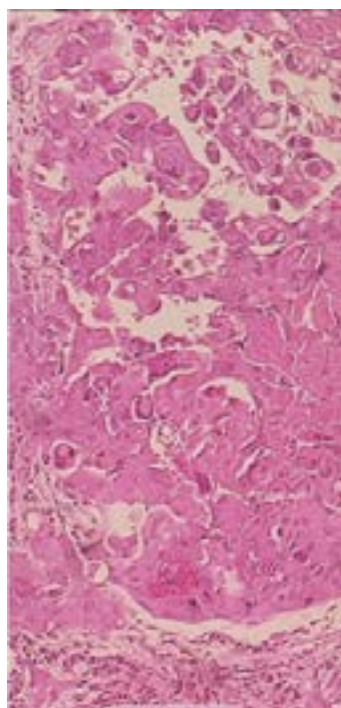
**Figure 2.** Sagittal section T2-weighted MRI of the lumbosacral spine.

The lumbar vertebral bodies and discs are normal in height and demonstrate normal alignment.



**Figure 3.** Axial section of spiral chest CT scan (with contrast).

Diffuse emphysematous changes with bullae formations are seen in upper zone of both lungs. Focal fibrotic lesion is seen in posterior segment of right upper lung lobe. Mildly enlarged mediastinal lymph nodes is seen.



**Figure 4.** Histopathological findings and IHC results of the thoracic specimen. Fragments of fibroconnective tissue by a malignant neoplasm in favor of poorly differentiated carcinoma with squamous differentiation.

(CT) scan revealed subpleural pulmonary lesion (Figure 3) and the biopsy obtained under CT guidance showed squamous cell carcinoma (Figure 4).

The patient was diagnosed with AMSAN and thoracic spinal cord metastasis of non-small cell lung cancer, so he underwent a 10-session chemotherapy. However, due to financial problems, insufficient family support, and pressure ulcer, he refused to continue treatment and eventually expired after experiencing deconditioning and immobility.

## Discussion

AFP is defined as clinical syndrome with rapid onset of severe weakness and absence of central nervous system signs. The patient's clinical manifestation suggests AFP with sensory impairments with polyradiculoneuropathies (such as Guillain-Barre Syndrome), toxic neuropathies, and myelopathies (TM and non-traumatic spinal cord injury) as differential diagnosis [7-10].

GBS is characterized by an acute inflammatory polyradiculopathy and neuropathy with consequential weakness and reflex changes and have been described, including acute inflammatory demyelinating polyradiculoneuropathy, acute motor axonal neuropathy, AMSAN,

acute sensory neuronopathy, the Fisher syndrome, and acute pandysautonomia [5, 10]. AMSAN is an unusual type of acute polyneuropathies involving both sensory and motor axons with the most severity and distribution manifested as extremities weakness, loss of sensory and muscle stretch reflexes, and possible respiratory failure.

Patients with AMSAN generally do not respond to IVIG or plasmapheresis and experience incomplete recovery. The electrodiagnostic findings are compatible with small or absent sensory and motor amplitudes in nerve conduction studies concomitant with significant degeneration signs in electromyography, while we do not expect to encounter Upper Motor Neuron (UMN) diseases in thoracic spinal cord lesions [4, 11-14]. The paraneoplastic or coincidental occurrence of GBS variants and some systemic cancers has been reported in the literature [15-17].

Clinically, ISCM can be asymptomatic or manifested by pain or a wide range of neurological compromises and autonomic dysfunction or confusing symptoms with various severities. ISCM represents less than 10% of CNS metastases; it mostly originates from lung and breast carcinomas. In contrast to small cell lung carcinoma, intramedullary spinal cord metastasis in non-small cell lung carcinoma has been reported less, and

considered a rare condition with poor prognosis with an average of 6-month survival time [1, 2, 18-21]. However, some investigations have demonstrated the role of early surgery in decreasing the symptoms and increasing of survival rate [2, 22]. As far as we know, this study is the first reported case of AMSAN associated with ISCM of squamous cell lung carcinoma and AMSAN seemingly represents the initial presentation and the main clue in diagnosis.

## Ethical Considerations

### Compliance with ethical guidelines

All ethical principles were considered in this article. The participants were informed about the purpose of the research and its implementation stages; they were also assured about the confidentiality of their information; Moreover, They were allowed to leave the study whenever they wish, and if desired, the results of the research would be available to them.

### Funding

This research did not receive any specific grant from funding agencies in the public, commercial, or not-for-profit sectors.

### Conflict of interest

The authors declared no conflict of interest.

## References

- [1] Kurtulus Duransoy Y, Mete M, Selçuki M, İşisağ A. Isolated solitary intramedullary spinal cord metastasis presenting as the first manifestation of small-cell lung cancer: Report of a rare case. *Case Reports in Neurological Medicine*. 2012; 2012(617280):1-4. [DOI:10.1155/2012/617280] [PMID] [PMCID]
- [2] Dam-Hieu P, Seizeur R, Mineo J, Metges JP, Meriot P, Simon H. Retrospective study of 19 patients with intramedullary spinal cord metastasis. *Clinical neurology and neurosurgery*. 2009; 111(1):10-7. [DOI:10.1016/j.clineuro.2008.06.019] [PMID]
- [3] Parker AL, Pugh T, Hirsch MA. A rare intramedullary spinal cord metastasis from a retroperitoneal leiomyosarcoma presenting as a non-traumatic spinal cord injury. *American Journal of Physical Medicine & Rehabilitation*. 2017; 96(7):e134-7. [DOI:10.1097/PHM.0000000000000651] [PMID]
- [4] Rostásy KM, Huppke P, Beckers B, Brockmann K, Degenhardt V, Wesche B, et al. Acute Motor And Sensory Axonal Neuropathy (AMSAN) in a 15-year-old boy presenting with severe pain and distal muscle weakness. *Neuropediatrics*. 2005; 36(4):260-4. [DOI:10.1055/s-2005-865774] [PMID]
- [5] Chowdhury D, Arora A. Axonal Guillain-Barré Syndrome: A critical review. *Acta Neurologica Scandinavica*. 2001; 103(5):267-77. [DOI:10.1034/j.1600-0404.2001.103005267.x] [PMID]
- [6] Vigliani MC, Magistrello M, Polo P, Mutani R, Chiò A, Piemonte and Valle d'Aosta Register for Guillain-Barré Syndrome. Risk of cancer in patients with Guillain-Barré Syndrome (GBS): A population-based study. *Journal of Neurology*. 2004; 251(3):3229-34. [DOI:10.1007/s00415-004-0317-3] [PMID]
- [7] Kaushik R, Kharbanda PS, Bhalla A, Rajan R, Prabhakar S. Acute Flaccid paralysis in adults: Our experience. *Journal of Emergencies, Trauma, and Shock*. 2014; 7(3):149-54. [DOI:10.4103/0974-2700.136847] [PMID] [PMCID]
- [8] Soltani J, Esmailnasab N, Roshani D, Karimi M, Amjadi MJ. Acute flaccid paralysis and its differential diagnosis in Kurdistan Province, Western Iran: An 11-year surveillance. *Iranian Journal of Pediatrics*. 2014; 24(2):131-9. [PMID] [PMCID]
- [9] Marx A, Glass JD, Sutter RW. Differential diagnosis of acute flaccid paralysis and its role in poliomyelitis surveillance. *Epidemiologic reviews*. 2000; 22(2):298-316. [DOI:10.1093/oxfordjournals.epirev.a018041] [PMID]
- [10] Vucic S, Kiernan MC, Cornblath DR. Guillain-Barré syndrome: An update. *Journal of Clinical Neuroscience*. 2009; 16(6):733-41. [DOI:10.1016/j.jocn.2008.08.033] [PMID]
- [11] Dimachkie MM, Barohn RJ. Guillain-Barré syndrome and variants. *Neurologic Clinics*. 2013; 31(2):491-510. [DOI:10.1016/j.ncl.2013.01.005] [PMID] [PMCID]
- [12] Huynh W, Kiernan MC. Nerve conduction studies. *Australian Family Physician*. 2011; 40(9):693-7.
- [13] Benecke R, Berthold A, Conrad B. Denervation activity in the EMG of patients with upper motor neuron lesions: Time course, local distribution and pathogenetic aspects. *Journal of Neurology*. 1983; 230(3):143-51. [DOI:10.1007/BF00313625]
- [14] Chung H, Joa KL, Kim HS, Kim CH, Jung HY, Kim MO, et al. Concomitant acute transverse myelitis and sensory motor axonal polyneuropathy in two children: Two case reports. *Annals of Rehabilitation Medicine*. 2015; 39(1):142-5. [DOI:10.5535/arm.2015.39.1.142] [PMID] [PMCID]
- [15] Colantuoni M, Matano E, Alfieri S, De Placido S, Carlomagno C. Guillain-Barre syndrome associated with gastric cancer: Paraneoplastic syndrome or immunological disorder. *World Journal of Oncology*. 2010; 1(6):247-9. [DOI:10.4021/wjon259w] [PMID] [PMCID]
- [16] Kiyat Atamer A, Okutur K, Tüzün E, Hasbal B, Boyacıyan A, Krespi Y, et al. Guillain-Barre syndrome in a patient with primary extranodal intestinal non-hodgkin's lymphoma: Paraneoplastic, drug induced or coincidental. *Nöro Psikiyatri Arşivi*. 2014; 51(3):288-92. [DOI:10.4274/npa.y7059] [PMID] [PMCID]
- [17] Kim MH, Hwang MS, Park YK, Park Y, Ahn YC, Oh HS, et al. Paraneoplastic Guillain-Barré syndrome in small cell lung cancer. *Case Reports in Oncology*. 2015; 8(2):295-300. [DOI:10.1159/000437295] [PMID] [PMCID]
- [18] Minomo S, Tokoro A, Utsumi T, Ishihara M, Akira M, Atagi S. A case of long-term survival after multimodal local treatments of intramedullary spinal cord metastasis of squamous cell lung cancer. *Journal of Thoracic Disease*. 2016; 8(8):E681-3. [DOI:10.21037/jtd.2016.06.58] [PMID] [PMCID]
- [19] Potti A, Abdel-Raheem M, Levitt R, Schell DA, Mehdi SA. Intramedullary Spinal Cord Metastases (ISCM) and Non-Small Cell Lung

- Carcinoma (NSCLC): Clinical patterns, diagnosis and therapeutic considerations. *Lung Cancer*. 2001; 31(2-3):319-23. [DOI:10.1016/S0169-5002(00)00177-X]
- [20] Payer S, Mende KC, Westphal M, Eicker SO. Intramedullary spinal cord metastases: An increasingly common diagnosis. *Neurosurgical Focus*. 2015; 39(2):E15. [DOI:10.3171/2015.5.FOCUS15149] [PMID]
- [21] Khoshnevisan A, Abdollahzade S, Jahanzad I, Niknezhad A, Naderi S, Khadivi M. Intramedullary spinal cord metastasis from endometrioid adenocarcinoma. *Archives of Iranian Medicine*. 2014; 17(4):293-6.
- [22] Wilson DA, Fusco DJ, Uschold TD, Spetzler RF, Chang SW. Survival and functional outcome after surgical resection of intramedullary spinal cord metastases. *World Neurosurgery*. 2012; 77(2):370-4. [DOI:10.1016/j.wneu.2011.07.016] [PMID]