



Case Report

Journal Homepage: <http://crp.tums.ac.ir>

Isolated Invasive Cerebral Mucormycosis in a Diabetic Female Patient: A Case Report With Rising Concerns

Farzad Ferdosian¹, Marzie Vaghefi^{1*}, Ehsan Sanaei²

1. Department of Pediatrics, School of Medicine, Shahid Sadoughi University of Medical Sciences and Health Services, Yazd, Iran.

2. Department of Internal Medicine, School of Medicine, Shahid Sadoughi University of Medical Sciences and Health Services, Yazd, Iran.

Use your device to scan and read the article online



Citation: Ferdosian F, Vaghefi M, Sanaei E. Isolated Invasive Cerebral Mucormycosis in a Diabetic Female Patient: A Case Report With Rising Concerns. Case Reports in Clinical Practice .2019; 4(2):35-39.

Running Title: Isolated Invasive Cerebral Mucormycosis in a Diabetes

**Article info:****Received:** 06 April 2019**Revised:** 28 April 2019**Accepted:** 16 June 2019**Keywords:**

Cerebral mucormycosis; Major thalassemia; Diabetes mellitus

ABSTRACT

Isolated cerebral mucormycosis can be life-threatening in immunocompromised patients. Sinus and lung were the most involved organs, while cerebral infection by mucormycosis is more fetal. This infection needs proper debridement and antifungal therapy. We report a 12-year-old diabetic girl with manifestations of fever, headache, and weakness in the right upper and lower extremities without any involvement of sinuses and lung. The patient had approximately normal routine laboratory data, and its CSF was not diagnostic. Because of its features in brain CT and MRI that suggested a necrotic lesion in the left parietal lobe, she was undergone craniotomy and received broad-spectrum antibiotics along with anti-fungal and anti-tuberculosis drugs. Histopathological findings of the mass, which was excised in craniotomy, confirmed the diagnosis of mucormycosis. Unfortunately, the patient died because of this invasive infection. The fatality of fungal infections, especially cerebral types, warn us to be aware of them in immunocompromised patients and perform the proper treatment to reduce its mortality.

Introduction

Invasive mucormycosis can be life-threatening, especially in children and diabetic patients with involvement of the Central Nervous System (CNS) [1]. Its CNS infection can be presented with cranial nerve paralysis

and loss of consciousness with possible skull involvement. The best management of mucormycosis consists of early diagnosis and suitable antifungal therapy with maximum debridement [2].

Roden MM et al. reviewed 929 cases in the English databases from 1885 to 2005 and reported it as the first

* Corresponding Author:

Marzie Vaghefi, MD.**Address:** Department of Pediatrics, School of Medicine, Shahid Sadoughi University of Medical Sciences, Yazd, Iran.**E-mail:** mh.vaghefi1991@gmail.com

comprehensive review article about the characteristics and outcomes of mucormycosis. They stated that the most prevalent and overall mortality were seen in diabetic individuals. Sinus (39%) and lung (24%) were the most involved organs. The mortality rate varied from 76% in pulmonary type to 96% in disseminated ones. The most underlying disease is malignancy, while diabetes reported as the underlying cause in 66% of cases [3].

Cerebral infection by mucormycosis is rare but fatal and usually happens in individuals with immune deficiency. If there is no infection in nasal sinuses or orbits, it can be called isolated cerebral mucormycosis. This type of mucor infection is strongly associated with systemic predisposing factors, like malignancy or any other situation which impairs immune system [4]. In this manuscript, we introduce an isolated cerebral mucormycosis in a diabetic girl who was worked up for fever and loss of consciousness.

Case Presentation

A 12-year-old girl suffered from major thalassemia, and type I Diabetes Mellitus (DM) was admitted to the Pediatric Intensive Care Unit of Shahid Sadoughi University Hospital, Yazd, Iran because of fever and headache in occipital and parietal areas from one month ago. Her temperature peaked at night and awakened the patient. Other symptoms were nausea and vomiting, especially in the morning and gradually decreased muscle strength in her right upper extremities. She did not complain from upper and lower respiratory tract infection and did not claim about rhinorrhea or nasal discharge. The patient also mentioned hypothyroidism, history of admission for urinary tract infection, and diabetes ketoacidosis approximately 5 years ago. She also had a history of frequent blood transfusion because of her thalassemia, and her ferritin level was more than 1500 µg/L.

She was under insulin therapy for blood sugar control and levothyroxine for hypothyroidism. In physical examination, fever was detected (38.3>°C). Neurologic evaluations confirmed that muscle strength of right upper and lower extremities decreased, while her left side extremities were in good condition. Plantar reflex was reported extended in the right side and flexed in the left foot. In comparison to the right side, her deep tendon reflex of the right knee increased. Other physical examination, including lung and heart auscultation, abdominal exams were all normal. Visual field and acuity were normal. In laboratory evaluations, normochromic normocytic anemia was detected (other laboratory data are mentioned in Table 1).

Other specific laboratory evaluations for management of Fever with Undetermined Origin (FUO) were inconclusive. Anti-diphtheria, anti-tetanus, toxoplasma antibody titers were all normal. Cerebrospinal Fluid (CSF) examination was also normal, and its culture was negative without evidence of malignancy. Flow cytometry was not done because it was expensive. Chest x-ray reported some mild nonspecific reticular pattern (Figure 1). Brain CT-scan without contrast showed vasogenic edema in the fronto-temporo-parietal areas with midline shifting and compression effect on left brain ventricle, suggesting neoplastic lesions (Figure 2).

There was no significant finding in abdominal ultrasonography and cervical color Doppler ultrasonography. No valvular vegetation was reported in cardiac echocardiography. According to the MRI report, the white matter signal changed as low T1, and high T2 with mild cortical involvement in left parietal lobe with mild punctuate enhancement and no apparent restrictions. Slight ependymal and dura arachnoid enhancement were seen. A restricted focus in left pons was noted suggesting acute ischemic changes. Differential diagnosis recommended by this MRI manifestation were septic emboli, lymphomatosis cerebri, and tuberculosis. The final diagnosis was septic emboli, lymphomatosis, or tuberculosis (Figure 3).

By worsening the patient's condition and her loss of consciousness, physicians performed craniotomy, and the extracted tissue was sent to an expert pathologist. The pathologist reported a neural tissue with multifocal neutrophils infiltration, necrosis, and hemorrhage with the presence of a few non-septic fungal hyphae. These findings were suggestive of mucormycosis. The patient was followed by anti-fungal, anti TB, meropenem, vancomycin, and trimethoprim-sulfamethoxazole

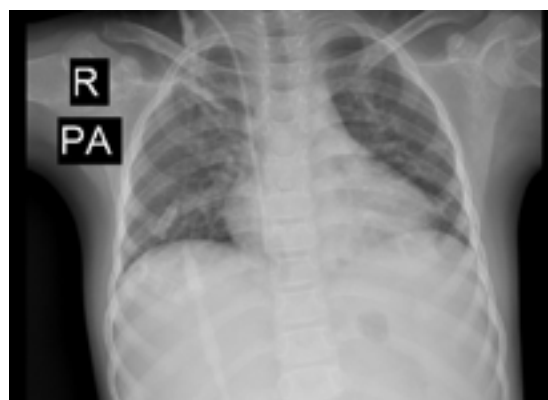

Figure 1. A mild nonspecific reticular pattern in chest X-ray

Table 1. Laboratory data of patient from admission

Test	Value	Normal Range
WBC (10 ³ /μL)	8.9	3.5-10
RBC (10 ⁹ /μL)	2.58	3.6-6.1
Hemoglobin (g/dL)	7.1	11.5-18.8
Hematocrit (%)	21.9	34-54
MCV (fL)	84.88	80-96
MCH (pg)	27.52	24-36
Platelet (10 ³ /μL)	160	165-415
Neutrophil	12	
Lymphocyte	85	
Urea (mg/dL)	25	17-42
Creatinine (mg/dL)	0.8	0.6-1.3
Albumin (g/dL)	2.8	3.5-5.2
Sodium (mEq/L)	138	134-145
Potassium (mEq/L)	3.9	3.5-5.5
Serum IgA (mg/dL)	208	70-400
T4 (mg/dL)	8.41	4.5-12.5
TSH (mIU/L)	3.87	0.3-5.0
Ferritin (ng/mL)	1336	10-148
PTH (ng/L)	5.2	10-65
ESR (1-h) (mm/h)	29	Up to 22
Blood sugar (mg/dL)	235	
CRP (mg/dL)	+++	
IgA	284	70-400
IgM	332	40-230
IgG	1869	800-1600
IgE	>2500	0-200
N.B.T	92	90-95
Isohemagglutinin	1.512 positive	
Ferritin	>1500	
TB PCR	Negative	
Pro C	27.6	70-130
Pro S	118	55-120
ANA	0.49	<0.8 negative
Anti DNA	0.60	<0.9 negative
C3	91	90-180
C4	13.5	10-40
CH50	81	
Vitamin D3 level	14.8	<10 deficiency

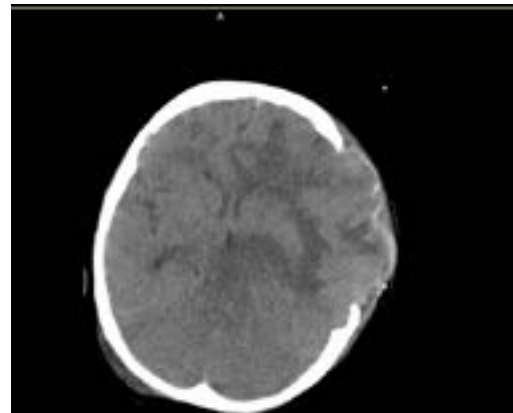
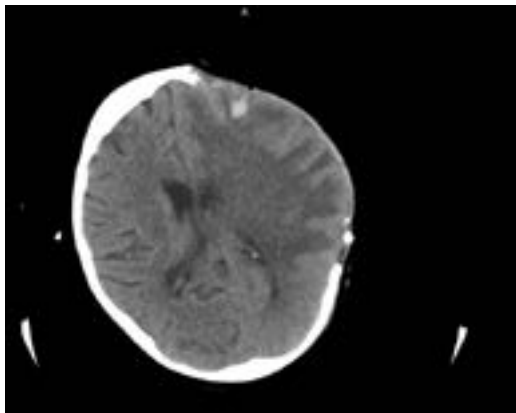


Figure 2. Brain CT without contrast fronto-temporo-parietal cut



A. Vasogenic edema with midline shifting; B. Compression effect on left brain ventricle

with proper doses. Unfortunately, the patient expired 7 days after the operation.

Discussion

One of the rare characteristics of our case was its symptoms and origin. In other words, we did not see any symptom or sign of sinus or pulmonary infection, so our case was an isolated CNS infection. Usually, in CNS infection by mucormycosis, we detect its origin in sinus or lungs [4, 5]. We also did not identify the upper and lower respiratory tract infection. Mucormycosis can be presented by any nervous system involvement like reduction in muscle strength, which was the dominant neurologic manifestation in our case. These symptoms and signs beside its fatal outcome make the mucormycosis as an important diagnosis, especially in immunocompromised individuals and diabetic ones [6].

Mucormycosis almost always needs a major defect in the immune system, such as malignancy, using any im-

munosuppressive drug, or some chronic diseases which are accompanied by a partially immune deficient situation like diabetes mellitus or thalassemia. High ferritin level in major thalassemia is another risk factor for fungal infection. Diabetes mellitus played the underlying part in this case, too [7, 8].

The best management is operation and antifungal therapy, while the mortality rate is more than 97% in cases with no specific invasive or non-invasive treatment. According to this high mortality rate, we tried our best to remove necrotic tissue by craniotomy and administer proper anti-fungal coverage [3, 9, 10]. Despite all anti-fungal and surgical treatment in our case, the patient, unfortunately, did not survive, so it is better to diagnosis invasive fungal infections as soon as possible.

In conclusion, it is crucial to be aware of invasive fetal fungal infections, like mucormycosis in immunosuppressed individuals and try to perform the operation and administer specific anti-fungal therapy as soon as

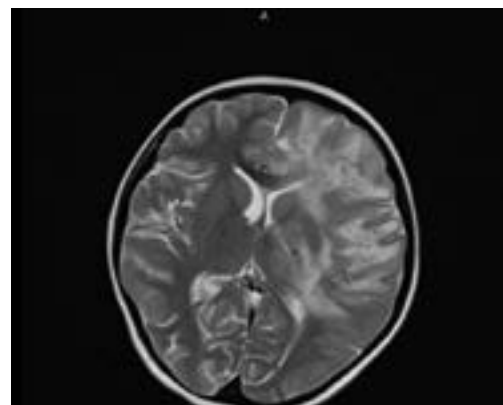
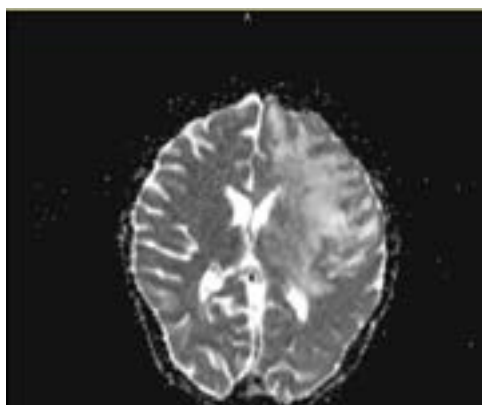


Figure 3. Brain MRI and DWI



A. White matter signal changes as high in DWI; B. Mild cortical involvement in left lobe and mild punctuate enhancement

possible to decrease mortality and morbidity rate in these cases.

Ethical Considerations

Compliance with ethical guidelines

There were no ethical considerations to be noted in this research.

Funding

This research did not receive any specific grant from funding agencies in the public, commercial, or not-for-profit sectors.

Conflict of interest

The authors declared no conflict of interest.

References

- [1] McCarthy M, Rosengart A, Schuetz AN, Kontoyiannis DP, Walsh TJ. Mold infections of the central nervous system. *New England Journal of Medicine*. 2014; 371(2):150-60. [DOI:10.1056/NEJMra1216008] [PMID] [PMCID]
- [2] Panackal AA, Williamson PR. Fungal infections of the central nervous system. *Continuum Lifelong Learning in Neurology*. 2015; 21(6):1662-78. [DOI:10.1212/CON.000000000000241] [PMID]
- [3] Roden MM, Zaoutis TE, Buchanan WL, Knudsen TA, Sarkisova TA, Schaufele RL, et al. Epidemiology and outcome of zygomycosis: A review of 929 reported cases. *Clinical Infectious Diseases*. 2005; 41(5):634-53. [DOI:10.1086/432579] [PMID]
- [4] Verma A, Brozman B, Petito CK. Isolated cerebral mucormycosis: Report of a case and review of the literature. *Journal of Neurology Sciences*. 2006; 240(1-2):65-9. [DOI:10.1016/j.jns.2005.09.010] [PMID]
- [5] Góralaska K, Błaszowska J, Dzikowiec M. Neuroinfections caused by fungi. *Infection*. 2018; 46(Suppl):1-17. [DOI:10.1007/s15010-018-1152-2] [PMID] [PMCID]
- [6] Balaguer Rosello A, Bataller L, Lorenzo I, Jarque I, Salavert M, González E, et al. Infections of the central nervous system after unrelated donor umbilical cord blood transplantation or human leukocyte antigen-matched sibling transplantation. *Biology of Blood and Marrow Transplantation*. 2017; 23(1):134-9. [DOI:10.1016/j.bbmt.2016.10.005] [PMID]
- [7] Man A, Mare A, Toma F, Curticăpean A, Santacrocce L. Health threats from contamination of spices commercialized in romania: Risks of fungal and bacterial infections. *Endocrine Metabolic & Immune Disorders-Drug Targets*. 2016; 16(3):197-204. [DOI:10.2174/1871530316666160823145817] [PMID]
- [8] Green KK, Barham HP, Allen GC, Chan KH. Prognostic factors in the outcome of invasive fungal sinusitis in a pediatric population. *Pediatric Infectious Disease Journal*. 2016; 35(4):384-6. [DOI:10.1097/INF.0000000000001015] [PMID]

atric Infectious Disease Journal. 2016; 35(4):384-6. [DOI:10.1097/INF.0000000000001015] [PMID]

[9] Ba PF, Shi LG, Li SC, Yin ZH, Wang GK. [Endoscopic sinus surgery for the treatment of invasive fungal sinusitis (Chinese)]. *Journal of Clinical Otorhinolaryngology*. 2017; 31(15):1195-8. [DOI:10.13201/j.issn.1001-1781.2017.15.013] [PMID]

[10] Irikuchi J, Imai T, Tanaka M, Tanuma M, Orii T, Kato T. Meta-analysis on the influence of antifungal spectrum on effectiveness of empirical antifungal therapy for febrile neutropenia. *Yakugaku Zasshi*. 2017; 137(9):1117-27. [DOI:10.1248/yakushi.16-00216] [PMID]