



## Case Report

Journal Homepage: <http://crp.tums.ac.ir>

# A Peritoneal Tuberculosis Mimicking Advanced Cancer: A Case Report



Mahsa Abbaszadeh<sup>1\*</sup>, Mohammadreza Salehi<sup>2</sup>, Mohammad Shirkhoda<sup>3</sup>, Sahar Karimpour Reyhan<sup>1</sup>

1. Department of Internal Medicine, Imam Khomeini Hospital Complex, Tehran University of Medical Sciences, Tehran, Iran.
2. Department of Infectious Diseases, Imam Khomeini Hospital Complex, Tehran University of Medical Sciences, Tehran, Iran.
3. Department of Surgery, Imam Khomeini Hospital Complex, Tehran University of Medical Sciences, Tehran, Iran.



**Citation:** Abbaszadeh M, Salehi M, Shirkhoda M, Karimpour Reyhan S. A Peritoneal Tuberculosis Mimicking Advanced Cancer: A Case Report. *Case Reports in Clinical Practice*. 2020; 5(2):39-42.

**Running Title:** Peritoneal Tuberculosis



## Article info:

**Received:** 22 April 2020

**Revised:** 20 May 2020

**Accepted:** 08 June 2020

## Keywords:

Tuberculosis; Peritoneal tuberculosis; Peritoneum; Ascites; Unnecessary services; Health economics

## ABSTRACT

Tuberculosis (TB) could be presented with different manifestations. On many occasions, further evaluation in patients with the first diagnosis of the lung, pancreas, ovarian, or bladder cancer leads to the definite diagnosis of TB and the symptoms subside by treatment. Concerning the easy access to diagnostic tests and dramatic treatment responses, it is essential that physicians in endemic areas consider TB in patients with suspicious symptoms and in the differential diagnosis of malignancies, to diagnose the disease sooner and by simple and inexpensive tests; thus, avoiding imposing extra expenses to patients and the health system. We reported a 45-year-old female who was evaluated for abdominal pain, significant weight loss, and ascites for the past 4 months. The mediastinal and abdominopelvic Computed Tomography (CT) scan was performed in the initial evaluations of the patient. Accordingly, massive para-aortic and mediastinal lymphadenopathies and two thyroid nodules were detected. Furthermore, considering peritoneal thickening and moderate ascites, lymphoproliferative disorders were highly suggested as the diagnosis. The laboratory test data revealed bicytopenia, Erythrocyte Sedimentation Rate (ESR:57), and a high Cancer Antigen 125 (CA125). Unfortunately, the results of paracentesis were unavailable, though cytology was negative for malignancy. Due to anemia and weight loss, endoscopy and colonoscopy were performed twice in two different clinics, of which only gastritis was reported. Multiple abdominal and vaginal sonography was performed; these assessments suggested mild splenomegaly, mesenteric engorgement and thickening, multiple para-aortic and iliac adenopathies, as well as healthy uterus and ovaries. At the beginning of admission in Imam Khomeini Hospital, the patient denied any relevant medical history or family history. With further detailed questioning, we noticed a positive TB history in the patient's grandmother, who lived with her. A Purified Protein Derivative (PPD)

\* Corresponding Author:

**Mahsa Abbaszadeh, PhD.**

**Address:** Department of Internal Medicine, Imam Khomeini Hospital Complex, Tehran University of Medical Sciences, Tehran, Iran.

**E-mail:** [m-abbaszadeh@sina.tums.ac](mailto:m-abbaszadeh@sina.tums.ac)

test was performed, which provided a negative result. Diagnostic laparoscopy was conducted, according to the observation of whitish nodules on the peritoneum and omentum, and the characteristic findings of TB, the surgeon, highly suggested TB as the definitive diagnosis. The pathology report mentioned granulomatous inflammation with a small focus of necrosis. Anti-TB treatment was initiated for the patient, and she was discharged accordingly. During three months of follow-up, the symptoms alleviated dramatically. Constitutional symptoms reduced, and bicytopenia eliminated. The most considerable issue, in this case, was unnecessary diagnostic tests and, subsequently, extra cost imposed on the health system. Such additional expense could be declined with obtaining a detailed history and performing appropriate tests toward the differential diagnosis. This issue is, unfortunately, a common mistake occurring in numerous outpatient clinics due to the high number of patient referrals.

## Introduction

Approximately one-third of the world's population is infected with Tuberculosis (TB). Furthermore, TB is among the top 10 causes of death and the leading cause of death from a single infectious agent (above Human Immunodeficiency Virus Infection & Acquired Immune Deficiency Syndrome [HIV/AIDS]) [1]. TB, the great mimicker, could be presented with different manifestations. On many occasions, patients have been diagnosed with the lung, pancreas, ovarian, and bladder cancers in the first evaluations; however, further investigations suggested it to be TB, and the symptoms had subsided with treatment.

We present a female with abdominal pain, weight loss, as well as a history of ascites and peritoneal nodularity, mimicking malignancy. In contrast, with further evaluation, peritoneal TB was revealed as a definitive diagnosis. A controversial issue, in this case, was the extra unnecessary diagnostic tests performed for the patient. Preventable harm and additional expenses could be mitigated by obtaining a detailed medical history and performing appropriate tests toward the differential diagnosis. Unfortunately, this issue is a common mistake occurring in numerous outpatient clinics, and proper policies should be considered to reduce healthcare waste.

## Case Report

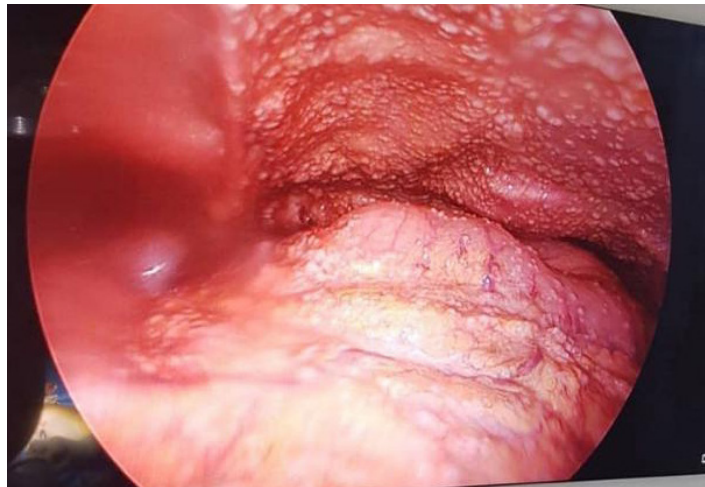
A previously healthy 45-year-old woman presented with a history of 4-month epigastric pain, decreased appetite, a 3-month abdominal distention which had subsided gradually, a transient history of nausea/vomiting, 10 kg weight loss in 3 months, night sweats, and menstrual irregularity. The abdominal pain was non-positional, and it was aggravated after eating. Her past medical history was unremarkable. The laboratory test

results indicated mild leukopenia (WBC:  $3.4 \times 10^3$  cells/mL) and mild anemia (Hb: 10.6). Erythrocyte Sedimentation Rate (ESR) was elevated to 57 mm/hr (normal: 0-20 mm/hr). Lactate Dehydrogenase (LDH): 398 U/L was moderately increased (normal: <190 U/L). Electrolytes and thyroid test functions were normal. Outpatient sonography conducted 3 months before admission suggested massive ascites with no other abnormal findings.

Paracentesis cytology was negative for malignancy; other paracentesis data were unavailable. Chest X-ray demonstrated mild scoliosis and was suggestive of bronchiectasis in the bases of both lungs. Multiple abdominal and vaginal sonography were performed and commonly reported mild splenomegaly, mesenteric engorgement and thickening, multiple para-aortic and iliac adenopathy, as well as healthy uterus and ovaries. The sonogram of axilla and mediastinum revealed a 3×6mm right axillary lymph and multiple retrosternal lymph nodes.

Tumor markers were sent, and the results indicated healthy Carcinoembryonic Antigen (CEA), Carbohydrate Antigen (CA)19-9, and a high CA125=109 (normal: ≤35). A Purified Protein Derivative (PPD) test was performed with a negative result. Abdominopelvic Computed Tomography (CT) scan with contrast reported multiple lymph nodes in the para-aortic region, aortocaval region, right iliac, celiac, retro rural and gastrohepatic region (≤45×30mm), mesenteric engorgement and thickening, peritoneal nodularity with moderate ascites, mild splenomegaly (120×50 mm), and a 6mm hypodense lesion in the liver. The lung and mediastinal CT scan with contrast revealed multiple mediastinal lymph nodes and two 17mm and 6mm thyroid nodules.

The Fine-Needle Aspiration (FNA) was performed following the observation of thyroid nodules, which was reported normal. Due to anemia and weight loss, endoscopy and colonoscopy were performed twice in two



**Figure 1.** Multiple small whitish nodules all over the peritoneum



different clinics; the relevant result reported only gastritis and *Helicobacter Pylori* (H-pylori) was positive. Echocardiography data indicated mild tricuspid regurgitation with an Ejection Fraction (EF:55%).

According to the symptoms of weight-loss, night sweats, generalized lymphadenopathy, high CA125, and sonogram findings, diagnostic laparoscopy was performed, and omental biopsies were obtained. According to the observation of multiple small whitish nodules all over the peritoneum and characteristic findings of TB, the surgeon highly suggested TB as the definitive diagnosis (Figure 1). Pathology reported granulomatous inflammation with a small focus of necrosis, i.e. negative for acid-fast bacilli in a ziehl-neelsen stain. During the first evaluation at admission, the patient denied any medical history or family history; however, after the final diagnosis and with further detailed questioning, we noticed a positive TB history in her grandmother who lived with her. Anti-TB quadruple therapy was initiated for the patient, and she was discharged accordingly. During three months follow-up, the symptoms alleviated dramatically, constitutional symptoms reduced, and bicytopenia was diminished.

## Discussion

Peritoneal TB is usually due to the reactivation of latent infection and by hematogenous dissemination from a previous pulmonary TB [2]. Our patient mentioned no history of TB. Pelvic TB could present without specific features and could be similar to other abdominal pathologies, such as peritoneal carcinomatous, intra-abdominal malignancies, and cirrhosis; thus, the diagnosis could be challenging, leading to diagnostic

delays and the development of complications. Peritoneal TB should be considered in the differential diagnosis in endemic areas for TB [3]. Several case series reported abdominal pain and fever as the two most frequent symptoms in this regard [4]. Other systemic symptoms, weight loss, fatigue, malaise, and anorexia are more prominent with peritoneal TB, compared to the other forms of abdominal TB [2]. Diarrhea is unusual; however, it can be present in one-fifth of patients. Ascites (73%) and abdominal tenderness are the prominent findings as well [5].

Diagnosis of peritoneal TB requires a high clinical suspicion. Biological examinations are not very helpful for the diagnosis. Microbiological or pathological confirmation is necessary for definitive diagnosis. Laparoscopy and direct peritoneal biopsy are currently the gold standard diagnostic procedure for TB. Radiologic imaging is not sensitive or specific. Ultra-sonographic findings include ascites (either free or loculated, in 30%-100%), echogenic debris with multiple fine strands of fibrin, and peritoneal thickening [2, 6].

CT is more sensitive in detecting abdominal lymphadenopathy and bowel thickening. Ascetic fluid cytology has a low negative predictive value in this respect. The acid-fast bacilli test in ascitic fluid is highly specific but not sensitive. The activity of ascitic fluid Adenosine Deaminase (ADA) could be a useful test for peritoneal TB cases. In populations with a high incidence of TB, the measurement of ADA may be a helpful screening test; however, in developed countries with a low rate of TB and a high prevalence of cirrhosis, ascitic fluid ADA is an appropriate inaccuracy but lacks sensitivity and specificity [7]. Considering the differential diagnosis of TB peri-

tonitis, peritoneal carcinomatosis, and ovarian cancer may be the first concerns. Increased serum CA125 levels have been reported in peritoneal TB; however, CA125 levels were usually higher in peritoneal carcinomatosis cases [8]. Laparoscopy allows direct inspection and the option of pathological and microbiological confirmation of the diagnosis. Laparoscopic examination with biopsy confirms TB peritonitis in 85% to 90% of cases [8, 9].

A positive PPD may help considering TB as a differential diagnosis; however, in our case, the PPD test result was negative. Peritoneal ascites analysis usually reveals a serum ascitic albumin gradient  $<1.1$  and high protein levels ( $>2.5$ mg/dL); we had no access to the ascites fluid in our patient.

An essential issue in this patient was extra diagnostic tests conducted for her. Multiple abdominopelvic CT scans, abdominal and vaginal sonography, repeated upper and lower endoscopy were unnecessarily performed for her in 4 months. Inappropriate diagnosis testing and overtreatment cause harm to the patient, waste in the healthcare system, and rise in healthcare costs [10]. In 2010, the Institute of Medicine (IOM) suggested “unnecessary services” as the primary contributor to waste in the United States healthcare system, accounting for approximately \$210 billion of the estimated \$750 billion in excess spending annually. Top reasons of over-diagnosis and overtreatment are fear of malpractice and litigation, patients demands, difficulty accessing prior medical records, inadequate time spent with patients, diagnostic uncertainty, insufficient knowledge of the diagnostic tools costs, the absence of feedback on testing practices, and the differing levels of healthcare professionals’ training [10, 11].

## Conclusion

Reducing unnecessary services could mitigate preventable harm to the patients and overall hospital expenditures. A 50% reduction in unnecessary services would result in \$105 billion in annual savings, or approximately 4% of total national healthcare spending [10]. A nationwide survey of the US specialties was designed to estimate physicians’ perspectives on the prevalence of overtreatment and identify potential causes and solutions. Consequently, the top possible solutions suggested by the physicians were training residents on appropriateness criteria, easy access to all health records, more practice guidelines, listing prices when ordering tests, increasing base salaries, and decreasing service fees [10].

## Ethical Considerations

### Compliance with ethical guidelines

All ethical principles were considered in this article.

## References

- [1] World Health Organization (WHO). Global tuberculosis report 2018. Geneva, Switzerland: World Health Organization; 2018. <https://apps.who.int/iris/handle/10665/274453>
- [2] Vaid U, Kane GC. Tuberculous peritonitis. *Microbiology spectrum*. 2017; 5(1):TNM17-0006-2016. [DOI:10.1128/microbiolspec.TNM17-0006-2016] [PMID]
- [3] Abbaszadeh M, Rezaei J, Hasibi M, Larry M, Ostovaneh M, Javidanbardan S, et al. Pancreatic Tuberculosis in an Immunocompetent Patient: A Case Report and Review of the Literature. *Middle East Journal of Digestive Diseases*. 2017; 9(4):239-41. [DOI:10.15171/mejdd.2017.80] [PMID] [PMCID]
- [4] Sanai FM, Bzeizi KI. Systematic review: Tuberculous peritonitis-presenting features, diagnostic strategies and treatment. *Alimentary Pharmacology & Therapeutics*. 2005; 22(8):685-700. [DOI:10.1111/j.1365-2036.2005.02645.x] [PMID]
- [5] Kapoor VK. Abdominal tuberculosis. *Postgraduate Medical Journal*. 1998; 74:459-67. <https://pmj.bmj.com/content/postgradmedj/74/874/459.full.pdf>
- [6] Pereira JM, Madureira AJ, Vieira A, Ramos I. Abdominal tuberculosis: Imaging features. *European Journal of Radiology*. 2005; 55(2):173-80. [DOI:10.1016/j.ejrad.2005.04.015] [PMID]
- [7] Katipoglu B, Basara E, Ates I, Yilmaz N. A case report of peritoneal tuberculosis: A challenging diagnosis. *Case Reports in Infectious Diseases*. 2018; 2018:4970836. [DOI:10.1155/2018/4970836] [PMID] [PMCID]
- [8] Sandikçi MU, Colakoglu S, Ergun Y, Unal S, Akkiz H, Sandikçi S, et al. Presentation and role of peritoneoscopy in the diagnosis of tuberculous peritonitis. *European Journal of Gastroenterology & Hepatology*. 1992; 7(3):298-301. [DOI:10.1111/j.1440-1746.1992.tb00984.x.] [PMID]
- [9] Wolfe JH, Behn AR, Jackson BT. Tuberculous peritonitis and role of diagnostic laparoscopy. *Lancet*. 1979; 1(8121):852-3. [DOI:10.1016/s0140-6736(79)91266-2]
- [10] Lyu H, Xu T, Brotman D, Mayer-Blackwell B, Cooper M, Daniel M, et al. Overtreatment in the United States. *PLoS One*. 2017; 12(9):e0181970. [DOI:10.1371/journal.pone.0181970] [PMID] [PMCID]
- [11] Eaton KP, Levy K, Soong C, Pahwa AK, Petrilli C, Ziemba JB, et al. Evidence-based guidelines to eliminate repetitive laboratory testing. *JAMA Internal Medicine*. 2017; 177(12):1833-9. [DOI:10.1001/jamainternmed.2017.5152] [PMID]