

RESEARCH ARTICLE

Preoperative Sterilization Preparation of the Shoulder: A Comparative Study Evaluating Gauze Sponge and Commercially Available Applicator Prep Stick

Usman Ali M. Syed, BS; Adam J. Seidl, MD; Ryan A. Hoffman, BS; Justin Bianchini, BS; Pedro K. Beredjiklian, MD; Joseph A. Abboud, MD

Research performed at The Rothman Institute, Thomas Jefferson University, Philadelphia, Pennsylvania, USA

Received: 13 February 2017

Accepted: 30 April 2017

Abstract

Background: Surgical site infection (SSI) remains a concern in shoulder surgery, especially during arthroplasty. While many studies have explored the characteristics and efficacy of different sterilizing solutions, no study has evaluated the method of application. The purpose of this study was to compare two popular pre-surgical preparatory applications (two 4 x 4 cm gauze sponges and applicator stick) in their ability to cover the skin of the shoulder.

Methods: Two orthopedic surgeons simulated the standard pre-surgical skin preparation on 22 shoulders of volunteer subjects. Each surgeon alternated between an applicator stick and two sterile 4x4 cm gauze sponges. Skin preparation was performed with a commercially available solution that can be illuminated under UV-A light. Advanced image-analysis software was utilized to determine un-prepped areas. A two-tailed paired t-test was performed to compare percentage of un-prepped skin.

Results: The applicator stick method resulted in a significantly higher percentage of un-prepped skin (27.25%, Range 10-49.3) than the gauze sponge method (15.37%, Range 5-32.8, $P=0.002$). Based on image evaluation, most un-prepped areas were present around the axilla.

Conclusion: Based on our findings, the use of simple gauze sponges for pre-surgical preparatory application of sterilization solution may result in a lower percent of un-prepped skin than commercially available applicator stick. Orthopaedic surgeons and operating room staff should be careful during the pre-surgical sterile preparation of the shoulder, especially the region around the axilla, in order to reduce the potential risk of surgical site infection.

Level of evidence: III

Keywords: Applicator stick, Gauze sponge, Infection, Shoulder, Sterile preparation, Surgical site infection

Introduction

Surgical site infection (SSI), although relatively infrequent, can be a devastating complication after shoulder surgery. The rate of infection has been reported up to 3.9% in primary shoulder arthroplasty and up to 15% in revision procedures (1-4). Pre-surgical sterilization of the shoulder is a routine procedure aimed at preventing SSI. While many studies have explored the characteristics and efficacy of different sterilizing solutions, no study has evaluated the method of application. Two popular methods for application of sterilization solution to the shoulder are utilized at our institution, an applicator stick (Chloraprep applicator,

Carefusion, San Diego, CA) and 4 x 4 cm gauze sponges. Although the method of application may be less critical in anatomic locations with limited contour and easy visibility such as the abdomen or back, un-prepped skin around the shoulder is a major concern due to the surface anatomy of the shoulder and limited direct visibility in the axilla. The purpose of this study was to determine which application method of sterilization solution yields the best coverage of skin on the shoulder. We hypothesized that the use of sterile gauze sponges would leave less un-prepped skin compared to commercially available applicator sticks.

Corresponding Author: Joseph A. Abboud, Rothman Institute, Thomas Jefferson University, Philadelphia, Pennsylvania, USA
Email: abboudj@gmail.com



THE ONLINE VERSION OF THIS ARTICLE
[ABJS.MUMS.AC.IR](http://abjs.mums.ac.ir)

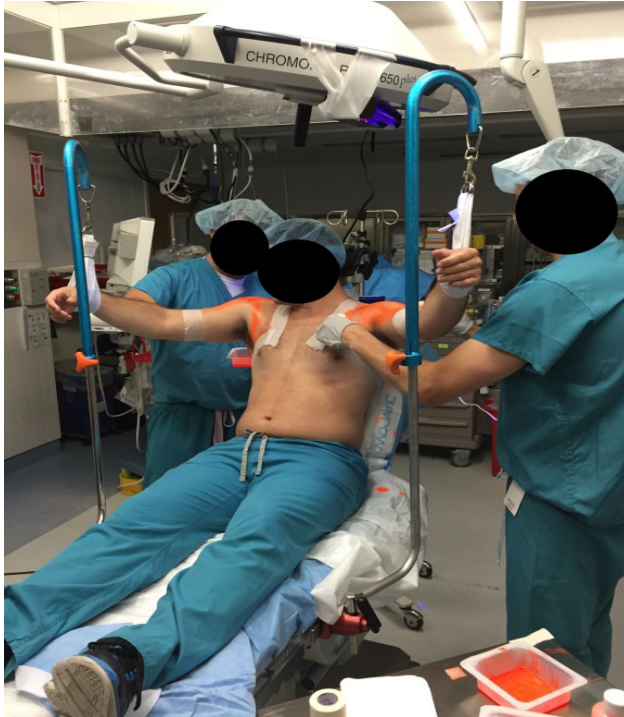


Figure 1. Depicts our surgical preparation setting with the patient in the beach chair position with the surgeons alternating between using the prep stick and the gauze sponge preparation setting with the patient in the beach chair position with the surgeons alternating between using the prep stick and the gauze sponge.

Materials and Methods

Twenty-two shoulders of healthy male volunteers were prepped by two shoulder fellowship trained orthopedic surgeons (AJS and JAA) as 11 matched pairs. Volunteers were placed supine in an operating room on an operating room table in a beach chair position to recreate a common positioning for both shoulder arthroscopy and arthroplasty.

Both shoulders were suspended off an adjustable candy cane style stirrup to recreate the pre-operative sterilization environment [Figure 1] with the shoulder in approximately 90 degrees of abduction and 45 degrees of external rotation. The surgeons sterilized the shoulder to the same standards used in the operating room setting and no maximum time limit was allotted to prepare each shoulder. The surgeons alternated between the two methods of application using either 4 x 4 cm gauze sponges or an applicator stick (Chloraprep applicator, Carefusion, San Diego, CA) immersed in a commercially available mineral oil solution. Each subject was tested as a matched pair with one shoulder sterilized using the 4 x 4 cm sponges and the contralateral shoulder using the applicator stick.

The solution used to assess methods of application is a commercially available mineral oil (GloGerm, Moab UT) that can be illuminated under UV-A light. This solution is used commercially as a visual training tool for hand washing and aseptic techniques. A new, unused applicator stick or 4X4 cm gauze pads were used on each shoulder. Two UV-A lights (GE, (Fairfield, CT), T12 Fluorescent Blacklight Lamp) were utilized, one placed postero-superior and one placed anterior to the shoulder. Prior to the prep, the shoulders were cleaned and checked under UV light to ensure no preexisting sites of illumination were present. Once the skin preparation was complete, overhead and room lights were switched off and the UV-A lights were turned on. A high-resolution digital camera (Nikon D3200, 24.2 MP) was used to document digital photographs of the anterior and posterior aspect of the shoulder.

An independent evaluator (JB) blinded to the preparation process evaluated the digital photographs to determine areas of un-prepped skin, referred to as regions of interest (ROIs) with the use of the NIS-Elements Advanced Research image-analysis software (Nikon Inc., Melville, NY). The threshold was created to include only a range of colors corresponding to the ROIs. This was done by visual evaluation of areas that did not illuminate under UV-A light. The threshold settings were then applied to all analyzed pictures. The total surface areas of the analyzed surfaces were defined by applying a separate hue threshold that isolated the shoulder from the background [Figure 2].



Figure 2. An example of the digital photographs before and after evaluation with the NIS-Element Advanced Research image analysis software. Notably, the region around the axilla remains largely un-prepped with the applicator stick.

The surface area of the ROIs was calculated for each shoulder and then was expressed as the percentage of the total surface area of the shoulder. The resulting percentages were statistically analyzed using a matched pair t-test.

Results

Un-prepped Area

The applicator stick method resulted in a significantly higher percentage of un-prepped skin (27.25%, Range 10%-49.3%) compared the gauze sponge method (15.37%, Range 5%-32.8%). This difference was statistically significant ($P=0.002$) [Table 1]. Based on visual evaluation of the images, the majority of the un-prepped areas were present around the axilla region [Figure 1].

Table 1. Percentage of un-prepped areas for each subject using the gauze sponge or the "prep stick"

Subject	"Prep Stick" (%)	Gauze Sponges (%)
Subject 1	49.379	32.797
Subject 2	10.077	10.683
Subject 3	22.505	24.918
Subject 4	41.882	14.494
Subject 5	29.058	11.01
Subject 6	19.474	15.643
Subject 7	18.541	9.191
Subject 8	15.701	10.215
Subject 9	46.95	26.152
Subject 10	32.593	9.008
Subject 11	13.6	5.011
AVERAGE	27.25 (+/- 13.77)*	15.37 (+/- 8.75)*

*P-value= 0.002

Surgeon Comparison

Comparing the percentage of un-prepped skin between the two surgeons applying the solution, there were no differences with the applicator ($P=0.72$) or gauze sponges [Table 2, $P=0.24$]. Additionally, there was no difference between the surgeons based on side of shoulder prepped [Table 2, $P=0.93$].

Table 1. Differences within gauze sponge, prep stick, and between surgeons using either method.

Gauze sponges	$P=0.72$
'Prep stick'	$P=0.72$
Between Surgeons	$P=0.93$

Discussion

Surgical site infection, although rare, remains a serious concern in shoulder surgery. Periprosthetic joint infections after shoulder arthroplasty have been reported from 0.7% to 3.9% in primary procedures and up to 15% in revision procedures (4-10 the delay between the diagnosis of infection and treatment and the type of treatment. Treatment was considered to be successful in 30 patients (71%). The economic burden on healthcare resulting from surgical site infection is significant (7). Numerous techniques have been described that aim to reduce the risk of infection in the orthopaedic literature, ranging from sterilization solutions and adjuvants, sterility of draping and surgical attire, antibiotic-coated implants, prophylactic antibiotics, laminar flow, and pre-operative blood glucose monitoring in patients undergoing arthroplasty (1-3, 11-13). Despite the abundance of literature describing these techniques, there is paucity of studies investigating the mechanism of application of sterilization solution. The goal of our study was to compare two popular methods of applying sterilization solution to the shoulder that are used at our institution: applicator stick and 4 x 4 cm gauze sponges.

The Chloraprep applicator or applicator stick theoretically enhances antiseptic technique by reducing direct patient contact, which ultimately lowers the potential risk of cross contamination. The application is quick and time efficient and does not require the use of sterile gloves. However, due to the surface anatomy of the shoulder, it can be challenging to prep the joint, especially the axilla region. Alternatively, while gauze sponges do not eliminate direct contact, they can theoretically make it easier to thoroughly apply the sterilization solution around the surgical site.

This study demonstrated that use of simple gauze sponges for application of sterilization solution produces significantly less un-prepped skin than a commercially available applicator stick. Although, we cannot comment on the reason for the higher percentage of un-prepped skin with the applicator stick, one theory is that the rigidity of the applicator limits the application in regions with contour, such as the axilla. While our results support the use of gauze sponges over an applicator stick, we were quite surprised at the high percentage of un-prepped skin after prepping using both methods.

The correlation between un-prepped areas and SSI still remains relatively unknown. A study done by Saltzman et al demonstrated the superiority of using Chloraprep in reducing the incidence of positive cultures of *Coagulase-negative Staphylococcus* and *Propionibacterium acnes* (P. Acnes) while Phadnis et al demonstrated in their series of patients that despite surgical preparation and prophylactic antibiotics, viable *P acnes* colonies persist (14, 15). Since our study did not explore the infection implication in the difference between the applicator stick and the gauze sponges, we are unable to conclude on its clinical significance, as unprepped areas do not necessarily correspond to infection. However, in our advanced healthcare environment, all precautions should be taken to reduce the potential of SSI in total shoulder

arthroplasty.

The strengths of the study include the use of a systematic approach to determine areas of un-prepped skin in the surgical sterilization of the shoulder. In order to minimize human error, we used a validated software technique to identify un-prepped areas (16). An independent evaluator not involved in the preparation reviewed the images to determine un-prepped areas, which were reported as a percentage of the total prepped area to reduce variability and allow for accurate comparison between shoulders. Finally, the surgeon alternated application techniques for each subject and there was no difference in either application method or side of extremity.

There are several limitations to this study. First, we understand that the application technique is user dependent and the results may not apply to other users; however, both surgeons involved were fellowship trained in shoulder surgery and have extensive experience in surgical preparation of the shoulder. Second, we acknowledge that GloGerm liquid is not a true sterilization solution, but rather a mineral oil with the same specific gravity as chloraprep ($P=0.88$) that can be illuminated under UV light. Finally, while we were able to determine areas of un-prepped skin, we did not determine a relationship to bacteria colonization and/or surgical site infection; thus, the clinical importance is unknown.

Based on our findings, use of gauze sponge produced a significantly lower percentage of un-prepped skin than the use of a 'prep stick', though we were not able to determine whether this translates to clinical significance. Orthopaedic surgeons and their staff should be mindful

of their application technique during the sterile preparation of the shoulder prior to surgery. Particular attention should be paid to the region around the axilla in order to reduce the areas of un-prepped skin and the potential risk of surgical site infection.

The authors report no conflicts of interest concerning the materials or methods used in this study or the findings specified in this paper.

Usman Ali M. Syed BS
Joseph A. Abboud MD
Shoulder and Elbow Division, The Rothman Institute,
Philadelphia, PA, USA

Adam J. Seidl MD
Department of Orthopedics, University of Colorado, USA

Ryan A. Hoffman BS
Medical Student, Drexel University College of Medicine,
Philadelphia, PA

Justin Bianchini BS
Department of Biomedical Engineering, Drexel University,
Philadelphia, PA, USA

Pedro K. Beredjikian MD
Division of Hand Surgery Rothman Institute, Sidney
Kimmel Medical College at Thomas Jefferson University,
Philadelphia, PA, USA

References

1. Boekel P, Blackshaw R, Van Bavel D, Riazi A, Hau R. Sterile stockinette in orthopaedic surgery: a possible pathway for infection. *ANZ J Surg.* 2012; 82(11):838-43.
2. Lee MJ, Pottinger PS, Butler-Wu S, Bumgarner RE, Russ SM, Matsen FA 3rd. Propionibacterium persists in the skin despite standard surgical preparation. *J Bone Joint Surg Am.* 2014; 96(17):1447-50.
3. Savage JW, Weatherford BM, Sugrue PA, Nolden MT, Liu JC, Song JK, et al. Efficacy of surgical preparation solutions in lumbar spine surgery. *J Bone Joint Surg Am.* 2012; 94(6):490-4.
4. Sperling JW, Kozak TK, Hanssen AD, Cofield RH. Infection after shoulder arthroplasty. *Clin Orthop.* 2001; 382(1):206-16.
5. Coste JS, Reig S, Trojani C, Berg M, Walch G, Boileau P. The management of infection in arthroplasty of the shoulder. *J Bone Joint Surg Br.* 2004; 86(1):65-9.
6. Dodson CC, Craig EV, Cordasco FA, Dines DM, Dines JS, Dicarolo E, et al. Propionibacterium acnes infection after shoulder arthroplasty: a diagnostic challenge. *J Shoulder Elbow Surg.* 2010; 19(2):303-7.
7. Padeigimas EM, Maltenfort M, Ramsey ML, Williams GR, Parvizi J, Namdari S. Periprosthetic shoulder infection in the United States: incidence and economic burden. *J Shoulder Elbow Surg.* 2015; 24(5):741-6.
8. Singh JA, Sperling JW, Schleck C, Harmsen WS, Cofield RH. Periprosthetic infections after total shoulder arthroplasty: a 33-year perspective. *J Shoulder Elbow Surg.* 2012; 21(11):1534-41.
9. Verhelst L, Stuyck J, Bellemans J, Debeer P. Resection arthroplasty of the shoulder as a salvage procedure for deep shoulder infection: does the use of a cement spacer improve outcome? *J Shoulder Elbow Surg.* 2011; 20(8):1224-33.
10. Wirth MA, Rockwood Jr CA. Complications of shoulder arthroplasty. *Clin Orthop Relat Res.* 1994; 307(1):47-69.
11. Ambrose CG, Clyburn TA, Mika J, Gogola GR, Kaplan HB, Wanger A, et al. Evaluation of antibiotic-impregnated microspheres for the prevention of implant-associated orthopaedic infections. *J Bone*

- Joint Surg Am. 2014; 96(2):128-34.
12. Glen L, Scammell B, Ashraf W, Bayston R. How sterile is patient's skin after preparation with alcoholic povidone iodine? Orthop Proc. 2012; 94(Suppl 18):34.
 13. Ricciardi BF, Bostrom MP, Lidgren L, Ranstam J, Merollini KM, W-Dahl A. Prevention of surgical site infection in total joint arthroplasty: an international tertiary care center survey. HSS J. 2014; 10(1):45-51.
 14. Phadnis J, Gordon D, Krishnan J, Bain GI. Frequent isolation of Propionibacterium acnes from the shoulder dermis despite skin preparation and prophylactic antibiotics. J Shoulder Elbow Surg. 2016; 25(2):304-10.
 15. Saltzman MD, Nuber GW, Gyzlo SM, Marecek GS, Koh JL. Efficacy of surgical preparation solutions in shoulder surgery. J Bone Joint Surg Am. 2009; 91(8):1949-53.
 16. Szpinda M, Daroszewski M, Szpinda A, Woźniak A, Wiśniewski M, Mila-Kierzenkowska C, et al. New quantitative patterns of the growing trachea in human fetuses. Med Sci Monit. 2012; 18(6):PH63-70.