

RESEARCH ARTICLE

Injury to the Infrapatellar Branch of the Saphenous Nerve during ACL Reconstruction with Hamstring Tendon Autograft: A Comparison between Oblique and Vertical Incisions

Hamid Mousavi, MD; Mohammad Mohammadi, MD; Hossein Akbari Aghdam, MD

Research performed at Kashani Educational Hospital, Isfahan, Iran

Received: 30 December 2016

Accepted: 10 August 2017

Abstract

Background: Injury to the infrapatellar branch of the saphenous nerve (IPBSN) is common after arthroscopic ACL reconstruction with hamstring tendon autograft, as reported in up to 88% of the cases. Due to close relationship between the IPBSN with pes anserine tendons insertion skin incision may sever IPBSN while harvesting gracilis and semitendinous tendons. As the IPBSN course at the anterior of knee is oblique, we hypothesized a parallel skin incision with nerve passage may decrease nerve injury.

Methods: Vertical and oblique incisions were compared in 79 patients in this clinical trial. The sensory loss area and patients' complain of numbness were measured at 2 and 8 weeks as well as 6 months after surgery.

Results: Both the sensory loss area and patients' complain of numbness decreased significantly in the oblique incision group ($P < 0.001$).

Conclusion: According to our findings, oblique incision is suggested instead of traditional vertical incision when hamstring tendons are being harvested in arthroscopic ACL reconstruction with hamstring tendon autograft.

Level of evidence: IV

Keywords: ACL reconstruction, Hamstring graft harvest, Infrapatellar branch of saphenous nerve, Nerve injury, Saphenous nerve

Introduction

With the substantial improvements in surgical techniques in the modern era of surgery, patients' expectations from surgical procedures are noticeably increased and even minor complications seem unacceptable. The exact incidence of anterior cruciate ligament (ACL) tear is unknown, however, it is the most common ligament injured in the knee. It is

estimated that among 200,000 ACL injuries per year in the united states, 50,000 to 150,000 undergo ACL reconstruction (1, 2).

Injury to the infra patellar branch of saphenous nerve (IPBSN) is a known complication of knee arthrotomy as well as arthroscopic ACL reconstruction with autograft (1, 3-10).

Corresponding Author: Hossein akbari aghdam, Department of Orthopedic, Isfahan Medical University, Isfahan, Iran
Email: akbariorthoped@gmail.com



THE ONLINE VERSION OF THIS ARTICLE
ABJS.MUMS.AC.IR

IPBSN injury during hamstring tendon harvest has been reported in up to 86% of the cases (3, 10). Anterior knee pain, paresthesia, painful neuroma, and even sympathetic dystrophy may occur (4, 10). These complications can affect patient's satisfaction from surgery (4, 6, 10, 13, 14).

Considering the anatomic variations and the close relationship between IPBSN with pes anserinus insertion, complete prevention of nerve injury seems impossible (14-16). IPSBN at the medial of the knee has an oblique course, about -45° distal-laterally; hence, the chance of damage may be decreased with the skin incision parallel to IPBSN (6-8, 10, 18). At this study we have compared IPSBN injury with vertical and oblique incisions.

Materials and Methods

During March 2013 to December 2014, 132 patient candidates for primary arthroscopic ACL reconstruction with hamstring tendon autograft were intended to be enrolled in this randomized clinical trial (Level 1) at Kashani hospital, Isfahan, Iran. The study protocol was approved by the Ethics Committee of Isfahan University of Medical Sciences (#393153). Each patient was examined for skin scar, disturbed sensation and eczema around the knee as well as history of previous knee surgery and peripheral neural disease. Any patient candidate for primary ACL reconstruction surgery at the age range of 15 -55 years was included in the study. Previous knee surgery, old scar around knee, history of nerve injury, PCL tear, and abnormal anterior knee sensation were the exclusion criteria. The intervention was declared prior to surgery for each patient and a questionnaire was completed for the cause of ACL injury, the injury to surgery interval, education, age, sex, and job.

Arthroscopic examination was performed and meniscal injury treated prior to ACL reconstruction. Patients were alternately divided into two groups. The traditional vertical incision was performed for one group while the other group underwent 45° lateral-distal oblique incisions. The oblique incision was centered over the pes anserine or centering the incision 3 fingerbreadths below the joint line, 1 cm medial to the tibial tubercle and 1 to 3 cm distal to the tubercle. Vertical incision was performed anteromedially on tibia, starting approximately 4 cm distal to the joint line and 3 cm medial to the tibial tuberosity.

At 2 and 8 weeks and 6 months after surgery, patients were examined for sensory loss around the knee by means of the pen prick test, then the sensory loss area was marked and digital pictures were snapped with a ruler beside as a scale; then the sensory loss area (cm²) and the incision length (cm) were measured by Photoshop software [Figure 1].

The awareness of sensory loss and complain of sensory loss were questioned as follows:

Awareness of skin sensory loss:

- A. No awareness
- B. Mild and occasionally sense of numbness
- C. Persistent moderate numbness
- D. Persistent severe numbness

Complain of sensory loss:

- A. No complain
- B. Mild and occasionally
- C. Moderate
- D. Severe and troublesome

Data were analyzed with SPSS v22 software and the statistical analysis was performed using independent T-test as well as Mann-Whitney and chi-square Tests. A $P < 0.05$ was considered as statistically significant.

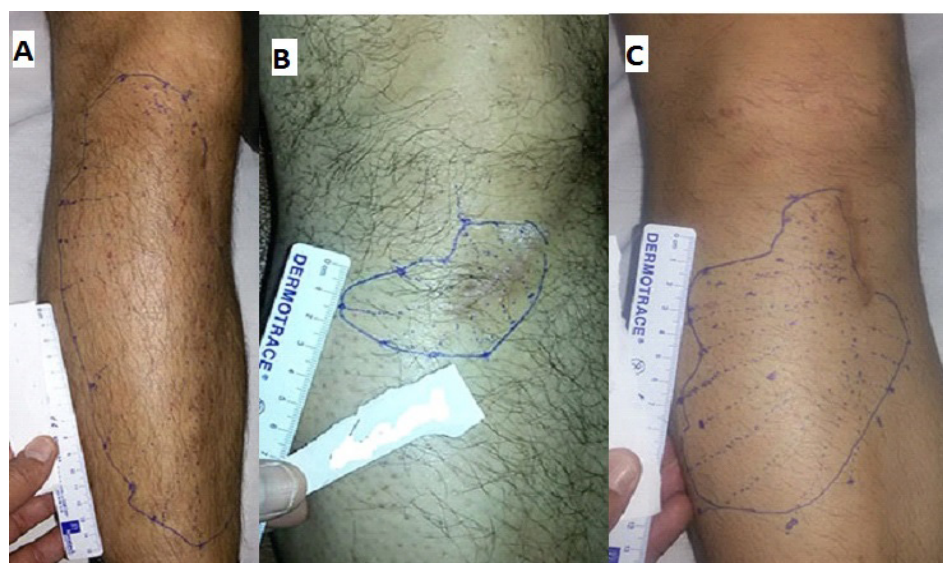


Figure 1. A) vertical incision; B) An oblique incision; C) One massive sensory disturbance (vertical incision). The sensory loss area was marked.

Results

Among 132 patients who underwent arthroscopic ACL reconstruction with four strand hamstring autograft, 28 disagreed to be enrolled in the study and 25 others were excluded from study [Figure 1].

Among a total of 79 patients who remained in study 74 were males and 5 were females (mean age=28.9 years, range: 17 to 44 years). Football accidents were the most frequent cause of ACL tear (n=33, 41.77%); other sports (n=13, 16.45%); falling (n=9, 11.4%); work (n=9, 11.4%); MVA (Motor Vehicle Accident) (n=4, 5%); and other causes (n=11, 13.9%).

The mean injury to surgery delay time was 22 months (1 to 180 months) and the mean incision length was 4.6 cm (2.37 to 6.83 cm). IPBSN injury was seen in 65 patients (83%) and only 4 cases had pain (5%) [Chart 1].

Meniscal injury was 46(58%) as:

Medial meniscus: 36 (45.6%)

Lateral meniscus: 6 (7.6%)

Both of medial and lateral: 4 (5.1%)

As mentioned in Table 1, no significant correlation found between age, sex, meniscal injury and delay to surgery with nerve injury. But sensory loss and Patient complains exactly correlate with skin incision, $P < 0.001$.

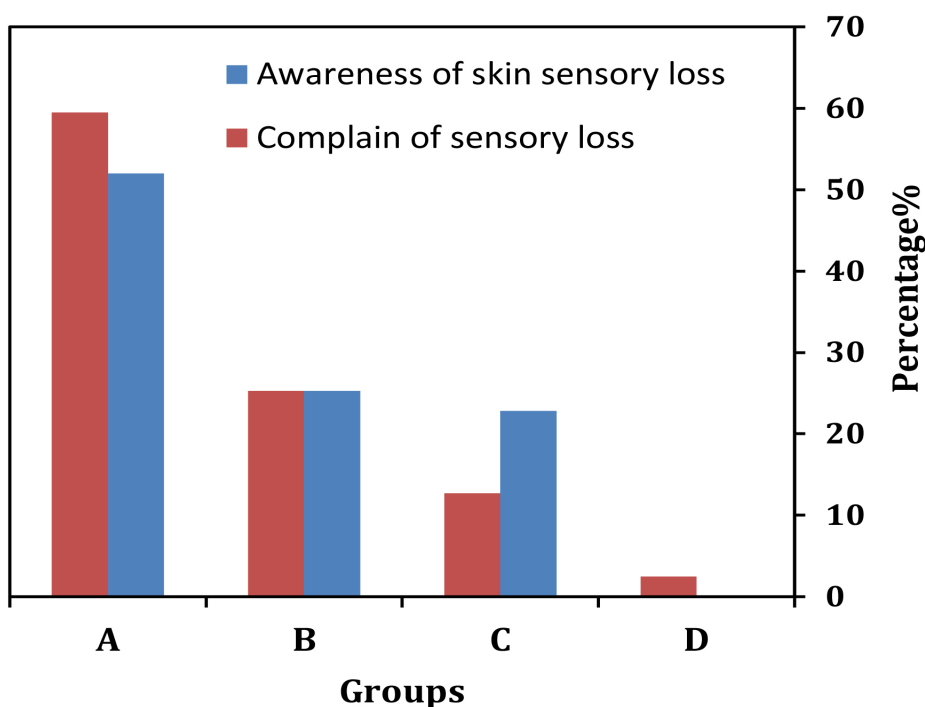


Chart 1. Comparison of severity in : awareness of skin loss and complain of sensory loss, in all pateints.

| Table 1. Comparison between vertical and oblique incision group | | | | | | | | | | | | |
|-----------------------------------------------------------------|----|------------------|----------------------|------------------|-------------------------|-------------------|------|------|-------------------|------|------|-----|
| Groups | n | Mean age (years) | Incision length (cm) | Sensory loss (%) | Area (cm ²) | Sensory awareness | | | Patient complain | | | |
| | | | | | | A | B | C | A | B | C | D |
| oblique | 31 | 28.1±6.3 | 3.8±0.8 | 61.3 | 11.5±2.2 | 80.6 | 12.9 | 6.5 | 93.3 | 0 | 6.5 | 0 |
| vertical | 48 | 29.5±6.2 | 5.1±0.9 | 95.8 | 59.9±7.8 | 33.3 | 33.3 | 33.3 | 37.5 | 41.7 | 16.7 | 4.2 |
| Statistical analysis | | t-test | t-test | chi- square | T-test | Mann-Whitney Test | | | Mann-Whitney Test | | | |
| Statistic result | | t = 0.97 | t = 5.9 | t = 15.41 | t = 4.86 | z = - 4.05 | | | z = - 4.56 | | | |
| P value | | 0.33 | <0.001 | < 0.001 | < 0.001 | < 0.001 | | | < 0.001 | | | |

Discussion

In the current study, two types of incisions (vertical & oblique) over the pes anserinus region, through which the medial hamstring tendons are harvested, were compared. This study suggests that oblique incision can significantly decrease IPBSN injury compared to the traditional vertical incision, leading to decreased patients complains.

The IPBSN exits from the adductor canal and obliquely and laterally passes downward with an almost 450 angle through the anterior knee (14-16, 18). It is intimate to pes anserine insertion at medial of the knee (1, 14-16). In addition, there are many variations of the transverse branches of IPBSN from the lower pole of patella up to the distal tibial tubercle (14). So nerve injury is inevitable when the skin is incised for tendon harvesting. Wisely, an incision parallel to the nerve passage may cause less nerve injury (1, 18). A sartorial branch injury may also occurs which has already been reported as up to 23% of cases (11, 17). In this study, injury to the sartorial branch happened in 4 patients (5%).

Spicer et al, assessed the incidence of anterior knee symptoms in a cohort of patients who had undergone hamstring reconstructions. Areas of sensory change over the front of the knee were identifiable in 50% of patients, among whom, 86% demonstrated sensory changes in the distribution of the infragenicular branch of the saphenous nerve (10). They did not compare two type of incision (vertical & oblique).

Tavakoli et al, studied 60 patients and found that oblique incision was associated with decreased

incidence of the injury but this association was not significant (11). Our cases were more than this study and we found significant difference in IPBSN injury between oblique and vertical incisions.

The effect of nerve injury on knee function was not assessed, and this was the main limitation of this study.

Our findings confirm the hypothesis that a parallel incision might decrease nerve injuries. In addition, complain of numbness was significantly related to the sensory loss area and happened less frequently in the oblique incision group ($P<0.001$). Age, sex, job, education, meniscal injury, and delay from injury to reconstruction did not show any significant correlation with nerve injury and patient complain. Our study demonstrated that further studies with more cases are necessary to be done.

According to our findings, oblique incision cause less injury to the infrapatellar branch of the saphenous nerve at arthroscopic ACL reconstruction with hamstring tendon autograft.

Hamid mousavi MD
Mohammad Mohammadi MD
Hossein Akbari Aghdam MD
Department of Orthopaedic, Isfahan Medical University,
Isfahan, Iran

References

1. Chambers GH. The prepatellar nerve. A cause of suboptimal results in knee arthrotomy. *Clin Orthop Relat Res.* 1972; 82:157-9.
2. Canale ST, Beaty JH. *Campbell's operative orthopedics.* 12th ed. Philadelphia: Elsevier Health Sciences; 2013.
3. Kartus J, Movin T, Karlsson J. Donor-site morbidity and anterior knee problems after anterior cruciate ligament reconstruction using autografts. *Arthroscopy.* 2001; 17(9):971-80.
4. Laxdal G, Kartus J, Hansson L, Heidvall M, Ejerhed L, Karlsson J. A prospective randomized comparison of bone-patellar tendon-bone and hamstrings grafts for anterior cruciate ligament reconstruction. *Arthroscopy.* 2005; 21(1):34-42.
5. Luo H, Yu JK, Ao YF, Yu CL, Peng LB, Lin CY, et al. Relationship between different skin incisions and the injury of the infrapatellar branch of the saphenous nerve during anterior cruciate ligament reconstruction. *Chin Med J (Engl).* 2007; 120(13):1127-30.
6. Mistry D, O'Meeghan C. Fate of the infrapatellar branch of the saphenous nerve post total knee arthroplasty. *ANZ J Surg.* 2005; 75(9):822-4.
7. Pagnani MJ, Warner JJ, O'Brien SJ, Warren RF. Anatomic considerations in harvesting the semitendinosus and gracilis tendons and a technique of harvest. *Am J Sports Med.* 1993; 21(4):565-71.
8. Poehling GG, Pollock Jr FE, Koman LA. Reflex sympathetic dystrophy of the knee after sensory nerve injury. *Arthroscopy.* 1988; 4(1):31-5.
9. Ganzoni N, Wieland K. The ramus infrapatellaris of the saphenous nerve and its importance for medial parapatellar arthrotomies of the knee. *Reconstr Surg Traumatol.* 1978; 16:95-100.
10. Spicer DD, Blagg SE, Unwin AJ, Allum RL. Anterior knee symptoms after four-strand hamstring tendon anterior cruciate ligament reconstruction. *Knee Surg Sports Traumatol Arthrosc.* 2000; 8(5):286-9.
11. Tavakoli Darestani R, Bagherian Lemraski MM, Hosseinpour M, Kamrani-Rad A. Electrophysiological assessment of injury to the infra-patellar branch(es) of the saphenous nerve during anterior cruciate

- ligament reconstruction using medial hamstring auto-grafts: vertical versus oblique harvest site incisions. *Arch Trauma Res.* 2013; 2(3):118-23.
12. Bertham C, Porsch M, Hackenbroch MH, Terhaag D. Saphenous neuralgia after arthroscopically assisted anterior cruciate ligament reconstruction with a semitendinosus and gracilis tendon graft. *Arthroscopy.* 2000; 16(7):763-6.
 13. Horner G, Dellon AL. Innervation of the human knee joint and implications for surgery. *Clin Orthop Relat Res.* 1994; 301:221-6.
 14. Hunter LY, Louis DS, Ricciardi JR, O'Connor GA. The Saphenous nerve: its course and importance in medial arthrotomy. *Am J Sports Med.* 1979; 7(4):227-30.
 15. Kalthur SG, Sumalatha S, Nair N, Pandey AK, Sequeria S, Shobha L. Anatomic study of infrapatellar branch of saphenous nerve in male cadavers. *Ir J Med Sci.* 2015; 184(1):201-6
 16. Kartus J, Ejerhed L, Eriksson BI, Karlsson J. The localization of the infrapatellar nerves in the anterior knee region with special emphasis on central third patellar tendon harvest: a dissection study on cadaver and amputated specimens. *Arthroscopy.* 1999; 15(6):577-86.
 17. Netter FH, Colacino S. *Atlas of the human anatomy.* New York: Novartis Medical Education; 1997.
 18. Kerver AL, Leliveld MS, den Hartog D, Verhofstad MH, Kleinrensink GJ. The surgical anatomy of the infrapatellar branch of the saphenous nerve in relation to incisions for anteromedial knee surgery. *J Bone Joint Surg Am.* 2013; 95(23):2119-25.