

## TECHNICAL NOTE

# Epineural Sleeve Reconstruction Technique for Median Nerve Complete Transection

Spyridon P. Galanakos, MD; Andreas F. Mavrogenis, MD; Christos Vottis, MD; George A. Macheras, MD; Ioannis Ignatiadis, MD

Research performed at ATTIKON University Hospital, Athens University Medical School, Athens, Greece

Received: 15 November 2016

Accepted: 29 July 2017

## Abstract

In microsurgical nerve repair, the epineural sleeve technique can be used to bridge short nerve defects and to cover the coaptation site with the epineurium of the nerve stump. The epineurium serves as a mechanical aid to reduce gap size, and increase repair strength, effectively assisting nerve regeneration.

This article presents a 32-year-old patient who experienced complete transection of the median nerve at the distal forearm, which was treated with the epineural sleeve graft reconstruction technique. Nerve regeneration was followed-up for 18 months and evaluated with the Rosén and Lundborg scoring system. The final outcome was excellent; at the last follow-up, the patient experienced complete sensory and motor function of the median nerve.

**Level of evidence:** V

**Keywords:** Epineural sleeve, Microsurgical repair, Nerve graft

## Introduction

Nerve coaptation is important for successful nerve reconstruction. Different techniques for enhancement of nerve regeneration after microsurgical nerve repair have been described previously (1-9). Significant loss of nerve tissue necessitates the use of a nerve graft, while nerve regeneration through a large peripheral nerve gap will not be successful unless a conduit is used. Autogenous nerve grafting is the most commonly used procedure for nerve repair when a significant nerve gap is present. It generally provides good results, but it is hampered by donor site morbidity and limited availability (10-13). Clinical implementation of nerve conduits has focused on the use of autogenous tissue (veins, arteries, pseudosheaths, nerve grafts) and occasionally on artificial conduits (silicone, polyglactine mesh) (10, 11,

14). According to current literature, conduit materials do not seem to significantly improve clinical outcome when compared with conventional nerve grafting (15, 16). A major difficulty in the use of conduits is the defect size that can be successfully bridged; in humans, this is approximately 25 mm. For larger defects, nerve grafting is necessary.

The epineurium may serve as an autologous biologically active conduit and may facilitate bridging of nerve defects. The use of the epineural cuff technique was first described by Snyder et al. (17, 18). This technique has been validated in animal models (19-23). We have previously presented the outcomes of using an epineural flap in a patient with a short radial nerve defect after excision of a neuroma-in-continuity, with excellent functional results after a follow-up of 17

**Corresponding Author:** Ioannis Ignatiadis, Athens Medical Center, Psychico Clinic, Athens, Greece  
Email: ignatioa@yahoo.com



THE ONLINE VERSION OF THIS ARTICLE  
ABJS.MUMS.AC.IR

months (24). The motor recovery of the wrist, finger, and thenar extensor muscles was measured as M4 (excellent), whereas sensory recovery at the area of distribution the superficial radial nerve over the second metacarpal was S3 (satisfactory). This article reports the successful outcome of a 32-year-old patient who experienced complete transection of the median nerve at the distal forearm treated with the epineural sleeve graft reconstruction technique. The patient provided written informed consent for print and electronic publication of this case report. The authors report no actual or potential conflict of interest in relation to this article.

#### Technical note

A 32-year-old male blue-collar worker presented with a median nerve transection at the distal third of his right forearm after a fall on broken glasses. Surgical exploration of the wound was done 3 hours after the injury. Exploration showed complete transection of the median nerve and radial artery, and the tendons of the flexor digitorum superficialis (FDS) and flexor digitorum profundus (FDP) to the index, middle and ring fingers, and the flexor carpi radialis [Figure 1]. The nerve was cut at 2 close areas and contused. Microsurgical debridement was done that resulted in a median nerve gap of 14 mm.

The tendons were repaired in a deep-to-superficial method with a 4-0 ethibond suture using a modified Kessler technique; tendons' repair was reinforced with a 6-0 prolene continuous epitendinous suture. Next, the radial artery was repaired using 9-0 nylon interrupted sutures. The injury to the median nerve

was then addressed. Care was taken to avoid extensive iatrogenic injury to the epineurium. After microsurgical debridement, the median nerve stumps were approximated with 10-0 nylon sutures, leaving a 10 mm nerve defect.

The epineurium was then incised longitudinally proximally and distally, creating two 1.5-cm-long epineural flaps, one for each end across the gap to bridge [Figure 2]. The epineurium was plicated serving as an additional mechanical aid to bridge the nerve gap, thus reducing nerve tension. The flaps were sutured to the epineurium of the other side and finally to each other with side-to-side stitches. The remaining gap between the nerve stumps was filled with a blood clot derived from the patient's own blood, as previously reported (19, 20).

Postoperatively, the patient's arm was immobilized in a long arm splint in 30 degrees of wrist flexion and 40-60 degrees of flexion at the metacarpophalangeal (MCP) joints, with the interphalangeal joints allowed to extend fully. Wrist position was changed on a weekly basis, with a gradual return to a neutral position. The postoperative rehabilitation protocol included active finger extension and passive finger flexion during the first 4 weeks. Then, at 4 weeks, the splint was removed and the patient was allowed protected early range of motion exercises. In addition, tendon-gliding exercises were initiated, and resumption of light activity of daily living was encouraged. The patient was informed on the necessity to protect the limb during the nerve recovery period, and returned to work 8 months after initial trauma. A sensory re-education program was performed in two phases, according to Dellon's

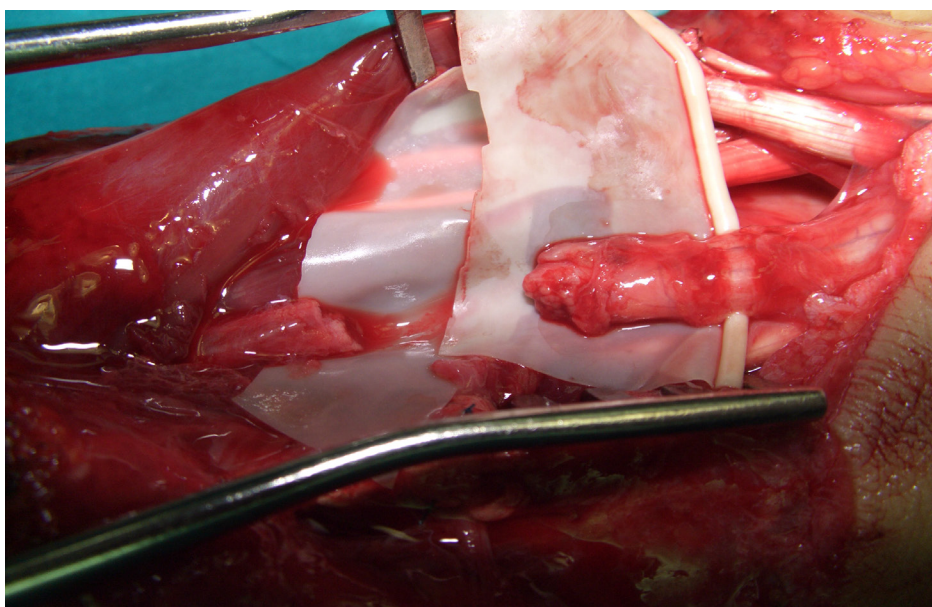


Figure 1. Intraoperative photograph shows complete transection of the median nerve.

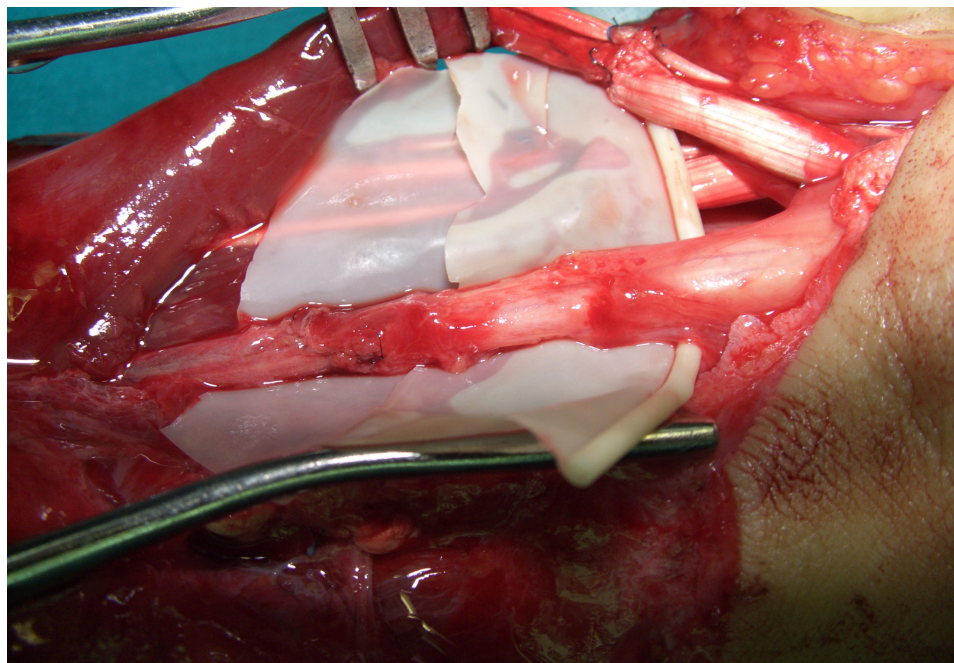


Figure 2. Intraoperative photograph of the sutured nerve stumps covered with the epineural sleeve.

Table 1. The numerical test protocol and numerical system based on the clinical results at the 18-month follow-up

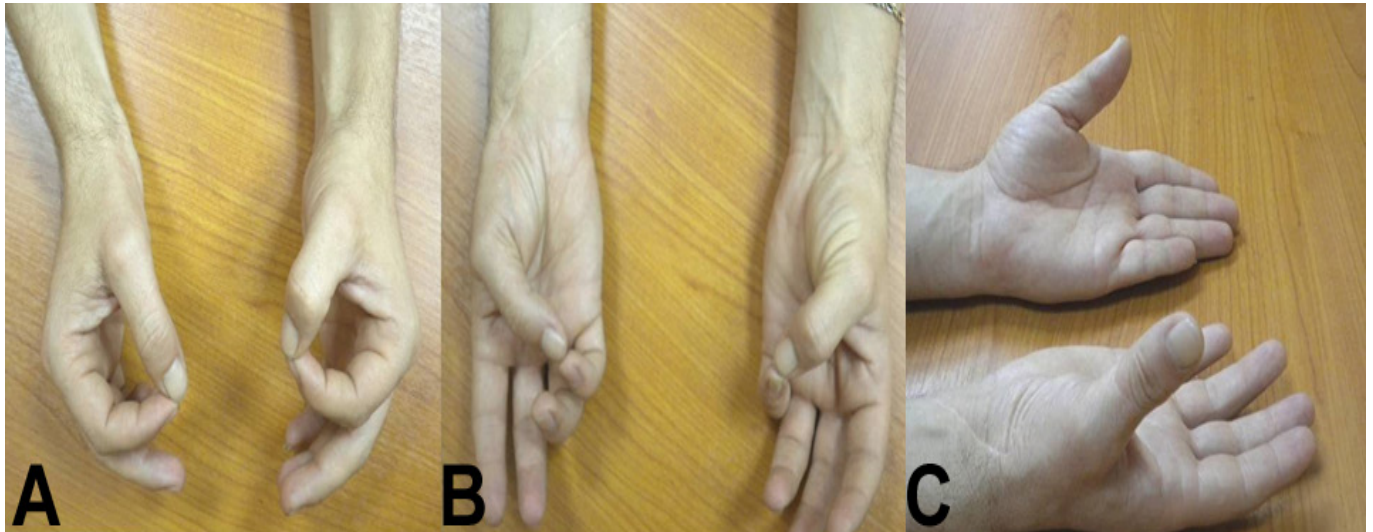
Sensory domain	Follow-up (months)							
	2	4	6	8	10	12	14	18
	<b>0.152</b>	<b>0.247</b>	<b>0.537</b>	<b>0.58</b>	<b>0.637</b>	<b>0.68</b>	<b>0.78</b>	<b>0.822</b>
Semmes-Weinstein	3 (0.2)	5 (0.33)	10 (0.66)	10 (0.66)	11 (0.73)	11 (0.73)	12 (0.8)	12 (0.8)
s2PD	0	0	1 (0.33)	1 (0.33)	1 (0.33)	1 (0.33)	2 (0.66)	2 (0.66)
STI-test	2 (0.33)	2 (0.33)	3 (0.5)	3 (0.5)	4 (0.66)	4 (0.66)	4 (0.66)	5 (0.83)
Sollerman test	1 (0.08)	4 (0.33)	8 (0.66)	10 (0.83)	10 (0.83)	12 (1)	12 (1)	12 (1)
<b>Motor domain</b>	0.472	0.489	0.542	0.58	0.724	0.791	0.8	0.819
Manual Muscle Strength Testing	4 (0.8)	4 (0.8)	4 (0.8)	4 (0.8)	5 (1)	5 (1)	5 (1)	5 (1)
Grip strength (Jamar dynamometer)	0.145	0.178	0.285	0.365	0.449	0.582	0.604	0.638
<b>Pain/discomfort domain</b>	0.495	0.495	0.495	0.66	0.66	0.66	0.66	0.66
Cold intolerance	2 (0.66)	2 (0.66)	2 (0.66)	2 (0.66)	2 (0.66)	2 (0.66)	2 (0.66)	2 (0.66)
Hyperaesthesia	1 (0.33)	1 (0.33)	1 (0.33)	2 (0.66)	2 (0.66)	2 (0.66)	2 (0.66)	2 (0.66)
<b>Total score</b>	1.11	1.23	1.574	1.82	2.02	2.131	2.24	2.3

s2PD: static 2-point discrimination, STI: shape/texture identification

recommendations (25).

Follow-up examination was done every 2 months for the first 1 year and at the last follow-up, at 18 months, for the purpose of the present study. Clinical evaluation was done using the protocol described by Rosén and Lundborg; analysis was conducted at three levels: sensory domain

(sensory innervation, tactile gnosis, and finger dexterity), motor domain (motor innervation and grip strength), and pain/ discomfort domain (hyperaesthesia and cold intolerance) [Table 1] (26). The quotient in each domain was calculated by dividing the obtained results with the normal outcome. Every domain was assigned a mean



**Figure 3.** Clinical photographs at the 18-month follow-up. The patient was able to make (A) "OK" sign, (B) normal opposition, and (C) palmar abduction of the thumb.

score and a total score. Total scores ranged from 0 to 3, with each domain contributing 1 point. This protocol has been developed for routine documentation and quantification of functional outcome following nerve repair at the wrist or distal forearm level, including sensory and motor function as well as evaluation of postoperative pain and discomfort in a summarized scoring system (26). It is simple and flexible and includes a numerical scoring system for clinical and scientific use (23). The calculated total score correlates strongly with the patients' subjective opinion about how much the nerve injury influenced their activities of daily living (26).

At the last follow-up, the patient experienced complete sensory and motor function of the median nerve [Figure 3]. No further operations, such as neurolysis or tenolysis were necessary until the period of this study; rupture of the tendons repair was not observed. Overall sensory recovery was classified as good (grade S3+) according to the modified classification of the British Medical Research Council, with a total numerical score of 2.3, based on the Rosén and Lundborg protocol (26, 27).

### Discussion

The idea of using the epineurium to bridge a nerve defect is not new (9, 19-23). Several experimental studies in animals supported the idea of using the epineurium in nerve reconstructive surgery (19-23). The general idea of the epineural sleeve in nerve repair is to use epineurium of the nerve stump to cover the coaptation site. Coaptation site becomes separated from the surrounding tissues, thus providing optimal environment for nerve regeneration. The epineural sleeve provides a favorable nerve regeneration

environment; it prevents protrusion of fascicles out from the suture line and prevents nerve from contact with scar or fibrotic tissues around coaptation site facilitating axonal regrowth (9). The interposed epineurium is not just a passive conduit. It assumes a more active role in the nerve regeneration process by providing neurotrophic factors. Additionally, the axoplasmic fluid is retained at the repair site and this facilitates the regeneration process (22). Siemionow et al. mentioned that the epineural sleeve provides a biological chamber at the coaptation site where axoplasmic fluid is collected, leaving a perfect milieu for regeneration of the nerve (22). They were able to collect as much as 1 ml of fluid from the transection site in a rabbit sciatic nerve model (3). The collected fluid, when administered subepineurally after nerve repair, enhanced the regeneration process, as confirmed by the increased number of axons and myelinated fibers (3). The authors concluded that preservation of axoplasmic fluid at the repair site may have a potentially beneficial effect on peripheral nerve regeneration and functional recovery. The studies by Lundborg et al. and Longo et al. showed that the fluid collected from the divided peripheral nerve stumps contained neurotrophic factor activity for several neural types, including sensory, motor, and sympathetic neurons (28, 29). In our practice and the present patient, we used an autologous blood clot to fill the gap between the nerve stumps based on our previous animal studies for lumen collapse prevention (19, 20). Instead of an autologous blood clot, neurotrophic factors could also be added into the epineural sleeve to enhance nerve regeneration, if necessary, based on the surgeons' preferences. Additionally, based on this experimental work, we have seen that the epineural sleeve technique may be useful

for bridging nerve gaps up to 25 mm. However, since this cannot be supported from the present case report, we can only recommend this technique to repair nerve gaps up to 14 mm.

The epineural sleeve nerve reconstruction technique has several advantages compared to other techniques: a conduit of neural origin is used; no separate surgical exposure for harvesting is necessary; there is no donor-recipient size mismatch; the biocompatibility is perfect; there is no antigenicity or inflammatory reaction; and the cost of harvesting is negligible. The disadvantages of this technique include: technical difficulties in surgical manipulation of the epineurium, time-consuming harvesting procedure, and limited amount of graft material. A concern is that stripping of the epineurium might influence nerve electrophysiologic properties. However, Karacaoglu et al. noted that denuding of the sciatic nerve from the epineurium in the rat did not induce significant any significant nerve function (21). In a study by Tetik et al., three methods of nerve repair involving the epineural sleeve technique were compared with conventional nerve repair using the rat sciatic nerve transection model in four groups (23). In group 1, the sciatic nerve was repaired using the conventional epineural technique by placing four sutures. In groups 2, 3, and 4, the epineural sleeve technique was combined with two sutures, fibrin glue, and two sutures with fibrin glue, respectively. Functional recovery was evaluated using walking track analysis, limb circumference, and toe contracture severity. The results showed better functional recovery and a higher number of myelinated fibers in groups using the epineural sleeve technique compared with conventional techniques. The addition of fibrin glue, however, did not make any difference. The epineural sleeve technique was found to be superior when compared with conventional nerve repair, providing faster functional recovery and improved nerve regeneration. Yavuzer et al. investigated the effects of the turnover epineural sheath tube (TEST) when used over the primary nerve repair site to improve nerve regeneration in twenty-five Wistar rats (30).

Three months postoperatively, functional analysis and nerve and muscle histomorphometric studies revealed similar results in the primary repair and TEST groups, with on statistically significant difference. However, during microscopic examination, a decrease in both foreign material reaction and an inflammatory response with less fibrosis were observed in the TEST group. The authors noted that the TEST had nerve-healing properties similar to primary epineural repair, with the advantage of a reduced number of sutures, thus decreasing fibrosis around the repair site. The authors concluded that the TEST is a good alternative treatment modality, especially for polyfascicular peripheral nerves.

In conclusion, the use of the epineural sleeve technique may be useful for bridging short nerve defects, up to 14 mm with excellent results, as the report has shown. The epineurium serves as a mechanical aid to reduce gap size, and increase repair strength, effectively assisting nerve regeneration.

No benefits have been or will be received from a commercial party related directed or indirectly to the subject matter of this article.

Spyridon P. Galanakos MD  
George A. Macheras MD  
Department of Orthopaedics, KAT Hospital, Athens, Greece

Ioannis Ignatiadis MD  
Athens Medical Center, Psychico Clinic, Athens, Greece

Andreas F. Mavrogenis MD  
Christos Vottis MD  
Department of Orthopaedics, National and Kapodistrian University of Athens, School of Medicine, ATTIKON University General Hospital, Athens, Greece

## References

1. Chiu DT, Janecka I, Krizek TJ, Wolff M, Lovelace RE. Autogenous vein graft as a conduit for nerve regeneration. *Surgery*. 1982; 91(2):226-33.
2. Chiu DT. Autogenous and synthetic conduits for nerve repair. In: Omer GE, Spinner M, Van Beek A, editors. *Management of peripheral nerve problems*. Philadelphia: WB Saunders Company; 1998. P. 305-10.
3. Demirkan F, Snyder CC, Latifoglu O, Siemionow M. A method of enhancing regeneration of conventionally repaired peripheral nerves. *Ann Plastic Surg*. 1995; 34(1):67-72.
4. Kiyotani T, Teramachi M, Takimoto Y, Nakamura T, Shimizu Y, Endo K. Nerve regeneration across a 25-mm gap bridged by a polyglycolic acid-collagen tube: a histological and electrophysiological evaluation of regenerated nerves. *Brain Res*. 1996; 740(1-2):66-74.
5. Lundborg G, Rosen B, Abrahamson SO, Dahlin L, Danielsen N. Tubular repair of the median nerve in the human forearm. Preliminary findings. *J Hand Surg Br*. 1994; 19(3):273-6.
6. Restrepo Y, Merle M, Michon J, Folliguet B, Petry D. Fascicular nerve graft using an empty perineurial tube:

- an experimental study in the rabbit. *Microsurgery*. 1983; 4(2):105-12.
7. Restrepo Y, Merle M, Michon J, Folliguet B, Barrat E. Free vascularized nerve grafts: an experimental study in the rabbit. *Microsurgery*. 1985; 6(2):78-84.
  8. Wang KK, Cetrulo CL Jr, Seckel BR. Tubulation repair of peripheral nerves in the rat using an inside-out intestine sleeve. *J Reconstr Microsurgery*. 1999; 15(7):547-54.
  9. Lubiatowski P, Unsal FM, Nair D, Ozer K, Siemionow M. The epineural sleeve technique for nerve graft reconstruction enhances nerve recovery. *Microsurgery*. 2008; 28(3):160-7.
  10. Malizos KN, Dailiana ZH, Anastasiou EA, Sarmas I, Soucacos PN. Neuromas and gaps of sensory nerves of the hand: management using vein conduits. *Am J Orthop (Belle Mead NJ)*. 1997; 26(7):481-5.
  11. Millesi H. The nerve gap. Theory and clinical practice. *Hand Clin*. 1986; 2(4):651-63.
  12. Varitimidis SE, Sotereanos DG. Partial nerve injuries in the upper extremity. *Hand Clin*. 2000; 16(1):141-9.
  13. Suematsu N. Tubulation for peripheral nerve gap: its history and possibility. *Microsurgery*. 1989; 10(1):71-4.
  14. Urabe T, Zhao Q, Danielsen N, Lundborg G. Regeneration across a partial defect in rat sciatic nerve encased in a silicone chamber. *Scand J Plast Reconstr Surg Hand Surg*. 1996; 30(1):7-15.
  15. Strauch B. Use of nerve conduits in peripheral nerve repair. *Hand Clin*. 2000; 16(1):123-30.
  16. Moore AM, Kasukurthi R, Magill CK, Farhadi HF, Borschel GH, Mackinnon SE. Limitations of conduits in peripheral nerve repairs. *Hand*. 2009; 4(2):180-6.
  17. Snyder CC. Epineurial repair. *Orthop Clin North Am*. 1981; 12(2):267-76.
  18. Snyder CC, Browne EZ, Herzog BG, Johnson EA, Coleman DA. Epineural cuff neurorrhaphy. *J Bone Joint Surg Am*. 1974; 2192(56A):1092.
  19. Ignatiadis IA, Tsiampa VA, Yiannakopoulos CK, Xeinis SF, Papalois AE, Xenakis TH, et al. A new technique of autogenous conduits for bridging short nerve defects. An experimental study in the rabbit. *Acta Neurochir Suppl*. 2007; 100S:73-6.
  20. Ignatiadis IA, Yiannakopoulos CK, Barbitsioti AD, Avram AM, Patralexis HG, Tsolakis CK, et al. Diverse types of epineural conduits for bridging short nerve defects. An experimental study in the rabbit. *Microsurgery*. 2007; 27(2):98-104.
  21. Karacaoglu E, Yuksel F, Peker F, Guler MM. Nerve regeneration through an epineurial sheath: its functional aspect compared with nerve and vein grafts. *Microsurgery*. 2001; 21(5):196-201.
  22. Siemionow M, Tetik C, Ozer K, Ayhan S, Siemionow K, Browne E. Epineural sleeve neurorrhaphy: surgical technique and functional results--a preliminary report. *Ann Plastic Surg*. 2002; 48(3):281-5.
  23. Tetik C, Ozer K, Ayhan S, Siemionow K, Browne E, Siemionow M. Conventional versus epineural sleeve neurorrhaphy technique: functional and histomorphometric analysis. *Ann Plastic Surg*. 2002; 49(4):397-403.
  24. Ignatiadis IA, Yiannakopoulos CK, Avram AM, Gerostathopoulos NE. Posttraumatic neuroma of the radial nerve treated with an autogenous epineural conduit technique. A case report. *Microsurgery*. 2009; 29(2):133-5.
  25. Dellon AL, Curtis RM, Edgerton MT. Reeducation of sensation in the hand after nerve injury and repair. *Plast Reconstr Surg*. 1974; 53(3):297-305.
  26. Rosen B, Lundborg G. A model instrument for the documentation of outcome after nerve repair. *J Hand Surg Am*. 2000; 25(3):535-43.
  27. Novak CB, Kelly L, Mackinnon SE. Sensory recovery after median nerve grafting. *J Hand Surg Am*. 1992; 17(1):59-68.
  28. Lundborg G, Longo FM, Varon S. Nerve regeneration model and trophic factors in vivo. *Brain Res*. 1982; 232(1):157-61.
  29. Longo FM, Manthorpe M, Skaper SD, Lundborg G, Varon S. Neuronotrophic activities accumulate in vivo within silicone nerve regeneration chambers. *Brain Res*. 1983; 261(1):109-16.
  30. Yavuzer R, Ayhan S, Latifoglu O, Atabay K. Turnover epineural sheath tube in primary repair of peripheral nerves. *Ann Plastic Surg*. 2002; 48(4):392-400.