

**CURRENT CONCEPTS REVIEW**

# Hip Surgery in Quiescent or Active Tubercular Hip Arthritis; Is Reactivation Risk Really a Matter

Ali Parsa, MD; Maryam Mirzaie, MD; Mohammad H. Ebrahimzadeh, MD; Ali Birjandinejad, MD; Abdolreza Malek, MD; Alireza Mousavian, MD

*Research performed at Massachusetts General Hospital at Harvard Medical School, Boston, USA*

*Received: 21 December 2017*

*Accepted: 19 February 2018*

**Abstract**

About 15 % of all musculoskeletal tuberculosis (TB) have hip involvement. Early anti-tubercular drug therapy and other conservative treatment including short-term traction and mobilization programs could prevent hip joint destruction. Reactivation of TB accounts for a significant of active TB incidence, especially in the developed countries with a low TB prevalence. The risk of TB activation for population with the latent form of disease is about 5-10%. According to the existing literature surgery in tubercular hip arthritis would be safe once sufficient debridement and precise anti tubercular chemotherapy has been done.

**Level of evidence:** III

**Keywords:** Active, Hip, Quiescent, Reactivation, Surgery, Tuberculosis

**Introduction**

Tuberculosis of the bone and joint is a hematogenous infection which is difficult to diagnose and treat. Hip involvement is being next to spine TB in the list of osteoarticular tubercular infection. According to latest report of World Health Organization (WHO), 10.4 million new cases of tuberculosis occurred in 2015 and musculoskeletal TB accounted for 10-15 % of all cases. Thus, more than one million new cases of orthopedic related TB happen annually (1-5).

10%-25% of cases with extra-pulmonary TB have musculoskeletal TB. Therefore, it is expected that prevalence of musculoskeletal TB is within the range of 19-38 million worldwide (6). Despite many efforts in developed countries to control TB, it remains a major cause of disability and death. The absolute incidence rate of TB in the United States has decreased over the last fifteen years; however, the rate of extra-pulmonary TB has increased (7).

It has been reported that the most affected site is spine, which affects in around 50% and up to 70% in such studies followed by the knee and hip involvement (8-10).

**Hip involvement**

About 15% of all musculoskeletal TB have hip involvement. Mycobacterium most often deposits in synovial tissue via a hematogenous route. In few cases, local foci of proximal femur osteomyelitis might be considered as the origin site. Early anti-tubercular drug therapy and other conservative treatment include short-term traction and mobilization programs could prevent hip joint destruction. However, it has been recognized that in developing countries and less privileged regions, a major number of patients are diagnosed based on clinical presentations and plain X-ray changes which are positive at advanced stages. X-ray changes consist of soft-tissue swelling, osteopenia

**Corresponding Author:** Ali Parsa, Massachusetts General Hospital, Harvard Medical School, Boston, MA, USA; Orthopedic Research Center, Mashhad University of Medical Sciences, Mashhad, Iran  
Email: Aparsa@mgh.harvard.edu; aliparsadr@yahoo.com



THE ONLINE VERSION OF THIS ARTICLE  
ABJS.MUMS.AC.IR

with mild periosteal reaction, joint space obliteration, juxta-articular bone cyst and erosions, epiphyseal enlargement in skeletally immature. In recent years with the aid of ultrasonographic-guided hip aspiration and MRI, detection of hip tuberculosis in earlier stages has been realized (11).

There is no exact age range for hip tuberculosis; however, many reports indicate that the occurrence is more frequent in the first three decades of life. Consequently, a major percentage of such patients are young and active and have several decades of life ahead. Furthermore, hip joint serves as the most important joint in weight bearing. Thus, infective destruction of the hip in an active young adult can interfere with a most portion of daily activity (8, 11).

## Diagnosis

### Clinical presentation

After deposition of Mycobacterium in synovial tissue, mild non-specific arthritis is developed. In this stage the result is not more than synovial hypertrophy and mild effusion. Common presentation of infected hip with TB is pain and decreased range of motion and limp. Few patients may describe this pain as "Night Cries" which reflect severe pain in a severely arthritic hip joint due

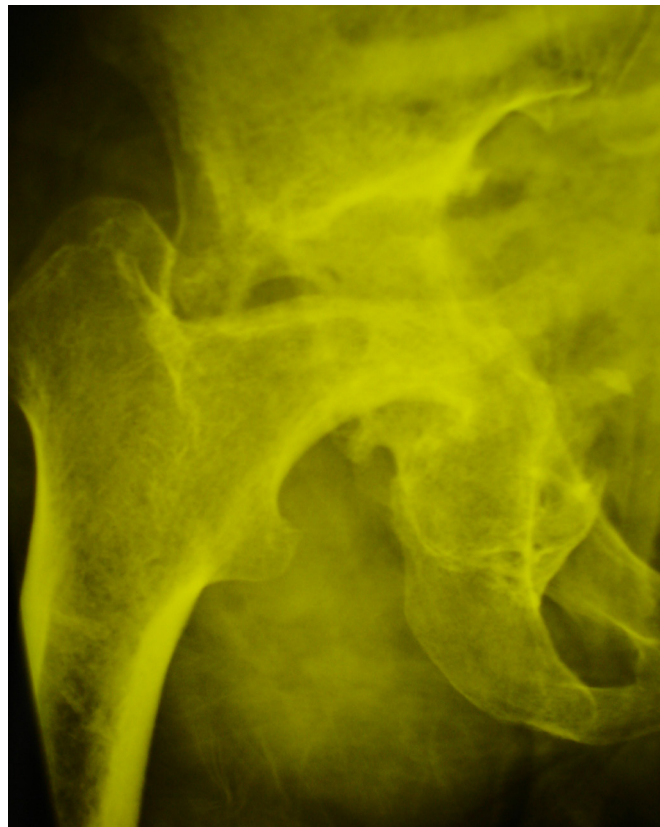
to unguarded movement during relaxed muscles at night time (12). In severe forms or untreated patients, abscess formation, sinus tract, pathologic dislocation and limb length discrepancy might be observed (13).

The differential diagnosis includes but not limited to acute septic arthritis, rheumatoid arthritis, osteomyelitis, Legg-calve-Perthes disease, transient toxic synovitis, osteonecrosis of femoral head and neoplastic lesions (11, 14).

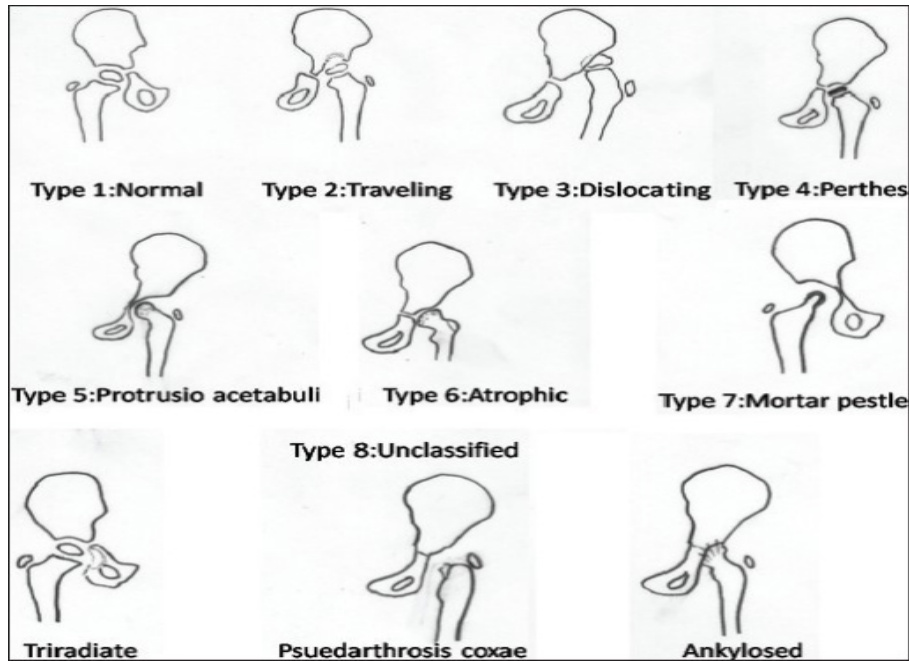
### Imaging

Radiographic findings might be the only indication of diagnosis in hip tuberculosis for up to 60% in some reports; however, CT scan and MRI are also gaining popularity to be employed for diagnosis [Figure 1] (15).

Pemister triad that includes periarticular osteoporosis, femoral head and neck erosions and decreased joint space is also suggestive for TB. Kissing sequestra (femoral side and acetabular side wedge-shaped necrosis) is another radiographic finding. Joint destruction is observed at late stages of a severe disease (16). Bony ankylosis in hip TB is uncommon without history of surgical intervention. Shanmugasundaram in 1983 released a classification for tubercular hip arthritis [Figures 2a; 2b]. Ultrasound is very important to detect



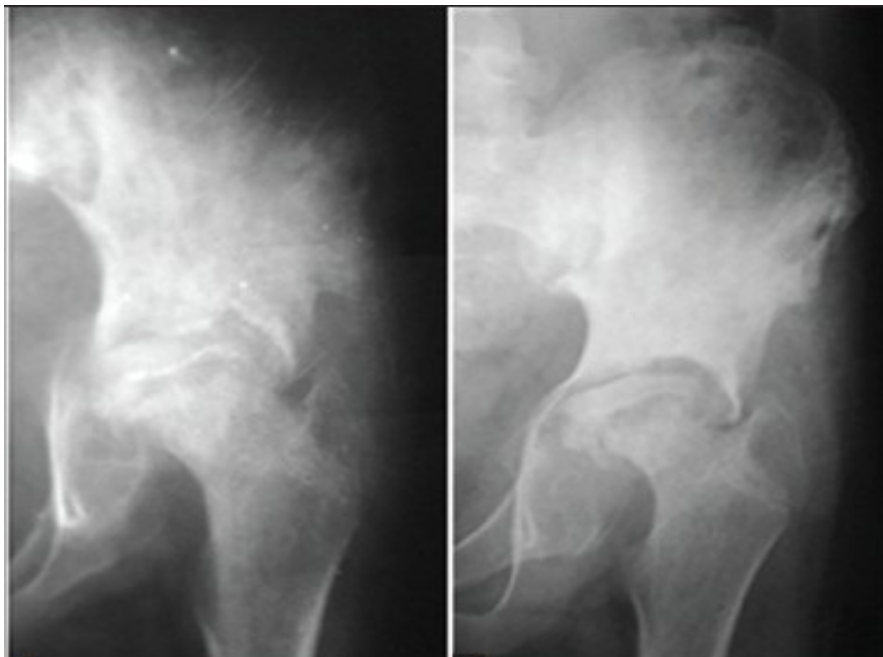**Figure 1.** A 44-year male with pseudoarthrosis type tubercular arthritis of right hip.



(a)

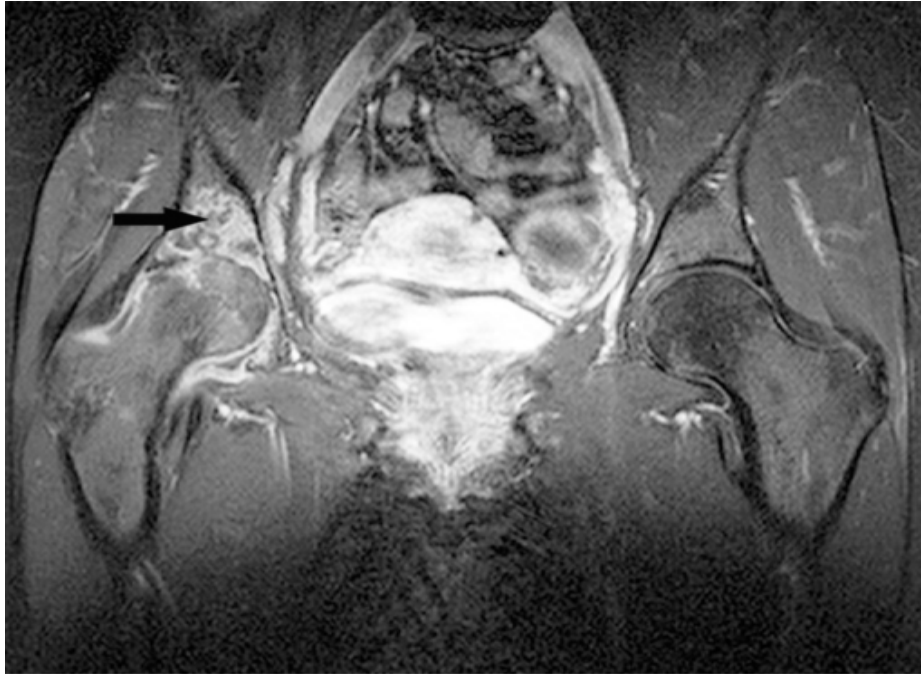
**Figure-2a.** Classification of Tubercular hip arthritis.

Reprint from: Agarwal A, Suri T, Verma I, Kumar SK, Gupta N, Shaharyar A. Tuberculosis of the hip in children: a retrospective analysis of 27 patients. Indian journal of orthopaedics. 2014 Sep;48(5):463.



(b)

**Figure-2b.** Left hip joint anteroposterior view showing protrusio acetabuli and perthoid type changes. Reprint from: Agarwal A, Suri T, Verma I, Kumar SK, Gupta N, Shaharyar A. Tuberculosis of the hip in children: a retrospective analysis of 27 patients. Indian journal of orthopaedics. 2014 Sep;48(5):463.



**Figure 3.** T1w image of right hip with chondral lesion in weight bearing area.

joint effusion in septic arthritis in childhood and might be found helpful to obtain aspiration fluid for PCR (17). CT scan can detect sequester in tuberculosis osteomyelitis around the hip, but the best modality for earlier stages is MRI [Figure 3]. Osteomyelitis and bone marrow signal changes can be visualized on MRI. Synovial hypertrophy in TB has a characteristic hyposignal feature in T2-Weighted image and it is completely different from other arthropathies with synovial hypertrophy. Soft tissue involvement determines on MRI as cellulitis, abscess formation, linear high signal intensity when sinus tract is existed around the hip and “tram-track” enhancement in contrast MRI (16).

#### **Aspiration and biopsy**

Confirmatory simple synovial fluid aspiration culture was positive in about one-third of patients while tissue samples would be positive in 90% (15). It is important that specimen was taken from the pathologic sites of joint adjacent to the erosions or synovial tissue.

#### **Treatment of primary disease**

There is no question that chemotherapy can treat the hip disease at any stage and any age. Functional outcome and additional treatment significantly depends on the extent of the disease. If the disease is diagnosed earlier, in tubercular synovitis stage and preserved joint space; the functional outcome with non-surgical treatment (protected weight bearing-early mobilization-splinting) (Rewrite the sentence). In a large series of musculoskeletal TB, more than 70% of patients were

treated with standard chemotherapy regimen alone for six months and less than 30% received long-term chemotherapy and surgical intervention (15). Skeletal traction should be applied to all patients in addition to medical treatment. If any abduction contracture is detected, contralateral traction on the healthy limb is recommended to balance the pelvis. Partial weight bearing should be started when pain is tolerated (11).

#### **Reactivation or recurrence**

Reactivation of TB accounts for a significant numbers of active TB incidence, especially in developed countries with low TB prevalence. The risk of active TB in future for population with latent form of disease is about 5-10% (16). Reactivation risk is continued after several years of apparent healing. Latent TB consists a broad spectrum of infection and the degree of infection depends on host immunity status, pathogenicity of Mycobacterium. Risk factors for TB reactivation are shown in Table 1 that indicates prophylaxis (18). About 13% of TB patients worldwide have co-infection with HIV/AIDS. Thus, despite the fact that HIV infection is a major risk factor for reactivation, HIV infection is seen in a significant portion of reactivated musculoskeletal TB.

Reactivation rate of diabetes mellitus (DM) is high. As for specific ethnicities, the rate is higher and more than 1:4 of DM Hispanic patients acquire Tuberculosis (19).

It has been shown that DM predisposes patients to infections, especially organisms that overcome the cell-mediated immunity, has a dominant role like TB. Phagocytosis, chemotaxis and almost all actions of

Table 1. Risk factors of TB reactivation	
Risk factor	Relative risk of reactivation
HIV/AIDS	10-100
Close contact	15
Recipient of organ transplant	20-70
Chronic renal failure(hemodialysis)	6.9-52.5
TNF- $\alpha$ blockers	1.6-25.1
Silicosis	2.8
Fibro-nodular disease on chest x-ray	6-19
Immigrants from endemic countries	2.9-5.3
Work related exposure (Health-care professionals, Prisoners, homeless persons, Substance abuse)	2.55
Diabetes	1.6-7.83
Smokers	2-3
Steroid therapy	2.8-7.7
Low BMI	2-3

monocyte immunity are affected in DM patients and are not improved by Insulin therapy (20, 21).

Treatment of latent TB is very effective to prevent reactivation, but there is significant debate about the target group who need treatment (22, 23).

Two recent meta-analyses showed that most interferon- $\gamma$  release assays (IGRA) positive patients did not progress to tuberculosis. There is no test with a stronger association between its positive results and active tuberculosis (24, 25).

### Discussion

Theoretically, biofilm formation and adherence of mycobacterium bacilli to orthopedic implants is very low, but still reactivation is a source of concern in any orthopedic intervention of these patients (26, 27).

### Hip replacement in quiescent TB

Total hip arthroplasty is a very successful surgery for all kind of hip arthritis. The problem with tubercular arthritis is fear about recurrence and concern about high rate of complications (28). Although the mid-term results of hip replacement were inspiring, however in most of these studies just patients who had completed their full course of antitubercular therapy were enrolled (29). Furthermore, contrast MRI was done to rule out any evidence of residual infection. The nearly same protocol for all these studies was administration of antitubercular drugs starting one week before surgery and continued for 2 months postoperatively and Isoniazid and Rifampicin continued for the next 4 months.

The tissue and fluid samples obtained at the time of surgery were sent for Gram staining, acid-fast bacilli staining, polymerase chain reaction (PCR), culture and

sensitivity for mycobacterium and histopathological examination (28-30).

Existing literature about the outcome of these patients is impressive [Table 2]. Although there is no high level of evidence in literature and most of the above- mentioned studies listed in Table 2 are case series or retrospective studies (Level III, Level IV of evidence), but it seems that hip replacement several years after primary infection in a patient with quiescent tuberculosis has impressive results. Among 154 cases of those 7 studies (published between 1979-2015) only in 11 patients experienced tuberculosis recurrence after arthroplasty. All of them were treated with both antitubercular treatment and surgical debridement. Tuberculosis was treated in 6 cases with good function of prosthesis and only in 5 patients (3%) the process resulted in prosthetic failure (26, 31, 32).

### Two-stage Hip replacement in active TB

Recently Li et al. reported a three-year follow-up of nine advanced tubercular hip arthritis. Their protocol included the administration of antitubercular drugs for at least 2 weeks prior to the first surgery. At the first surgery, extensive debridement was considered and antibiotic-loaded cement spacer was used (Combination of streptomycin and vancomycin). TB chemotherapy was continued for at least next four months. If CRP and ESR were normal, hip replacement was performed and drug treatment was completed (12 months) Significant pain relief achieved without any recurrence (33).

### One-stage hip replacement in active TB

One-stage hip replacement in TB is challenging.

**Table 2. Outcome of hip replacement for Tubercular hip arthritis**

Author (Year)	No of patients	TB status	Type of prosthesis	Tubercular prosthetic joint infection	Early loosening	Follow-up (Y)	Final Outcome	Failure
Hardinge (36)	21	Quiescent	Cemented	0	0	2.6	Good	0
Johnson (31)	2	Quiescent	Cemented	2	2	3	Poor	2
Jupiter (37)	7	Quiescent	Cemented	0	0	3.5	Good	0
Kim (32)	44	Quiescent ,Anti TB started 4 months before	Cemented	6	1	3.8	Good	1
Santavirta (28)	14	Quiescent ,Anti TB started 1 months before	Cemented	1	2	8	Good	2
Yoon (27)	7	Active TB	Cementless	0	0	4.8	Excellent	0
Negoi (26)	12	Active TB	Cementless	1	0	2.1	Excellent	1
O' ztu'rkmen (30)	9	Active TB	Cementless	0	0	5.6	Excellent	0
Kumar (18)	65	Quiescent	Cementless	2	0	8.2	Good	0
Tan (29)	1	Quiescent	Cementless	0	0	0.3	Good	0
Li (33)	9	Active TB	Cementless	0	0	3.3	Excellent	0

Always sinus tracts and extent of the disease to pelvis or deep thigh region is possible.

But, fortunately biofilm formation on implant surface is not a source of concern in mycobacterial infection in comparison to bacterial infections (26, 33, 34).

We found three reports of one stage-hip replacement in active TB, which all of them had been published after 2005. Only one failure reported for total cases of 27 (4%).

This patient did not receive a complete antitubercular treatment despite surgical debridement and was converted to receive resection arthroplasty.

### Hip arthroscopy

To the best of our knowledge, there is only one report of hip arthroscopy in tubercular arthritis in English literature. In this recent retrospective study, Tiwari et al. reported the improvement of outcome in 22 hips after arthroscopic debridement and synovectomy (35). For all patients, antitubercular treatment was started at least two months in advance. They had no case of hip dislocation; cold abscess or recur at a minimum follow-up of 4 years.

Surgery in tubercular hip arthritis would be safe with sufficient debridement and precise antitubercular

chemotherapy.

Ali Parsa MD  
Massachusetts General Hospital, Harvard Medical School, Boston, MA, USA; Orthopedic Research Center, Mashhad University of Medical Sciences, Mashhad, Iran

Maryam Mirzaie MD  
Community and Preventive Medicine Specialist, Mashhad University of Medical Sciences, Mashhad, Iran

Mohammad H. Ebrahimzadeh MD  
Ali Birjandinejad MD  
Alireza Mousavian MD  
Orthopedic Research Center, Mashhad University of Medical Sciences, Mashhad, Iran

Abdolreza Malek MD  
Department of Pediatrics, Mashhad University of Medical Sciences, Mashhad, Iran

### References

1. Babhulkar S, Pande S. Tuberculosis of the hip. Clin

Orthop Relat Res. 2002; 398(1):93-9.

2. Birjandinejad A, Parsa A, Ebrahimzadeh MH. Isolated tuberculosis of the talonavicular joint in a child. *Foot*. 2012; 22(3):255-7.
3. Jeddo S, Huang CW, Li M. Case report on the recurrence of tuberculosis of hip after 40 years. *Springerplus*. 2014; 3(1):662.
4. Held MF, Hoppe S, Laubscher M, Mears S, Dix-Peek S, Zar HJ, et al. Epidemiology of musculoskeletal tuberculosis in an area with high disease prevalence. *Asian Spine J*. 2017; 11(3):405-11.
5. World Health Organization. World malaria report 2015. Geneva: World Health Organization; 2016.
6. Johansen IS, Nielsen SL, Hove M, Kehrer M, Shakar S, Wøyen AV, et al. Characteristics and clinical outcome of bone and joint tuberculosis from 1994 to 2011: a retrospective register-based study in Denmark. *Clin Infect Dis*. 2015; 61(4):554-62.
7. Peto HM, Pratt RH, Harrington TA, LoBue PA, Armstrong LR. Epidemiology of extrapulmonary tuberculosis in the United States, 1993-2006. *Clin Infect Dis*. 2009; 49(9):1250-7.
8. Malaviya AN, Kotwal PP. Arthritis associated with tuberculosis. *Best Pract Res Clin Rheumatol*. 2003; 17(2):319-43.
9. Gharehdaghi M, Hassani M, Ghodsi E, Khooei A, Moayedpour A. Bacille Calmette-Guérin Osteomyelitis. *Arch Bone Jt Surg*. 2015; 3(4):291-5.
10. Elmi A, Tabrizi A, Tolouei FM. Skeletal tuberculosis presenting as a small cystic lesion in the medial femoral condyle. *Arch Bone Jt Surg*. 2013; 1(2):112-5.
11. Yadav S, Rawal G. Primary extrapulmonary extensively drug resistant tuberculosis of the hip in an immunocompetent female-a case report. *J Clin Diagn Res*. 2017; 11(1):LD01-3.
12. Agarwal SP, Chauhan LS. Tuberculosis control in India. New Delhi: Directorate General of Health Services, Ministry of Health and Family Welfare; 2005.
13. Lešić AR, Pešut DP, Marković-Denić L, Maksimović J, Čobeljić G, Milosevic I, et al. The challenge of osteo-articular tuberculosis in the twenty-first century: a 15-year population-based study. *Int J Tuberc Lung Dis*. 2010; 14(9):1181-6.
14. Mazloumi SM, Ebrahimzadeh MH, Kachooei AR. Evolution in diagnosis and treatment of Legg-Calve-Perthes disease. *Arch Bone Jt Surg*. 2014; 2(2):86-92.
15. De Backer AI, Vanhoenacker FM, Sanghvi DA. Imaging features of extraaxial musculoskeletal tuberculosis. *Indian J Radiol Imaging*. 2009; 19(3):176-86.
16. Robben SG. Ultrasonography of musculoskeletal infections in children. *Eur Radiol*. 2004; 14(4):L65-77.
17. Ai JW, Ruan QL, Liu QH, Zhang WH. Updates on the risk factors for latent tuberculosis reactivation and their managements. *Emerg Microbes Infect*. 2016; 5(2):e10.
18. Kumar V, Garg B, Malhotra R. Total hip replacement for arthritis following tuberculosis of hip. *World J Orthop*. 2015; 6(8):636-40.
19. Restrepo BI, Fisher-Hoch SP, Pino PA, Salinas A, Rahbar MH, Mora F, et al. Tuberculosis in poorly controlled type 2 diabetes: altered cytokine expression in peripheral white blood cells. *Clin Infect Dis*. 2008; 47(5):634-41.
20. Dooley KE, Chaisson RE. Tuberculosis and diabetes mellitus: convergence of two epidemics. *Lancet Infect Dis*. 2009; 9(12):737-46.
21. Smieja MJ, Marchetti CA, Cook DJ, Smaill FM. Isoniazid for preventing tuberculosis in non-HIV infected persons. *Cochrane Database Syst Rev*. 2000; 1(2):CD001363.
22. Stagg HR, Zenner D, Harris RJ, Muñoz L, Lipman MC, Abubakar I. Treatment of latent tuberculosis infection: a network meta-analysis. *Ann Internal Med*. 2014; 161(6):419-28.
23. Rangaka MX, Wilkinson KA, Glynn JR, Ling D, Menzies D, Mwansa-Kambafwile J, et al. Predictive value of interferon-γ release assays for incident active tuberculosis: a systematic review and meta-analysis. *Lancet Infect Dis*. 2012; 12(1):45-55.
24. Diel R, Goletti D, Ferrara G, Bothamley G, Cirillo D, Kampmann B, et al. Interferon-γ release assays for the diagnosis of latent Mycobacterium tuberculosis infection: a systematic review and meta-analysis. *Eur Respir J*. 2011; 37(1):88-99.
25. Ha KY, Chung YG, Ryoo SJ. Adherence and biofilm formation of Staphylococcus epidermidis and Mycobacterium tuberculosis on various spinal implants. *Spine (Phila Pa 1976)*. 2005; 30(1):38-43.
26. Neogi DS, Yadav CS, Ashok Kumar SA, Rastogi S. Total hip arthroplasty in patients with active tuberculosis of the hip with advanced arthritis. *Clin Orthop Relat Res*. 2010; 468(2):605-12.
27. Yoon TR, Rowe SM, Santosa SB, Jung ST, Seon JK. Immediate cementless total hip arthroplasty for the treatment of active tuberculosis. *J Arthroplasty*. 2005; 20(7):923-6.
28. Santavirta S, Eskola A, Konttinen YT, Tallroth K, Lindholm ST. Total hip replacement in old tuberculosis: a report of 14 cases. *Acta Orthop Scand*. 1988; 59(4):391-5.
29. Tan SM, Chin PL. Total hip arthroplasty for surgical management of advanced tuberculous hip arthritis: case report. *World J Orthop*. 2015; 6(2):316-21.
30. Öztürkmen Y, Karamehmetoğlu M, Leblebici C, Gökçe A, Caniklioğlu M. Cementless total hip arthroplasty for the management of tuberculosis coxitis. *Arch Orthop Trauma Surg*. 2010; 130(2):197-203.
31. Johnson R, Barnes KL, Owen R. Reactivation of tuberculosis after total hip replacement. *J Bone Joint Surg Br*. 1979; 61(2):148-50.
32. Kim YH, Han DY, Park BM. Total hip arthroplasty for tuberculous coxarthrosis. *J Bone Joint Surg Am*. 1987; 69(5):718-27.
33. Li L, Chou K, Deng J, Shen F, He Z, Gao S, et al. Two-stage total hip arthroplasty for patients with advanced active tuberculosis of the hip. *J Orthop Surg Res*. 2016; 11(1):38.
34. Oga M, Arizono T, Takasita M, Sugioka Y. Evaluation of the risk of instrumentation as a foreign body in spinal tuberculosis: clinical and biologic study. *Spine*. 1993;

- 18(13):1890-4.
35. Tiwari V, Khan SA, Kumar A, Poudel R, Kumar VS. Functional improvement after hip arthroscopy in cases of active paediatric hip joint tuberculosis: a retrospective comparative study vis-à-vis conservative management. *J Child Orthop.* 2015; 9(6):495-503.
36. Hardinge K, Cleary J, Charnley J. Low-friction arthroplasty for healed septic and tuberculous arthritis. *J Bone Joint Surg Br.* 1979; 61-B(2):144-7.
37. Jupiter JB, Karchmer AW, Lowell JD, Harris WH. Total hip arthroplasty in the treatment of adult hips with current or quiescent sepsis. *J Bone Joint Surg Am.* 1981; 63(2):194-200.