

RESEARCH ARTICLE

Results of Open Bankart Surgery for Recurrent Anterior Shoulder Dislocation with Glenoid Bone Defect and Concomitant Hill-Sachs Lesion

Morteza Nakhaei Amroodi, MD; Davod Jafari, MD; Ali A. Kousari, MD

Research performed at Shafa Orthopedic Hospital, Iran University of Medical Sciences, Tehran, Iran

Received: 11 August 2017

Accepted: 02 December 2017

Abstract

Background: Open Bankart surgery is the main treatment procedure in patients with recurrent anterior shoulder dislocation, especially in cases with glenoid bone defect. The goal of this study was to determine the outcomes after open Bankart surgery in cases of recurrent anterior shoulder dislocation with glenoid bone defects and concomitant Hill-Sachs lesions.

Methods: Between 2006 and 2010, 89 patients with recurrent anterior shoulder dislocation and concomitant glenoid bone defects (10-30%) and Hill-Sachs lesions undergoing open Bankart surgery were reviewed. The mean follow-up after surgery was 7 years (5.5-9.5 years). The recurrence rate as well as the degree of shoulder pain and daily activity level was determined subjectively based on the visual analogue scale (VAS) and activity daily living scale (ADLs). Shoulder range of motion (ROM) in abduction and external rotation was compared with contralateral side; and finally, the American shoulder and elbow score (ASES) and constant-Murley score (CMS) were calculated.

Results: Over 7 years of follow-up, a total of 15 patients (16.8%) undergoing surgery were found to have instability (3 patients (3.3%) with dislocation and 12 patients with (13.4%) subluxation). Patients with postsurgical instability had significantly larger glenoid bone defects ($P=0.0001$) and Hill-Sachs lesions ($P=0.019$) compared to those without instability. The mean loss of forward flexion compared with the normal contralateral side was 4° while the mean loss of external rotation between both sides was 5° . At the final visit, the average VAS was 0.4 (out of 10); ADL was 28.97 (range: 25-30); ASES was 96.1 (range: 78.3-100); and the mean CMS value was 93.9 (range: 82-100).

Conclusion: Open Bankart surgery with anteroinferior capsular shift for recurrent anterior shoulder dislocation with up to 30% glenoid bone defect and Hill-Sachs lesion provided desirable results in terms of shoulder function and recurrence rate. Bankart surgery is a successful and practical option in these patients and can be considered as an alternative to other procedures.

Level of evidence: IV

Keywords: Hill-sachs lesion, Glenoid bone defect, Open Bankart surgery, Recurrent shoulder dislocation

Introduction

Bankart lesion is the most common pathology observed in 85% of patients with recurrent anterior shoulder dislocation (1). The primary

therapeutic procedure includes capsule and labrum repair at glenoid anterior border along with anteroinferior capsular shift (1-3).

Corresponding Author: Ali A. Kousari, Bone and Joint Diseases Research Center, Department of Orthopedic Surgery, Chamran Hospital, Shiraz university of medical Sciences, shiraz, Iran
Email: dr.kousari57@gmail.com



THE ONLINE VERSION OF THIS ARTICLE
ABJS.MUMS.AC.IR

Despite the success in arthroscopic treatment of Bankart lesion, the rate of treatment failure and recurrence of dislocation in patients with extensive glenoid bone defects and Hill-Sachs lesions is still relatively high; and hence, open surgery is associated with greater success rate and lower recurrence in this group of patients (4-9).

Moreover, Latarjet procedure, as an effective treatment for patients with extensive glenoid defect, has a low recurrence rate; however, due to its significant complications, especially in case of technical problems, it is not chosen as the initial treatment for recurrent anterior shoulder dislocation in most clinical centers (10-12). This study aims to determine the midterm results and clinical recurrence rate after open Bankart surgery and antero-inferior capsular shift for recurrent anterior shoulder dislocation with glenoid bone defect and Hill-Sachs lesion.

Materials and Methods

After ethics committee's approval, a total of 89 patients undergoing open Bankart surgery with two anchor sutures and antero-inferior capsular shift due to recurrent anterior shoulder dislocation with glenoid bone defects (10-30%) and Hill-Sachs lesions (10-30%) were enrolled in this retrospective study between 2006-2010. The exclusion criteria included posterior dislocation, multidirectional instability, convulsive disorders and revision cases, concomitant SLAP (Superior Labral Anterior Posterior) lesions or massive rotator cuff tears, patients receiving arthroscopy or undergoing other surgical procedures and patients who were lost to the follow-up. Patients without bone defect or those with a glenoid defect of less than 10% and non-engaging Hill-Sachs were treated with arthroscopic surgery. Patients with a Hill-Sachs lesion or glenoid defect of more than 30% were treated with other surgical procedures like Latarjet surgery.

To determine the surgical procedure (arthroscopic, open Bankart, or Latarjet surgery) preoperative evaluation including physical examination, radiography, CT scan and MRI were performed for all patients. MRI was performed to assess the associated lesions such as Bankart or SLAP lesions; CT scan was used to assess bone defect in glenoid and humeral head; glenoid defects were determined using "best-fit circle" method; and the size of Hill-Sachs was measured using conventional methods described in "Atlas of Radiologic Measurement" (13, 14).

Surgical techniques

After general anesthesia, placing the patient in semi-sitting position, and prep and drape of entire affected upper extremity, a deltopectoral incision was performed. The cephalic vein and the conjugate tendon were retracted to the lateral and medial sides, respectively. The subscapularis tendon was splitted transversely in line with its fibers at the junction between its upper 2/3 and lower 1/3, and 1 cm medial to the insertion in an L-shaped fashion, and was held with stay sutures. The axillary nerve was explored and

protected until the end of the operation. The capsule was opened by NEER technique (T-shape incision that produces a superomedial and an inferomedial leaf). The Bankart lesion was observed and completed. The glenoid edge and 1-2 cm of the anterior cortex of the scapular neck were decorticated with a dental burr (3).

Two No. 2.8 anchor sutures (Fastak[®], Artex) were placed at 3 and 5 o'clock in the right shoulder and 7 and 9 o'clock in the left shoulder. Both threads of the inferior anchor were passed through the inferomedial leaf. One thread of the superior anchor was passed through the inferomedial leaf and the other through the superomedial leaf. To do so, the threads were directed from the innermost part of the capsule and labrum to the outsider using a suture shuttle. The distance between each thread was approximately 1 cm. The threads were tied on the anterior side of the capsule. After repairing the Bankart lesion, antero-inferior capsular shift was performed using NEER technique and with fiberwire[®] thread No. 2 at 20° external rotation and 20° abduction of the humerus. The rotator interval was repaired up to 0.5 cm of coracoid process without reefing or overlapping with the same sutures. The subscapularis tendon was also sutured to its anatomical site with the same sutures. A drain was inserted; the deltopectoral split was repaired with No. 2 Vicryl[®] sutures; the skin was repaired in two layers; the wound was dressed; and the shoulder was immobilized with sling & swathe [Figures 1; 2].

Post operation management

The patients were visited at 2, 6, and 12 weeks as well as 3, 6, and 12 months postoperation, and then annually for unlimited time.

Pendular movement exercises were started intermittently after two weeks. The immobilizer was removed 6 weeks after surgery and active assisted exercises were started at home and the physiotherapy department to restore full range of motion except for abduction in external rotation which was started after 12 weeks postoperatively concomitant with strengthening exercises. Patients were instructed to avoid extreme abduction in external rotation until one year postoperatively.

Assessment

The initial patient data including the age; gender; age, cause, and frequency of dislocation; and the duration of suffering were collected from the patients' clinical records. All patients with any signs or symptoms of subluxation or dislocation were screened out during the follow-up period. Post-operative dislocation was defined as any event that required manipulation for reduction. Subluxation was also defined as any event that the patient described as slip, move or pop in the shoulder that caused pain and led to abandonment of exercise and sports activities. The visual analog scale (VAS) was used to evaluate the postoperative pain, in which the patients assessed their pain level subjectively in final visit. The daily activity was evaluated based on ADL (activity daily living) questionnaire, which contained 10

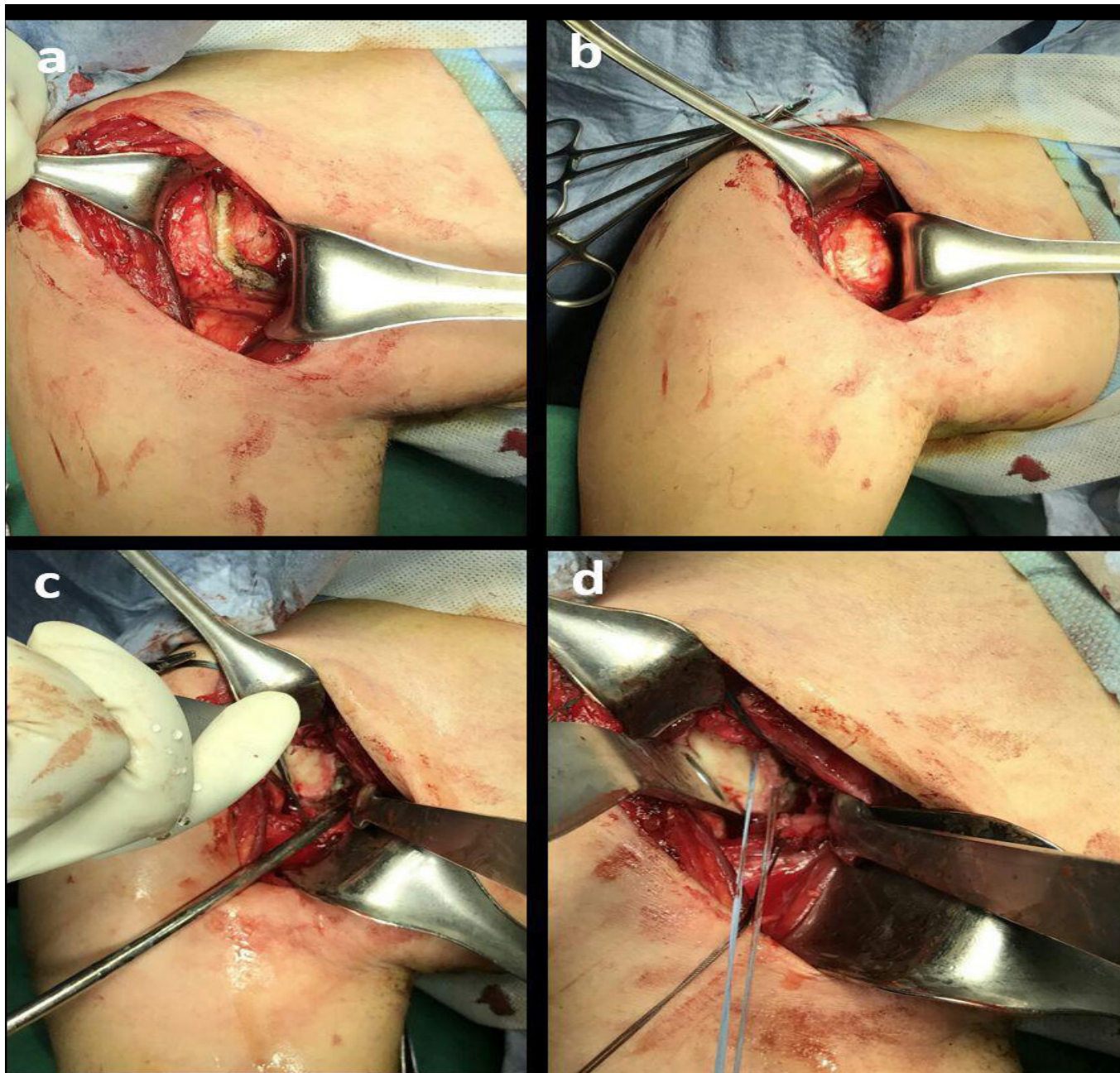


Figure 1. (a) L-shape incision at the superior two-thirds subscapularis tendon. (b) the capsule exposed after medial retraction of the subscapularis tendon. (c) The capsule was opened by NEER technique (T-shape incision) and the Bankart lesion was completed. the glenoid edge was decorticated with a dental burr. (d) Two anchor sutures were placed at 3 and 5 o'clock.

items daily on personal activities. ASES was computed using $[(10-VAS) \times 5] + [(5/3) \times ADL]$ formula (15).

Constant-Murley score (CMS) or constant shoulder score included pain (15 points), level of daily activities (ADL) (20 points), strength (25 points) and mobility (40 points). Shoulder mobility was measured by a

goniometer at forward elevation, abduction, external rotation at side and internal rotation. Strength was determined based on muscle strength in bearing weight at 90° shoulder abduction position based on Murley's scale (16).

Shoulder ROM in abduction and external rotation was

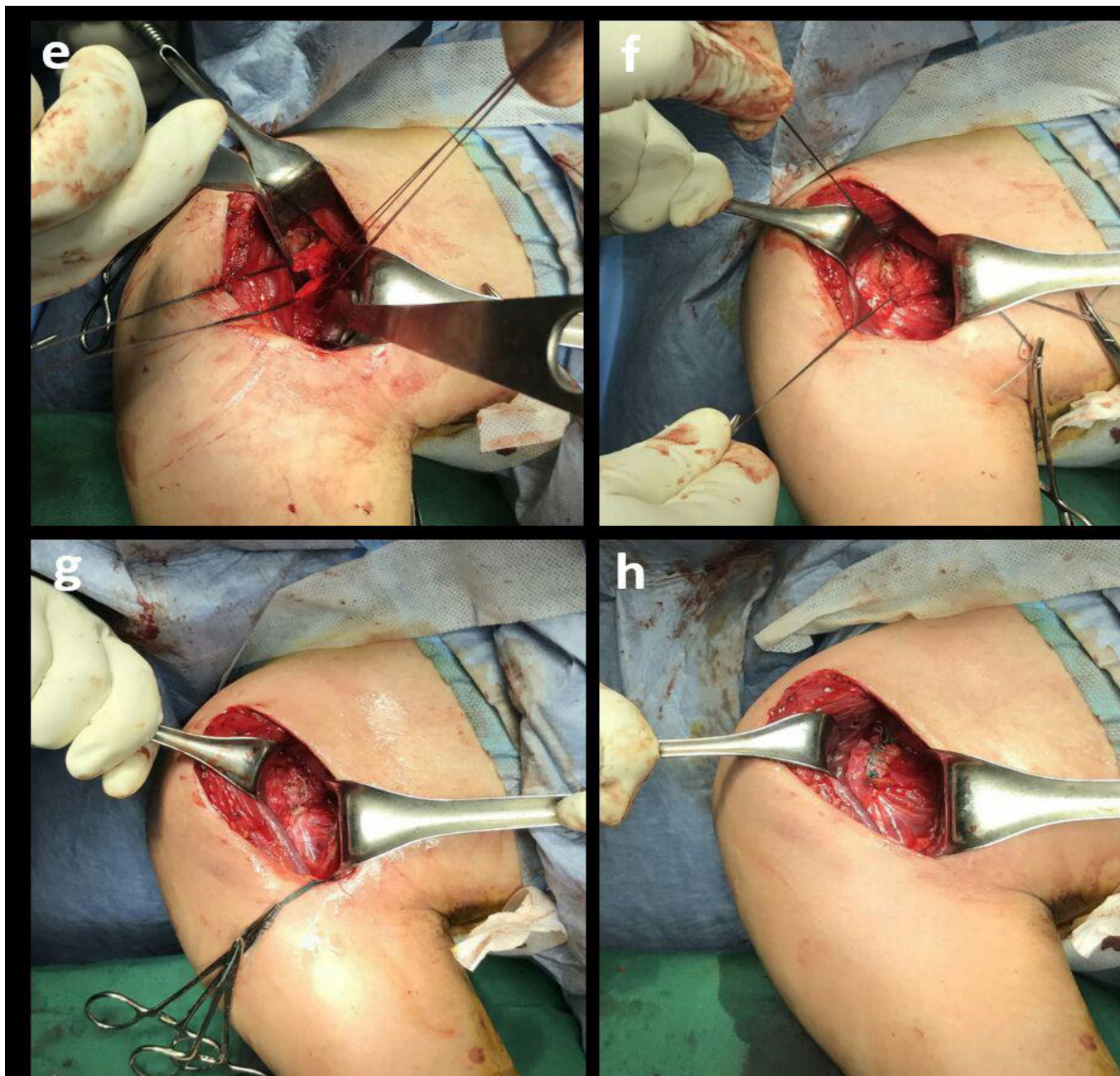


Figure 2. (e) anchor threads were passed through the superior and inferior leaves. (f) the threads were tied on the anterior side of the capsule and the capsular leaves held at the capsular shift position. (g) the capsular shift was performed using NEER technique. Rotator interval also was repaired. (h) subscapularis tendon was also sutured to its anatomical site.

evaluated and compared with contralateral side. Also, patient evaluation was performed by one orthopedic surgeon, who had not participated in any of the surgeries. Statistical analysis was performed using paired Student t test. The significance level was set at a $P < 0.05$. Data analysis was performed using SPSS

version 22 software.

Results

The number of patients referring for the final assessment was 89 patients out of whom, 72 were men and 17 were women with a mean age of 25.6 years

(18-36 years). The dislocation of dominant limbs was observed in 51 patients (57%). The average frequency of dislocation was 28 times (4-500 times) (based on interviews with patients), and the mean time from the first dislocation to the time of operation was 17 months (5-60 months).

Trauma was the primary cause of dislocation in 64 patients (72%); while 25 patients (28%) had suffered from this injury because of seizure. The use of tramadol was reported in 21 (84%) seizure-induced dislocations. The average follow-up period was 7 years (5.5 -9.5) during which, 15 patients (16.8%) had instability (12 (13.4%) subluxation, 3 (3.3%) dislocation). Of this figure, 3 patients with dislocation and 1 with subluxation were subjected to surgical treatment again. According to the preliminary analyses prior to the surgery, the average glenoid bone defect and Hill-Sachs lesions were 15.4% (10-30%) and 17.75% (10-30%), respectively, and all cases had both lesions (bipolar lesion) with a minimum 10% bone defect for each lesion. The average glenoid bone defect and Hill-Sachs lesion was 17% (10-25%) and 19.3 % (10-25%), respectively in patients (15 cases) with postsurgical instability. The average glenoid bone defect and Hill-Sachs lesion was 15.13% (10-30%) and 17.16 % (10-30%), respectively in patients (74 cases) without postsurgical instability. Comparison between the patients with and without postsurgical instability showed a significant difference in glenoid bone defects ($P=0.0001$) and Hill-Sachs lesions ($P=0.019$) in patients with postsurgical instability. This indicated the size of bone defect influence in increasing the postsurgical dislocation and recurrence rate.

In the final assessment, 64 patients (72%) felt no pain in the operated shoulder and the maximum severity of pain in patients based on VAS was 3 (out of 10). Also, the average severity of pain based on VAS was 0.4. The mean range of forward flexion on the operated side at the last follow up was 172° (range,160-190) compared to 176° (range,170-210) on the unaffected side with a 4° mean deficit. The mean external rotation with the elbow at the side was 48° (range: 30-80) on the affected side compared to 53°(range,40-100) on the intact side with a 5° mean deficit. Also ADL was 28.97 (range 25-30); ASES: 96.1 (range 78.3-100); and 44 patients (49%) had an ASES value of 100. The mean value of CMS was 93.9 (range: 82-100).

Discussion

Open Bankart surgery is a desirable procedure among conventional treatments for recurrent anterior shoulder dislocations. It yields the least recurrence rate compared to arthroscopic surgeries (2, 7). In particular, patients with extensive glenoid bone defects or engaged Hill-Sachs lesions show a higher recurrence rate. Hence, open surgery is the recommended procedure for these patients (10).

A major limitation of this study was the lack of a comparison group (such as patients undergoing Latarjet or arthroscopic Bankart surgeries). Moreover, this study offered midterm follow-up, and as noted

earlier, the chance of recurrence increases in the long term. In addition, in the final evaluation, the occurrence rate of joint osteoarthritis due to the failure to do radiography for all patients was not determined.

In previous studies, variable rates of recurrence have been reported after open Bankart surgery. In the study of Rowe, which is one of the first studies on the results of open Bankart surgery, on 145 patients, the recurrence of instability and dislocation following open Bankart surgery was 8% and 2%, respectively (1). In a study by Pelet al., which followed up 39 patients for 2 years, 3 patients (10%) were reported to have recurrence with a constant shoulder score of 73.4 (17).

The study of Mordor on 40 patients without glenoid defect, undergoing open Bankart surgery, instability was reported in 7 patients (17.5%) after 20-25 years, out of whom 5 patients had dislocation. Surprisingly, all 5 patients had reported trauma-induced recurrence after at least 8 years of going without any symptom. Subjective shoulder value (SSV) in patients with and without dislocation was 83.7 and 91.4 and the VAS was 0.6 and 0.8, respectively (18). Strahovink reported a recurrence rate of 12% for instability over a 9-year follow-up on 83 patients. The average VAS and CMS were 3.5 and 77, respectively (19). Uhorchak JM in his study on 66 athletes treated with open Bankart surgery reported only 2 cases (3%) of dislocation, but, 13 patients (20%) developed subluxation after surgery (20). However, satisfactions with the surgery was relatively high and the mean ASES score was 95 points (71-100) and the mean Rowe score was 82 points (40-100).

Berendes in an 11-year follow-up of 31 Bankart surgeries reported 2 cases (3%) of dislocation and 4 cases (13%) of subluxation. The mean Rowe score and constant shoulder score were 90 and 96, respectively (21). Magnusson studied 18 patients with a 7.5-year follow-up, reporting only 2 (11%) cases of dislocation and 1 (6%) of subluxation after surgery with the mean Rowe score and constant shoulder score of 90 and 89, respectively (22).

Mandeep compared open and arthroscopic Bankart surgeries by studying 24 patients with open Bankart surgery and 58 patients with arthroscopic Bankart after 39 months. He reported 4 cases (16.6%) of dislocation in the first group and 7 cases of instability (2 dislocations and 5 subluxations) in the second group. Also, the mean ASES score and constant shoulder score were 94.7 and 93.3, respectively, in patients with open Bankart (Group I), and 92.8 and 91.3, respectively, in patients with arthroscopic Bankart (Group II) (23).

In the final assessment of our patients, 72% reported no pain with VAS= 0.4 and the mean ASES and CMS were 96.1 and 93.9, respectively, which was more desirable and promising than previous studies. The recurrence and instability rates were 3.3% and 16.8%, respectively. In the interpretation of results, it should be noted that patients undergoing surgery in this study had 10 to 30% glenoid bone defect and concomitant 10 to 30% Hill-Sachs lesion, which could influence the recurrence rate. In this study, the average bone defect in patients with postsurgical instability was more

than those without postsurgical instability, indicating an increased recurrence rate of open bankart surgery in patients with increased size of glenoid bone defect and concomitant Hill-Sachs lesion. However, our study results conclude that open Bankart surgery with anteroinferior capsular shift is a practical procedure in recurrent anterior shoulder dislocation when glenoid bone defect and concomitant Hill-Sachs lesion is less than 30%.

Latarjet procedure is performed in patients with recurrent anterior shoulder dislocations with extensive glenoid defect. Recent studies have reported a high level of satisfaction and desirable function along with high shoulder stability after this surgical procedure (24-26). Zimmerman performed a comparison between 93 patients undergoing Latarjet surgical treatment and 271 patients treated with arthroscopic Bankart surgery, suggesting that the recurrence rate of dislocation and subluxation was 1% and 9%, respectively, in the Latarjet group and 13% and 19%, in the Bankart group (24). Mizano reported a recurrence rate of 5.9% in a 20-year follow-up after Latarjet surgery. Also, in the final analysis, 20% of patients were reported to have symptoms of osteoarthritis (27). The study of Havelius on comparing the results of 27 years of follow-up of Bankart and Latarjet surgeries suggested that postoperative instability was 13.8% and 28.7%, respectively, in the Latarjet and Bankart groups (28).

However, considering the disturbed shoulder anatomy after surgery in Latarjet surgery, the reproducibility and revision would be more difficult in cases of recurrence. There is also a greater risk of technical problems during the surgery as well as more complications. There is a higher risk of osteoarthritis in long-term follow-ups especially in cases with technical problems (12, 27, 28)

Open Bankart surgery with anteroinferior capsular shift for recurrent anterior shoulder dislocation with glenoid bone defect (up to 30%) and concomitant Hill-Sachs lesion offered desirable results with low midterm recurrence rate. Despite the increased failure rate in patients with massive bone defects, open Bankart surgery is a successful and practical alternative option to other procedures.

Morteza Nakhaei Amroodi MD

Davod Jafari MD

Ali A. Kousari MD

Bone and Joint Reconstruction Research Center,
Department of Orthopedic Surgery, Shafa Orthopedic
Hospital, Iran university of medical Sciences, Tehran, Iran

References

1. Rowe CR, Patel D, Southmayd WW. The Bankart procedure: a long-term end-result study. *J Bone Joint Surg Am.* 1978; 60(1):1-16.
2. Linters TR, Franta AK, Wolf FM, Leopold SS, Matsen FA 3rd. Arthroscopic compared with open repairs for recurrent anterior shoulder instability. A systematic review and meta-analysis of the literature. *J Bone Joint Surg Am.* 2007; 89(2):244-54.
3. Neer CS 2nd, Foster CR. Inferior capsular shift for involuntary inferior and multidirectional instability of the shoulder: a preliminary report. *J Bone Joint Surg Am.* 1980; 62(6):897-908.
4. Kim SH, Ha KI, Cho YB, Ryu BD, Oh I. Arthroscopic anterior stabilization of the shoulder: two to six-year follow-up. *J Bone Joint Surg Am.* 2003; 85-A(8):1511-8.
5. Aslani H, Zafarani Z, Ebrahimpour A, Salehi S, Moradi A, Sabzevari S. Early clinical results of arthroscopic remplissage in patients with anterior shoulder instability with engaging hill-sachs lesion in Iran. *Arch Bone Joint Surg.* 2014; 2(1):43-6.
6. Boileau P, Villalba M, Hery JY, Balg F, Ahrens P, Neyton L. Risk factors for recurrence of shoulder instability after arthroscopic Bankart repair. *J Bone Joint Surg Am.* 2006; 88(8):1755-63.
7. Freedman KB, Smith AP, Romeo AA, Cole BJ, Bach BR Jr. Open Bankart repair versus arthroscopic repair with transglenoid sutures or bioabsorbable tacks for recurrent anterior instability of the shoulder: a meta-analysis. *Am J Sports Med.* 2004; 32(6):1520-7.
8. Bigliani LU, Newton PM, Steinmann SP, Connor PM, McIlveen SJ. Glenoid rim lesions associated with recurrent anterior dislocation of the shoulder. *Am J Sports Med.* 1998; 26(1):41-5.
9. Burkhart SS, De Beer JF. Traumatic glenohumeral bone defects and their relationship to failure of arthroscopic Bankart repairs: significance of the inverted-pear glenoid and the humeral engaging Hill-Sachs lesion. *Arthroscopy.* 2000; 16(7):677-94.
10. Hovelius L, Sandström B, Sundgren K, Saebö M. One hundred eighteen Bristow-Latarjet repairs for recurrent anterior dislocation of the shoulder prospectively followed for fifteen years: study I-clinical results. *J Shoulder Elbow Surg.* 2004; 13(5):509-16.
11. Burkhart SS, De Beer JF, Barth JR, Cresswell T, Roberts C, Richards DP. Results of modified Latarjet reconstruction in patients with anteroinferior instability and significant bone loss. *Arthroscopy.* 2007; 23(10):1033-41.

12. Griesser MJ, Harris JD, McCoy BW, Hussain WM, Jones MH, Bishop JY, et al. Complications and re-operations after Bristow-Latarjet shoulder stabilization: a systematic review. *J Shoulder Elbow Surg.* 2013; 22(2):286-92.
13. Barchilon VS, Kotz E, Barchilon Ben-Av M. A simple method for quantitative evaluation of the missing area of the anterior glenoid in anterior instability of the glenohumeral joint. *Skeletal Radiol.* 2008; 37(8):731-6.
14. Keats TE, Siström C. Atlas of radiologic measurement. 7th ed. London: Mosby Incorporated; 2001. P. 181-2.
15. Richards RR, An KN, Bigliani LU, Friedman RJ, Gartsman GM, Gristina AG, et al. A standardized method for the assessment of shoulder function. *J Shoulder Elbow Surg.* 1994; 3(6):347-52.
16. Constant CR, Murley AH. A clinical method of functional assessment of the shoulder. *Clin Orthop Relat Res.* 1987; 214(1):160-4.
17. Pelet S, Jolles BM, Farron A. Bankart repair for recurrent anterior glenohumeral instability: results at twenty-nine years' follow-up. *J Shoulder Elbow Surg.* 2006; 15(2):203-7.
18. Moroder P, Odorizzi M, Pizzinini S, Demetz E, Resch H, Moroder P. Open Bankart repair for the treatment of anterior shoulder instability without substantial osseous Glenoid defects: results after a minimum follow-up of twenty years. *J Bone Joint Surg Am.* 2015; 97(17):1398-405.
19. Strahovnik A, Fokter SK. Long-term results after open Bankart operation for anterior shoulder instability. *Wien Klin Wochenschr.* 2006; 118(Suppl 2):58-61.
20. Uhorchak JM, Arciero RA, Huggard D, Taylor DC. Recurrent shoulder instability after open reconstruction in athletes involved in collision and contact sports. *Am J Sports Med.* 2000; 28(6):794-9.
21. Berendes TD, Wolterbeek R, Pilot P, Verburg H, te Slaa RL. The open modified Bankart procedure: outcome at follow-up of 10 to 15 years. *J Bone Joint Surg Br.* 2007; 89(8):1064-8.
22. Magnusson L, Ejerhed L, Rostgard L, Sernert N, Kartus J. Absorbable implants for open shoulder stabilization. A 7-8-year clinical and radiographic follow-up. *Knee Surg Sports Traumatol Arthrosc.* 2006; 14(2):182-8.
23. Virk MS, Manzo RL, Cote M, Ware JK, Mazzocca AD, Nissen CW, et al. Comparison of time to recurrence of instability after open and arthroscopic Bankart repair techniques. *Orthop J Sports Med.* 2016; 4(6):2325967.
24. Zimmermann SM, Scheyerer MJ, Farshad M, Catanzaro S, Rahm S, Gerber C, et al. Long-term restoration of anterior shoulder stability: a retrospective analysis of arthroscopic Bankart repair versus open Latarjet procedure. *J Bone Joint Surg Am.* 2016; 98(23):1954-61.
25. Ebrahimzadeh MH, Moradi A, Zarei AR. Minimally invasive modified Latarjet procedure in patients with traumatic anterior shoulder instability. *Asian J Sports Med.* 2015; 6(1):e26838.
26. Ebrahimzadeh MH, Birjandinejad A, Golhasani F, Moradi A, Vahedi E, Kachooei AR. Cross-cultural adaptation, validation, and reliability testing of the Shoulder Pain and Disability Index in the Persian population with shoulder problems. *Int J Rehabil Res.* 2015; 38(1):84-7.
27. Mizuno N, Denard PJ, Raiss P, Melis B, Walch G. Long-term results of the Latarjet procedure for anterior instability of the shoulder. *J Shoulder Elbow Surg Am.* 2014; 23(11):1691-9.
28. Hovelius L, Vikersjö O, Olofsson A, Svensson O, Rahme H. Bristow-Latarjet and Bankart: a comparative study of shoulder stabilization in 185 shoulders during a seventeen-year follow-up. *J Shoulder Elbow Surg.* 2011; 20(7):1095-101.