

CASE REPORT

Simultaneous Quadruple Joint Replacement (QJR) in Disabling Juvenile Rheumatoid Arthritis – a Case Report with Review of Literature

Rajesh Malhotra, MS, FRCS; Deepak Gautam, MS; Bhavuk Garg, MS; Anjan Trikha, MD

Research performed at All India Institute of Medical Sciences (AIIMS), New Delhi, India

Received: 21 September 2017

Accepted: 03 October 2017

Abstract

We wish to present a case of 47-year-old patient with Juvenile Rheumatoid Arthritis and ankylosis of both hips and both knees treated by bilateral hip and knee arthroplasty in a single anaesthesia i.e. Quadruple joint replacement in single sitting. He was back on his feet from his bed-ridden state within the fortnight following surgery. He has been followed up for four years and has been performing his activities of daily living independently. We discuss the preoperative planning, surgical details and post-operative rehabilitation and unique challenges pertaining to this case.

Level of evidence: IV

Keywords: Bilateral hip and knee arthroplasty, Juvenile rheumatoid arthritis, Simultaneous quadruple joint replacement

Introduction

Total joint replacement has become the standard of care for patients with end stages of Juvenile Rheumatoid Arthritis (JRA) (1-5). There are several reports of isolated conversion of an ankylosed hip or knee to total joint replacement (6-9). Also, there are several reports of simultaneous bilateral hip and knee replacement in such patients (10-13). However, the conversion of bilateral hip and knee ankylosis to total joint replacement in the same anaesthetic sitting has not been described previously. We wish to present the result of total joint replacement in a patient with bilateral ankylosis of hips and knees in a single anaesthesia.

Case presentation

47 years old male, a diagnosed case of Juvenile Rheumatoid Arthritis (JRA) presented with end stage arthritis of both hips and knees. He was bedridden for past one year. He was not even able to sit and was

dependent on his family members for his activities of daily living. On physical examination, the right hip had a fixed deformity of 30° flexion, 20° adduction and 25° external rotation. The left hip had a fixed deformity of 35° flexion, 15° adduction and 20° external rotation. Both the knees were fixed at 15° flexion. Standard radiographs of both the hips and the knees showed that all four joints had fibrous ankylosis [Figure 1].

He was planned for quadruple joint replacement including both hips and knees. He was counseled and was well motivated to undergo total joint replacement. The anaesthetic part was highly challenging. He underwent naso-tracheal intubation under fibre-optic guidance and caudal catheter for analgesia. He first underwent total hip arthroplasty of right side followed by the left. Both the procedures were performed via posterior approach with patient in the lateral position. Positioning of the patient was of great concern, particularly due to deformed knees and the

Corresponding Author: Deepak Gautam, Department of Orthopedics, All India Institute of Medical Sciences (AIIMS), New Delhi, India
Email: cmcdeepak@yahoo.com



THE ONLINE VERSION OF THIS ARTICLE
ABJS.MUMS.AC.IR

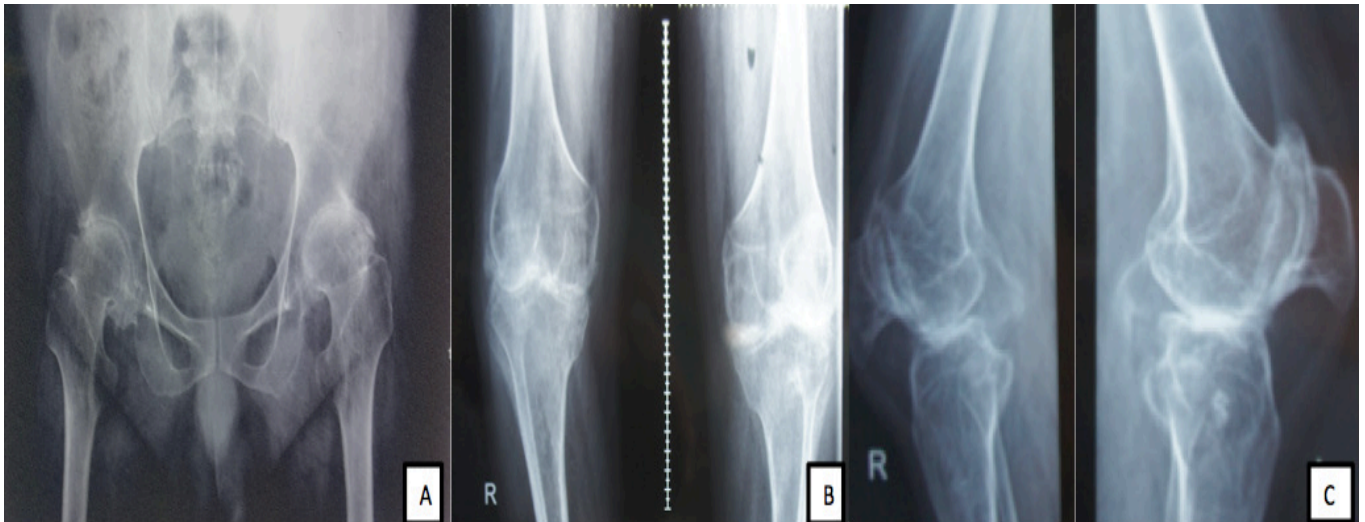


Figure 1. (A) Anteroposterior radiograph of the pelvis showing end stage arthritis of both the hips joints (B) Anteroposterior radiograph of both the knees showing end stage arthritis of both the knee joints (C) Lateral radiograph of both the knees showing end stage arthritis of both the knee joints.

other hip. The joint dislocation was difficult for which in situ neck osteotomy was to be done. The acetabulum was prepared and the uncemented cup (R3, Smith & Nephew, Memphis, TN, US) was used. Broaching of the femur also presented difficulty because of the ankylosed knee and restricted internal rotation of the hip. An uncemented stem (Synergy, Smith & Nephew, Memphis, TN, US) was inserted. The articulation used was metal on polyethylene. After both the hips were replaced, an opinion was sought from the anesthetists for fitness of proceeding with knee replacement. The patient's vitals were stable and the blood loss was much less than expected. A decision for both knee replacements was taken, as that would save the trouble of undergoing the same difficult anaesthetic procedure again.

We proceeded with bilateral total knee replacement simultaneously with two teams. A medial parapatellar approach was used. The fused patellofemoral joint was osteotomised from medial side. The tibiofemoral ankylosis was also divided with an osteotome. The bone was found to be very osteoporotic. Femoral preparation was done first as it would provide a space for tibial preparation. A stemmed tibial component and Posterior stabilized femoral component (Genesis II, Smith & Nephew, Memphis, TN, US) was used. The patella was resurfaced and a lateral retinacular release was performed to improve the patellar tracking. The whole procedure took four and half-hours excluding the anaesthesia time. The total blood loss was 1100 ml.

Postoperatively, the patient was monitored in ICU for two days with analgesics round the clock. The intravenous antibiotics were given for 5 days. Prophylaxis for DVT was started with subcutaneous injection of Low Molecular Weight Heparin and continued for 2 weeks. Indomethacin was started for prophylaxis of heterotopic ossification. The wound was inspected on second postoperative day,

the drains were removed and the patient was made to sit by the bedside. We had a considerable delay in making the patient stand and walk in view of osteoporotic bone and muscle weakness due to prolong immobilization. The sutures were removed on 14th postoperative day and the patient was made to stand and walk few steps with the help of walker. An intravenous injection of Zoledronic acid (5 mg) was given in view of osteoporosis. He was put under gradual range of motion exercises for both hips and the knees along with Interferential therapy for the knees. He continued to walk with walker followed by a stick and gradually regained his independence.

At latest follow up of 4 years, he is able to move around independently without any support. The range of movement at the right knee is 5° to 100° with a 5° extension lag and 5° to 90° on the left side. The right hip has flexion of 80° , abduction of 25° and external rotation of 15° . In the left hip the flexion is up to 75° with 30° abduction and external rotation of 10° . Radiologically, ectopic bone formation is seen right hip and lateral aspect of left knee. However, there were no symptoms pertaining to the heterotopic bone formation. There were no signs of loosening or implant failure as seen in the serial radiographs [Figures 2; 3].

Discussion

The aim of quadruple joint replacement was to render the joints painless, correct the deformity, and make him walk as early as possible. There are several successful reports of dramatic improvement in quality of life following sequential bilateral hip and knee replacement in patients with disabling JRA (1, 14-17).

Earlier, we had reported the successful outcome of bilateral simultaneous total hip replacements in 54 patients with 92 ankylosed hips due to Ankylosing Spondylitis. Among them, in 18 patients, knees were

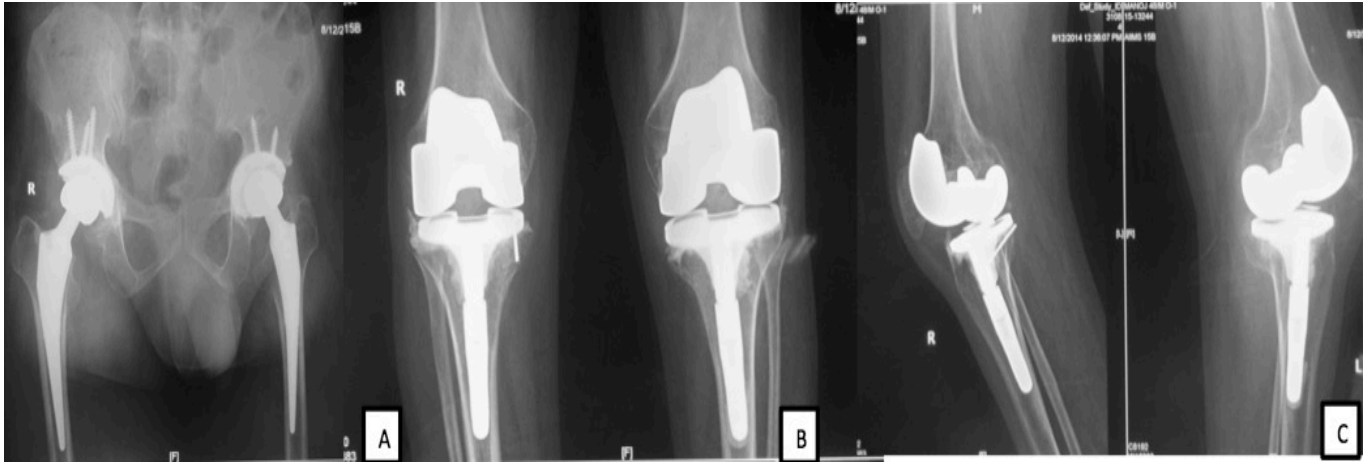


Figure 2. One year follow up X-ray showing (A) Anteroposterior view of the pelvis with both hips (B) Anteroposterior view of both the knees (C) Lateral view of both the knees. Note the heterotopic bone formation in the right hip as well as the left knee. However, the patient was asymptomatic.

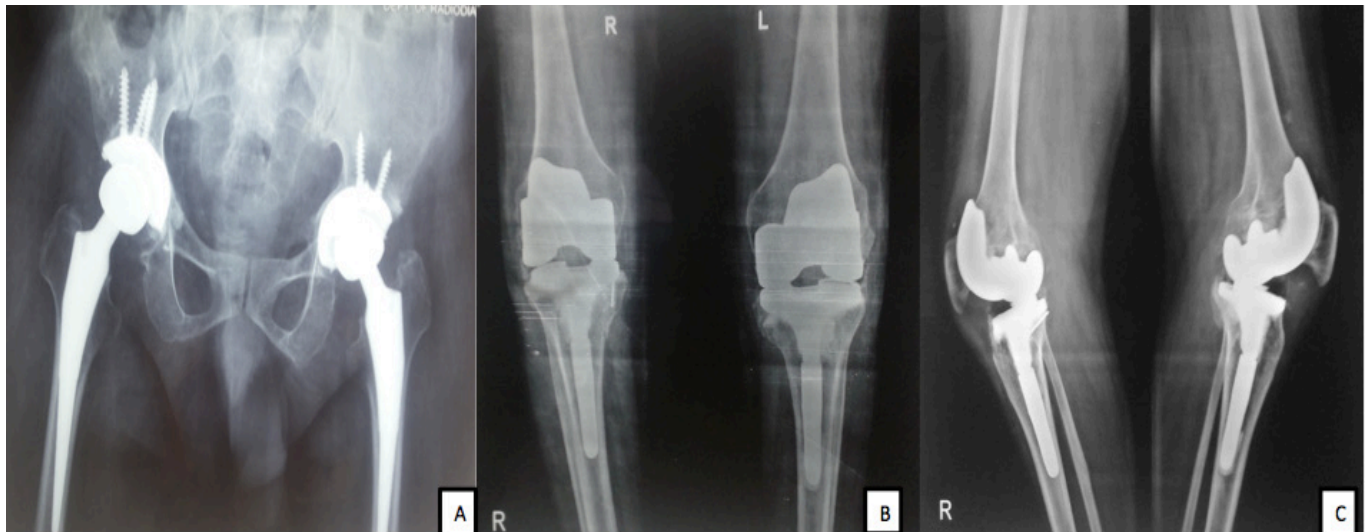

Figure 3. Four years follow up X-ray showing (A) Anteroposterior view of the pelvis with both hips (B) Anteroposterior view of both the knees (C) Lateral view of both the knees.

also operated simultaneously to correct the non-arthritic knee contracture associated with Ankylosing Spondylitis (18). Knee contracture was released by modified posterior soft tissue release (19). So, the concept and need for four joint surgeries was much felt by us for these difficult patients if they present with arthritic knees in addition to hips. The current case was a step ahead of this where the arthritic knees were also replaced simultaneously. Yoshino and Jegersen et al in their independent series of 18 & 16 patients respectively with Rheumatoid Arthritis who underwent replacement of both hips and knees in stages concluded that bilateral replacement of hip and knees can achieve the objectives of relieving pain

and improving the quality of life in severely disabled patients (20, 21). Kevin et al, in his study with 6 consecutive patients with JRA where 5 were wheel chair bound preoperatively, reported good long-term functional results (1). He emphasized that good long term functional results can be obtained in patients with relatively young age, and, early and aggressive approach to the joints. Ranawat et al in his study of 16 patients with JRA reported that 12 of them required bilateral hip and knee replacement to make them ambulatory (22). Of the 12 patients, 8 of them had undergone bilateral total hip replacement under single anaesthesia followed by bilateral total knee replacement in later stage, remaining 4 had staged

procedures. In an average follow up of 4 years, the disability score increased from 40.3 to 79.9.

In the current case, the decision to replace all the four joints in single sitting was taken because of the following reasons:

1. The patient needed the replacement of all the four joints. Replacing any one, two or even 3 joints leaving one stiff joint would not have permitted him to sit or walk properly.
2. Staging these surgeries has the distinct risk of residual stiffness or reankylosis in case the subsequent surgery is delayed.
3. This is particularly true as staging these surgeries would require at least an interval of 6 weeks as major joint replacements may increase the risk of infection if performed in quick succession.
4. A delay in replacements between hips and knees would make it difficult for the patient to cope emotionally with repeated major surgery and prolonged hospital stay.
5. The patient's hemoglobin and other blood parameters were within the normal range which limited the risk related to the anaesthesia.
6. It was a case of difficult intubation from anaesthetic point of view. In a patient with successful intubation at one time and stable hemodynamics, it was wise to go along with the major surgery at one time.
7. The rehabilitation would be easier with all the joints replaced together than with some stiff major joints remaining with others replaced. Rather, there would be a chance of development of stiffness in the replaced joints if the mobilization is not adequate and easy.
8. Replacing all the four joints and making the patient walk early would decrease the chance of all those unseen comorbidities like osteoporosis, bedsores, chest and urinary tract infection.

9. It gives tremendous psychological benefits to the patient after he/she is mobilized.

At 4 years follow up, the range of movements achieved at the hip and knee were satisfactory and the patient was able to perform his activities of daily living independently.

We suggest that simultaneous quadruple joint replacement is possible and is the quickest way to put the patient back on his/her own feet. One stage surgery accomplishes a lot. It avoids inordinate delay in stages due to interval complications, allows quick rehabilitation and provides psychological benefits to the patients. However, proper patient selection and the institutional support are vital.

Disclaimer: The views expressed in this article are our own and not an official position of the institution.

Funding source: This work was funded by the Wellcome Trust/DBT India Alliance Fellowship Grant (No. IA/RTF/15/1/1003). Deepak Gautam is the recipient of the grant.

Conflict of interest: Rest of the authors do not take any benefits in any form or have received or will be receiving from a commercial party related directly or indirectly to the subject of this article.

Rajesh Malhotra MS FRCS
Deepak Gautam MS
Bhavuk Garg MS
Anjan Trikha MD
All India Institute of Medical Sciences (AIIMS), New Delhi,
India

References

1. Mulhall KJ, Saleh KJ, Thompson CA, Severson EP, Palmer DH. Results of bilateral combined hip and knee arthroplasty in very young patients with juvenile rheumatoid arthritis. Arch Orthop Trauma Surg. 2008; 128(3):249-54.
2. Jolles BM, Bogoch ER. Juvenile arthritis patients report favorable subjective outcomes of hip arthroplasty despite poor standard outcome scores. J Arthroplasty. 2012; 27(9):1622-8.
3. Li XA, Iyer S, Cross MB, Figgie MP. Total joint replacement in adolescents: literature review and case examples. Curr Opin Pediatr. 2012; 24(1):57-63.
4. Kilgus DJ, Amstutz HC, Wolgin MA, Dorey FJ. Joint replacement for ankylosed hips. J Bone Joint Surg Am. 1990; 72(1):45-54.
5. Siavashi B, Mohseni N, Zehtab MJ, Ramim T. Clinical outcomes of total hip arthroplasty in patients with ankylosed hip. Arch Bone Jt Surg. 2014; 2(1):25-30.
6. Hardinge K, Williams D, Etienne A, MacKenzie D, Charnley J. Conversion of fused hips to low friction arthroplasty. J Bone Joint Surg Br. 1977; 59-B(4): 385-92.
7. Strathy GM, Fitzgerald RH Jr. Total hip arthroplasty in the ankylosed hip. A ten-year follow-up. J Bone Joint Surg Am. 1988; 70(7):963-6.
8. Naranja RJ Jr, Lotke PA, Pagnano MW, Hanssen AD. Total knee arthroplasty in a previously ankylosed or arthrodeseed knee. Clin Orthop Relat Res. 1996; 331:234-7.
9. Scott RD. Total hip and knee arthroplasty in juvenile

- rheumatoid arthritis. *Clin Orthop Relat Res.* 1990; 259:83-91.
10. Aghayev E, Beck A, Staub LP, Dietrich D, Melloh M, Orljanski W, et al. Simultaneous bilateral hip replacement reveals superior outcome and fewer complications than two-stage procedures: a prospective study including 1819 patients and 5801 follow-ups from a total joint replacement registry. *BMC Musculoskelet Disord.* 2010; 11:245-55.
 11. Johnston LR, Clift BA, Abboud RJ. Bilateral simultaneous hip replacement versus bilateral sequential hip replacement. A 7-year data review. *Orthop Nurs.* 2011; 30(2):119-23.
 12. Pfeil J, Höhle P, Rehbein P. Bilateral endoprosthetic total hip or knee arthroplasty. *Dtsch Arztebl Int.* 2011; 108(27):463-8.
 13. Schwarzkopf R, Olivieri P, Jaffe WL. Simultaneous bilateral total hip arthroplasty with hydroxyapatite-coated implants: a 20-year follow-up. *J Arthroplasty.* 2012; 27(7):1364-9.
 14. Malviya A, Foster HE, Avery P, Weir DJ, Deehan DJ. Long term outcome following knee replacement in patients with juvenile idiopathic arthritis. *Knee.* 2010; 17(5):340-4.
 15. Pakos EE, Paschos NK, Xenakis TA. Long term outcomes of total hip arthroplasty in young patients under 30. *Arch Bone Jt Surg.* 2014; 2(3):157-62.
 16. Bangjian H, Peijian T, Ju L. Bilateral synchronous total hip arthroplasty for ankylosed hips. *Int Orthop.* 2012; 36(4):697-701.
 17. Jolles BM, Bogoch ER. Quality of life after TKA for patients with juvenile rheumatoid arthritis. *Clin Orthop Relat Res.* 2008; 466(1):167-78.
 18. Bhan S, Eachempati KK, Malhotra R. Primary cementless total hip arthroplasty for bony ankylosis in patients with ankylosing spondylitis. *J Arthroplasty.* 2008; 23(6):859-66.
 19. Bhan S, Rath S. Modified posterior soft tissue release for management of severe knee flexion contracture. *Orthopedics.* 1989; 12(5):703-8.
 20. Yoshino S, Fujimori J, Morishige T, Uchida S. Bilateral joint replacement of hip and knee joints in patients with rheumatoid arthritis. *Arch Orthop Trauma Surg.* 1984; 103(1):1-4.
 21. Jergesen HE, Poss R, Sledge CB. Bilateral total hip and knee replacement in adults with rheumatoid arthritis: an evaluation of function. *Clin Orthop Relat Res.* 1978; 137:120-8.
 22. Ranawat CS, Bryan WJ, Inglis AE. Total knee arthroplasty in juvenile arthritis. *Arthritis Rheum.* 1983; 26(9):1140-4.