

SYSTEMATIC REVIEW

Denosumab in Patients with Giant Cell Tumor and Its Recurrence: A Systematic Review

Khodamorad Jamshidi, MD; Mohamad Gharehdaghi, MD; Sami Sam Hajjaliloo, MD; Masoud Mirkazemi, MD; Kamran Ghaffarzadehgan, MD; Azra IZANLOO, Msc

Research performed at Razavi Hospital, Mashhad, Iran and Iran University of Medical Sciences, Tehran, Iran

Received: 09 August 2017

Accepted: 18 January 2018

Abstract

Recent studies suggest that Denosumab reduces tumor size, therefore, makes the surgery easier with lower morbidity. However, some studies have reported several complications for this drug. So, this systematic review was performed to determine the effectiveness and safety of Denosumab in reducing bone destructions activity of giant cell tumor and skeletal-related events (SRE) in affected patients with giant cell tumor of bone (GCTB) and its recurrence.

We explored studies in PubMed, and Cochrane Library. For this purpose, articles of various levels were retrieved until October 22, 2016. Two reviewers assessed the articles independently based on predefined criteria to extract the relevant data. Primary outcomes associated with skeletal-related event, overall survival, and secondary outcomes such as pain, quality of life and adverse events were evaluated and analyzed.

The total population of this meta-analysis consisted of 686 patients. Of this population, 55% had primary GCTB and 45% had giant cell tumor recurrence, with 2% experiencing secondary recurrence.

The results showed the effectiveness of Denosumab in reducing the tumor size due to inhibiting the Osteoclastogenesis. Denosumab did not show any effect on reducing tumor recurrence, but, in cases where complete tumor surgery is not possible and tumor residuals may remain, Denosumab can be helpful. Also, the clinicians should consider the risk benefit of Denosumab.

Level of evidence: I

Keywords: Denosumab, Giant cell tumor of bone, Meta-analysis, Recurrence, Systematic review

Introduction

Giant cell tumor is considered as a benign aggressive tumor with a recurrence rate of 0-65% depending on the type of treatment and tumor location (1, 2). Secondary malignant transformations in a typical pathological form of giant cell tumor without radiotherapy are rare (occurring in less than one percent of patients) (3). It is highly improbable to emerge malignantly in initial biopsy (4). Tumor recurrence usually occurs in most cases that receive

radiotherapy or have multiple cysts lesion in the range of 1.4 to 6.6% (5-7).

The giant cell tumor treatment is highly controversial. Surgical treatment options include curettage using high-speed burr or resection (8). Curettage has a high recurrence rate, but maintains the adjacent joint function. Resection with a wide margin reduces tumor recurrence but correlates with worse functional outcomes.

In 2013, FDA approved Denosumab as a monoclonal

Corresponding Author: Azra IZANLOO, Razavi Cancer Research Center, Razavi Hospital, Imam Reza International University, Mashhad, Iran
Email: a.izanloo64@gmail.com



THE ONLINE VERSION OF THIS ARTICLE
ABJS.MUMS.AC.IR

antibody that activates the receptor activator of nuclear factor kappa-B ligand (RANKL) to treat adults and adolescents with giant cell tumors in cases where surgical resection has considerable side effects or is unresectable (9).

The giant cell tumor is considered as biphenotypic cell pathology with the interaction of mesenchymal spindle-like stromal cells that express the RANKL and osteoclast giant cells that are activated with RANKL, resulting in bone resorption (10). In general, it can be said that giant cell tumor of bone (GCTB) with primary behavior is benign and is traditionally treated with surgery. However, the disease can recur even after the best surgical intervention. In addition, it can develop in places where surgery will be difficult and risky. Therefore, understanding the role of RANKL in the pathophysiology of giant cell tumors of bone can lead to the application of Denosumab.

Denosumab is a monoclonal antibody that binds with RANKL and inhibits osteoclastogenesis directly. It has been shown to cause objective changes in tumors with clinical response in patients with non-removable tumors or huge recurrences (11). Recently, Denosumab

has been reported to destroy RANKL expression almost completely, with pathologic assessment demonstrating the absence of giant cells but the persistence of stromal neoplastic cells (12).

A host of questions such as the efficacy of Denosumab in treating GCTB have been raised. Accordingly, this paper seeks to review studies about the effectiveness of Denosumab on GCTB and how to manage it under these conditions and evaluate the skeletal-related complication.

In this study, the effectiveness of Denosumab was considered as decreasing the tumor size and prevention of recurrence and growing of tumor residual.

Materials and Methods

Sources and search strategies

We searched all English articles in PubMed and Cochrane Library databases on October 22, 2016. The references of articles were also reviewed manually. The search strategy is shown in Figure 1.

Selection of studies

The titles and abstracts of all articles and their

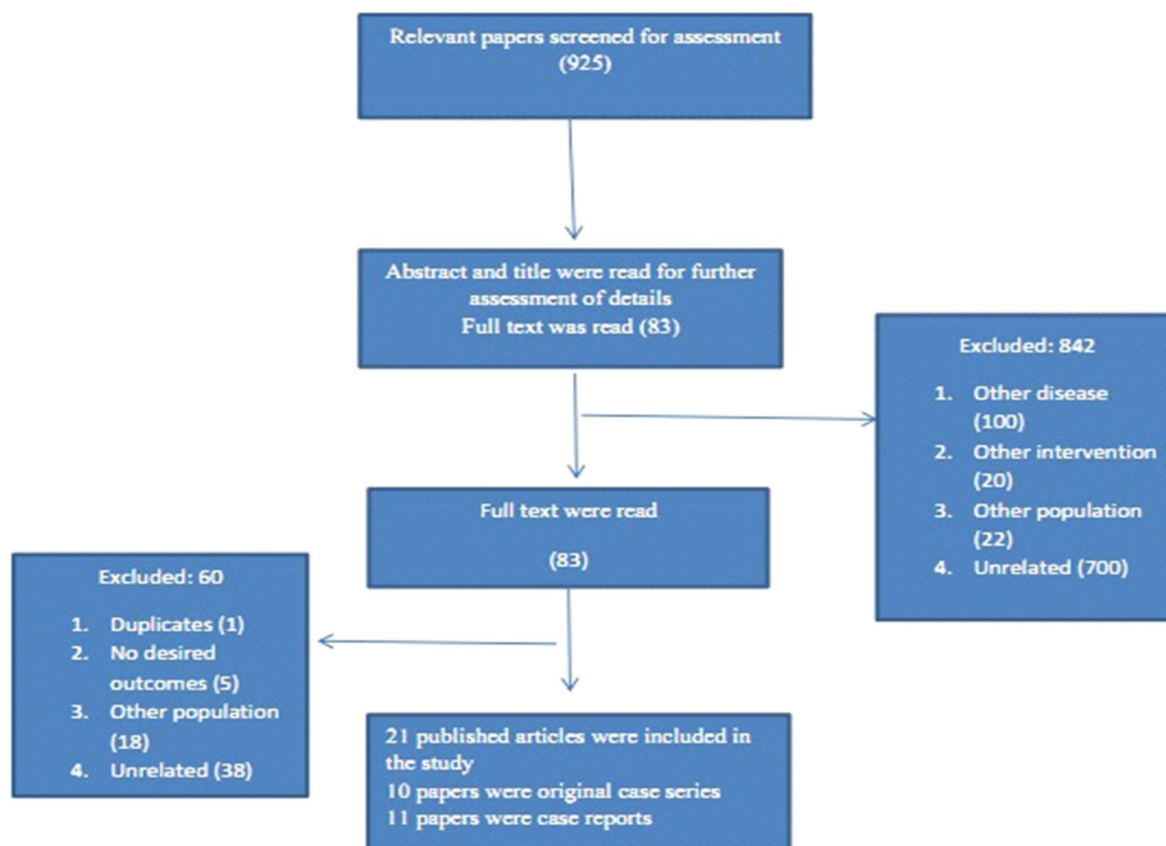


Figure 1. Search strategy.

Table 1. Risk of bias for studies included in the meta-analysis

Study	Adequate sequence generation	Adequate allocation concealment	Blinding	Incomplete outcome data addressed	Free of selective Reporting
Thomas, 2010 (14)	Low	Low	Low	Low	Low
Daniel, 2012 (15)	Low	Low	Low	Low	Low
Chawla, 2013 (9)	Low	Low	Low	Low	Low
Martin, 2014 (16)	Low	Low	Low	Low	Low
Ueda, 2015 (17)	Low	Low	Low	Low	Low
Rutkowshi, 2015 (19)	Low	Low	Low	Low	Low
Girolami, 2016 (18)	Low	Low	Low	Low	Low
Traub, 2016 (20)	Low	Low	Low	Low	Low
Relehi, 2016 (21)	Low	Low	Low	Low	Low
Wojcik, 2016 (22)	Low	Low	Low	Low	Low

citations were reviewed by two independent reviewers (an orthopedic oncologist and a Master of Medical Education) and possible disagreements were resolved through negotiation and discussion.

Inclusion criteria

All studies about the effectiveness of Denosumab (at any dose or frequency) for the treatment of patients with GCTB and its recurrence were investigated and those possessing at least one of the measures under study such as occurrence of SRE, overall survival, overall progression of disease or adverse effects were included.

The abstracts presented at conferences, which had been printed in the conference booklet but their full text was not published in any journal, were also included in the study. All papers in which the study population had tumors other than GCTB or children with this condition were excluded from the study.

It is worth noting that only research articles were considered in this meta-analysis.

Data extraction

Primary outcomes of the study included: 1) Skeletal-related event (SRE): This is as a pathological fracture, bone radiotherapy; 2) Overall survival: which covered the period of entering the study until the death of participants; 3) Histopathologic results: This referred to the absence of more than 80% of osteoclastic giant cells; 4) Radiological results: an improvement of more than 60% in the size or shape of the tumor in radiological images.

Secondary outcomes included: 1) pain: which referred to deteriorated or improved condition or enhanced physical activity of the patient. The pain was measured by any valid means or using visual analogue scale; 2) Hypocalcemia: defined as marked or unmarked serum calcium below 8 mg /dl; 3) Osteonecrosis of the jaw

(ONJ): bone necrosis in the oral cavity; and 4) Infection.

Quality assessment

The eligibility criteria for each article were assessed by two authors in accordance with Cochrane collaboration's risk of bias tool for studies included in the meta-analysis (13). Two researchers performed the evaluation of studies independently and the differences were resolved through discussion [Table 1].

All outcomes were analyzed with comprehensive Meta analysis software. The dichotomous results of single group including values and their ratios were computed at 95% confidence intervals. The means and standard deviations of demographic information were calculated and reported. Median was used in cases where no mean was reported.

Results

Out of a total of 925 evaluated studies only 1 cohort study and 9 case series were included in the meta-analysis and 11 case reports were also reported separately. The inter-reviewer agreement was 98.5%.

Characteristics of studies and subjects

The information of 10 studies included in the meta-analysis is given in Table 2. The study population consisted of 686 patients with an average age of 31.5±2.8 years out of whom 55% with primary GCTB and 45% with recurrence were enrolled in the study.

Outcomes

SRE: All studies that did not indicate the occurrence of SRE during or after the treatment of patients.

Overall survival: None of the studies had considered overall survival, and only mortality of patients had been reported. Therefore, one case of death was reported in RELEHI and another in CHAWLA, which was caused by respiratory failure and thus irrelevant to Denosumab

Table 2. Characteristics of included studies

Study	Study population	Duration of follow-up	Duration of Treatment	Outcome
Thomas, 2010(14)	37	13	13	Histopathologic results, side effects, local recurrence, radiology images
Daniel, 2012(15)	37	6.1	6.1	Histopathologic results, side effects, local recurrence
Chawla, 2013(9)	282	10.5 months	13 months	Radiology images, sideeffects, recurrence, histopathologic results
Martin, 2014(16)	20	27	6	Histopathologic results, side effects, local recurrence, radiology images
Ueda, 2015 (17)	17	3 months after treatment	12.25 months	Radiology images, sideeffects, recurrence, histopathologic results
Girolami, 2015 (18)	15	13 months	5.7 months	Histopathologic results, side effects, local recurrence
Rutkowshi, 2015(19)	222	After 6 months	153 months	Histopathologic results, side effects, local recurrence
Traub, 2016(20)	20	30	6	Radiology images, side effects, recurrence
Relehi, 2016(21)	27	18	6	Histopathologic results, side effects, local recurrence
Wojcik, 2016(22)	37	27	13	Side effects, local recurrence

histopathologic results

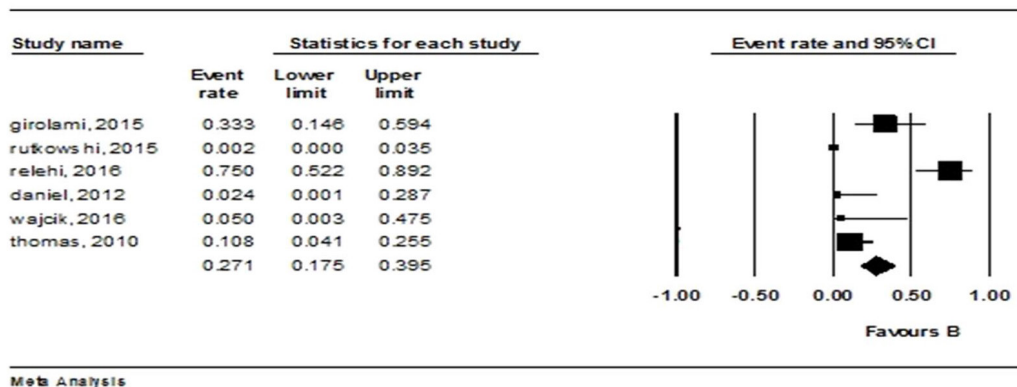


Figure 2. Summary of histopathologic results regarding the rate of denosumab from the baseline until the first follow up; pooled estimates adapted from a fixed- effect model.

treatment.

Histopathologic results: Post-treatment biopsy had been performed for histopathology in eight studies. The reports had been expressed qualitatively with patients lacking more than 80% of osteoclastic giant cells were regarded as receiving positive response from the treatment. Details are given in Figure 2.

Radiological results: Five studies reporting more than 60% improvement in size or shape of the tumor in radiological images including PET, CT scan, MRI or X-ray after treatments were studied and the results are shown in Figure 3.

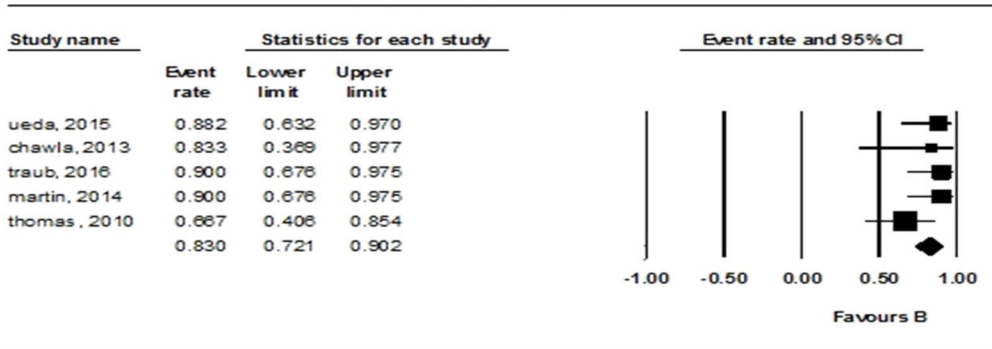
Pain: It was referred to the deteriorated or improved condition of the patient or enhanced physical activity. In papers under study, pain had been referred to as a

condition. In Figure 4, the severity of post-treatment pain has been reported, which was either caused by disease or persisted throughout the treatment.

Hypocalcemia: The papers under study had only reported the number of patients with or without hypocalcemia after treatment without giving the numerical value of hypocalcemia [Figure 5].

None of the studies had reported the symptoms of the ONJ. The only exception was the study of Chawalain in which 2 cases of ONJ and 7 cases of infection were reported. Given the large population of this study and the prolonged duration of treatment with Denosumab, it could be argued that these symptoms only appear in long-term treatment. Therefore, further studies are required to verify the results.

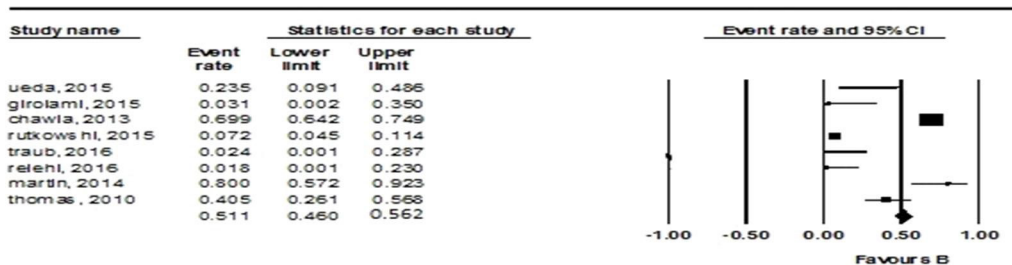
radiologic results



Meta Analysis

Figure 3. Forest plot: summary of radiologic results regarding the rate of denosumab from the baseline until the first follow up; pooled estimates are adapted from afixed- effect model.

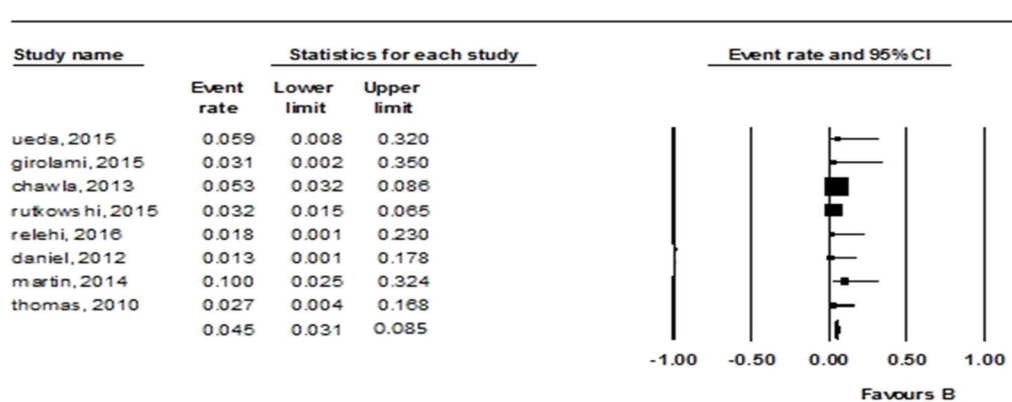
pain rate



Meta Analysis

Figure 4. Forest plot: summary of pain rate of denosumab from the baseline until the first follow up; pooled estimates are adapted from afixed- effect model.

hypocalcemia rate



Meta Analysis

Figure 5. Forest plot: summary of hypocalcemia rate of denosumab from the baseline until the first follow up; pooled estimates are adapted from afixed- effect model.

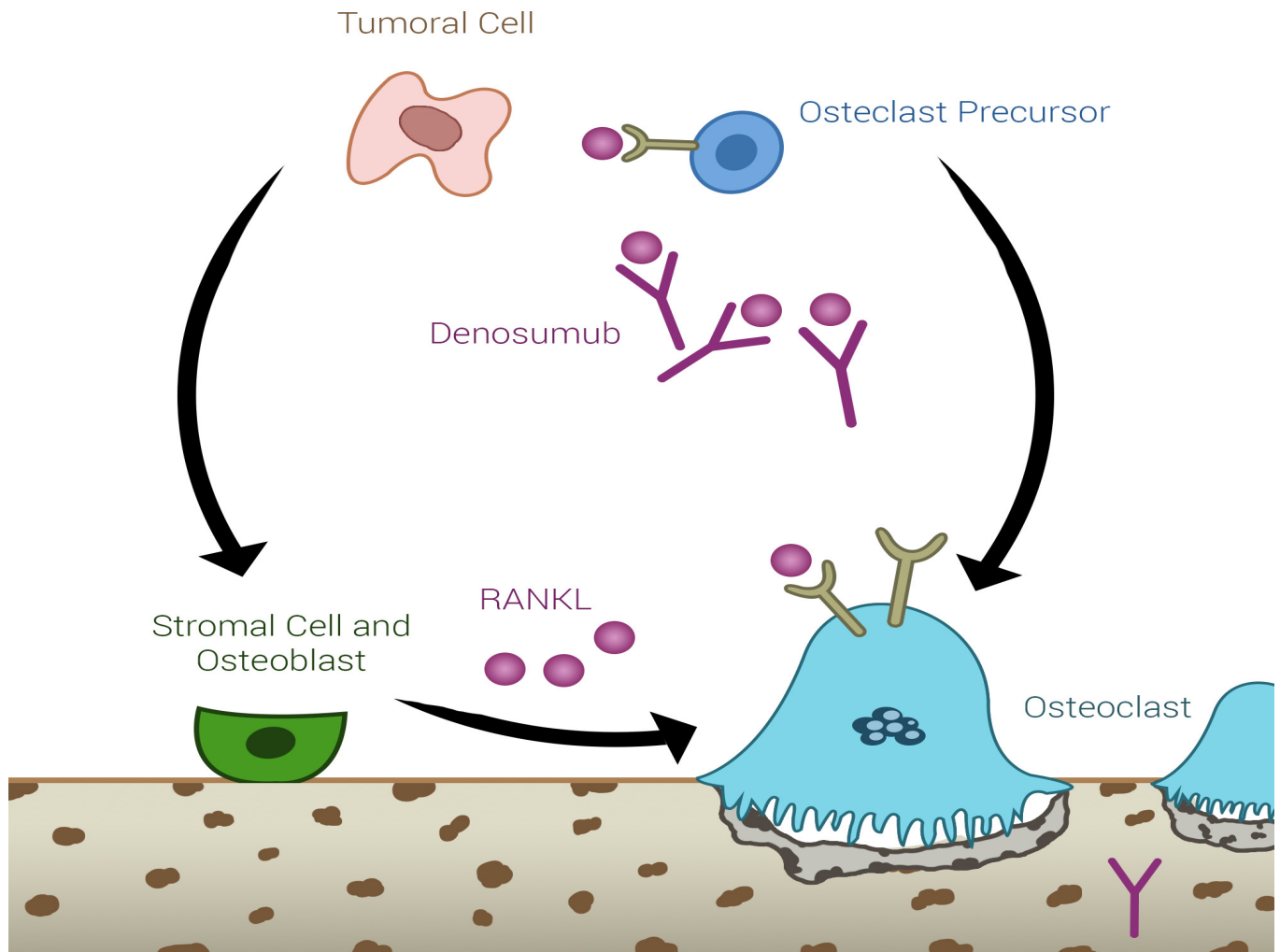


Figure 6. Denosumab in patients with cancer.

Recurrence: Only 2% of all subjects of the study had experienced recurrence.

Case reports

Nearly 11 case reports had mentioned the treatment of giant cell tumors or its recurrence with Denosumab. Hakozaiki in 2014 reported the neoadjuvant treatment of Denosumab in a 20-year old man with GCTB in femur. PET images revealed reduced uptake of tumor. Histologic results showed fibrosis of histiocytoma-like features, disappearance of bone mononuclear stromal cells, and multinuclear osteoclast-like giant cell (23). Vaishya in 2015 reported Denosumab therapy in three inoperable patients due to improper location or small size of the tumor. The results of follow-up radiology showed the positive response of the tumor to the treatment (24). Diagnosis in oncology group released

a report in 2013 about a 10-year-old girl with giant cell tumor in the knee and a nodule in the lungs who did not need to use pain killers and was able to walk after postoperative treatment with Denosumab for 4 months (25).

In 2015, Stadler reported the case of a 20-year-old woman with secondary recurrences of tumor leading to the removal of her upper knee. Although sarcoma was reported as the result of biopsy, the patient had no signs of recurrence or complications after two years of treatment with Denosumab after surgery (26).

In 2014, Akaike discussed the case of a 28-year-old man with third recurrences of tumor in the distal femur. In this case, Denosumab treatment had been prescribed before the surgery. The patient had not demonstrated any certain side effects during Denosumab treatment, the tumor had shrunk in size,

and the conditions were favorable for the surgery of patient (27).

In another study in 2014, Isabella treated two patients with neoadjuvant Denosumab and four other patients without Denosumab. The results of follow-up after six months revealed no side effects in both groups and reduced postoperative complications in patients treated with Denosumab (28). In 2016, Kajiwara reported the case of a 43-year old man who had lost all symptoms after two -month treatment with Denosumab so that no signs of tumor recurrence were detected in CT scan (29).

In 2016, Yamagishi reported the case of a 19-year-old boy with giant cell tumor of sacrum and a nodule in the lung. The nodule shrank eight months after treatment with Denosumab and the patient was operated to remove tumor in sacrum and nodule in lung. No sign of recurrence was observed in this case (30).

In another study, a 41 year-old male with giant cell tumor of ischium, who was inoperable due to the largeness of the tumor. Three months after treatment with Denosumab the patient was operated without any side effect (31).

In a study in 2014, a 22-year old woman with a lesion in the C2 vertebral body and odontoid process were treated with Denosumab every three weeks. After 16 months, radiologic images showed complete disappearance of osteolytic process (32).

In 2013, the case of a 27-year-old patient were reported, who was subject to radiotherapy after the first recurrence of the tumor. However, the tumor grew larger and therefore the patient was treated with Denosumab. The operation was carried out after three months and Denosumab treatment continued postoperatively without any symptoms of recurrence in follow-ups (33).

As these studies show, it seems that the use of Denosumab helps the treatment or smoothes the surgery. However, the exact duration of using this drug medicine is an issue that calls for further research.

Discussion

The results of this study showed that giant cell tumors are more likely to develop in the third decade of life, especially in women. Bone resorption follows the tumor activation via direct osteoclast activated with RANKL (this precursors being derived from monocytes/macrophage cell line residing in bone) (34).

Tumoral giant cells are activated osteoclasts through indirect effect on osteoblasts and stromal cells with presence of a stimulating factor (RANKL) increases the overall process of osteoclasts formation and activation, so increases bone resorption.

To differentiate at the level of osteoclasts, RANK receptors have to interact with RANKL. There is a theory that this interaction is inhibited in the presence of Denosumab (the monoclonal antibody that bond with RANKL) (34, 1). Moreover, we know that surgery is a typical treatment of GCTB with a recurrence rate of 15-45% (35, 36). This rate drops to 2-14% when an intralesional surgery is done by high speed burr and

allograft bone-cement (37, 1).

With regard to local recurrence of treatments such as repeated intralesional curettage or wide surgical resection, mutilating procedure should be avoided. It is posited that compared to intralesional surgery, massive removal of tumor is accompanied with lower risk of recurrence (5% vs. 25%), which intensifies the problems of reconstruction (1).

Many studies suggest that Denosumab is a suitable treatment alternative for GCTB, when function-sparing surgery is not an option or the tumor is placed in an improper location or the surgery is highly risky due to large size of the tumor (35).

The medical treatment of GCTB is experimental and based on broad theories regarding the cause of the disease. The present study showed a recurrence rate of 2% in the case of using Denosumab. However, other studies have reported a local recurrence rate of 2.4% in the case of bisphosphonate therapy due to the effect of antibodies (38).

Consistent with other studies the present study showed that the use of Denosumab over a six-month period before standard surgery can improve the treatment of certain cases of GCTB and its recurrence. The results of this study suggest that the use of Denosumab can slightly reduce surgical complications and it can be helpful in complex cases or in patients resistant to pain killers (39). The long-term use of Denosumab can increase concerns over its toxicity.

Recent studies regarding Denosumab suggest that it reduces the size of tumor, and therefore makes the surgery easier with lower morbidity. However, some studies have reported several complications associated with this drug.

Denosumab makes surgery easier because it reduces the stage of the tumor and improves treatment in cases when there are recurrence or tumor residuals after surgery. However, it has been shown that the use of Denosumab does not prevent relapse in patients who have initially been treated with surgery.

Complications such as arthralgia, headache, nausea, fatigue, pain, anemia, hypercalcemia and osteonecrosis in jaw have been reported with Denosumab (17, 7, 34). The present study also showed similar complications; however, Denosumab can be used as a helpful alternative along with surgery or in cases where surgery is not an option or it would be complex and difficult.

In general, there are several questions yet to be answered about the use of Denosumab in the treatment of GCTB. It is clear that this drug is useful in neoadjuvant settings, but, its optimal treatment duration is still unknown. The authors of this study believe that its benefits can be variable in any situation, depending on the location, the presence of fracture and surgical skills, the tumor aggressiveness and the size of tumor. As a result, clinical judgment should be determining the course of treatment for this disease, and follow-up is especially important to determine the long-term effects of this drug.

Thomas and Chawla's reported four patients

developing new sarcoma (9, 14). There have been reports of atypical femoral fracture in osteoporotic patients with metastatic bone disease treated by Denosumab. Despite the complications of Denosumab, it can be used in cases where recurrence is possible or complete resection is not an option. Therefore, clinicians should be aware of the possible clinical problems (40).

Considering the level of evidence in previous studies, conducting randomized clinical trials is necessary to make more accurate decisions regarding the effectiveness of Denosumab.

This work was not supported by any funds.

The authors report no conflict of interest concerning the materials or methods used in this study or the findings specified in this paper.

Acknowledgements

We sincerely acknowledge Dr. Maryam Erfani for the

illustrations in the manuscript.

Khodamorad Jamshidi MD

Sami Sam Hajialiloo MD

Masoud Mirkazemi MD

Bone and Joint Reconstruction Research Center, Shafa Orthopedic Hospital, Iran University of Medical Sciences, Tehran, Iran

Mohamad Gharehdaghi MD

Orthopedic Research Center, Mashhad University of Medical Sciences, Mashhad, Iran

Kamran Ghaffarzadehgan MD

Azra IZanloo Msc

Razavi Cancer Research Center, Razavi Hospital, Imam Reza International University, Mashhad, Iran

References

- Klenke FM, Wenger DE, Inwards CY, Rose PS, Sim FH. Giant cell tumor of bone: risk factors for recurrence. *Clin Orthop Relat Res.* 2011; 469(2):591-9.
- Sobti A, Agrawal P, Agarwala S, Agarwal M. Giant cell tumor of bone-an overview. *Arch Bone Jt Surg.* 2016; 4(1):2-9.
- Unni K. Giant cell tumor/malignancy in giant cell tumor of bone. *Dahlin's bone tumors: general aspects and data on 11,087 cases.* 5th ed. Philadelphia, PA: Lippincott-Raven; 1996. P. 263-89.
- Bertoni F, Bacchini P, Staals EL. Malignancy in giant cell tumor of bone. *Cancer.* 2003; 97(10):2520-9.
- Campanacci M, Baldini N, Boriani S, Sudanese A. Giant-cell tumor of bone. *J Bone Joint Surg Am.* 1987; 69(1):106-14.
- Li J, Zhu Y, Wei Y. Fibrosarcoma development 15 years after curettage and bone grafting of giant cell tumor of bone. *Orthopedics.* 2014; 37(5):e512-6.
- Rock MG, Sim FH, Unni KK, Wittrak GA, Frassica FJ, Schray MF, et al. Secondary malignant giant-cell tumor of bone. Clinicopathological assessment of nineteen patients. *J Bone Joint Surg Am.* 1986; 68(7):1073-9.
- Briët JP, Becker SJ, Oosterhoff TC, Ring D. Giant cell tumor of tendon sheath. *Arch Bone Jt Surg.* 2015; 3(1):19-21.
- Chawla S, Henshaw R, Seeger L, Choy E, Blay JY, Ferrari S, et al. Safety and efficacy of Denosumab for adults and skeletally mature adolescents with giant cell tumour of bone: interim analysis of an open-label, parallel-group, phase 2 study. *Lancet Oncol.* 2013; 14(9):901-8.
- Thomas DM. RANKL, Denosumab, and giant cell tumor of bone. *Curr Opin Oncol.* 2012; 24(4):397-403.
- Xu SF, Adams B, Yu XC, Xu M. Denosumab and giant cell tumour of bone: a review and future management considerations. *Curr Oncol.* 2013; 20(5):e442-7.
- Mak IW, Evaniew N, Popovic S, Tozer R, Ghert M. A translational study of the neoplastic cells of giant cell tumor of bone following neoadjuvant Denosumab. *J Bone Joint Surg Am.* 2014; 96(15):e127.
- Higgins J, Green S. *Cochrane handbook for systematic reviews of interventions.* London: The Cochrane Collaboration; 2011.
- Thomas D, Henshaw R, Skubitz K, Chawla S, Staddon K, Blay JY, et al. Denosumab in patients with giant-cell tumour of bone: an open-label, phase 2 study. *Lancet Oncol.* 2010; 11(3):275-80.
- Branstetter DG, Nelson SD, Manivel JC, Blay JY, Chawla S, Thomas DM, et al. Denosumab induces tumor reduction and bone formation in patients with giant-cell tumor of bone. *Clin Cancer Res.* 2012; 18(16):4415-24.
- Martin-Broto J, Cleeland CS, Glare PA, Engellau J, Skubitz KM, et al. Effects of denosumab on pain and analgesic use in giant cell tumor of bone: interim results from a phase II study. *Acta Oncol.* 2014; 53(9):1173-9.
- Ueda T, Morioka H, Nishida Y, Kakunaga S, Tsuchiya H, Matsumoto Y, et al. Objective tumor response to Denosumab in patients with giant cell tumor of bone: a multicenter phase II trial. *Ann Oncol.* 2015; 26(10):2149-54.
- Girolami I, Mancini I, Simoni A, Baldi GG, Simi L, Campanacci D, et al. Denosumab treated giant cell tumour of bone: a morphological,

- immunohistochemical and molecular analysis of a series. *J Clin Pathol.* 2016; 69(3):240-7.
19. Rutkowski P, Ferrari S, Grimer RJ, Stalley PD, Dijkstra SP, Pienkowski A, et al. Surgical downstaging in an open-label phase II trial of denosumab in patients with giant cell tumor of bone. *Ann Surg Oncol.* 2015; 22(9):2860-8.
 20. Traub F, Singh J, Dickson BC, Leung S, Mohankumar R, Blackstein ME, et al. Efficacy of denosumab in joint preservation for patients with giant cell tumour of the bone. *Eur J Cancer.* 2016; 59:1-12.
 21. Rekhi B, Verma V, Gulia A, Nirmala A, Desai S, Juvekar SL, et al. Clinicopathological features of a series of 27 cases of post-denosumab treated giant cell tumors of bones: a single institutional experience at a tertiary cancer referral Centre, India. *Pathol Oncol Res.* 2017; 23(1):157-64.
 22. Wojcik J, Rosenberg AE, Bredella MA, Choy E, Hornicek FJ, Hornicek FJ, et al. Denosumab-treated giant cell tumor of bone exhibits morphologic overlap with malignant giant cell tumor of bone. *Am J Surg Pathol.* 2016; 40(1):72-80.
 23. Michiyuki H, Takahiro T, Hitoshi Y, Osamu H, Kazuhiro T, Watanabe K, et al. Radiological and pathological characteristics of giant cell tumor of bone treated with Denosumab. *Diagn Pathol.* 2014; 9(1):111.
 24. Vaishya R, Agarwal AK, Vijay V. Salvage treatment' of aggressive giant cell tumor of bones with denosumab. *Cureus.* 2015; 7(7):e291.
 25. Karras NA, Polgreen LE, Ogilvie C, Manivel JC, Skubitz KM, Lipsitz E. Denosumab treatment of metastatic giant-cell tumor of bone in a 10-year-old girl. *J Clin Oncol.* 2013; 31(12):e200-2.
 26. Stadler N, Fingernagel T, Hofstaetter SG, Trieb K. A recurrent giant cell tumor of bone treated with Denosumab. *Clin Pract.* 2015; 5(1):697.
 27. Keisuke A, Yoshiyuki S, Tatsuya T, Kazuo K, Tsuyoshi S. Hell-like mineralized recurrent lesion in the popliteal region after treatment of giant cell tumor of the bone with Denosumab. *Skeletal Radiol.* 2014; 43(12):1767-72.
 28. Mak IW, Evaniew N, Popovic S, Tozer R, Ghert M. A translational study of the neoplastic cells of giant cell tumor of bone following neoadjuvant denosumab. *J Bone Joint Surg Am.* 2014; 96(15):e127.
 29. Kajiwara D, Kamoda H, Yonemoto T, Iwata S, Ishii T, Tsukanishi T, et al. Denosumab for treatment of a recurrent cervical giant-cell tumor. *Asian Spine J.* 2016; 10(3):553-7.
 30. Yamagishi T, Kawashima H, Ogose A, Sasaki T, Hotta T, Inagawa S, et al. Disappearance of giant cells and presence of newly formed bone in the pulmonary metastasis of a sacral giant-cell tumor following Denosumab treatment: a case report. *Oncol Lett.* 2016; 11(1):243-6.
 31. Watanabe N, Matsumoto S, Shimoji T, Ae K, Tanizawa T, Gokita T, et al. Watanabe et al. Early evaluation of the therapeutic effect of Denosumab on tartrate-resistant acid phosphatase 5b expression in a giant cell tumor of bone: a case report. *BMC Res Notes.* 2014; 7(1):608.
 32. Mattei TA, Ramos E, Rehman AA, Shaw A, Patel SR, Mendel E. Sustained long-term complete regression of a giant cell tumor of the spine after treatment with denosumab. *Spine J.* 2014; 14(7):e15-21.
 33. Amit A, Larsen BT, Buadu LD, Dunn J, Crawford R, Jonathan D, et al. Denosumab chemotherapy for recurrent giant-cell tumor of bone: a case report of neoadjuvant use enabling complete surgical resection. *Case Rep Oncol Med.* 2013; 2013(4):496351.
 34. Boyce BF, Xing L. Biology of RANK, RANKL, and osteoprotegerin. *Arthritis Res Ther.* 2007; 9(Suppl 1):S1.
 35. Yasko AW. Interferon therapy for vascular tumors of bone. *Curr Opin Orthop.* 2001; 12(6):514-8.
 36. Miller G, Bettelli G, Fabbri N, Capanna R. Curettage of giant cell tumor of bone. Introduction—material and methods. *Chir Organi Mov.* 1990; 75(Suppl 1):203.
 37. Chakarun CJ, Forrester DM, Gottsegen CJ, Patel DB, White EA, Matcuk GR Jr. Giant cell tumor of bone: review, mimics, and new developments in treatment. *Radiographics.* 2013; 33(1):197-211.
 38. Tse LF, Wong KC, Kumta SM, Huang L, Chow TC, Griffith JF. Bisphosphonates reduce local recurrence in extremity giant cell tumor of bone: a case-control study. *Bone.* 2008; 42(1):68-73.
 39. Huang L, Xu J, Wood DJ, Zheng MH. Gene expression of osteoprotegerin ligand, osteoprotegerin, and receptor activator of NF-kappaB in giant cell tumour of bone: possible involvement in tumour cell-induced osteoclast-like cell formation. *Am J Pathol.* 2000; 156(3):761-7.
 40. Yang SP, Kim TW, Boland PJ, Farooki A. Retrospective review of atypical femoral fracture in metastatic bone disease patients receiving Denosumab therapy. *Oncologist.* 2017; 22(4):438-44.