

## CASE REPORT

# Knee and Hip Joint Replacement Surgery in a Patient with Ochronotic Arthropathy: Surgical Tips

Hamed Mazoochy, MD; Mohammad Razi, MD

*Research performed at Shahid Modarress Hospital, Saveh, Markazi, Iran**Received: 17 February 2017**Accepted: 16 July 2018***Abstract**

Ochronosis or black joints disorder is a rare autosomal recessive disorder caused by deficiency of homogentisic acid oxidase. Orthopaedic manifestations are common and mostly involve spine and large joints such as knee and hip. Arthropathy is progressive and will eventually leads to arthroplasty. Not being familiar with this disorder might lead to devastating complications. We present a 57 year-old woman with Ochronosis who successfully underwent cemented cruciated substituted knee replacement and cementless hip replacement. Proper orthopaedic and anesthetic pre-operative preparation, soft tissue specially patella tendon management throughout operation and meticulous bleeding control during surgery are crucial. The results of the knee and the hip replacement surgery in this patient are satisfactory, after 24 months and 18 months follow-up, respectively. If Orthopaedic surgeons and anesthesiologists are well prepared, the outcome of joint replacement in Ochronosis patients will be as satisfactory as patients with primary osteoarthritis.

**Level of evidence:** V**Keywords:** Hip replacement, Knee replacement, Ochronosis**Introduction**

Ochronosis is an autosomal recessive disorder caused by deficiency of homogentisic acid oxidase. Deposition of oxidized homogentisic acid within hyaline cartilage causes black discoloration of joints, thus, it is known as black joints disorder. Orthopaedic manifestations are common and mostly involve spine and large joints. Other systems, such as cardiovascular, respiratory, genitourinary and ocular systems, can be involved as well. Arthropathy is progressive and will eventually leads to arthroplasty (1).

Sometimes this disorder is diagnosed for the first time due to orthopaedic manifestations, moreover, it might even surprise you during operation, when you face a black joint in a patient never diagnosed as such before (1, 2).

This disorder is rare and just a small number of orthopaedic surgeons will ever have an encounter with it. However, not being familiar with this disorder might lead to two probable circumstances. Either the surgeon finds the black appearance of soft tissue and joint so strange that they just take a biopsy and decide to postpone definitive surgery after histological diagnosis,

or the surgeon continues the operation without basic knowledge about precautions in these patients and ends up with devastating intraoperative complications. Although the first scenario seems to be a more rational decision, any surgical procedure in these patients has a higher risk of complications than normal and a second operation will have a higher risk especially in terms of infection and anesthesia complications. We present a case of Ochronosis who successfully underwent total hip and knee joint replacement. Moreover, we will discuss surgical tips of arthroplasty in these patients. Written informed consent was obtained from the patient for publication of this case report and accompanying images.

**Case presentation**

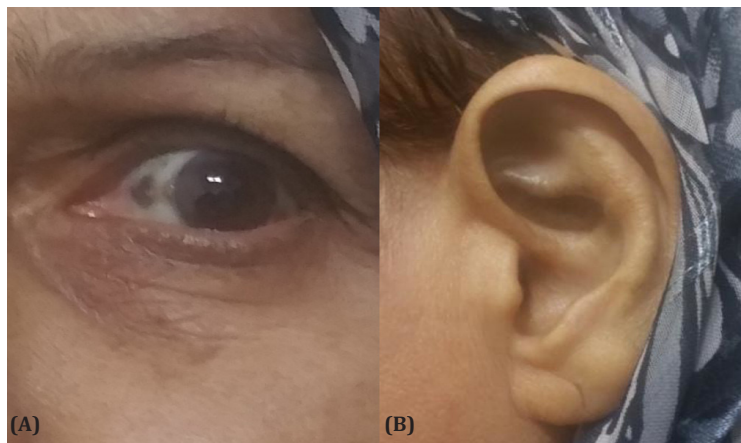
A 57 year-old woman presented with chronic low back pain and chronic bilateral hip and knee pain. It was more severe in the right knee, which was not responding to medical treatment anymore. In physical examination the patient had a dark bluish sclera and pinnae characteristic of Ochronosis [Figure 1A; 1B].

**Corresponding Author:** Hamed Mazoochy, Department of Trauma and Orthopedics, Shahid Modarress Hospital, Saveh, Markazi, Iran

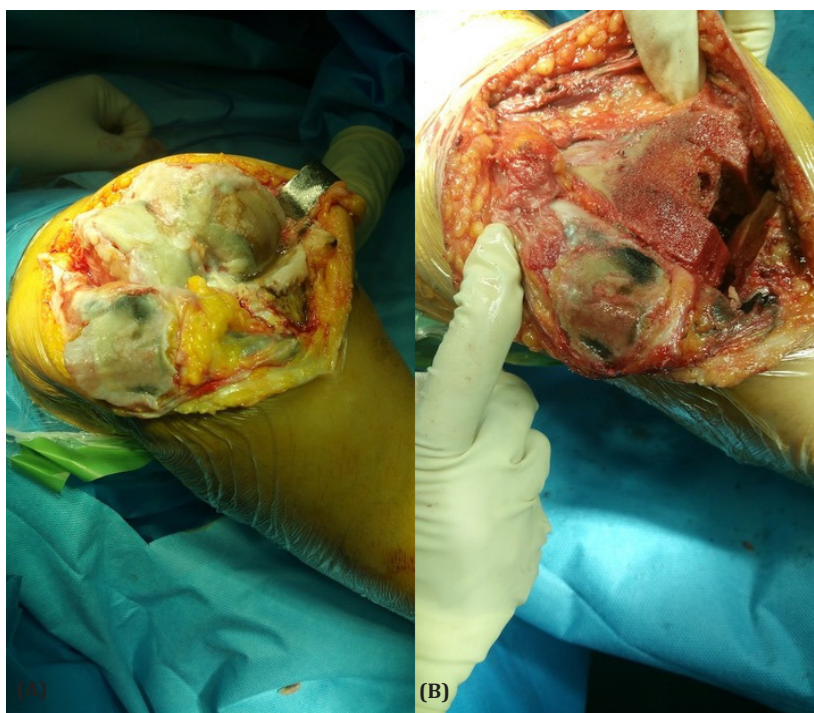
Email: hmazoochy@hotmail.com



THE ONLINE VERSION OF THIS ARTICLE  
ABJS.MUMS.AC.IR



**Figure 1. Dark bluish pigmentation in physical examination characteristic of Ochronosis in: A) sclera. B) pinnae.**

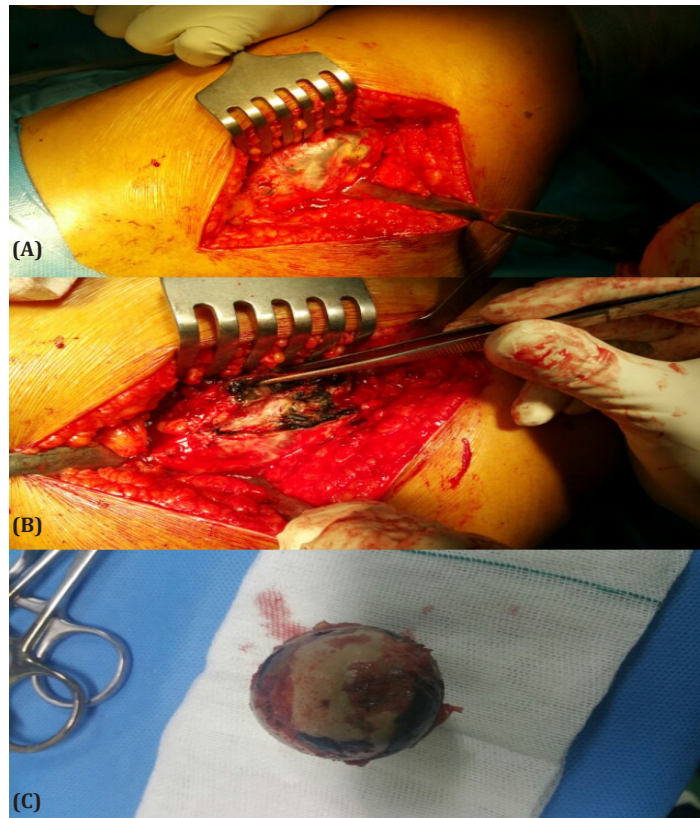


**Figure 2. Black discoloration of cartilage and soft tissue in knee joint and progression throughout operation. A) After arthrotomy. B) Forty minutes after arthrotomy. (During operation patella eversion in flexion should be avoided. This photo is taken in semi extension positions and just to show ochronotic change).**

Urine analysis confirmed the diagnosis of Ochronosis. Radiologic evaluation showed degenerative changes in spine, bilateral hip joints and bilateral knee joints, which were more severe in the right knee.

Patient was scheduled for cemented right total knee arthroplasty with the diagnosis of Ochronotic arthropathy. The procedure was performed under general

anesthesia and with tourniquet control. After standard medial parapatellar capsulotomy, we observed joint degeneration and black colored pigmentation in synovial tissue and articular cartilage. Patella tendon was severely affected and fragile. Black discoloration in cartilage and soft tissue was progressing throughout operation and patella tendon was getting more fragile [Figure 2A; 2B].



**Figure 3.** Black discoloration of cartilage and soft tissue in hip joint. A) Fascia lata. B) Vastus Lateralis. C) Femoral head cartilage.

Patella was subluxated laterally with minimal tension on patella tendon throughout operation. A cemented cruciated sacrificing knee replacement without patella arthroplasty performed without any intra-operative complication. Post-operative rehabilitation was similar to regular patients. The patient was satisfied with the right knee arthroplasty. After 6 months, she referred due to aggravated right hip pain. The right hip X-Ray showed progression in Ochronotic arthropathy. The patient was scheduled for right total hip arthroplasty. The operation was performed under general anesthesia and lateral approach was selected in lateral position. On exploration, there was black pigmentation in soft tissue around the hip joint and hip cartilage similar to the knee joint [Figure 3A; 3B; 3C]. However, despite black discoloration, the quality of soft tissue was better than the knee and it was not fragile. Degenerative changes were seen in femoral head and acetabular cartilages. Acetabulum and femoral stem were press fit and the patient underwent cementless total hip replacement without any intra-operative complication. Post-operative rehabilitation was similar to regular patients. The results of the knee and the hip replacement surgery in this patient are satisfactory, after 24 months and 18 months follow-up, respectively.

### Discussion

Several studies have demonstrated that knee and hip joint replacement surgery in known cases of Ochronosis has excellent short-term and long-term outcomes and is comparable with patients with primary osteoarthritis (3, 4).

Intra-operative diagnosis of Ochronosis is not uncommon. Musculoskeletal symptoms are among the main symptoms in these patients. On the other hand, the extra skeletal features of Ochronosis are subtle in many patients, which might lead to missing the early diagnosis. There are several reports of the diagnosis being made during operation, subsequent to observing black discoloration of synovium and cartilaginous surfaces. If surgeons were familiar to intraoperative management of Ochronosis arthropathy, the outcome of joint replacement was excellent (1, 2).

There are some reports of the surgeons having changed the planned surgery and postponing the definitive procedure until receiving the results of histopathology, however, their results were satisfactory as well (5, 6).

Results of cementless hip arthroplasty in Ochronosis patients are comparable to patients with primary osteoarthritis. The risk of intraoperative or postoperative orthopaedic complications in hip arthroplasty is

not reported higher than primary osteoarthritis (7). Moreover, results of cemented cruciate substituted knee arthroplasty in Ochronosis arthropathy are similar to patients with primary osteoarthritis (8).

Spontaneous patella and achilles tendons rupture in patients with Ochronosis are reported (9, 10). Patella tendon rupture is a major complication in knee arthroplasty. Sahoo et al reported a case of Ochronosis that patella tendon was ruptured during knee arthroplasty. They emphasized that preoperative diagnosis is essential so that a greater care would be taken in handling the tendon during TKR. Also, they suggested a preoperative ultrasonography of the patellar and achilles tendons to anticipate such complications in advance (11). Our patient had significant patella tendon involvement, too. Knee arthroplasty must be performed very carefully in order not to damage the patella tendon throughout operation. Patella tendon may be very fragile and patella eversion or other situations, which put patella tendon under excessive tension, should be avoided.

Synovial hypertrophy is another knee manifestation of Ochronotic arthropathy. Ulucay et al reported a case of Ochronosis with significant post-operative bleeding and blood loss after knee arthroplasty. They suggested intraoperative bleeding control after synovectomy (8).

Patients with Ochronosis may have cardiac problems, such as coronary calcification, valvular stenosis and conduction block. Moreover, these patients might have respiratory problems, such as airways involvement, dyspnea and diminished vital capacity (12-14). Pandey et al evaluated anesthetic concerns in Ochronosis. They

emphasized that since the Ochronosis is a systemic disorder, these patients need a pre-operative diagnosis and a thorough preoperative evaluation. Although, spinal anesthesia is a good option, Ochronotic changes in spine might challenge the regional anesthesia. Pandey et al concluded that general anesthesia is safe with proper preoperative preparation (15).

In conclusion, many of these patients might be undiagnosed at time of orthopaedic referral. Therefore, Ochronosis should be suspected in patients with degenerative arthritis involving multiple joints specially knee and hip joints and spinal column. Clinical clues including black pigmentations in sclera and pinnae can be helpful in diagnosis. Ochronosis presence will not change the kind of prosthesis. If Orthopaedic surgeons and anesthesiologists are well prepared, the outcome of joint replacement in Ochronosis patients will be as satisfactory as patients with primary osteoarthritis.

Hamed Mazoochy MD

Department of Trauma and Orthopaedic, Shahid Modarress Hospital, Saveh, Markazi, Iran

Mohammad Razi MD

Department of Orthopaedic Surgery and Department of Sports Medicine, Iran University of Medical sciences, Tehran, Iran

## References

1. Harun M, Hayrettin Y, Serhat M, Cuneyt M, Fırat F, Ufuk O. A rare cause of arthropathy: an ochronotic patient with black joints. *Int J Surg Case Rep.* 2014; 5(8):554-7.
2. Ozmanevra R, Güran O, Karatosun V, Günel I. Total knee arthroplasty in ochronosis: a case report and critical review of the literature. *Eklemler Hastalıkları Cerrahisi.* 2013; 24(3):169-72.
3. Karaoglu S, Karaaslan F, Mermerkaya MU. Long-term result of arthroplasty in the treatment of a case of ochronotic arthropathy. *Acta Orthop Traumatol Turc.* 2016; 50(5):584-6.
4. Acar MA, Erkocak OF, Aydin BK, Altan E, Senaran H, Elmadag NM. Patients with black hip and black knee due to ochronotic arthropathy: case report and review of literature. *Oman Med J.* 2013; 28(6):448-9.
5. Siavashi B, Zehtab MJ, Pendar E. Ochronosis of hip joint; a case report. *Cases J.* 2009; 16(2):9337.
6. Mohapatra S, Biswas T, Das S, Saxena A. Ochronosis of the hip joint: differential diagnosis of inflammatory arthropathy with lytic lesion. *Indian J Clin Biochem.* 2014; 29(1):112-3.
7. Cebesoy O, Isik M, Subasi M, Kaya A, Bilgin F, Kaya O. Total hip replacement for an ochronotic patient: a technical trick. *Am J Case Rep.* 2014; 15(1):27-30.
8. Ulucay C, Ozler T, Altintas F, Inan M, Onur A. Arthroplasty in ochronosis "tips and pearls in surgery": case series. *J Arthritis.* 2013; 3(116):2.
9. Manoj Kumar RV, Rajasekaran S. Spontaneous tendon ruptures in alkaptonuria. *J Bone Joint Surg Br.* 2003; 85(6):883-6.
10. Alajoulin OA, Alsbou MS, Ja'afreh SO, Kalbouneh HM. Spontaneous Achilles tendon rupture in alkaptonuria. *Saudi Med J.* 2015; 36(12):1486-9.
11. Sahoo MM, Mahapatra SK, Sethi GC, Dash SK. Patellar ligament rupture during total knee arthroplasty in an ochronotic patient. *Acta Orthop Traumatol Turc.* 2014; 48(3):367-70.
12. Fisher AA, Davis MW. Alkaptonuric ochronosis with aortic valve and joint replacements and femoral fracture: a case report and literature review. *Clin Med Res.* 2004; 2(4):209-15.

THE ARCHIVES OF BONE AND JOINT SURGERY. ABJS.MUMS.AC.IR  
VOLUME 6. NUMBER 6. NOVEMBER 2018

KNEE AND HIP JOINT REPLACEMENT IN OCHRONOTIC ARTHROPATHY

13. Wauthy P, Seghers V, Mathonet P, Deuvaert FE. Cardiac ochronosis: not so benign. *Eur J Cardiothorac Surg.* 2009; 35(4):732-3.
14. Ogata J, Tamura K, Miyanishi K, Minami K, Haranishi Y. Anesthesia in a patient with alkaptonuric ochronosis

- for total hip arthroplasty. *Masui.* 2008; 57(4):439-42.
15. Pandey R, Kumar A, Garg R, Khanna P, Darlong V. Perioperative management of patient with alkaptonuria and associated multiple comorbidities. *J Anaesthesiol Clin Pharmacol.* 2011; 27(2):259-61.