

RESEARCH ARTICLE

Long-term Outcomes after Primary Radial Head Resection Arthroplasty vs. Acute Radial Head Resection vs. Secondary Prosthetic Removal in Comminuted Radial Head Fractures

Martin Kiechle, MD; Andreas Thannheimer, MD; Sven Hungerer, MD; Jan Friederichs, MD; Volker Bühren, MD; Christian von Rüden, MD

Research performed at BG Trauma Center Murnau, Murnau, Germany

Received: 22 July 2018

Accepted: 30 September 2018

Abstract

Background: Aim of this study was to compare the clinical and radiological long-term outcomes following operative treatment of comminuted radial head fractures using 1) primary radial head resection arthroplasty, 2) acute radial head resection, or 3) necessary secondary prosthetic removal. Additionally, we evaluated complex radial head fractures combined with elbow dislocation and verified the hypothesis of whether primary radial head resection arthroplasty could contribute to ligament healing.

Methods: In a comparative retrospective cohort study between 2004 and 2014, 87 (33 female, 54 male) patients with comminuted radial head fractures with a median age of 45 (range 18-77) years were included and followed-up clinically and radiologically. Functional results were evaluated according to MEPS, DASH, Broberg and Morrey, and VAS scores.

Results: After a median range of 46 months postoperatively, 48 patients (group 1) obtained an acute radial head resection arthroplasty (MEPS: 70 points, Broberg and Morrey: 63 points, DASH: 34 points, VAS: 3.3 points). Twenty patients (group 2) were treated by radial head resection (MEPS: 63 points, Broberg and Morrey: 50 points, DASH: 49 points, VAS 4.2 points) and 19 patients (group 3) needed secondary prosthesis removal (MEPS: 73 points, Broberg and Morrey: 66 points, DASH: 38 points, VAS: 2.8 points). The overall outcome demonstrated a trend towards better results and the Kellgren-Lawrence grade of postoperative osteoarthritis was significantly better in groups 1 and 3 compared to group 2 ($P=0.02$).

Conclusion: Clinical and radiological long-term results of this study demonstrate a trend towards a better outcome after acute radial head resection arthroplasty compared to primary radial head resection, especially in complex fractures associated with elbow dislocation. Furthermore, our results encourage the use of primary radial head replacement in cases of comminuted non-reconstructable radial head fractures.

Level of evidence: III

Keywords: Broberg and Morrey; DASH, Outcome, Radial head fracture, Radial head resection arthroplasty

Introduction

The radial head is a major stabilizer of the elbow joint, especially for valgus stability, posterolateral and axial displacement of the radius and varus

loading (1). Radial head fractures account for about 5% of all fractures in adults, approximately 15% of elbow trauma, and about one third of all elbow fractures.

Corresponding Author: Christian von Rüden, Department of Trauma Surgery, BG Trauma Center Murnau, Germany
Email: christian.vonrueden@bgu-murnau.de



THE ONLINE VERSION OF THIS ARTICLE
ABJS.MUMS.AC.IR

Comminuted fractures of the radial head mainly occur as part of a complex injury configuration, and they have several mobile fragments without any soft tissue envelope. Commonly, this fracture pattern is associated with osseous and ligamentous injuries of the elbow or forearm (2). The primary aim of operative treatment is to avoid subluxation or dislocation of the elbow joint by restoration of the radio-humeral connection crucial for joint alignment and stability (3, 4). When elbow or forearm stability is secured, partial or complete radial head resection is an alternative treatment option (5, 6). In most cases when the elbow is unstable, different options include open reduction and internal fixation (ORIF) or acute prosthetic joint replacement (7-10).

In unstable comminuted fractures, superior results for acute prosthetic joint replacement over ORIF were described in literature (11, 12). Some authors described increased rates of early failure and nonunion for ORIF (7, 13, 14). A large number of replacement options are available including comparable mid- to long-term results (15-17). Nevertheless, the frequency of further surgery for hardware revision needed following this procedure remains incompletely observed (2, 18).

The aim of this study was to compare the clinical and radiological long-term results following surgical treatment of comminuted radial head fractures using 1) primary radial head resection arthroplasty, 2) acute radial head resection, or 3) necessary secondary removal of a primary radial head resection arthroplasty. In addition, we evaluated complex radial head fractures combined with elbow dislocation and proved the hypothesis of whether primary radial head resection arthroplasty could contribute to ligament healing.

Materials and Methods

Cohort groups

In a retrospective cohort study between 04/2004 and 06/2014, 87 patients with surgically treated comminuted radial head fractures (Mason type III and IV) were identified in a single Level I Trauma Center. Patients were excluded if there was inadequate fracture configuration, management, or follow-up data, or if patients were younger than 18 years. Patients with skeletal immaturity or congenital forms of elbow instability as well as patients unable to give a written informed consent for the study and patients with an increased risk for elective operative treatment according to the American Society of Anesthesiologists (ASA) grade > 3 were excluded (18). The primary outcome measure was long-term functional and radiological assessment, with the minimum time from surgery of 24 months. Initial radiographs were reviewed where available to confirm fracture classification and presence of subluxation or dislocation of the elbow. All fractures were assessed using a computed-tomography scan of the elbow and were subsequently classified according to the modified Mason fracture classification system (19). Associated injuries were defined as those found in CT scans or at the time of surgery requiring repair.

Surgical procedure

In the eleven-year-period, several surgeons were

involved in the treatment of patients and indications for surgery therefore varied. Nevertheless, general indications for operative treatment were a confirmed mechanical block to forearm rotation, as well as severe displacement or comminution of the fracture associated with instability of the elbow (7). Open reduction and internal fixation was performed when the treating surgeon felt the fracture could be reconstructed. Acute radial head resection without primary replacement was indicated in cases where the radial head was removed and where elbow stability was sufficient.

Follow-up

Follow-up studies were performed at regular intervals including one week, six weeks, three and six months as well as at the most recent office visit at the Department of Orthopedic Trauma. Follow-up assessment included thorough physical examination, functional evaluation, and diagnostic radiological studies. The influence of the treatment outcome on patients' mental and physical health status was assessed using the Disabilities of the Arm, Shoulder and Hand Outcome Measure (DASH), the Mayo Elbow Performance Score (MEPS), the Broberg and Morrey Score, and the Visual Analog Scale (VAS) (21-23). Severity of posttraumatic osteoarthritis was assessed according to the Kellgren-Lawrence grading scale (24). Outcome measures are presented as median values (and quartiles).

Statistical analysis

Statistical analysis was performed using IBM SPSS® Statistics for Windows 19.0 (IBM Corp., Armonk, NY, U.S.A.). Significance between groups was statistically assessed based on Mann-Whitney U test. A result was considered to be statistically significant with *P*-value <0.05.

Results

Eighty-seven patients (33 female, 54 male) with a median age of 45 years (range 18-77 years) were included in the study. After a median range of 46 months patients were followed-up clinically and radiologically. According to the modified Mason fracture classification system [19] there were 31 Mason III and 56 Mason IV fractures, with 9 out of those being a terrible triad injury. The median time to surgery after injury was 2 days (range 0-7 days).

Forty-eight out of 87 patients (55%) obtained a primary radial head resection arthroplasty (MoPyC® Modular Pyrocarbon Radial Head Prosthesis, Tornier, Montbonnot Saint Martin, France) (group 1). Five out of those were cemented prostheses. Twenty patients (23%) were treated by acute radial head resection (group 2), and 19 patients (22%) needed a secondary removal of a primary inserted radial head resection arthroplasty [Figure 1, group 3]. In three patients, the removed implants were cemented. Indications for secondary removal of a primary inserted radial head resection arthroplasty were as follows: Subluxation of prosthesis in 5 patients, persistent pain in 5 patients, loss of function in 4 patients, significant cartilage damage in

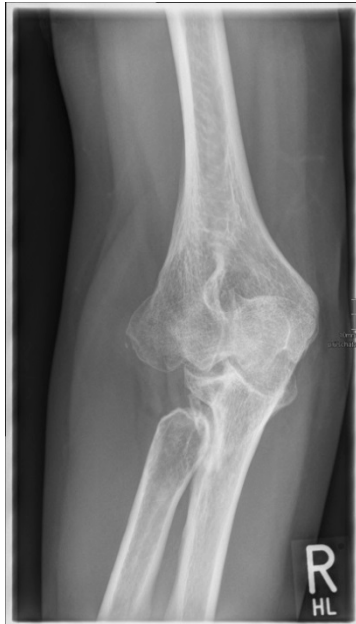

Figure 1. Situation after necessary secondary removal of a primary inserted radial head resection arthroplasty in a 32-year-old female patient.

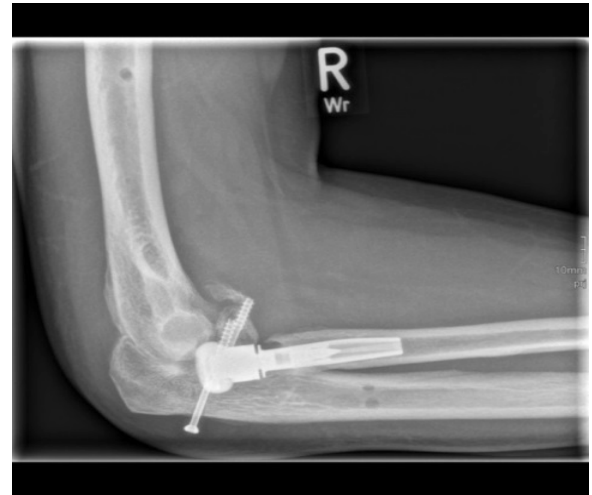

Figure 2. Secondary subluxation of primary inserted radial head resection arthroplasty.

3 patients, signs of superficial infection in 1 patient, and loosening of material in 1 patient [Figure 2].

Clinical and radiological follow-up was performed after a median of 46 months postoperatively. Results according to the Neutral Zero Method are presented in Table 1 (25). Functional results according to MEPS, Broberg and Morrey, DASH and VAS scoring systems were as follows: MEPS 70 points, Broberg and Morrey score 63 points, DASH score 34 points, and VAS 3.3 points for group 1. In group 2, MEPS was 63 points, Broberg and Morrey score was 50 points, DASH score was 49 points, and VAS 4.2 points. In group 3, the MEPS score was 73 points, the Broberg and Morrey score 66 points, the DASH score 38 points, and VAS 2.8 points. The overall long-term result of group 1 and 3 was superior to group 2 [Figure 3; 4].

The following complications in 5 out of 48 patients (10.4%) of group 1 were as follows: Subluxation of prosthesis (1), loosening of prosthesis (1), heterotopic ossifications (1), ulnar nerve affection (1), and need for additional application of an external fixator (1). In group 2, 4 out of 20 patients (20%) suffered the following complications: Heterotopic ossifications (1), Complex Regional Pain Syndrome (CRPS) (1), ulnar positive variance (1), and need for a muscular flap (1).

Severity of posttraumatic osteoarthritis according to the Kellgren-Lawrence grading scale was significantly lower in groups 1 and 3 compared with group 2 ($P=0.02$) [Figure 4] (24). Comparing subgroups, the group of radial head fracture related to elbow dislocation demonstrated a trend of worse functional outcome

Table 1. Long-term range of movement according to the Neutral Zero Method [degrees] (median) (17)		
Cohort group	Extension/Flexion	Pronation/Supination
Group 1	0-20-118°	69-0-57°
Group 2	0-27-117°	67-0-59°
Group 3	0-19-117°	68-0-54°

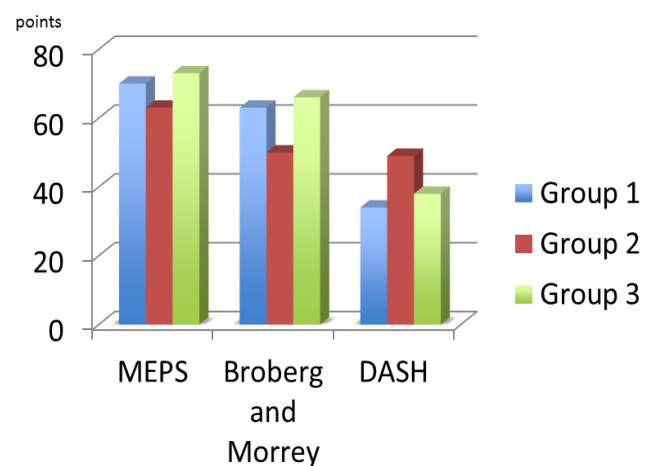


Figure 3. Long-term functional results of cohort groups 1-3 according to MEPS, Broberg and Morrey, and DASH scoring systems ([points], MEPS: maximum 100 points, Broberg and Morrey: maximum 100 points, DASH: maximum 0 points; median) (19, 20).

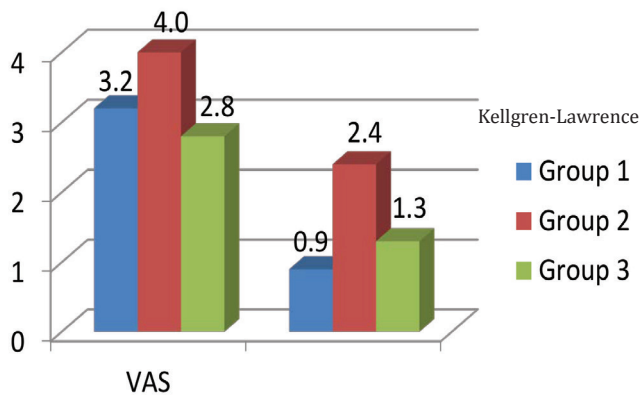


Figure 4. Long-term results in terms of pain (VAS) and Kellgren-Lawrence osteoarthritis grading scale of subgroups 1, 2 and 3 in patients with Mason IV fractures [points] (VAS: maximum 10 points, Kellgren-Lawrence scale: grade 0-4; median) (22, 32).

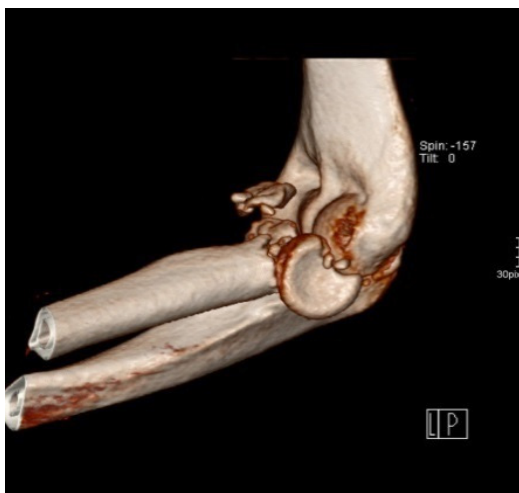

Figure 5. 3-D computed-tomography scan demonstrating a Mason type IV fracture with elbow dislocation and fracture of the coronoid process in a 42-year-old male patient leading to functional instability.

compared to the group of isolated radial head fracture, but without significance [Figure 4]. In the subgroup of patients with Mason IV fracture [Figure 5], the outcomes of group 1 and group 3 were superior to group 2 in terms of secondary osteoarthritis ($P=0.006$), pain ($P=0.04$), and functional outcome ($P=0.012$) [Figure 4].

Discussion

Complex multi-fragmentary fractures of the radial head represent a common lesion of the elbow. Already, three decades ago, resection of the radial head was mentioned to be justified either isolated or in accordance with acute prosthetic joint replacement (26). Primary radial head resection arthroplasty seemed to be the

surgical treatment of choice for comminuted fractures of the radial head in cases where internal fixation is not achievable and which used to be indications for simple radial head resection (11, 12, 27). There is good outcome data supporting metal and pyrocarbon prostheses (7, 16, 27). However, revision rates following primary radial head replacement are still widely unidentified.

The main aim of this comparative study was to evaluate how the elbow joint reacts to an acute radial head resection arthroplasty or a necessary secondary prosthetic removal after complex primary repair compared with primary radial head resection. The overall good clinical results obtained in our study confirm findings of recent literature which suggest the option of primarily shaping a scar tissue adequate to ensure sufficient elbow stability after a required secondary radial head prosthetic removal (28). Our study reported a high secondary resection rate for primary radial head resection arthroplasty utilized in the initial operative management of acute comminuted Mason type III and IV radial head fractures. The revision rates in recent literature are both wide ranging from 0-32% and still ambiguous (7, 16, 29). The overall rate of 22% at a median of 46 months in our investigation is less than the results of Duckworth et al. (28%) and Doornberg et al. (32%), and comparable to Harrington et al. (20%) (7, 29, 30). Accurate reasons for the variation of rates in literature are still unclear. They could probably be explained multifactorially by pivotal factors such as surgeons' preference, patient-related and injury-related factors, the type of prosthesis, and the range of time to follow-up. In this investigation most common reasons for hardware removal were subluxation of prosthesis, persistent pain, loss of function with persistent stiffness, significant cartilage damage, and prosthetic loosening, which is consistent with the findings of other studies (18, 31).

Recent literature provided acute resection arthroplasty for comminuted radial head fractures (Mason type III and IV) to yield good clinical but poor radiological long-term results (32). Our long-term outcomes and range of motion are similar to those reported in earlier investigations, with overall satisfactory functional results after secondary hardware removal [Table 1; Figures 3; 4] (15, 27, 28). Despite satisfactory functional long-term outcomes, radial head resection resulted in migration of the proximal radius followed by an increased carrying angle. Also, secondary osteoarthritic degeneration in both elbow and wrist joints, as well as heterotopic ossifications, were frequently seen without pronounced functional impairment (32). Also persistent pain was associated with findings of radiographic hardware loosening (18). Other studies described complications leading to a necessary hardware removal including neuritis, superficial or deep infection, and persistent subluxation or dislocation of prosthesis, which were comparable to the findings of our investigation (17, 29, 33).

Study limitations

The primary strength of this study is that a large cohort of patients undergoing the same acute prosthetic replacement for complex radial head fractures was

reported, in contrast to other studies that included a heterogeneous cohort of acute and chronic radial head replacements and a wide range of different implant types (18).

Limitations of the study include the retrospective study design, the variable range of time to follow-up of patients, and the treatment by multiple surgeons over a long period. The study did not focus on possible independent risk factors such as patient age or prosthesis material associated with necessary hardware revision or removal. Besides, our study did not compare with the treatment option of primary ORIF using modern osteosynthesis materials such as anatomically pre-contoured angle stable plating systems. This could be explained by the early beginning of the study in 2004 when primary radial head resection was a common concept for acute care. In the meanwhile, a treatment shift towards open reduction and internal fixation evolved.

Functional and radiological long-term results of this study demonstrate a trend towards a better outcome following temporary radial head resection arthroplasty compared to radial head resection especially in complex fractures associated with elbow dislocation. Furthermore, our results encourage the use of primary radial head replacement in cases of comminuted non-reconstructable radial head fractures. Future comparative studies including modern osteosyntheses are needed.

Compliance with Ethical Standards

All procedures performed in this study involving human participants were in accordance with the ethical standards of the institutional and national research committee and with the 1964 Helsinki declaration and its later amendments. Written informed consent was obtained from all individuals participating in the study.

Conflicts of interest: The authors report no conflict of interest concerning the materials or methods used in this

study or the findings specified in this paper.

Authors' contributions: MK and CVR drafted the manuscript. CVR, SH, AT, JF and VB contributed to the acquisition of data, analysis, and interpretation of data. JF and SH helped to search literature and to finalize the manuscript. CVR and MK participated in the conception, design, and coordination. VB supervised the whole study. All authors read and approved the final manuscript.

Ethics approval and consent to participate: All patients agreed and signed to participate on this study.

All procedures performed in this study involving human participants were in accordance with the bioethical standards of the institutional research committee and with the 1964 Helsinki declaration and its later amendments.

Consent to publish: Written informed consent for publication of this study and any accompanying images was obtained from all patients.

Funding: This research received no specific grant from any funding agency in the public, commercial or not-for-profit sectors.

Martin Kiechle MD
Andreas Thannheimer MD
Jan Friederichs MD
Volker Bühren MD
Department of Trauma Surgery, BG Trauma Center
Murnau, Germany

Sven Hungerer MD
Christian von Rüden MD
Department of Trauma Surgery, BG Trauma Center
Murnau, Germany
Institute for Biomechanics, Paracelsus Medical University,
Salzburg, Austria

References

- Estrada-Malacón CA, Perez-Valtierra M, Torres-Zavala A, Fonseca-Bernal M. Hemiarthroplasty of the radial head in patients with Mason Johnston types III and IV fracture. *Acta Ortop Mex.* 2015; 29(3):148-54.
- Duckworth AD, McQueen MM, Ring D. Fractures of the radial head. *Bone Joint J.* 2013; 95-B(2):151-9.
- Charalambous CP, Stanley JK, Mills SP, Hayton MJ, Hearnden A, Trail I, et al. Comminuted radial head fractures: aspects of current management. *J Shoulder Elbow Surg.* 2011; 20(6):996-1007.
- Ring D. Radial head fracture: open reduction-internal fixation or prosthetic replacement. *J Shoulder Elbow Surg.* 2011; 20(2 Suppl):S107-12.
- Herbertsson P, Josefsson PO, Hasselius R, Besjakov J, Nyqvist F, Karlsson MK. Fractures of the radial head and neck treated with radial head excision. *J Bone Joint Surg Am.* 2004; 86-A(9):1925-30.
- Iftimie PP, Calmet Garcia J, de Loyola Garcia Forcada I, Gonzalez Pedrouzo JE, Gine Goma J. Resection arthroplasty for radial head fractures: long-term follow-up. *J Shoulder Elbow Surg.* 2011; 20(1):45-50.
- Duckworth AD, Wickramasinghe NR, Clement ND, Court-Brown CM, McQueen MM. Radial head replacement for acute complex fractures: what are the rate and risks factors for revision or removal? *Clin Orthop Relat Res.* 2014; 472(7):2136-43.
- Sun H, Duan J, Li F. Comparison between radial head arthroplasty and open reduction and internal fixation in patients with radial head fractures (modified Mason type III and IV): a meta-analysis. *Eur J Orthop*

- Surg Traumatol. 2016; 26(3):283-91.
9. Zunkiewicz MR, Clemente JS, Miller MC, Baratz ME, Wysocki RW, Cohen MS. Radial head replacement with a bipolar system: a minimum 2-year follow-up. *J Shoulder Elbow Surg.* 2012; 21(1):98-104.
 10. Zarifian A, Rahimi Shoorin H, Hallaj Moghaddam M, Fathi Vavsari M, Gharedaghi M, Moradi A. The best option in treatment of modified mason type iii radial head fractures: open reduction and internal fixation versus radial head excision. *Arch Bone Jt Surg.* 2018; 6(5):365-70.
 11. Chen X, Wang SC, Cao LH, Yang GQ, Li M, Su JC. Comparison between radial head replacement and open reduction and internal fixation in clinical treatment of unstable, multi-fragmented radial head fractures. *Int Orthop.* 2006; 35(7):1071-6.
 12. Ruan HJ, Fan CY, Liu JJ, Zeng BF. A comparative study of internal fixation and prosthesis replacement for radial head fractures of Mason type III. *Int Orthop.* 2009; 33(1):249-53.
 13. Lindenhovius AL, Felsch Q, Doornberg JN, Ring D, Kloen P. Open reduction and internal fixation compared with excision for unstable displaced fractures of the radial head. *J Hand Surg Am.* 2007; 32(5):630-6.
 14. Wu PH, Shen L, Chee YH. Screw fixation versus arthroplasty versus plate fixation for 3-part radial head fractures. *J Orthop Surg (Hong Kong).* 2016; 24(1):57-61.
 15. Burkhart KJ, Mattyasovszky SG, Runkel M, Schwarz C, Kuchle R, Hessmann MH, et al. Mid- to long-term results after bipolar radial head arthroplasty. *J Shoulder Elbow Surg.* 2010; 19(7):965-72.
 16. Grewal R, MacDermid JC, Faber KJ, Drosdowech DS, King GJ. Comminuted radial head fractures treated with a modular metallic radial head arthroplasty. Study of outcomes. *J Bone Joint Surg Am.* 2006; 88(10):2192-200.
 17. Laun R, Wild M, Hakimi M. One-year results of cemented bipolar radial head prostheses for comminuted radial head fractures. *GMS Interdiscip Plast Reconstr Surg DGPW.* 2015; 4(Doc12):1-7.
 18. van Riet RP, Sanchez-Sotelo J, Morrey BF. Failure of metal radial head replacement. *J Bone Joint Surg Br.* 2010; 92(5):661-7.
 19. Neuhaus V, Christoforou DC, Kachooei AR, Jupiter JB, Ring DC, Mudgal CS. Radial head prosthesis re-moval: a retrospective case series of 14 patients. *Arch Bone Jt Surg.* 2015; 3(2):88-93.
 20. Keats AS. The ASA classification of physical status--a recapitulation. *Anesthesiology.* 1978; 49(4):233-6.
 21. Broberg MA, Morrey BF. Results of treatment of fracture-dislocations of the elbow. *Clin Orthop Relat Res.* 1987; 216(1):109-19.
 22. Hudak PL, Amadio PC, Bombardier C. Development of an upper extremity outcome measure: the DASH (disabilities of the arm, shoulder and hand) [corrected]. *The Upper Extremity Collaborative Group (UECG).* *Am J Ind Med.* 1996; 29(6):602-8.
 23. Aitken RC. Measurement of feelings using visual analogue scales. *Proc R Soc Med.* 1969; 62(10):989-93.
 24. Kellgren JH, Lawrence JS. Radiological assessment of osteo-arthritis. *Ann Rheum Dis.* 1957; 16(4):494-502.
 25. Ryf C, Weymann A. The neutral zero method-a principle of measuring joint function. *Injury.* 1995; 26(Suppl 1):1-11.
 26. Nonnenmacher J, Schurch B. Fractures of the radial head and lesions of the lower radius and ulna in the adult: the importance of the prosthesis in resection. *Ann Chir Main.* 1987; 6(2):123-30.
 27. Clembosky G, Boretto JG. Open reduction and internal fixation versus prosthetic replacement for complex fractures of the radial head. *J Hand Surg Am.* 2009; 34(6):1120-3.
 28. Vanni S, Marenco S, Calo M, Battiston B. Resection arthroplasty after failure of a radial head prosthesis: a case report. *Case Reports Plast Surg Hand Surg.* 2016; 3(1):28-31.
 29. Doornberg JN, Parisien R, van Duijn PJ, Ring D. Radial head arthroplasty with a modular metal spacer to treat acute traumatic elbow instability. *J Bone Joint Surg Am.* 2007; 89(5):1075-80.
 30. Harrington IJ, Sekyi-Otu A, Barrington TW, Evans DC, Tuli V. The functional outcome with metallic radial head implants in the treatment of unstable elbow fractures: a long-term review. *J Trauma.* 2001; 50(1):46-52.
 31. Smets S, Govaers K, Jansen N, Van Riet R, Schaap M, Van Glabbeek F. The floating radial head prosthesis for comminuted radial head fractures: a multicentric study. *Acta Orthop Belg.* 2000; 66(4):353-8.
 32. Yalcinkaya M, Bagatur AE, Erdogan S, Zorer G. Resection arthroplasty for Mason type III radial head fractures yield good clinical but poor radiological results in the long term. *Orthopedics.* 2013; 36(11):e1358-64.
 33. Butler MA, Holt GE, Crosby SN, Weikert DR. Late posterior interosseous nerve palsy associated with loosening of radial head implant. *J Shoulder Elbow Surg.* 2009; 18(6):e17-21.