

RESEARCH ARTICLE

Short Term Complications and Functional Results of Sarcoma Limb Salvage Surgeries

Mohammad Gharehdaghi, MD; Mohammad Hassani, MD; Ali Parsa, MD; Farzad Omidikashani, MD; Lida Jarrahi, MD; Rahim Hosseini, MD

Research performed at Mashhad University of Medical Sciences, Mashhad, Iran

Received: 08 October 2018

Accepted: 01 December 2018

Abstract

Background: Limb salvaging surgeries are current surgical treatment of extremity bone sarcomas. Resected bone replacement consists of two main methods; tumor prosthesis versus structural allograft. Biological reconstruction with an allograft is an economic cheap method in young sarcoma patients, however, the surgeons are more convinced with tumor prosthesis replacement.

Methods: We evaluated the short-term complications and functional results of 40 patients with aggressive extremity tumors in a retrospective cohort study. The mean age of cases was 25 and we followed them for 24 months. 17 patients underwent tumor prosthesis replacement after wide resection of limb sarcomas. 16 cases had structural allograft reconstruction and 7 patients treated with amputation. We matched confounders including age, sex, blood cell count and chemotherapy treatment in the study groups.

Results: We found 15 major complications (45.5%) in limb salvage surgeries composing infection, allograft nonunion, allograft fracture, prosthesis fracture, prosthesis loosening and device failure that needed another surgery to be resolved. We had 10 major complications in allograft group (62%) and 5 in tumor prosthesis group (29.4%). Although the rate of complications was higher in allograft group, it didn't statistically indicate strong correlation (Fisher's exact: 0.084). Mean Musculo-Skeletal tumor rating Scale (MSTS) score was 25.8(73.7%) and 22.3(63.7%) in allograft group and prosthesis cases respectively. MSTS score had a normal distribution in the different groups with no significant difference between them.

Conclusion: Although complications were higher in the allograft group, allograft could be offered to bone sarcoma patients, whom are predicted to have short life expectancy.

Level of evidence: III

Keywords: Allograft, Limb salvage, Sarcoma, Tumor prosthesis

Introduction

Sarcomas are mesenchymal cell malignancies which account for about 1% of all malignancies in adults with the proportion of 0.2% for bone sarcomas. The

annual incidence of bone sarcomas is about 8 cases per million (1).

Until the 1970s, amputation was the main treatment

Corresponding Author: Mohammad Hassani, Department of Orthopedic Surgery, Orthopedic Research Centre, Mashhad University of Medical Sciences (MUMS), Mashhad, Iran
Email: hasanim@mums.ac.ir



THE ONLINE VERSION OF THIS ARTICLE
ABJS.MUMS.AC.IR

of limb sarcomas but after publishing an article in 1980 reporting the results of limb salvaging surgeries (LSS) in 104 patients, the tendency to limb preservation after tumor resection increased gradually (2).

Increasing knowledge and skills in tumor surgery in addition to the development of chemotherapy and radiotherapy methods, as well as improved imaging techniques especially magnetic resonance imaging (MRI), altogether resulted in escalating the number and quality of LSS for limb sarcomas (3).

Due to these advances, many of definite contraindications for limb salvaging surgery including pathologic fractures and neurovascular bundle involvements are now considered as relative contraindications (4).

Although limb salvaging surgeries are more time-consuming and costly than amputations and they are also associated with more complications, in most studies the function and satisfaction of patients in the limb preserving groups are much higher compared to those in the amputation group (5).

There are various reconstructive methods that can be used after resecting the involved bone.

These methods are grouped into two main categories: reconstruction of the bone with a structural allograft; or replacement of the bone with a tumor prosthesis (6).

Each of these two methods has their own advantages and disadvantages which lead the tumor surgeons to choose one based on the patient's age, tumor location, type of limb involvement and cost consideration.

The aim of this study was to compare the short-term complications and functional results of these two main methods in the first two years after the limb salvaging surgery.

Materials and Methods

40 patients, 35 of whom had high-grade sarcomas, 3 had low-grade sarcomas, and 2 had benign aggressive tumors, all were evaluated in a retrospective cohort study. These patients were divided into three groups:

1. LSS by replacing the bone with tumor prosthesis (17 patients);
2. LSS by replacing the bone with allograft (16 patients);
3. Amputation (7 patients).

In all three groups, tumors were removed by two sarcoma surgeons from Mashhad University of Medical Sciences and we used wide-margin resection method. Patients were evaluated for post-operative complications requiring surgical intervention and also their function in the first two years after the first surgery.

Patients were monitored for WBC, Lymphocyte and Platelet counts. Hemoglobin and Alkaline phosphatase levels were also evaluated. Fresh frozen Gamma-ray-sterile allograft was used in allograft group. In this retrospective cohort study, all three groups were matched in terms of patient's sex, age, familial history, serum evaluations and risk factors like smoking. To evaluate the relationship between the rate of complications and the type of surgical procedure Fisher's exact test was used.

The surgical functional results of the patients in this study was assessed by MSTs 87 (Musculo-Skeletal tumor rating Scale) Questionnaire. It is a health-provider

assessment method for evaluating outcomes of limb sarcoma surgeries. MSTs evaluates the following 7 components: Pain; Range of motion; Strength; Stability; General functional ability; Emotional acceptance; and Deformity.

Results

The age of patients was between 7 and 62 years with an average of 25. 4 patients had a familial history of malignancies and 4 patients had a history of smoking. Distal femur was the most common site of tumor involvement (50% of cases) and accordingly knee pain was the most common symptom (55%). The final diagnosis of 31 patients was Osteosarcoma (77.5%); 3 patients had Ewing sarcoma; And 2 patients were diagnosed with Chondrosarcoma. In 2 patients, final pathologic evaluation of the tumor (after the surgical removal) did not match the preoperative biopsy report. 30 patients received neo-adjuvant chemotherapy with a mean of 4 courses prior to their surgery, and 21 patients received adjuvant chemotherapy with a mean of 3 courses postoperatively.

In the first 24 months after the surgery, out of the whole 40 cases, 17 had severe complications (42%) requiring secondary surgical intervention to control the complications.

These complications comprised infection, allograft non-union, allograft fracture, prosthesis fracture, prosthesis loosening, and device failure [Figure 1-3].

Ten patients suffered minor complications such as

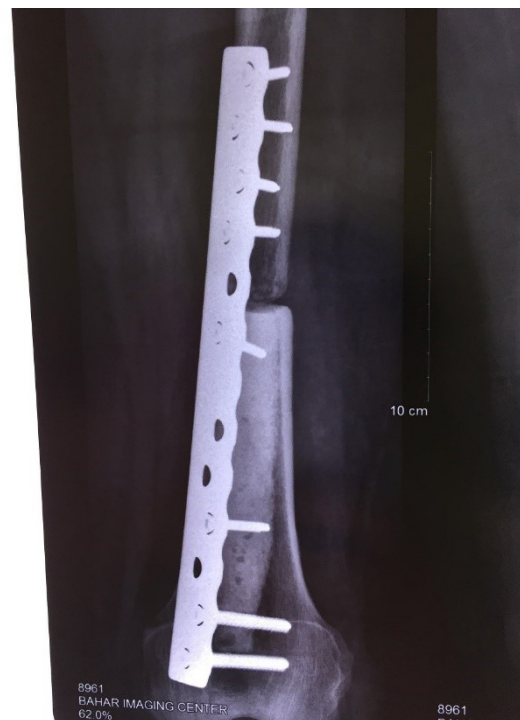

Figure 1. Distal femur allograft non-union.

shortness of the limb, reduced joint range of motion, pain, and neutropenia [Tables 1; 2].

In allograft group, 10 patients had major complications (62%) while the rate of major complications in prosthesis and amputation groups was 5 patients (29.4%) and 2 patients (28.5%) respectively. The total incidence of major complications in limb salvaging group was 45.5%. Despite the higher incidence of complications in allograft group, by using Fisher's statistical analysis, we found no significant correlation

between using allograft and complications (Fisher's exact: 0.084) [Table 3].

From the viewpoint of MSTs score, the mean score of allograft group was 25.8 (73.7%) and the mean of prosthesis group was 22.3 (63.7%).

Although the MSTs score in two limb salvaging groups followed a normal distribution pattern, there was no statistically meaningful correlation between the mean MSTs score and the selected reconstruction method [Figure 4; 5].

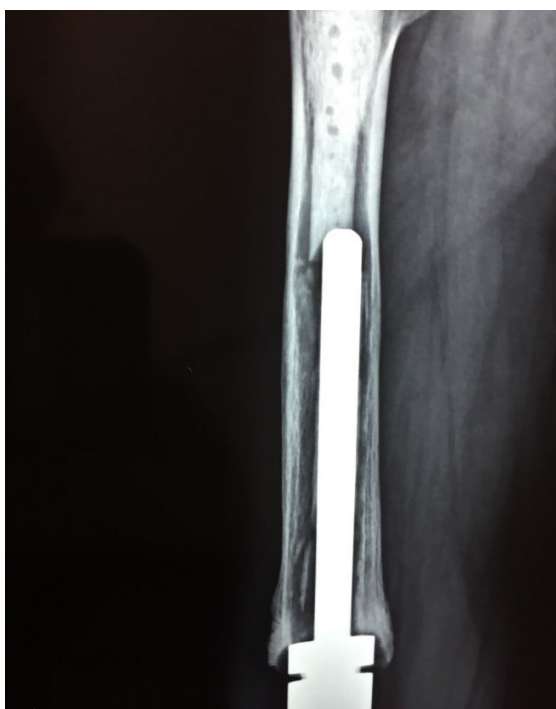

Figure 2. Tumor prosthesis Loosening.

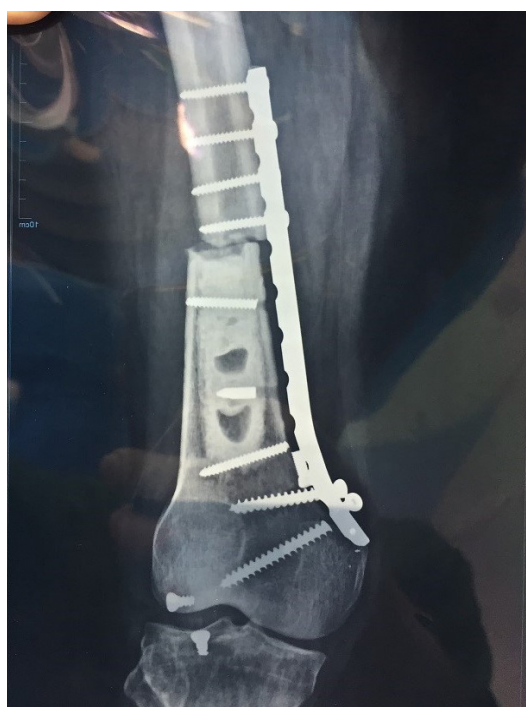

Figure 3. Allograft fixation-device failure.

| Table 1. Short-term complications in the allograft group | | |
|--|---------------------------|--------------------------|
| Case Number | Pathology | Complication |
| 1 | Osteoblastic Osteosarcoma | NO (mild pain) |
| 2 | Spindle Cell Sarcoma | LLD |
| 3 | Osteosarcoma | Local Recurrence |
| 4 | Osteosarcoma | Allograft Fx + non-union |
| 5 | Low Grade Osteosarcoma | Device failure |
| 6 | Ewing Sarcoma | LLD 1.5cm |
| 7 | Ewing Sarcoma | Non-union |
| 8 | Brown Tumor | Non-union |
| 9 | Osteosarcoma | Infection |
| 10 | Osteosarcoma | Allograft Fx |
| 11 | Osteosarcoma | LLD 5cm + device failure |

| Table 1. Continued | | |
|--------------------|-------------------------------|-----------|
| 12 | Osteosarcoma | NO |
| 13 | Osteosarcoma of Distal Tibia | Non-union |
| 14 | Chondrosarcoma | NO |
| 15 | Osteosarcoma (telangiectatic) | Non-union |
| 16 | Ewing Sarcoma | NO |

| Table 2. Short-term complications in the tumor prosthesis group | | |
|---|-------------------------------|-------------------------|
| Case number | Pathology | Complication |
| 1 | Osteosarcoma | neutropenia |
| 2 | Small round cell tumor | No |
| 3 | Osteosarcoma | Loosening |
| 4 | Low Grade osteosarcoma | LLD+ loosening+ Ext lag |
| 5 | Paraosteal osteosarcoma | Decrease ROM +infection |
| 6 | Osteosarcoma | Decrease ROM |
| 7 | Osteosarcoma | Prosthesis locker Fx |
| 8 | Osteosarcoma | Mild pain |
| 9 | Osteosarcoma | No |
| 10 | Osteosarcoma | No |
| 11 | Osteosarcoma | Prosthesis locker Fx |
| 12 | Osteosarcoma | Decrease ROM |
| 13 | Osteosarcoma | No |
| 14 | Osteosarcoma | Decrease ROM |
| 15 | Osteosarcoma | Decrease ROM |
| 16 | Osteosarcoma </td <td>No</td> | No |
| 17 | Chondrosarcoma | No |

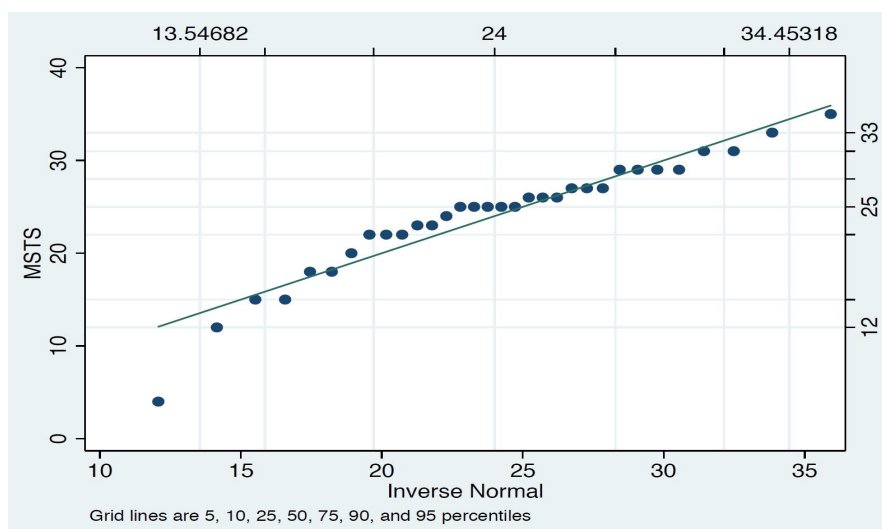


Figure 4. Normal distribution of MSTS score in the salvaging groups.

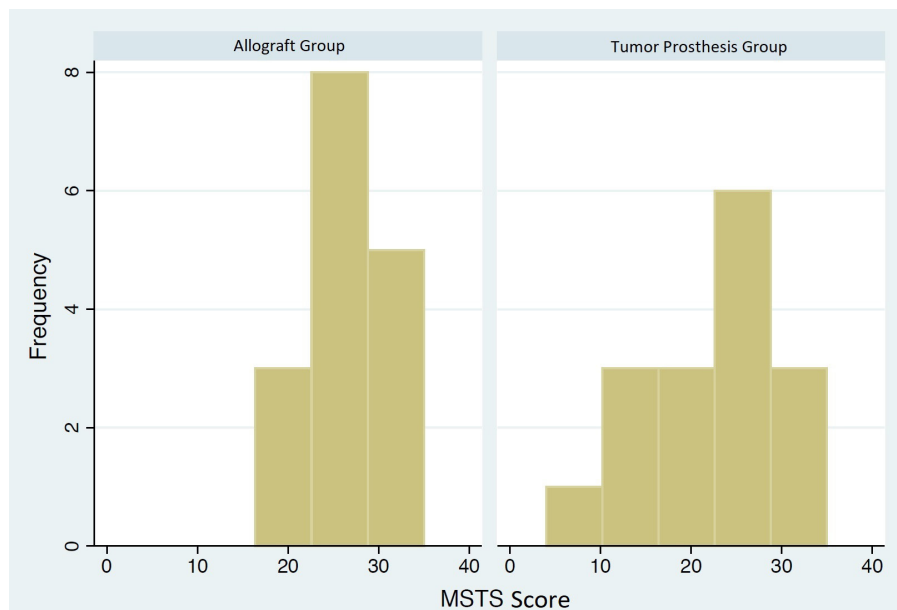


Figure 5. MSTS-score distribution in allograft (1) and prosthesis (2) groups.

Discussion

Patients with bone sarcomas are mostly young people with a mean age of 25.8 years in our study. These patients are in the most active period of their lives in terms of social and personal function. Therefore, treatment in these patients focuses on a goal beside tumor removal: Using a method with minimal cost and surgical complications in addition to helping these patients to achieve the maximum function.

In recent studies in order to review the treatment outcomes, factors such as disease recurrence, the limb's function, the patient's function and his quality of life were evaluated (7,8). In current study we evaluated the incidence of short term postoperative major complications requiring secondary surgical interventions and the patients' functional results.

It has been shown that there is not necessarily a relationship between the operation method and the patient's quality of life, but there is a significant relation between the patient's function and his quality of life (9).

There are several questionnaires like MSTS and TESS that are available for evaluating the surgical outcomes after sarcoma treatment. Additionally, there are common measures like SF-36 and EQ-5D for assessing the quality of life of patients (10). We assessed our patients' outcome with MSTS-87 which is a health-provider measure. We found no significant difference in a 24-month evaluation of the patient's function who undergone limb salvaging surgeries with either tumor prosthesis or allograft replacement method. This finding suggested that the short-term results of the allograft replacement are comparable with the prosthesis replacement.

Another considerable issue in our study was the incidence of major complications in 24 months after

the surgery with the total incidence of 45.5% in limb salvaging group which was higher than the amputation group (28.5%).

Although Mavrogenis et. all reported the same rate of complications in the both amputation and limb salvaging groups, patient's satisfaction and general function in most studies outweigh in the limb salvaging group (11, 12).

Another subject in our study was the greater rate of major complications in the allograft group (62%) in comparison to the prosthesis group (29.4%). However, this was not a significant difference by using the Fisher's test which can be due to the small number of participants in our study.

Recently, there is an increasing tendency among tumor surgeons for using tumor prosthesis in most specialized centers for treatment of sarcomas, however, allograft usage in the form of structural osteochondral graft or composite form (APC) is still the preferred treatment method of some surgeons especially in younger patients and in those with specific anatomical locations (13-15).

Another advantage of allograft replacement is the lower cost of this method compared to tumor prosthesis (16) that leads this method to be selective in some public health systems like Iran's (17).

A topic that should be highlighted in this study was the use of gamma ray for sterilizing the allografts which increases the risk of non-union. In our study, 4 of the 20 patients (25%) in the allograft group presented with complication of non-union in a 2-year follow-up that could probably be decreased with a change in the sterilization method.

One limitation of our study was the low number of

total patients which could be due to the low incidence of bone sarcomas in the community. A solution is to design multi-centered studies that can improve the accuracy of the results and the validity of the study. Another limitation was our tool for outcome measure. MSTs is not a PRO (Patient Reported Outcome) measure and does not necessarily reflect the quality of patients' lives which could introduce a bias. Adding a patient-reported outcome measure (PRO) for estimating the patients' quality of life (QOL) to these kinds of studies, is something we are going to consider in future which can be a great help in evaluating the effects of the treatment method on quality of patient's lives.

Short-term complications of limb salvaging surgeries in patients with limb sarcomas are high (45% of our patients needed a secondary procedure to control the complications). There was no significant difference in complication rate between the two methods of limb salvaging surgery using allograft or tumor prosthesis in short-term follow-up.

Furthermore, MSTs evaluation of the functional outcome of the patients who undergone these two methods of surgery did not show a significant difference.

Therefore, considering the lower cost of using allograft, allograft could be offered to bone sarcoma patients, whom are predicted to have short life expectancy.

Disclosure: The authors did not have any financial interest in conducting this study. This article is based on the results of a medical student's thesis in Mashhad University of medical sciences (MUMS).

Mohammad Gharehdaghi MD
Ali Parsa MD
Farzad Omidikashani MD
Orthopedic Research Center, Mashhad University of Medical Sciences (MUMS), Mashhad, Iran

Mohammad Hassani MD
Department of Orthopedic Surgery, Orthopedic Research Centre, Mashhad University of Medical Sciences (MUMS), Mashhad, Iran

Lida Jarrahi MD
Mashhad University of Medical Sciences (MUMS), Mashhad, Iran

Rahim Hosseini MD
Department of Orthopedic Surgery, Imamreza Hospital, Mashhad University of Medical Sciences, Mashhad, Iran

References

1. Fletcher CD. World Health Organization classification of tumours pathology and genetics of tumours of soft tissue and bone. Lyon: IARC Press; 2002.
2. Eilber FR, Mirra JJ, Grant TT, Weisenberger T, Morton DL. Is amputation necessary for sarcomas? A seven-year experience with limb salvage. *Ann Surg.* 1980; 192(4):431-8.
3. DiCaprio MR, Friedlaender GE. Malignant bone tumors: limb sparing versus amputation. *J Am Acad Orthop Surg.* 2003; 11(1):25-37.
4. Bacci G, Ferrari S, Longhi A, Donati D, Manfrini M, Giacomini S, et al. Nonmetastatic osteosarcoma of the extremity with pathologic fracture at presentation, local and systemic control by amputation or limb salvage after preoperative chemotherapy. *Acta Orthop Scand.* 2003; 74(4):449-54.
5. Han G, Bi WZ, Xu M, Jia JP, Wang Y. Amputation versus limb-salvage surgery in patients with osteosarcoma: a meta-analysis. *World J Surg.* 2016; 40(8):2016-27.
6. Albergio JJ, Gaston CL, Aponte-Tinao LA, Ayerza MA, Muscolo DL, Grimer RJ, et al. Proximal tibia reconstruction after bone tumor resection: are survivorship and outcomes of endoprosthetic replacement and osteoarticular allograft similar? *Clin Orthop Relat Res.* 2017; 475(3):676-82.
7. Ayerza A, Farfalli G, Aponte-Tinao L, Muscolo D. Does increased rate of limb-sparing surgery affect survival in osteosarcoma? *Clin Orthop Relat Res.* 2010; 468(11):2854-9.
8. Bacci G, Forni C, Longhi A, Ferrari S, Mercuri M, Picci P, et al. local recurrence and local control of non-metastatic osteosarcoma of the extremities: a 27-year experience in a single institution. *J Surg Oncol.* 2007; 96(2):118-23.
9. Eiser C, Darlington AS, Stride CB, Grimer R. Quality of life implications as a consequence of surgery: limb salvage, primary and secondary amputation. *Sarcoma.* 2001; 5(4):189-95.
10. Gundle KR, Cizik AM, Jones RL, Davidson DJ. Quality of life measures in soft tissue sarcoma. *Expert Rev Anticancer Ther.* 2015; 15(1):95-100.
11. Mavrogenis AF, Abati CN, Romagnoli C, Ruggieri P. Similar survival but better function for patients after limb salvage versus amputation for distal tibia osteosarcoma. *Clin Orthop Relat Res.* 2012; 470(6):1735-48.
12. Mei J, Zhu XZ, Wang ZY, Cai XS. Functional outcomes and quality of life in patients with osteosarcoma treated with amputation versus limb-salvage surgery: a systematic review and meta-analysis. *Arch Orthop Trauma Surg.* 2014; 134(11):1507-16.
13. Abed YY, Beltrami G, Campanacci DA, Innocenti M, Scoccianti G, Capanna R. Biological reconstruction after resection of bone tumors around the knee:

- long-term follow-up. *J Bone Joint Surg Br.* 2009; 91(10):1366-72.
14. Campanacci L, Ali N, Casanova JM, Kreshak J, Manfrini M. Resurfaced allograft-prosthetic composite for proximal tibial reconstruction in children: intermediate-term results of an original technique. *J Bone Joint Surg Am.* 2015; 97(3):241-50.
15. Levin AS, Arkader A, Morris CD. Reconstruction following tumor resections in skeletally immature patients. *J Am Acad Orthop Surg.* 2017; 25(3):204-13.
16. Wilson RJ, Sulieman LM, VanHouten JP, Halpern JL, Schwartz HS, Holt GE, et al. Cost-utility of osteoarticular allograft versus endoprosthetic reconstruction for primary bone sarcoma of the knee: a Markova analysis. *J Surg Oncol.* 2017; 115(3):257-65.
17. Gharedaghi M, Peivandi MT, Mazloomi M, Shoorin HR, Hasani M, Seyf P, et al. Evaluation of clinical results and complications of structural allograft reconstruction after bone tumor surgery. *Arch Bone Jt Surg.* 2016; 4(3):236-42.