

RESEARCH ARTICLE

Treatment of Massive Irreparable Rotator Cuff Tear with Arthroscopic Subacromial Bursectomy, Biceps Tenotomy, and Tuberopecty

Fateme Mirzaee, MSc; Mohammad A. Aslani, MD; Zohreh Zafarani, MD; Hamidreza Aslani, MD

Research performed at Knee and Sport Medicine Research and Education Center, Milad hospital, Tehran, Iran

Received: 20 June 2017

Accepted: 11 November 2018

Abstract

Background: The alternative surgery for massive and irreparable shoulder rotator cuff tears in older patients is the debridement of subacromial bursa, biceps tenotomy, and tuberopecty (reverse acromioplasty). This study aimed to report the effectiveness of such a treatment performed arthroscopically in a small group of patients for a short period of time.

Methods: This prospective study was conducted on 12 patients with massive irreparable rotator cuff tear during 2014-2017. Participants with the mean age of 65 were subjected to arthroscopic debridement of subacromial bursa, necrotic rotator cuff tendon remnants, and tuberopecty without coracoacromial ligament excision. The sign and symptoms of patients before and after the surgery were evaluated based on Modified-University of California at Los Angeles (UCLA) Shoulder Score.

Results: With the mean follow-up of 18 months (12-24 months), the mean of the modified UCLA score improved from 9.2 to 27.5. The obtained results of the study revealed that the pain and range of motion improved to near normal in the participants. The functional outcome was good although there were a decrease of acromiohumeral distance from 5 to 4 mm and a slight increase in degenerative changes.

Conclusion: This simple arthroscopic procedure is recommended for massive irreparable rotator cuff tear, especially in elderly patients.

Level of evidence: IV

Keywords: Arthroscopy, Biceps tenotomy, Rotator cuff tear, Tuberopecty

Introduction

Shoulder pain has been defined as the second-most common musculoskeletal disorder after low back pain (1, 2). Rotator cuff tears are among the most common causes of pain and functional disability in

the shoulder, which generally affect the supraspinatus tendon (3).

The integrity of the supraspinatus is essential for overhead shoulder function. Full-thickness rotator cuff

Corresponding Author: Hamidreza Aslani, Shahid Beheshti University of Medical Sciences, Knee and Sport Medicine Education and Research Center, Tehran, Iran
Email: hraslani1342@gmail.com



THE ONLINE VERSION OF THIS ARTICLE
ABJS.MUMS.AC.IR

tears mostly do not heal by itself. These tears can be repaired surgically using open surgery or arthroscopic-assisted approach (4, 5).

In recent years, there has been a dramatic change in the surgical treatment of massive irreparable shoulder rotator cuff tears. Current treatments include a wide range of non-surgical treatment, open debridement or arthroscopic and subacromial decompression, superior capsular reconstruction, direct repair of tear, muscles transfer, and glenohumeral joint arthroplasty (3, 5, 6).

Many authors believe that the decompression and debridement of massive rotator cuff tear can lead to good outcomes and patient satisfaction for appropriately selected patients. Elderly patients with lower activity demands and the main concern of pain relief are suitable candidates for this surgery, more specifically if they do not respond to conservative treatments (5, 7).

Many studies in the field of decompression and debridement have emphasized on the importance of releasing sufficient subacromial space to relieve pain in patients with massive rotator cuff tear (8, 9). Clinical studies on the cadaver have explained the importance of coracoacromial arch as passive stabilizer strength against upward and forward humeral head displacement, more specifically in the presence of massive rotator cuff tear (10).

In 2004, the arthroscopic procedure was explained by Scheibel, including the arthroscopic glenohumeral debridement, arthroscopic tuberoplasty of subacromial space, and possibility of biceps tenotomy based on the pathology of biceps tendon (11). The current study aimed to evaluate the efficiency of this method regarding the pain and improvement of the range of motion among elderly patients.

Materials and Methods

This prospective study was conducted on 12 patients (7 males and 5 females) with extensive rotator cuff tears during 2014-2017. The mean age of participants was 65 years [range: 60-75 years; Table 1]. The exclusion criteria included young age, extensive but restorable tear (even partially restorable), and rotator cuff arthropathy. The history of minor trauma was reported by four patients and none of the participants

Table 1. patient characteristics	
Number of patients	12
Mean Age, years (range)	65 (60_75)
Males/females, n	7 / 5
Side of effect (R/L)	8 / 4
Mean Symptom duration, month (range)	12 (7_17)
Type of non-operative treatment	
• Local injection(Steroid/ Hyaluronic gel)	4 / 3
• physical therapy	8
• Both	10

were previously subjected to surgery on the shoulder. All the patients had been under treatment with physical therapy, nonsteroidal anti-inflammatory drugs, and subacromial injections (hyaluronic gel or corticosteroid) for at least 6 months. The mean duration of the symptoms before surgery was 12 months (8-18).

Examination of the patients before the Surgery

Based on the clinical examination and radiographic evaluation, including true anteroposterior view and outlet projection of the supraspinatus muscle of the shoulder, and magnetic resonance imaging (MRI), the subjects were diagnosed with rotator cuff tear. Regarding physical examination, all patients had a positive "Hawkins-Kennedy" impingement test, and Belly-press test was positive in two patients (12).

The pain or function, motion, muscle strength, and satisfaction of the investigated patients before the surgery and at the final visit after the surgery were evaluated based on the Modified-University of California at Los Angeles (UCLA) Shoulder Rating Scale (13).

All patients had significant weakness of supraspinatus and other rotator cuff muscles of the shoulder. Before the surgery, the mean shoulder abduction was 100° (20-150°), and 4 patients had obvious clinical atrophy of supraspinatus and infraspinatus muscles.

On radiographic examination, the mean acromiohumeral distance was 5 mm (range: 5-9 mm). Moreover, six patients had mild degenerative changes in the upper half of the glenohumeral joint. In the supraspinatus outlet view, six patients had type II and two patients had type III acromion.

The MRI examination aimed to evaluate the muscular atrophy and fatty degeneration (muscle tissue replacement by fat). Moreover, the results of MRI indicated chronic tears, severe tendon retraction, and muscular atrophy [positive tangent sign was detected by MRI (14)], especially in supraspinatus. All patients completed the consent form before the surgery.

Surgical technique

Diagnostic arthroscopy was performed through a standard primary posterior portal. The size of rotator cuff tears was estimated in the next step. Accordingly, eight patients had a complete tear of supraspinatus and infraspinatus, and four patients had large tears of subscapularis tendon, which were repaired partially or completely. The biceps tenotomy was performed through the anterolateral portal for all the patients. The long head of the biceps tendon led to pathologic changes, including dislocation, complete or incomplete tear and synovitis.

The patients were in a beach chair position. The debridement of the inflamed synovium and subacromial bursa was performed considering the acromion and surrounding the coracoacromial ligament. The necrotic and irregular remnant of the tendon attached to the tuberosity was also removed. If the free end of the rotator cuff tendon was unstable, it was debrided in order to create a stable edge. The coracoacromial arch was retained, followed by exostoses (bone tuberosity)

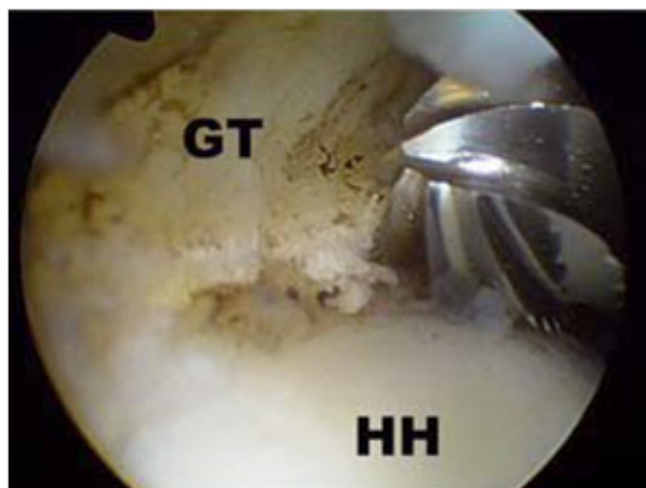


Figure 1. Shaping humeral head view by Burr (GT: greater tuberosity, HH: humeral head).

on the greater tuberosity of the humerus. Moreover, the impingement test was performed to identify the sections that got stuck under the coracoacromial arch.

The prominent part of the tuberosity was removed using an arthroscopic burr. The goal was to remove all prominent parts of tuberosity, shaping the humeral head, and creating a smooth uniform surface that can slide under the arch [Figure 1].

The limb was kept at 60° abduction and all sections of tuberosity were examined in this position by the internal and external rotation of the shoulder. After 24 h of immobilization in a shoulder sling, physiotherapy with passive movements was started for the first 2 weeks. Subsequently, the active movements and strengthening of the remaining rotator cuff, deltoid, and muscles surrounding the scapula continued until improvement in shoulder function reached a steady state (mean duration of 6 months). To protect the long head of the biceps tendon after tenotomy, the patient needed to avoid doing heavy work with the elbow and

strong supination of the forearm for 4 months.

Results

During the mean follow-up of 18 months (12-24 months), preoperative data were compared with the final visit according to the criteria of Modified-UCLA Shoulder Rating Scale. Data analyses were conducted using the SPSS software (version 22; SPSS Inc, Chicago IL). *P*-value less than 0.05 was considered statistically significant. The Kolmogorov-Smirnov test was used to assess the normality of the data. Moreover, paired sample t-test (for normal data) and Wilcoxon rank sum test (for non-parametric data) were used to compare the mean differences before and after the surgery.

The results of the treatment were excellent for six patients (34-35 points), good for five patients (29-33 points), and moderate for one patient (<29 points). The mean UCLA score before the surgery was 9.2, which increased to 27.5 after the surgery (*P*<0.001). The most considerable symptom in these patients was pain that improved from 9 (out of 10) before the surgery to 2.5 after the surgery (*P*<0.001). The results showed that 10 patients had no pain, 2 patients had pain at the time of exercise, and none of the patients had any nighttime pain.

The mean shoulder abduction increased after the surgery (*P*<0.001). The increased range of motion in each patient was closely correlated with the improvement of postoperative pain. The results indicated that, at the final visit, the mean shoulder flexion increased from 97° before the surgery to 148° after the surgery in 9 patients (*P*<0.001, Table 2). Compared with the preoperative radiographs, immediate postoperative radiograph showed a slightly greater tuberosity with a uniform surface in all patients. However, the acromiohumeral distance decreased from 5 to 4 mm [Figure 2].

As was observed, four patients had degenerative changes before the surgery, and the radiographic results of two patients showed degenerative changes after the surgery. However, degenerative changes had no significant correlation with clinical and functional outcomes after the surgery (*P*=0.07).

Table 2. Comparison of patient's outcomes before and after surgery

Variables	Before surgery		After surgery		P Value
	Mean	Std. Deviation	Mean	Std. Deviation	
Abd°	100	19.4	160	19.9	.000
Flx°	97	17.6	148	18.1	.000
VAS	9	0.7	2.5	0.5	.000
UCLA	9.2	0.8	27.5	0.8	.000
Acromiohumeral distance(mm)	5	0.2	4	0.3	.000

score Shoulder (UCLA) Angeles Los at California of University-Modified ,(VAS) scale scale analogue Visual

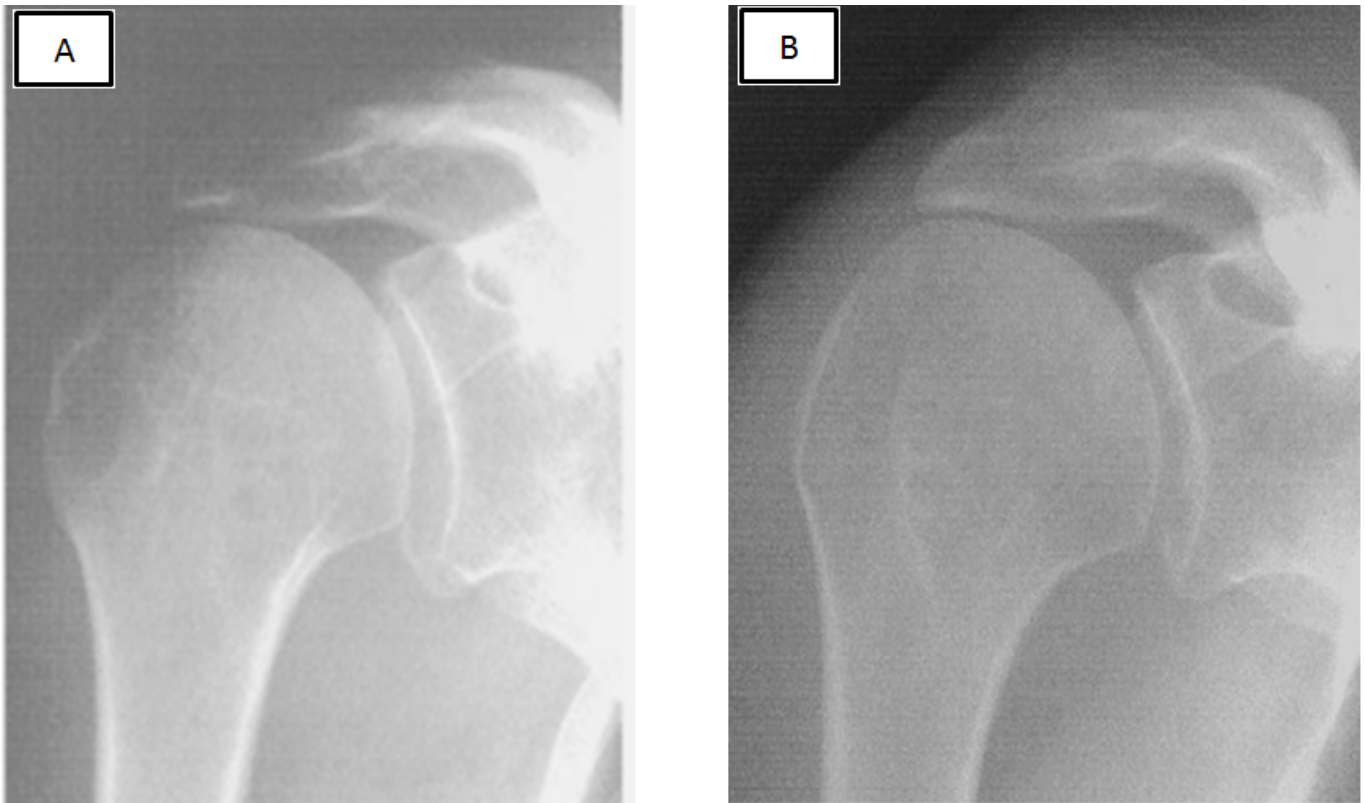


Figure 2. Anterior shoulder X-ray. A: before, B: after Tuberoplasty.

Discussion

The term massive rotator cuff tear has been widely used to identify very large tears that are particularly difficult to repair. Massive rotator cuff tears occur most often in elderly people and are associated with an uncertain prognosis (15-17). Despite the massive tear, the patient has no pain and has an acceptable performance for a long time. If we try to repair the rupture even partially, there is a high risk of re-rupture due to the improper quality of muscle tissue and extensive fatty degeneration (19). It has been widely accepted that the repair of massive rotator cuff tears is difficult and associated with a high incidence of failure. For the first time, Rockwood et al. employed the debridement methods and decompression for wide and irreparable rotator cuff tears. This method was designed to remove any factor that causes subacromial (SA) impingement, including acromioplasty, removal of coracoacromial ligament, subacromial bursa and remnants of the necrotic tendon. In a 6-year follow-up of 58 patients, there was a significant improvement in most patients regarding pain and range of motion (20).

In another study conducted by Ellman, this procedure was managed arthroscopically through the long-term follow-up of 2-7 years. The obtained results indicated that pain improved significantly in 40 patients; however, this procedure did not improve the range of motion or

strength (21).

Ogillvi-Harris et al. emphasized that debridement and decompression should be performed for elderly patients with a low range of activity to reduce pain and improve the range of motion. On the other hand, the repair must be managed in younger patients to restore strength and performance (22).

In a study performed by Wiley, the head of the humerus was dislocated upward in four patients after acromioplasty and removing coracoacromial ligament (23).

Tuberoplasty was introduced for the first time by Fenelin et al as a new surgical procedure. The method was employed for 20 patients with a massive rotator cuff tear, accompanied by preserving the coracoacromial arc and the creation of an acromio-humeral joint. In another study, similar outcomes with arthroscopic method were reported for 23 patients.

In 2010, Verhelst evaluated the subacromial decompression and biceps tenotomy as a valuable method with good results of the mid-term for the treatment of the extensive and irreparable rotator cuff tears. In case this operation failed, reverse shoulder arthroplasty was the alternative approach (24).

Pericles et al. evaluated the effect of the mini-open technique using a tendon-grasping suture on the

patients with large and massive rotator cuff tears. They suggested that this method can successfully improve large and massive rotator cuff tears and has a satisfactory clinical outcome despite a significant re-tear rate (25).

Similar to a study conducted by Fenelin et al., arthroscopic tuberoplasty was introduced in the present study as an appropriate method for irreparable rotator cuff tears in elderly people, especially for non-functional rupture. This surgery is easy and quick with minimal side effects and predictable long-term results. This process does not disrupt the shoulder stabilizer factor and creates the smooth surface between the humeral head and the acromion. There is no serious concern about the minor displacement of the humeral head upward after the surgery. In this study, there was a little increase in degenerative changes in this period and it had no effect on clinical and functional outcomes. Some believe that long head biceps tendon should be preserved in rotator cuff tear as a humeral head depressor. However, because that keeping it known as a major cause of pain resistant to treatment and also the retentive effect it is almost nonexistent when we keep coracoacromial arc. Therefore, in case of damage, it is better to perform biceps tenotomy (26).

Although this study provided groundbreaking findings, it suffered from some limitations, including small sample size, short follow-up, and the lack of control group to perform standard acromioplasty. Therefore, it is

recommended to conduct randomized controlled trials with longer follow-up to investigate the influence of this method.

The short-term results of the current study indicated that large and massive tears can be successfully treated with arthroscopic tuberoplasty. This surgery is an appropriate method for the treatment of this ruptures, especially for elderly people. According to the obtained results of the current study, this method improved performance, range of motion, and pain in the investigated patients.

Fateme Mirzaee MSc
University of Social Welfare and Rehabilitation Sciences,
Knee and Sport Medicine Research Center, Milad hospital,
Tehran, Iran

Mohammad A. Aslani MD
Zohreh Zafarani MD
Knee and Sport Medicine Research Center, Milad hospital,
Tehran, Iran

Hamidreza Aslani MD
Shahid Beheshti University of Medical Sciences, Knee and
Sport Medicine Research Center, Tehran, Iran

References

1. Familiari F, Gonzalez-Zapata A, Ianno B, Galasso O, Gasparini G, McFarland EG. Is acromioplasty necessary in the setting of full-thickness rotator cuff tears? A systematic review. *J Orthop Traumatol*. 2015; 16(3):167-74.
2. Aslani H, Nourbakhsh ST, Zafarani Z, Ahmadi-Bani M, Ananloo ME, Beigy M, et al. Platelet-rich plasma for frozen shoulder: a case report. *Arch Bone Jt Surg*. 2016; 4(1):90-3.
3. Pennington WT, Bartz BA, Pauli JM, Walker CE, Schmidt W. Arthroscopic superior capsular reconstruction with acellular dermal allograft for the treatment of massive irreparable rotator cuff tears: short-term clinical outcomes and the radiographic parameter of superior capsular distance. *Arthroscopy*. 2018; 34(6):1764-73.
4. Rubenis I, Lam PH, Murrell GA. Arthroscopic rotator cuff repair using the undersurface technique: a 2-year comparative study in 257 patients. *Orthopa J Sports Med*. 2015; 3(10):2325967115605801.
5. Kang JR, Sin AT, Cheung EV. Treatment of massive irreparable rotator cuff tears: a cost-effectiveness analysis. *Orthopedics*. 2017; 40(1):e65-76.
6. Castagna A, Garofalo R, Maman E, Gray AC, Brooks EA. Comparative cost-effectiveness analysis of the subacromial spacer for irreparable and massive rotator cuff tears. *Int Orthop*. 2018; 43(2):395-403.
7. Gerber C, Fuchs B, Hodler J. The results of repair of massive tears of the rotator cuff. *J Bone Joint Surg Am*. 2000; 82(4):505-15.
8. Burkhart SS. Arthroscopic treatment of massive rotator cuff tears. Clinical results and biomechanical rationale. *Clin Orthop Relat Res*. 1991; 267(1):45-56.
9. Song L, Miao L, Zhang P, Wang WL. Does concomitant acromioplasty facilitate arthroscopic repair of full-thickness rotator cuff tears? A meta-analysis with trial sequential analysis of randomized controlled trials. *Springerplus*. 2016; 5(1):685.
10. Fenlin JM Jr, Chase JM, Rushton SA, Frieman BG. Tuberoplasty: creation of an acromioclavicular articulation—a treatment option for massive, irreparable rotator cuff tears. *J Shoulder Elbow Surg*. 2002; 11(2):136-42.
11. Scheibel M, Lichtenberg S, Habermeyer P. Reversed arthroscopic subacromial decompression for massive rotator cuff tears. *J Shoulder Elbow Surg*. 2004; 13(3):272-8.
12. Austin L, Chang ES, Zmistowski B, Nydick J, Lazarus M.

- Isolated subscapularis repair for massive rotator cuff tear. *Orthopedics*. 2014; 37(11):e962-7.
13. Wylie JD, Beckmann JT, Granger E, Tashjian RZ. Functional outcomes assessment in shoulder surgery. *World J Orthop*. 2014; 5(5):623-33.
 14. Gerber C, Fuchs B, Hodler J. The results of repair of massive tears of the rotator cuff. *J Bone Joint Surg Am*. 2000; 82(4):505-15.
 15. Burkhart SS, Nottage WM, Ogilvie-Harris DJ, Kohn HS, Pachelli A. Partial repair of irreparable rotator cuff tears. *Arthroscopy*. 1994; 10(4):363-70.
 16. Gerber C, Maquieira G, Espinosa N. Latissimus dorsi transfer for the treatment of irreparable rotator cuff tears. *J Bone Joint Surg Am*. 2006; 88(1):113-20.
 17. Consigliere P, Polyzois I, Sarkhel T, Gupta R, Levy O, Narvani AA. Preliminary results of a consecutive series of large & massive rotator cuff tears treated with arthroscopic rotator cuff repairs augmented with extracellular matrix. *Arch Bone Jt Surg*. 2017; 5(1):14-21.
 18. Williams GR. Painful shoulder after surgery for rotator cuff disease. *J Am Acad Orthop Surg*. 1997; 5(2):97-108.
 19. Rockwood CA Jr, Williams GR Jr, Burkhead WZ Jr. Debridement of degenerative, irreparable lesions of the rotator cuff. *J Bone Joint Surg Am*. 1995; 77(6):857-66.
 20. Ellman H. Arthroscopic subacromial decompression: analysis of one- to three-year results. *Arthroscopy*. 1987; 3(3):173-81.
 21. Wiley AM. Superior humeral dislocation. A complication following decompression and debridement for rotator cuff tears. *Clin Orthop Relat Res*. 1991; 263(1):135-41.
 22. Fenlin JM Jr, Chase JM, Rushton SA, Frieman BG. Tuberoplasty: creation of an acromiohumeral articulation-a treatment option for massive, irreparable rotator cuff tears. *J Shoulder Elbow Surg*. 2002; 11(2):136-42.
 23. Verhelst L, Berghs B, Liekens KO, Schepens A, Vandekerckhove P, Vanhoonacker P. Tuberoplasty: advantages of reversed decompression-three year follow-up results in 34 patients. *Orthop Proc*. 2010; 92(Suppl 5):10.
 24. Papadopoulos P, Karataglis D, Boutsiadis A, Fotiadou A, Christoforidis J, Christodoulou A. Functional outcome and structural integrity following mini-open repair of large and massive rotator cuff tears: a 3-5 year follow-up study. *J Shoulder Elbow Surg*. 2011; 20(1):131-7.
 25. Jost B, Pfirrmann CW, Gerber C. Clinical outcome after structural failure of rotator cuff repairs. *J Bone Joint Surg Am*. 2000; 82(3):304-14.