

RESEARCH ARTICLE

Use of a Digital Protractor and a Spirit Level to Determine the Intraoperative Anteversion of Femoral Component during Cemented Hip Hemiarthroplasty: a Prospective Clinical Trial

Anuwat Pongkunakorn, MD; Patanapong Palawong, MD; Swist Chatmaitri, MD; Nawakun Phetpangnga, MD

Research performed at Lampang Hospital, Lampang, Thailand

Received: 14 August 2018

Accepted: 18 September 2018

Abstract

Background: Femoral stem anteversion during hip arthroplasty is generally estimated by eye intraoperatively and has proven to be different from targeted values. This study aims to determine the accuracy of a novel technique using a digital protractor and a spirit level to improve surgeons' estimation of stem anteversion.

Methods: A prospective non-randomized study was conducted among 93 patients with femoral neck fracture who underwent cemented hemiarthroplasty via posterolateral approach. In the control group (N=62), five experienced surgeons assessed stem anteversion related to the posterior femoral condylar plane using visual estimation with a target angle of 15°-25°. In the study group (N=31), another two surgeons assessed stem anteversion with the same target angle by placing a digital protractor on the femoral stem inserter handle while the assistant held the leg in the truly vertical position, verified by a spirit level that was attached to the shin with cable ties. Stem anteversion was measured blind, postoperatively, on 2D-CT and compared with the intraoperative results.

Results: The mean postoperative anteversion was 22.4° (-4.2° to 51.3°, SD 11.1°) in the control group and 23.0° (16.0° to 29.9°, SD 3.6°) in the study group ($P=0.810$). The study group had more stems positioned in 15°-25° anteversion (71.0% vs 32.3%, $P=0.001$) and the mean absolute value of surgeon error was -0.2° (-5.4° to 7.0°, SD 3.0°). Twenty-eight stems of the study group (90.3%) had an error within 5°. Surgeon overestimation >5° was found in 1 hip (3.2%) and underestimation >5° was found in 2 hips (6.4%).

Conclusion: Using a digital protractor and a spirit level was reliable with high accuracy and precision to improve the intraoperative estimation of cemented stem anteversion.

Level of evidence: II

Keywords: Digital protractor, Femoral stem anteversion, Hip arthroplasty, Spirit level

Introduction

Successful hip replacement surgery is associated with prosthetic design and surgical technique. Biomechanical aspects of aseptic loosening are

related to stem anteversion, prosthesis offset, stem size and body mass index (BMI) (1-4). Rotational positioning of the femoral component during surgery is decisive for

Corresponding Author: Anuwat Pongkunakorn, Department of Orthopaedic Surgery, Lampang Hospital and Medical Educational Center, Mueang District, Lampang, Thailand
Email: dranuwat@hotmail.com



THE ONLINE VERSION OF THIS ARTICLE
ABJS.MUMS.AC.IR

the degree of later posterior rotation, subsidence and aseptic loosening. The femoral prosthetic anteversion angle is believed to influence the occurrence of dislocation of an implant (5). It is generally advised to place a prosthesis within the range of 10°-30° anteversion for a cemented femoral component whereas some authors have recommended approximately 15° of anteversion for a cementless femoral component (1, 2, 6).

The traditional technique for assessing the femoral component anteversion is visual estimation by the surgeon. In the lateral decubitus position, the leg is used as a protractor in the vertical position to determine the measurement of the femoral version with respect to the tibial angle (7). Van Embden *et al* found that the mean difference between the anteversion angle estimated by this technique and the CT measurement is 9° (5). In 70% of cases the measured angle was greater than desired. Dorr *et al* found a poor precision of surgeons' estimation for the cementless femoral stem (6). They were often outside the intended zones of 10°-20° of anteversion. Some surgeons tried to improve the precision by using a manual goniometer and found the mean absolute value of surgeon error to be about 7.3° (8).

Currently the most precise technique to determine femoral stem anteversion intraoperatively is computer navigation with a precision of 5° (9). However, the proven advantages of navigation must be traded off against the argument of prolonged surgery and higher costs (10). Some investigators applied devices that enable the surgeon to aim for a predetermined target and reduced outliers significantly, such as a digital protractor to measure the operative inclination angle or a closed tube inclinometer to aim the angles of the acetabular component in total hip arthroplasty (THA) (11, 12). There has been no previous study about using these devices for femoral prosthetic implantation. This study aims to assess the precision of a digital goniometer and a closed tube inclinometer (spirit level) for improving surgeons' intraoperative estimation of femoral stem anteversion.

Materials and Methods

A prospective non-randomized study was conducted among patients with femoral neck fracture who underwent cemented hemiarthroplasty via posterolateral approach between January 2016 and December 2017. In the control group, five experienced surgeons assessed stem anteversion related to the posterior femoral condylar plane using visual estimation with a target angle of 15°-25°. In the study group, another two surgeons assessed stem anteversion with the same target angle by placing a digital protractor on the femoral broach and stem inserter handle while the assistant held the leg in the truly vertical position, verified by a spirit level that was attached to the shin with cable ties. Exclusion criteria were patients with advanced knee osteoarthritis, knee deformity with radiographic tibio-femoral angle more than 5° varus or 10° valgus, and previous ipsilateral tibial or femoral fractures.

Surgical techniques

The patients were placed in the lateral decubitus position. The leg was put in a plastic bag and stockinette. In the study group, an EKG electrode (3M Red Dot, USA) was attached to the skin overlying the medial 1/3 of the tibial tubercle. Two plastic pipe clips (Thai Pipe, Thailand) were attached to the anterior aspect of the leg with Nylon cable ties. The base of one clip was locked onto the Red Dot electrode and the other was positioned at the midpoint of the most medial and most lateral aspects of the malleoli. An aluminum pipe (Yunteng self picture monopod YT-188, China) was installed into these clips by gently pressing the pipe over the clips until the bilateral grooves of the pipe were snugly locked between the clip edges. A small spirit level (Haccury YK-3, China) was attached to the flat side of another pipe clip with cyanoacrylate glue, and then installed on the pipe by pressing the clip over the pipe that represented the anatomical axis of the tibia [Figure 1]. During femoral canal preparation, the femur was internally rotated and the knee flexed so that the tibia was perpendicular to the floor, verified by the neutral position of the bubble in the spirit level. The broach was inserted at 15°-25° of anteversion, verified by placing a digital protractor (Etopoo DC10, China) on the flat surface of the broach handle. The final anteversion angle after insertion of the femoral prosthesis and cement hardening, was measured by placing a digital protractor on the flat surface of the inserter handle [Figure 2].

In the control group, stem anteversion was assessed as

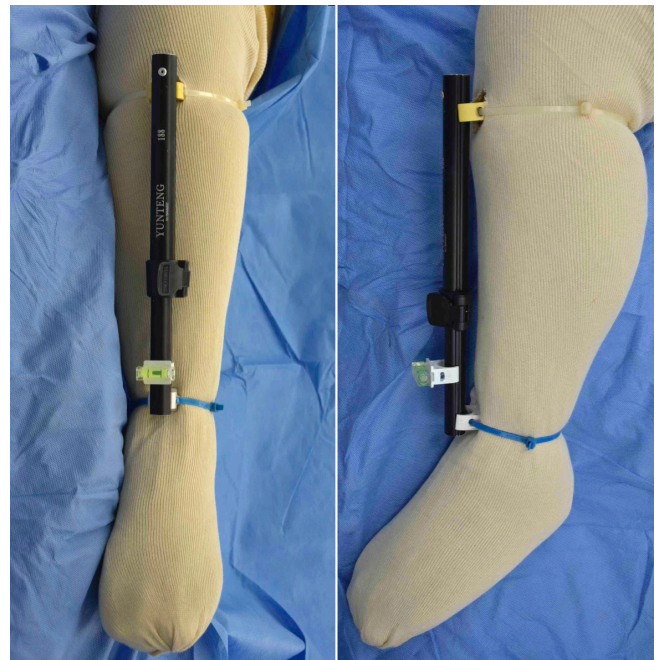


Figure 1. A spirit level was installed on an aluminum pipe that was attached to the medial 1/3 of the tibial tubercle and the intermalleolar midpoint to represent the anatomical axis of the tibia.

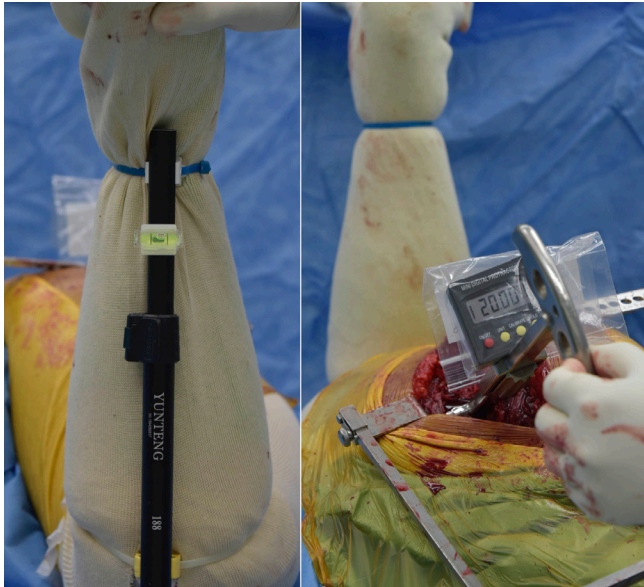


Figure 2. During femoral canal preparation, the hip was internally rotated until the tibia was perpendicular to the floor, verified by the neutral position of the bubble of spirit level. A digital protractor was placed on the flat surface of the inserter handle to verify the anteversion of 15°-25°.

the angle between the leg axis and the femoral stem axis by the surgeons' visual estimation, with a target angle of 15°-25° after flexing the knee and placing the leg in a vertical position manually. In both groups, the posterior capsule and short external rotators were repaired. Antibiotic prophylaxis was intravenous cefazolin before skin incision and at 6-hour intervals for 24-48 hours.

The sample size was calculated to detect a significant difference in percentages of stems positioned in the 15°-25° target zone of anteversion. We hypothesized that our devices could achieve this goal in 75% of cases according to the results in 12 cases of our pilot study, whereas 38% of the previous 20 hemiarthroplasties performed by five experienced surgeons in our institution using the traditional estimation technique were positioned in this goal. With a two-sided type I error level of 0.05, a 90% statistical power of detection and a group ratio of 2:1, the sample size was 62 hips in the control group and 31 in the study group.

Preoperative demographic data included patient age, gender, BMI and American Society of Anesthesiologists (ASA) physical status classification. Primary outcomes were stem anteversion angles and percentage of stems positioned in the 15°-25° zone. The femoral component was assessed by 2D-CT scan (Philips Ingenuity Core 128, Cleveland, USA) three days postoperatively. Consecutive scans were performed at 1.5-mm intervals from the acetabulum to the level of the proximal tibia. Stem version was measured as the angle between a line through the center of the neck of the femoral prosthesis and a line connecting the posterior aspect of the medial and lateral femoral condyles (7). Native anteversion of the opposite

hip was defined as the angle between the axis of the femoral neck and the posterior condylar axis. The femoral neck axis was measured as the best-fit line connecting slices taken through a central segment of the neck (13). The tibio-femoral angle of knee deformity was measured in a supine antero-posterior knee radiograph by drawing a line from the center of the tibial plateau to the midpoints of the proximal shaft of the tibia and the line from the center of intercondylar notch to the midpoints of the distal shaft of the femur.

All radiographic measurements were performed by two orthopaedic residents who were not involved with the surgery, and repeated again two weeks later. The average of four measurements was used for data analysis. The intra-class correlation coefficients (ICCs) were calculated for intra- and inter-observer reliability. We used the two-way random-effects model and absolute agreement for ICCs calculation. The Shapiro-Wilk test was used to ascertain normal distribution prior to further statistical analysis. The exact probability test was used to compare categorical data between the two groups whereas the t-test and Wilcoxon rank-sum test were used to analyze continuous data. A p-value of <0.05 was considered statistically different. The protocol was approved by the Institutional Ethics Committee (Code 42/60) and registered in the Thai Clinical Trials Registry (ID: TCTR 20180326003). Informed consent was obtained from each participant.

Results

There were 93 patients enrolled in the study. The patients' baseline characteristics were not significantly different between the two groups [Table 1]. Excia stems (Aesculap, Tuttlingen, Germany) were used in 60 cases (64.5%) and CPT stems (Zimmer Biomet, Warsaw, Indiana, USA) in 33 cases (35.5%). The mean postoperative anteversion was 22.4° (range -4.2° to 51.3°) in the control group and 23.0° (range 16.0° to 29.9°) in the study group ($P=0.810$). However, the standard deviation (SD) of the angle in the study group was significantly lower (3.6° vs 11.1°, $P<0.001$) [Chart 1]. The study group had more stems placements in the target zone of 15°-25° than the control group (71.0% vs 32.3%, $P=0.001$). Stems with anteversion <15° were found to be significantly fewer in the study group (0% vs 29%, $P<0.001$), but not different for those with anteversion >25° (29% vs 39%, $P=0.491$). The mean operative time and blood loss were not significantly different ($P=0.133$ and $P=0.153$ respectively) [Table 2].

Among 31 hips in the study group, the average intraoperative anteversion angle was 22.8° (SD 1.4°, range 20° to 25°) and the mean true anteversion angle was 23.0° (SD 3.6°, range 16.0° to 29.9°). The mean absolute value of surgeon error was -0.2° (SD 3.0°, range -5.4° to 7.0°) and 28 stems (90.3%) had an error within 5°. Surgeon overestimation >5° was found in 1 hip (3.2%). Surgeon underestimation >5° was found in 2 hips (6.4%) [Charts 2; 3]. The ICCs for intra- and inter-observer reliability of measurements were 0.978 and 0.965 for stem anteversion, 0.968 and 0.972 for native anteversion, and 0.979 and 0.977 for tibio-femoral angle, respectively.

Table 1. Patients' baseline characteristics comparing between the two groups (N=93).

Data	Control group (N=62)	Study group (N=31)	P-value
Age (year)			
mean (SD)	75.9 (7.5)	77.0 (6.9)	0.477
range	60 - 91	63 - 91	
Gender F : M	53 : 9	27 : 4	0.552
BMI (kg/sqm)			
mean (SD)	20.4 (3.1)	21.1 (3.0)	0.363
range	16.0 - 27.3	15.6 - 25.8	
ASA class N (%)			
1	1 (1.6%)	0 (0%)	1.000
2	13 (21.0%)	6 (19.4%)	
3	48 (77.4%)	25 (80.6%)	
Tibio-femoral angle *			
mean (SD)	3.8° (3.3°)	4.0° (3.4°)	0.854
range	-3.6° to 8.8°	-3.6° to 9.1°	
Native femoral anteversion **			
mean (SD)	9.1° (8.8°)	5.3° (11.0°)	0.199
range	-3.9° to 33.8°	-12.1° to 27.7°	
Stem type N (%)			
CPT (Zimmer)	22 (35.5%)	11 (35.5%)	1.000
Excia (Aesculap)	40 (64.5%)	20 (64.5%)	

* value positive represents valgus, negative represents varus alignment

** value positive represents anteversion, negative represents retroversion

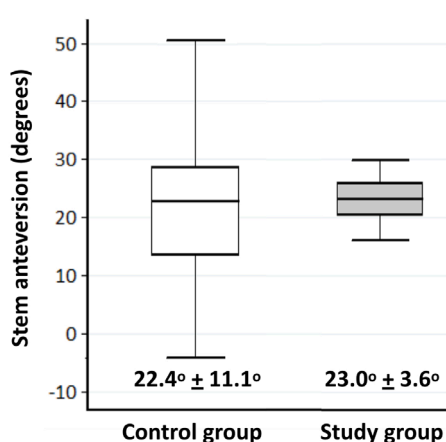


Chart 1. The values of the postoperative stem anteversion comparing between the two groups. The bar represents the range of anteversion. Box length represents the interquartile range (first to third quartiles). The line in the center of the boxes represents the median value.

Table 2. Comparison of postoperative radiographic measurements and perioperative results between the two groups (N=93).

Data	Control group (N=62)	Study group (N=31)	P-value
CT anteversion angle			
mean	22.4°	23.0°	0.810
SD	11.1°	3.6°	<0.001
IQR	13.3°, 28.7°	20.2°, 25.9°	
95% CI	19.6° - 25.2°	21.7° - 24.3°	
range	-4.2° to 51.3°	16.0° to 29.9°	
within target 15°-25° N	20 (32.3%)	22 (71.0%)	0.001
Operative time (minutes)			
mean (SD)	77.1 (13.1)	82.1 (15.4)	0.133
range	55 - 120	55 - 115	
Intraoperative blood loss (ml)			
mean (SD)	237 (136)	270 (129)	0.153
range	100 - 700	100 - 500	
Dislocation N (%)	2 (3.2%)	0 (0%)	0.551

Postoperatively, there was no surgical site infection. The average duration of follow-up was 19.1 months (SD 6.8, range 8-31). There was no hip dislocation in the study group. Two hips in the control group had posterior dislocation (3.2%) and both of them had femoral stem anteversion less than 15°. However, the dislocation rate was not significantly different between the two groups ($P=0.551$) [Table 2].

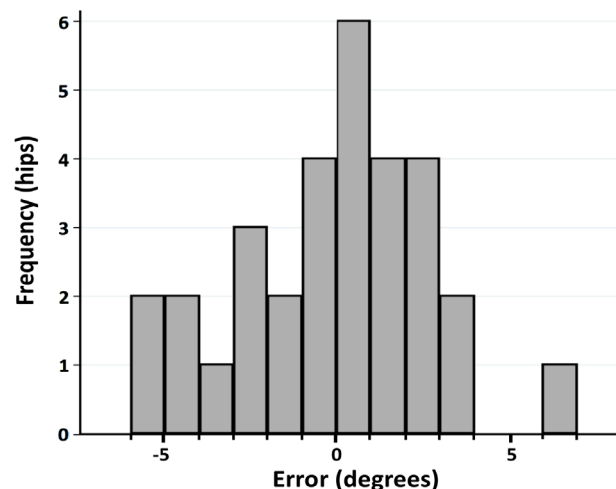


Chart 2. Distribution of errors in intraoperative estimation of the stem anteversion in the study group (N=31) by digital protractor compared with CT scan.

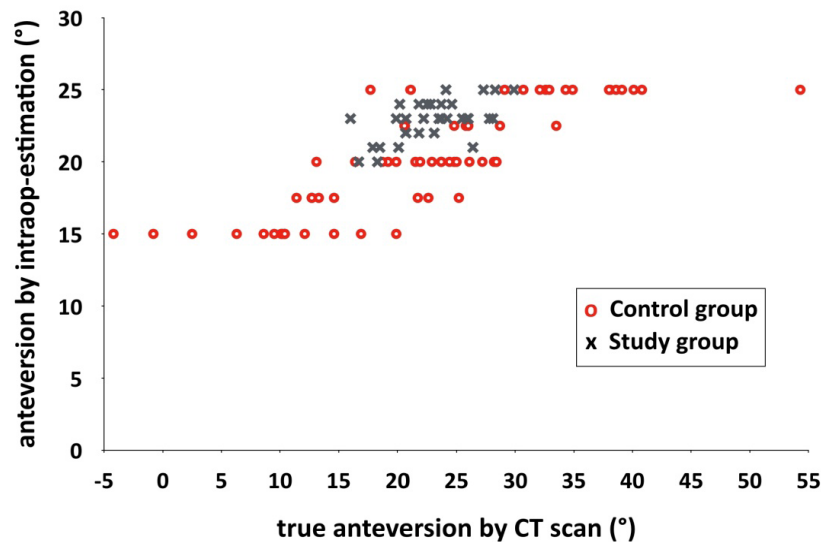


Chart 3. The scattergram showing the intraoperative estimation and true prosthetic anteversion by CT scan in both groups.

Discussion

Internal rotation with posterior head migration (PHM) is one of the most important modes of early failure of a cemented femoral stem. Femoral stem anteversion is considered to be significantly correlated with PHM and believed to affect the occurrence of postoperative dislocation (2, 5). The recommended anteversion angles for a cemented femoral component are varied. Van Embden *et al* suggested the range of 10°-20° for cemented hemiarthroplasty via anterolateral approach, whereas some authors recommended the posterolateral approach with a range of 15°-25° to reduce the number of posterior dislocations (5, 14). Implantation with <10° of anteversion is potentially harmful with the subsequent rotational migration. Kiernan *et al* found a strong correlation between postoperative anteversion and later posterior rotation (1). At one year, the <10° group showed significantly more progressive retroversion together with distal migration, and four of ten cemented stems had been revised at ten years, and additional two stems were radiologically loose. They assumed the normal anteversion group to be 10°-25° with only one revised (3%) and one loose stem (3%) of a total of 30 stems. Moreover, Gill *et al* found a correlation between low stem anteversion and PHM (2). They suggested cemented stems be placed in ≥20° anteversion and should not be >30°, as this may contribute to dislocation. Therefore, our target anteversion of 15°-25° in this study is considered to be appropriate for cemented hemiarthroplasty via posterolateral approach in the elderly with femoral neck fracture.

The baseline for the measurement of stem anteversion differed among the studies. This study used the posterior condylar axis as the baseline because it is a reliable reference for defining the neutral rotation of the femur (15). Likewise, many studies used this axis as the

reference and this has been accepted as standard (5, 7, 15). In contrast, some studies used the epicondylar axis as the baseline giving results in which the true anteversion tended to be smaller and the surgeon error tended to be larger because of the relatively external rotation of the epicondylar to the posterior condylar line (8, 9).

There are some studies which have examined the accuracy and precision of intraoperative estimation of stem anteversion in hip arthroplasty. Two studies reported results with high accuracy (low bias) but low precision (high random errors) results (7, 9). Wines and McNicol studied the intraoperative estimations by the surgeons for both cemented and cementless femoral stem in 111 hips using direct lateral and posterolateral approaches (7). The mean difference between the surgeons' intraoperative assessment and the CT measurement relative to the posterior condylar axis was an underestimation of 1.1° with an SD of 10.4° and a range of 25° underestimation to 30° overestimation. A study by Dorr *et al* found that the precision of the surgeon was 16.8° and bias was 0.2° for estimating the intraoperative anteversion of the cementless femoral stem compared with the CT measurement using the epicondylar axis as the baseline (9). The surgeons' estimations had outliers of 6° to 10° in 11 of 47 (23.4%) hips and more than 10° in 11 of 47 (23.4%). Moreover, van Embden *et al* found the average difference between the anteversion angle estimated by the surgeon during 20 cemented hemiarthroplasties and the CT-measured angle was 9° (SD 4°, range -11° to +18°) using the posterior condylar axis as the reference (5). Similarly, our findings in the control group confirmed the imprecise outcomes of this visual estimation.

Currently the most accurate technique to measure femoral stem anteversion intraoperatively is computer

navigation. Dorr *et al* found that the precision of navigation was 4.8° and bias was 0.2° (9). There were no outliers of 6° or more of stem anteversion. The previous literature had suggested that having a device that enables the surgeon to aim for a predetermined target can reduce outliers significantly. Meermans *et al* used a digital protractor to measure the operative inclination angle in 100 primary THAs and could significantly reduce the number of outliers of the acetabular component in relation to the safe zone and did not require additional operative time (11). Sykes *et al* used a closed tube inclinometer for aiming the different target angles of the acetabular cup placement on a mounted Sawbone pelvis and had no outliers for all trials compared with 78% for the freehand method and 58% for the use of a mechanical alignment guide (12).

Using a digital protractor and a spirit level as an aiming device in this study improved the precision of intraoperative estimation of femoral stem anteversion represented by the smaller SD of the angles than in the conventional method (3.6° vs 11.1°). The mean absolute error was -0.2° , range from 5.4° underestimation to 7.0° overestimation, and 90% of cases had an error within 5° . These outcomes resulted from two possible explanations. Studies have reported that the midpoint of the most medial and most lateral aspects of the malleoli was 4.5 ± 4.1 mm lateral to the center of the ankle and the medial $1/3$ of the tibial tubercle averaged 4 ± 2 mm lateral to the AP axis of the tibial component during total knee arthroplasty (16, 17). Thus, the spirit level that was attached to the anterior part of the leg in this study could represent the anatomical axis of the tibia. Nevertheless, the angle between this axis and the posterior condylar axis of the femur is 87° in the flexed knee because the tibial articular surface is approximately 3° of varus with respect to the mechanical axis in a normal knee. Using the leg as a lever to rotate the femur internally during the knee flexion until the tibia is perpendicular to the floor, the medial collateral ligament must be stretched and the medial joint space widened. Theoretically, this might correct the constitutional varus of the tibia and its anatomical axis will become perpendicular to the posterior condylar axis. While the assistant held the leg in the truly vertical position, verified by the neutral position of the bubble of the spirit level, the posterior condylar axis was parallel with the floor. With this assumption, the degree of surgeon error was significantly influenced by the grade of knee osteoarthritis (8). A varus knee tended to cause underestimation and valgus knee tended to cause overestimation of the stem anteversion. The tibio-femoral angles in the study group averaged 4° or slightly varus. Two cases with surgeon underestimation of stem anteversion $>5^\circ$ had tibio-femoral angles of -3° and -3.6° . The second explanation is the utility of the digital protractor when applied to the flat surface of the handle of the prosthesis inserter. It shows the accurate and precise degree of the prosthesis version relative to the floor and may be more practical than a manual goniometer used by Hirata *et al* (8). They measured the angle between the lower-leg axis and the trial-stem axis by flexing the knee and placing the tibia in

a vertical position. The mean surgeon error was 1.3° when using the posterior condylar line as the baseline and 7.3° when using the epicondylar line as the baseline with an SD of 5.7° .

Posterior dislocation occurred in two hips in the control group. Both of them had femoral stem anteversion of 14.6° . Among these, the postoperative global femoral offset compared with the opposite side was 20% decreased in one case and might lessen the soft-tissue tension around the operated hip and predispose to dislocation (18, 19). We found no significant difference of dislocation rate between the two groups and this might be from the inadequate sample size. The calculated sample size with 80% power to compare this outcome at the same dislocation rate requires 300 hips in each group. Nevertheless, this study has a power of 93% (type 1 error 5%) to detect the outcome of anteversion target zone outlier.

There are some limitations in this study. Firstly, it was not a randomized study and so might be biased by the patient allocation. However, the demographic data in both groups were not significantly different, especially for the native femoral anteversion and tibia-femoral angles that play important roles during the anteversion assessment. Secondly, the surgeons who estimated the angles in both groups were not the same ones and so the results might be biased by surgeon experience. In any event, all hemiarthroplasties in both groups were performed by experienced surgeons who had passed the learning curve of such operations more than 50 cases previously. All of them tried their best to implant the stems in the desired target zones. Finally, the knee alignment of the patents in this study was slightly valgus without any cases of moderate or severe malalignment. The precise estimation in the study group might not be applicable to those with advanced osteoarthritis. To the best of our knowledges, this is the first clinical study that uses a digital protractor and a spirit level to determine the intraoperative anteversion of the femoral component during hip arthroplasty.

Using a digital protractor and a spirit level could improve the precision of stem anteversion assessment in cemented hip hemiarthroplasty. It can be used with different stem handles from different companies in the lateral decubitus position. Most femoral stems were placed within a narrow margin inside the desired target angle.

Acknowledgements

The authors wish to thank Andrew Sherratt for his help in approving the English language use.

Anuwat Pongkunakorn MD
Patanapong Palawong MD
Swist Chatmaitri MD
Nawakun Phetpangnga MD
Department of Orthopaedic Surgery, Lampang Hospital
and Medical Educational Center, Mueang District,
Lampang, Thailand

References

1. Kiernan S, Hermann KL, Wagner P, Ryd L, Flivik G. The importance of adequate stem anteversion for rotational stability in cemented total hip replacement: a radiostereometric study with ten-year follow-up. *Bone Joint J.* 2013; 95-B(1):23-30.
2. Gill HS, Alfaro-Adrián J, Alfaro-Adrián C, McLardy-Smith P, Murray DW. The effect of anteversion on femoral component stability assessed by radiostereometric analysis. *J Arthroplasty.* 2002; 17(8):997-1005.
3. Olofsson K, Digas G, Kärrholm J. Influence of design variations on early migration of a cemented stem in THA. *Clin Orthop Relat Res.* 2006; 448(1):67-72.
4. Flugsrud GB, Nordsletten L, Espehaug B, Havelin LI, Meyer HE. The effect of middle-age body weight and physical activity on the risk of early revision hip arthroplasty: a cohort study of 1,535 individuals. *Acta Orthop.* 2007; 78(1):99-107.
5. van Embden D, van Gijn W, van de Steenhoven T, Rhemrev S. The surgeon's eye: a prospective analysis of the anteversion in the placement of hemiarthroplasties after a femoral neck fracture. *Hip Int.* 2015; 25(2):127-30.
6. Dorr LD, Wan Z, Malik A, Zhu J, Dastane M, Deshmane P. A comparison of surgeon estimation and computed tomographic measurement of femoral component anteversion in cementless total hip arthroplasty. *J Bone Joint Surg Am.* 2009; 91(11):2598-604.
7. Wines AP, McNicol D. Computed tomography measurement of the accuracy of component version in total hip arthroplasty. *J Arthroplasty.* 2006; 21(5):696-701.
8. Hirata M, Nakashima Y, Ohishi M, Hamai S, Hara D, Iwamoto Y. Surgeon error in performing intraoperative estimation of stem anteversion in cementless total hip arthroplasty. *J Arthroplasty.* 2013; 28(9):1648-53.
9. Dorr LD, Malik A, Dastane M, Wan Z. Combined anteversion technique for total hip arthroplasty. *Clin Orthop Relat Res.* 2009; 467(1):119-27.
10. Eingartner C. Current trends in total hip arthroplasty. *Orthop Traumatol Rehabil.* 2007; 9(1):8-14.
11. Meermans G, Goetheer-Smits I, Lim RF, Van Doorn WJ, Kats J. The difference between the radiographic and the operative angle of inclination of the acetabular component in total hip arthroplasty: use of a digital protractor and the circumference of the hip to improve orientation. *Bone Joint J.* 2015; 97-B(5):603-10.
12. Sykes AM, Hill JC, Beverland DE, Orr JF. A novel device to measure acetabular inclination with patients in lateral decubitus. *Hip Int.* 2012; 22(6):683-9.
13. Sugano N, Noble PC, Kamaric E. A comparison of alternative methods of measuring femoral anteversion. *J Comput Assist Tomogr.* 1998; 22(4):610-4.
14. Hsu A, Blomberg J. Femoral neck fracture cemented bipolar hemiarthroplasty. *Lineage Medical.* Available at: URL: <http://www.orthobullets.com/approaches/12087/hip-cemented-hemiarthroplasty>; 2018.
15. Turley GA, Ahmed SM, Williams MA, Griffin DR. Validation of the femoral anteversion measurement method used in imageless navigation. *Comput Aided Surg.* 2012; 17(4):187-97.
16. Siston RA, Daub AC, Giori NJ, Goodman SB, Delp SL. Evaluation of methods that locate the center of the ankle for computer-assisted total knee arthroplasty. *Clin Orthop Relat Res.* 2005; 439(1):129-35.
17. Howell SM, Chen J, Hull ML. Variability of the location of the tibial tubercle affects the rotational alignment of the tibial component in kinematically aligned total knee arthroplasty. *Knee Surg Sports Traumatol Arthrosc.* 2013; 21(10):2288-95.
18. Mukka S, Lindqvist J, Peyda S, Brodén C, Mahmood S, Hassany H, et al. Dislocation of bipolar hip hemiarthroplasty through a postero-lateral approach for femoral neck fractures: a cohort study. *Int Orthop.* 2015; 39(7):1277-82.
19. Emami M, Manafi A, Hashemi B, Nemati A, Safari S. Comparison of intertrochanteric fracture fixation with dynamic hip screw and bipolar hemiarthroplasty techniques. *Arch Bone Jt Surg.* 2013; 1(1):14-7.