

## RESEARCH ARTICLE

# Iliac Pedicle Wedge Graft as a New Modification for Iliac Osteotomies in Young Adolescents: A Single-blind Randomized Clinical Trial

Mohsen Karami, MD; Alireza Radyn Majd, MD; Mohammad A. Tahririan, MD; Sajad Badiei, MD; Amin Karimi, MD

Research performed at Taleghani Hospital, Tehran, Iran

Received: 16 August 2017

Accepted: 11 July 2018

## Abstract

**Background:** Iliac osteotomies in adolescent patients may accompany graft related difficulties such as graft absorption and delayed union. A new modification of iliac osteotomies has been proposed to address these difficulties.

**Methods:** A total of 24 consecutive hip joints in 21 juvenile or adolescent patients who were candidate for salter or triple pelvic osteotomy were included. A modification was performed to harvest a wedged bone graft based on a muscle pedicle of Tensor Fascia Lata and inserted at pelvic osteotomy site instead of a traditional graft technique. The hips were randomized into two groups. The traditional wedge graft was used in group 1, while the new modification was performed in group 2. The primary outcome of this study was duration of union. The secondary outcomes were Center Edge Angle (CE) Angle on pre-operation, immediately post-operation and at the end of follow-up.

**Results:** Both groups were similar statistically regarding their age, gender, estimated blood loss and the duration of follow-up. However, significant differences were found in the time to complete union between the two groups ( $P=0.03$ ). CE angle decreased in both groups when comparing its last follow-up to its right postoperative values, but the decrease was significant only in group 1 ( $P=0.03$ ). The type of surgery (Salter or TPO) had no significant effect on the average time to union. That shows faster union in pedicle graft group and less coverage loss during follow-up period than conventional graft patients.

**Conclusion:** With the modification proposed, the healing at the osteotomy site was faster and the loss of correction, owing to the graft resorption, decreased. Using this pedicle wedge graft technique may improve the results of pelvic osteotomies in adolescent.

**Level of evidence:** II

**Keywords:** Complication, Pelvic osteotomy, Surgical technique

## Introduction

Persistent acetabular dysplasia and Legg-Calvé-Perthes (LCP) disease are well-known causes of early hip osteoarthritis (1, 2). In a dysplastic hip, stress loading occurs at the edge of the steep and shallow acetabulum (3). Pelvic osteotomies reduce this load by increasing the contact area, relaxing the capsule and

muscles around the hip, improving its moment arm, and normalizing the forces of weight bearing (4). An orthopedic surgeon can choose a pelvic osteotomy (e.g., redirection, reshaping, or salvage) to restore normal anatomy and biomechanical forces around the hip joint. Treatment of residual dysplasia or coverage issues is

**Corresponding Author:** Mohammad A. Tahririan, Department of Orthopaedics, School of Medicine, Isfahan University of Medical Sciences, Isfahan, Iran  
Email: tahririan@med.mui.ac.ir



THE ONLINE VERSION OF THIS ARTICLE  
ABJS.MUMS.AC.IR

based on the patient's age and the presence or absence of congruent hip reduction. A Salter procedure is generally appropriate for children between the ages of 2 to-10 (5). A triple pelvic osteotomy (TPO) can be considered for older children or adolescents in whom the triradiate cartilage remains open. Most of these procedures like Salter innominate and triple pelvic osteotomies, need a wedge or trapezoidal bone graft from the iliac bone. In previous studies, non-union has not been reported for Salter osteotomy site but reported at pubis or ischial ramus for TPO. Graft resorption has been reported in older or adolescent patients (6). In order to improve the union at osteotomy site, spica cast can be helpful, but the use of spica cast is not well tolerated by older patients.

In this randomized clinical trial, a new modification "pedicle wedge graft" was introduced using infor pelvic osteotomies in older patients and the results were compared with traditional wedge graft.

## Materials and Methods

### Participants and Study design

This prospective single-blind randomized clinical trial was conducted on 24 consecutive hips in 21 juvenile or adolescent patients (aged 6-16 years) who were candidate for Salter innominate or triple pelvic osteotomy from January 2013 to March 2016. Patients older than 6 years who needed a pelvic redirection osteotomy (Salter or TPO) and had a concentric hip reduction with 25-30° abduction and neutral rotation, reasonable congruity of the hip joint surfaces and a good range of hip motion were included in the study. Patients with paralytic hip subluxation; age>16; previous history of major surgery in the surgical site; and those who did not show up for the follow-ups were excluded from the study. Eligible patients were allocated into two groups through simple randomization; in the traditional technique group (group1), non-pedicle wedge graft was harvested to insert at iliac osteotomy site, whereas in the pedicle wedge graft group (group 2), a muscle pedicle graft was harvested using Tensor Fascia Lata (TFL) muscle.

According to the flexibility of the iliac osteotomy site, the single senior surgeon decided which osteotomy should have been done. Provided that the osteotomy site is enough pliable to insert a triangular graft, a Salter osteotomy is the best option, otherwise, TPO is the choice.

### Surgical technique and intervention

All surgeries were performed under general anesthesia with a standard regimen which was done by an anesthesiologist. Intravenous cefazolin (EXIR®, Iran) 25 mg/kg with maximal dose of 1 gram was administered an hour before the surgery.

All operations were performed electively by a single skilled pediatric orthopedic surgeon, the senior author (M.K.). The patient was positioned supine on the operating table with the thorax on the affected side elevated by a radiolucent sandbag. The whole lower extremity to the trunk on the affected side was prepared. The adductor muscles were released by open tenotomy. A bikini skin incision was made beginning inferior to the middle of the iliac crest and extending to about the

middle of the inguinal ligament. Dissection was done between the tensor fasciae latae muscle laterally and the sartorius and rectus femoris medially, to expose the anterior superior iliac spine. TFL and gluteal muscles fascia were separated from the iliac apophysis with sharp incision (the muscles stayed attached to the iliac bone). A deep incision using scalpel was made beneath the iliac apophysis along the crest from the posterior end of the skin incision to the anterior superior iliac spine anteriorly and then turning distally to the anterior inferior iliac spine [Figure 1.A.]. The iliac apophysis was reflected towards the medial side together with the interior periosteum from the medial surface of the iliac crest in a continuous sheet. Using power saw from the interior surface of the iliac bone, a triangular graft was harvested by cutting its vertical base from 1.5 cm posterior to the anterior superior iliac spine (ASIS) and then an oblique cut from the lower leg of the vertical cut towards the postero-superior, which was completed on the upper border of the iliac bone [Figure 1.B.]. The cut bone with attached TFL muscle was then released from the surrounding muscle fibers long enough to be inserted in the osteotomy site [Figure 1.C.]. Then Salter type osteotomy or TPO was completed by Gigli or power saw and after displacing the distal portion of the osteotomy site, the pedicle wedge graft was inserted at the osteotomy site and fixed using pins or screws [Figure 1.D.]. The skin was sutured with a continuous subcuticular technique. The osteotomy site of patients who were 8 years or less (eight patients) were fixed by multiple pins and the others were fixed by screws.

For conventional graft harvesting, the patient positioning and approach were the same but the graft was harvested with no muscle pedicle using power saw from the iliac crest.

A single spica cast was applied for patients who had pin fixation at the osteotomy site. The spica cast was removed four weeks after surgery and the patients were encouraged to partially bear weight until complete union of the osteotomy site was detected.

### Measurements

The duration of the procedure as well as the amount of bleeding was recorded for both groups. Radiographic evaluation was performed on a standing anteroposterior (AP) pelvic X-ray pre and postoperatively and then 4 and 8 weeks after the procedure. If the healing was not evident, X-ray was repeated every 4 weeks until complete union. A pelvic X-ray was also obtained at the last follow-up visit. Radiographic angle measurements were made using Surgimap software (version 2.2.3, Nemaris Inc, USA). Union at the iliac osteotomy site was evaluated at two points: the bone graft side (outer portion of the osteotomy site) and arcuate line (inner portion of the osteotomy site) [Figure 2]. Union was considered complete when bony trabeculae crossed both portions of the osteotomy site. Hip coverage was measured by the lateral center-edge (CE) angle (normal, >20 degrees) of Wiberg (7). The CE angle was considered as an index to measure graft resorption at the osteotomy site. Heterotopic ossification was graded according to the

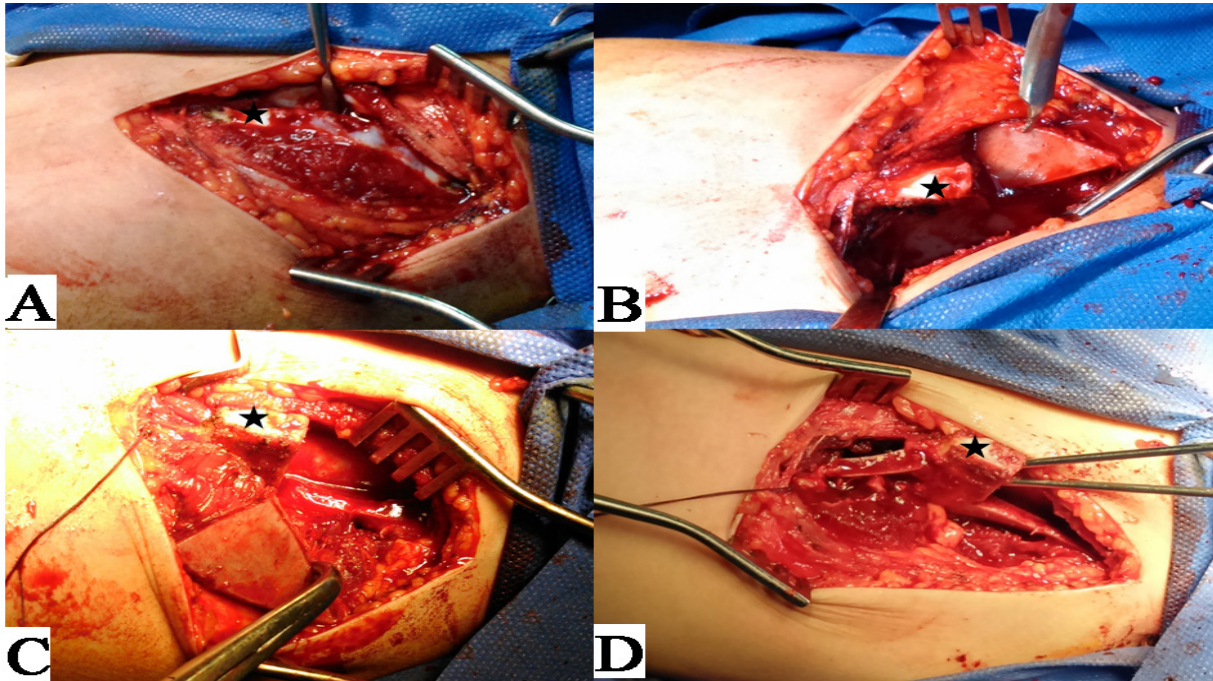


Figure 1. Surgical technique. "Star" locates Anterior Superior Iliac Spine (ASIS). A. reflection of abdominal muscles along with iliac apophysis toward medial side. B. the wedge graft was harvested by power saw. C. The bone with attached muscle is released from the surrounding muscle fibers. D. Pedicle graft is inserted at the osteotomy site and fixed using pins.

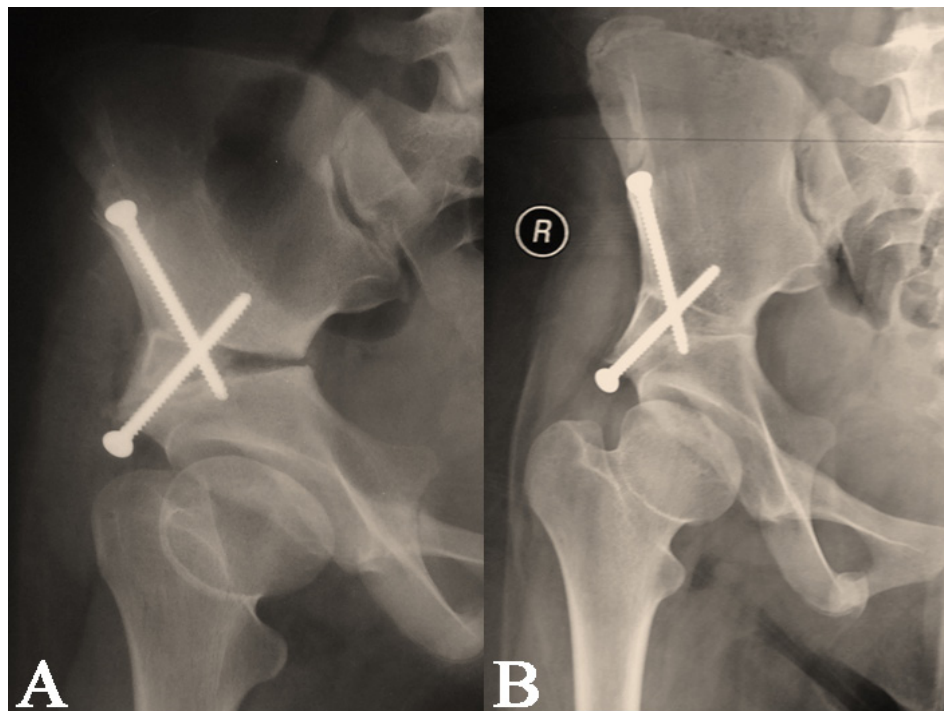


Figure 2. A. Union at osteotomy site; 50% when the outer portion is healed. B. complete union, when the whole osteotomy line is healed.



**Table 1. The comparison of demographic features between non-pedicle wedge graft group with pedicle wedge graft group**

| Variables                              |        | non-pedicle wedge graft group | pedicle wedge graft group | P-value* |
|--|--------|-------------------------------|---------------------------|----------|
| Gender                                 | Male   | 6 (50%)                       | 7 (58%)                   | 0.69 **  |
|  | Female | 6 (50%)                       | 5 (42%)                   |          |
| Age at the time of surgery [years old] |        | 10.72 ± 3.30                  | 9.61 ± 2.74               | 0.38 *   |
| Diagnosis                              | DDH    | 6 (50%)                       | 3 (25%)                   | 0.42 **  |
|  | LCP    | 5 (42%)                       | 8 (67%)                   |          |
|  | MED    | 1 (8%)                        | 1 (8%)                    |          |
| Side of Surgery                        | Right  | 8 (66%)                       | 4 (34%)                   | 0.11 **  |
|  | Left   | 4 (34%)                       | 8 (66%)                   |          |
| Type of Surgery                        | S.O.   | 8 (66%)                       | 9 (75%)                   | 0.50 **  |
|  | T.P.O. | 4 (34%)                       | 3 (25%)                   |          |

Data expressed as mean ± SD and Number (Percent).

P-values calculated by \*Independent sample t-test, and \*\*Chi-square. \* P-value lesser than 0.05 ( $P < 0.05$ ) is significant.

classification described by Brooker et al. (8).

All patients as well as the person who analyzed data were blind to this study. The surgeon and person who recorded measurements were aware of the study, but it did not seem to have had any confounding effect on the results.

### Demographics

There were 24 hips in twenty-one patients (three bilateral involvement), including 13 hips in male patients (54%) and 11 in females (46%) [Figure 3]. The average age at the time of surgery was 10.2 ± 3 years. The youngest patient was six years and one month old, and the oldest was sixteen years. Nine hips were dysplastic (37.5%), 13 hips were diagnosed as LCP (54.2%), and two hips (one patient) were affected in multiple epiphyseal dysplasia. Post-operative hemi-spica cast was applied for only 8 patients (30%). Three patients in this series had previous surgical treatments which included varization osteotomy (3 hips) and open reduction of the hip (1 hip). The average surgical time was 57.64±6.64 minutes for the Salter osteotomy, and 60.71±6.72 minutes for the TPO ( $P=0.31$ ). The estimated blood loss was 194.7±19.2 mL for the Salter osteotomy and 197.14±26.43 mL for TPO ( $P=0.80$ ). These results include total surgical time and estimated blood loss only for pelvic osteotomies and no other combined procedures. Two hips underwent a concomitant intertrochanteric osteotomy through a direct lateral surgical approach. The two groups were statistically homogeneous in terms of age ( $P=0.38$ ), gender ( $P=0.69$ ), and side of surgery ( $P=0.11$ ) [Table 1].

### Statistical analysis

Nonprobability sampling was done to select patients were scheduled for pelvic osteotomy admitted to a teaching tertiary referral hospital (Taleghani Educational hospital, affiliated by Shahid Beheshti University of Medical sciences in Tehran, Iran). According to previous studies, the sample size was calculated by using two

means comparison formulas for at least 12 hips in each group (2, 3). The patients in the two groups underwent operation by the same orthopedic surgeon after general anesthesia.

Qualitative variables were compared using Chi-square tests. Quantitative variables had normal distribution and were compared using Independent sample t-test and one-way ANOVA. All data are presented as mean±SD. The significance level was set at  $P < 0.05$ .

Written informed consent was obtained from the parents for each child at the beginning of the study. The protocol of this study was approved by the review board and also the ethics committee of Shahid Beheshti University of Medical Sciences (Project No. 82.M, Ethics No. IR.SBMU.MSP.REC.1395.76).

### Results

In all patients, complete union was detected in all patients in average of 70.9±35.6 days (range, 28-183 days). The patients were followed for 19.9±7.9 months (range: 12.29-48 months). The CE angle was 15.7±10.6° (range: 0-40°) pre-operatively; 31.96±8.554 right immediately after surgery (range: 12-45°). The angle measured at the last follow-up was 30.5±8.2° (range, 12-46°).

In the non-pedicle wedge graft group, the most frequent diagnosis was dysplastic hip (6 hips, 50%). Salter osteotomy was done on 8 hips (66.7%). Comparing the immediate post-operative with the last follow-up, CE angle revealed a significant decrease from 27.6° to 26.4° ( $P=0.03$ ) although this amount is clinically non-significant.

In pedicle wedge graft group, the most frequent diagnosis was LCP in 8 hips (66.7%). Salter osteotomy was performed in 9 hips (75%); however, the immediate post-operative CE angle showed a non-significant decrease from 36.2 to 34.7 compared to the last follow-up ( $P=0.1$ ).

The outcomes of pedicle and non-pedicle wedge graft

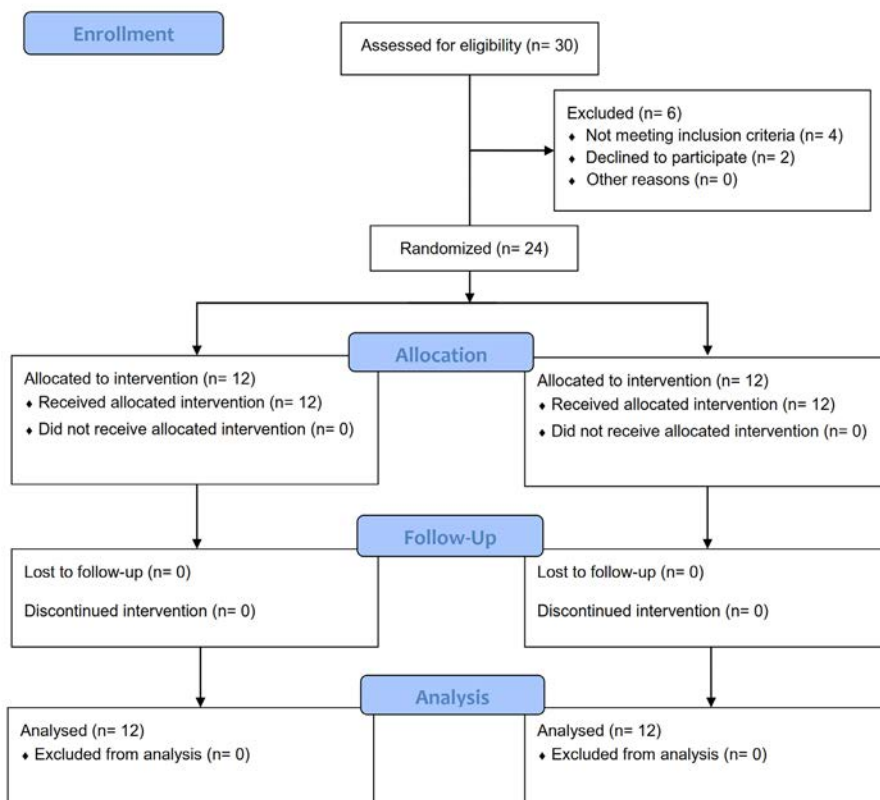


Figure 3. Patient flowchart.

Table 2. The comparison of surgical features between non-pedicle wedge graft group with pedicle wedge graft group

| Variables  | non-pedicle wedge graft group | pedicle wedge graft group | P-value* |
|--|-------------------------------|---------------------------|----------|
| Duration of Surgery [minute]                           | 60.41 ± 6.20                  | 56.66 ± 6.85              | 0.17     |
| The estimated blood loss [milliliter]                  | 194.7 ± 19.2                  | 198.75 ± 20.46            | 0.43     |
| Time to complete union [day]                           | 86.4 ± 41.2                   | 55.4±20.6                 | 0.03     |
| Preoperative Center Edge Angle [degree]                | 11.67 ± 10.12                 | 19.75 ± 9.94              | 0.06     |
| Immediately after operation Center Edge Angle [degree] | 27.67 ± 8.26                  | 36.25 ± 6.68              | 0.01     |
| Postoperative Center Edge Angle [degree]               | 26.41 ± 7.78                  | 34.66 ± 6.66              | 0.01     |
| Final Follow-up Center Edge Angle [degree]             | 21.18 ± 9.59                  | 18.67 ± 6.01              | 0.45     |
| Duration of Follow-up [month]                          | 21.18 ± 9.58                  | 18.67 ± 6.01              | 0.45     |

Data are presented as mean ± standard deviation.

\* P-value lesser than 0.05 ( $P < 0.05$ ) is significant. P-values are calculated by One-Way ANOVA.

groups are compared in Table 2. The mean time to complete union was significantly different between the two groups ( $P = 0.03$ ). There was no significant difference in duration of follow-up, and the estimated blood loss between the two groups ( $P=0.45$  and  $P=0.43$  respectively). There was a non significant difference in preoperative CE Angle between the groups ( $P=0.06$ ), while mean

postoperative and final follow-up CE Angles were significantly more in the pedicle wedge graft group ( $P=0.01$  for both).

CE angle decreased in both groups when comparing its last follow-up to its right postoperative values, but the decrease was clinically non-significant. The type of surgery (Salter or TPO) had no significant effect on the

average time to union [Table 2].

One case of heterotopic ossification type 1 was detected at the wedge graft but patient's hip range of motion was not adversely affected.

### Discussion

Acetabular dysplasia and hip incongruency are present in a large number of patients undergoing treatment for DDH and Legg-Calve-Perthes disease. Comparing to younger children adolescent age features a lower biological remodeling and healing potential, hence more attention is needed to choose a reliable technique to have better bone healing. Currently, Salter osteotomy and TPO are two pelvic osteotomies that are commonly performed to treat developmental dysplasia of the hip and LCP disease in pediatric patients (2, 7). The advantage of Salter osteotomy is that it is easy to understand and perform once the principles are learned. Several authors reported excellent and good mid and long term results with Salter osteotomy. Salter and Dubos reported good or excellent results of 93.6% by Severin's classification, after Salter surgery in patients under four years of age, and 56.7% for those treated between the ages of four and ten years, after an average follow-up period of 5.5 years (8). Loss of correction and graft resorption at the osteotomy site may be the most probable reason for less favorable results in older children. Roth et al. also reported that 100% of 12 hips in patients 1.5 to 4 years of age with Salter surgery for congenitally dislocated hip but 80% of 25 hips in patients 1.5 to 16 years of age with secondary treatment for residual dislocation or subluxation had excellent or good results after an average of 5.4 years follow-up. In older children, the osteotomy site is stiffer and may put more pressure on the wedge graft that might affect the results of surgery (9). In this study, it revealed that follow-up CE angles decreased but this decrement was significant in non-pedicle graft group. That means using pedicle wedge graft can be a good solution to prevent this effect. In addition, our study showed faster union in pedicle graft group that enabled us to have more confidence on our post-operative management. In other words, we used shorter period of crutch walking in group 2 patients.

The method of evaluation have to be enough reliable to assess the improvement of CE angle (10, 11). The CE angle of Wiberg shows the degree of lateral femoral head coverage by the acetabulum in the frontal plane. Inter-observer CE angle measurement is not reliable enough to evaluate its improvement, but intra-observer is reliable in children (10, 11). In this study, we compare the mean and difference of CE angles in different times of evaluation between non pedicle and pedicle wedge graft groups by one examiner to decrease inter-observer errors.

Unsurprisingly, other complications may occur with Salter osteotomy. The complications can be studied as early and late postoperative ones. Immediate postoperative ones are superficial and deep wound infection, wound dehiscence and retroperitoneal hematoma. Rossillon et al. demonstrated distinct hypoplasia of the ilium due to premature growth arrest in 16 out of 21 patients who had unilateral pelvic

osteotomy (12). We didn't encounter such complication in our patients, but one type 1 heterotopic ossification was noticed in our patients but the hip range of motion was completely normal. Loss of correction is also reported due to crushing of the bone graft which is due to the osteoporosis of disuse atrophy, operating on children <18 months of age or premature removal of Kirschner wires. It can also be due to excessive pressure on the graft in older patients. Graft displacement or dislocation can be secondary to poor surgical technique, inadequate fixation or migration of Kirschner wires and the incidence ranges between 0-19% (3, 4, 13). In the present study, the loss of correction has been measured by changing the CE angle right after surgery and at last follow-up X-rays which was more significant in non-pedicle graft group ( $P=0.03$ ). It means using a pedicle wedge graft can be considered as an efficient means to prevent loss of correction even in adolescent patients.

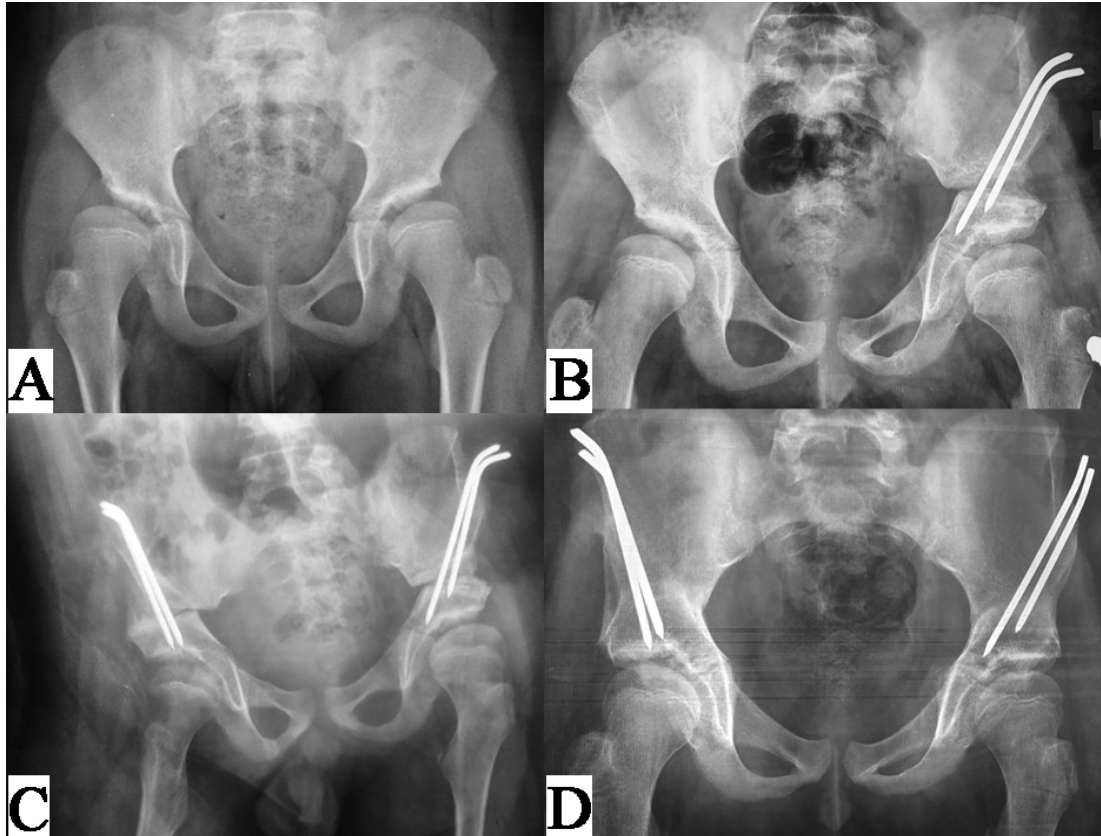
The other complication is pseudoarthrosis. For triple osteotomy, non-union has been reported as 2.6% at the pubis osteotomy and 6.6% of both pubic and ischial bones (4, 14). Other authors reported similar and even worse results, and also cases of painful pseudoarthrosis of the pubis that had to be operatively managed. The incidence has been reported to be in positive correlation with age (4, 6, 14, 15). Non-union at ilium has also been reported for triple osteotomy (16). In one of the patients, her left side was operated for Salter osteotomy using traditional graft technique. Three months later, her right side was operated for Salter osteotomy using a pedicle wedge graft. Surprisingly, the union on the right side was faster and was completed before left side osteotomy healed [Figure 4].

The benefit of our technique was early union at the iliac osteotomy site. The average time to complete union at the iliac osteotomy site was 55.4 days, this made us able to remove spica cast at 4 weeks and patients started weight bearing with crutches right after the surgery in which screw fixation was performed.

The rate of pseudoarthrosis was reported to be higher with complex osteotomies (16-18). Studies on periacetabular osteotomy in adults have described nonunion rates ranging from 1 to 6% (14, 16-18). These non-unions are frequently symptomatic and often require operative intervention (1, 9, 19, 20). All patients in this study were in pediatric age group, so it was not possible to compare the results to adult patient.

There are many modifications which were proposed for Salter or triple osteotomy (21-22). These modifications are designed primarily to address the limitations of the osteotomy mainly, inherent instability of the osteotomy necessitating internal fixation and later pin removal, and lengthening of the ipsilateral lower extremity. Kalamchi et al. described the removal of a wedge shaped bone from the proximal edge of osteotomy and lodging of the distal fragment to this notch, thereby preventing posterior and medial displacement of the osteotomy (21).

The modification of the present study included using a pedicle wedge graft to get faster union at the osteotomy site in older children. In younger children probably,



**Figure 4.** A. A 10 y-old girl who had bilateral hip dysplasia, on right side, open reduction has been done at age 1, her left side was operated for Salter osteotomy using traditional graft technique. B. her pelvic X-rays 3 months post-operatively. Then, her right side was operated for Salter osteotomy again using a pedicle wedge graft. C. one month after the second surgery and 4 months after the first. D. shows complete union at both sides 5 month after the first procedure.

there is no concern about bone healing at fracture site and using long period of spica cast is acceptable, but in older children, this modification decreased the duration of casting to 4 weeks. Loss of correction which may be as a result of graft desorption was less likely to happen when using a pedicle wedge graft in older children ( $P=0.01$ ).

In summary, Salter and triple osteotomies are reasonable techniques in the treatment of developmental dysplasia of the hip and LCP disease. There are several options to correct acetabular dysplasia in patients with developmental dysplasia of the hip and LCP. Each osteotomy has unique advantages and none of them is absolutely superior to another. But most of them need a wedge graft to be put at the osteotomy site. With the new modification of the present study, healing at the osteotomy site will be faster and loss of correction due to graft resorption will be decreased comparing to traditional graft method. Using this pedicle wedge graft may improve

the results of pelvic osteotomies in older patients.

Mohsen Karami MD  
Alireza Radyn Majd MD  
Amin Karimi MD

Department of Orthopaedics, School of Medicine, Shahid Beheshti University of Medical Sciences, Tehran, Iran

Mohammad A. Tahririan MD  
Department of Orthopaedics, School of Medicine, Isfahan University of Medical Sciences, Isfahan, Iran

Sajad Badiei MD  
Department of Orthopaedics, School of Medicine, Isfahan University of Medical Sciences, Isfahan, Iran  
Students Research Committee (Center), Isfahan University of Medical Sciences, Isfahan, Iran



## References

1. Baki C, Sener M, Aydin H, Yildiz M, Saruhan S. Single-stage open reduction through a medial approach and innominate osteotomy in developmental dysplasia of the hip. *J Bone Joint Surg Br.* 2005; 87(3):380-3.
2. Pailhé R, Cavaignac E, Murgier J, Cahuzac JP, de Gauzy JS, Accadbled F. Triple osteotomy of the pelvis for Legg-Calve-Perthes disease: a mean fifteen year follow-up. *Int Orthop.* 2016; 40(1):115-22.
3. Barrett WP, Staheli LT, Chew DE. The effectiveness of the Salter innominate osteotomy in the treatment of congenital dislocation of the hip. *J Bone Joint Surg Am.* 1986; 68(1):79-87.
4. Utterback JD, MacEwen GD. Comparison of pelvic osteotomies for the surgical correction of the congenital hip. *Clin Orthop Relat Res.* 1974; 98(1):104-10.
5. Salter RB. The classic. Innominate osteotomy in the treatment of congenital dislocation and subluxation of the hip by Robert B. Salter, J. Bone Joint Surg. (Brit) 43B:3:518, 1961. *Clin Orthop Relat Res.* 1978; 137(1):2-14.
6. Denton JR, Ryder CT. Radiographic follow-up of Salter innominate osteotomy for congenital dysplasia of the hip. *Clin Orthop Relat Res.* 1974; 98(1):210-3.
7. Wenger DR, Pring ME, Hosalkar HS, Caltoun CB, Lalonde FD, Bastrom TP. Advanced containment methods for Legg-Calvé-Perthes disease: results of triple pelvic osteotomy. *J Pediatr Orthop.* 2010; 30(8):749-57.
8. Salter RB, Dubos JP. The first fifteen year's personal experience with innominate osteotomy in the treatment of congenital dislocation and subluxation of the hip. *Clin Orthop Relat Res.* 1974; 98(1):72-103.
9. Roth A, Gibson DA, Hall JE. The experience of five orthopedic surgeons with innominate osteotomy in the treatment of congenital dislocation and subluxation of the hip. *Clin Orthop Relat Res.* 1974; 98(1):178-82.
10. Clohisy JC, Carlisle JC, Trousdale R, Kim YJ, Beaulé PE, Morgan P, et al. Radiographic evaluation of the hip has limited reliability. *Clin Orthop Relat Res.* 2009; 467(3):666-75.
11. Upasani VV, Bomar JD, Parikh G, Hosalkar H. Reliability of plain radiographic parameters for developmental dysplasia of the hip in children. *J Child Orthop.* 2012; 6(3):173-6.
12. Rossillon R, Desmette D, Rombouts JJ. Growth disturbance of the ilium after splitting the iliac apophysis and iliac crest bone harvesting in children: a retrospective study at the end of growth following unilateral Salter innominate osteotomy in 21 children. *Acta Orthop Belg.* 1999; 65(3):295-301.
13. Coleman SS. The incomplete pericapsular (Pemberton) and innominate (Salter) osteotomies; a complete analysis. *Clin Orthop Relat Res.* 1974; 98(1):116-23.
14. Ito H, Ooura H, Kobayashi M, Matsuno T. Middle-term results of Salter innominate osteotomy. *Clin Orthop Relat Res.* 2001; 387(1):156-64.
15. Böhm P, Brzuske A. Salter innominate osteotomy for the treatment of developmental dysplasia of the hip in children: results of seventy-three consecutive osteotomies after twenty-six to thirty-five years of follow-up. *J Bone Joint Surg Am.* 2002; 84(2):178-86.
16. Huang SC, Hwang YF, Liu HC, Chen PQ, Liu TK. Triple innominate osteotomy and rotational acetabular osteotomy in the treatment of congenital hip dysplasia. *J Formos Med Assoc.* 1997; 96(2):91-7.
17. Gür E, Sarlak O. The complications of Salter innominate osteotomy in the treatment of congenital dislocation of hip. *Acta Orthop Belg.* 1990; 56(1 Pt B):257-61.
18. Karakaş ES, Baktir A, Argün M, Türk CY. One-stage treatment of congenital dislocation of the hip in older children. *J Pediatr Orthop.* 1995; 15(3):330-6.
19. Lin CJ, Lin YT, Lai KA. Intraoperative instability for developmental dysplasia of the hip in children 12 to 18 months of age as a guide to Salter osteotomy. *J Pediatr Orthop.* 2000; 20(5):575-8.
20. Thawrani D, Sucato DJ, Podeszwa DA, DeLaRocha A. Complications associated with the Bernese periacetabular osteotomy for hip dysplasia in adolescents. *J Bone Joint Surg Am.* 2010; 92(8):1707-14.
21. Kalamchi A. Modified Salter osteotomy. *J Bone Joint Surg Am.* 1982; 64(2):183-7.
22. Zerrog B, al-Zahrani S, Ali AA. Modified Salter's innominate osteotomy. *J R Coll Surg Edinb.* 1998; 43(4):262-4.