

TECHNICAL NOTE

Tibial Tunnel Preparation in Posterior Cruciate Ligament (PCL) Reconstruction. A Technical Tip to Lessen the Stress

S.M. Javad Mortazavi, MD; Ahmad Ramezanpoor Asl, MD; Hamed Jafari, MD; Hojjat Asgari, MD; Mohamad H. Kaseb, MD; Mohammad J. Dehghanifiroozabadi, MD

Research performed at Joint Reconstruction Research Center, Tehran University of Medical Sciences, Tehran, Iran

Received: 21 May 2018

Accepted: 19 November 2018

Abstract

Background: The purpose of this study was to introduce a technical tip for the preparation of tibial tunnel in a posterior cruciate ligament (PCL) reconstruction to reduce the chance of popliteal artery injury and duration of the surgery.

Methods: This study included 18 patients who underwent PCL reconstructions at Imam Khomeini University Hospital, Tehran, Iran, between 2016 and 2017. In all patients, the PCL tibial aimer device was inserted from the anteromedial portal and its tip aimed 8-9 mm below shiny white fibers in PCL facet. Subsequently, the smooth guide pin was inserted from anteromedial tibial cortex and advanced just to the posterior cortex but not through it based on the measurement of tibial tunnel length. Thereafter, the reaming was done over the guide pin. As the pin was engaged in the posterior cortex, it was assured that it would not run before the reamer to the popliteal fossa. The pin was removed when the reamer touched the posterior cortex, and the reaming continued until reamer's head appeared in the PCL facet. Other steps of standard arthroscopic PCL reconstruction were done in this study. All patients were subjected to computed tomography scans.

Results: The mean age of the patients and the mean duration of surgery were 25 ± 3 years and 95 min, respectively. There was no vascular injury, and the position of the tibial tunnel in all cases was accurate. Moreover, the mean distance between the centers of the tibial tunnel to champagne-glass drop-off of the posterior cortex of tibia was obtained at 7.42 mm (range: 4.6-10.4 mm).

Conclusion: This study showed that avoiding the penetration of posterior cortex of the tibia by means of the pin during tibial tunnel preparation for PCL reconstruction is a safe, reproducible, and time-saving technique. This technique eliminates the need for fluoroscopy during the procedure.

Level of evidence: IV

Keywords: Arterial injury, Neurovascular injury, Posterior cruciate ligament reconstruction, Tibial tunnel

Introduction

Posterior cruciate ligament (PCL) reconstruction is indicated in the patients with grade III PCL injuries and failed nonoperative treatment in patients with combined ligament injuries involving the PCL (1). The number of PCL reconstructions is increasing due to

the improvements in the surgical techniques for PCL reconstruction (1). One of the most feared complications during tibial preparation for PCL reconstruction is popliteal artery injury (2). Although it is an extremely rare complication, it is a serious and possibly fatal one

Corresponding Author: S.M. Javad Mortazavi, Joint Reconstruction Research Center, Tehran University of Medical Sciences, Tehran, Iran
Email: smjmort@yahoo.com



THE ONLINE VERSION OF THIS ARTICLE
ABJS.MUMS.AC.IR

(2). Several techniques have been described in the literature to decrease the risk of vascular injury during PCL reconstruction, including direct visualization, intraoperative imaging, posteromedial safety incision to protect the neurovascular with fingertip, and the entrance of the guide pin lateral to the tibial tuberosity (3-5).

In this study, a modified technique was reported for tibial tunnel preparation to reduce the popliteal artery injury risk while preserving the accurate position of the tunnel.

Materials and Methods

This study included 18 patients who underwent PCL reconstructions at Imam Khomeini University Hospital affiliated to Tehran University of Medical Sciences, Tehran, Iran, between 2016 and 2017. Each patient was subjected to a computed tomography scan with standard sagittal and coronal views in 1-2 days postoperatively to evaluate the tibial tunnel placement [Figure 1]. The distance between the center of the tibial tunnel to champagne-glass drop-off (CGD) in the posterior cortex of tibia was measured in this study [Figure 2] (6). The main focus was the precision of the tibial tunnel placement in the sagittal plane. However, the location of the tibial tunnel exit was evaluated on coronal views to confirm its mediolateral position in the PCL facet.

Surgical Technique

Each patient was placed in the supine position under

general anesthesia, and the affected knee joint was flexed at 90 degrees. First, a standard arthroscopic examination of the knee joint was performed using the anterolateral and anteromedial portals. After a complete examination of the intra-articular pathologies in the knee joint, the arthroscope was redirected toward the posteromedial (PM) compartment from the anterolateral portal through the intercondylar notch with 90 degrees of knee flexion. In a PCL-deficient knee, it is easy to pass the arthroscope from the anterolateral portal to the PM compartment through the intercondylar notch due to the widened space between the PCL and the medial femoral condyle.

Thereafter, the PM portal was made in the point that calf muscles intersect hamstring muscle [Figure 3-A]. A shaver was introduced via the PM portal to clean the PCL fovea [Figure 3-B]. The PCL tibial aimer was inserted from the anteromedial portal and the tip was placed 8-9 mm below shiny white fibers in PCL facet [Figure 4]. Subsequently, a lens was entered through a posteromedial portal to determine the anatomic location of PCL. With the use of an aimer guide, the length of tibial tunnel is determined and the drill stopper would adjust accordingly [Figure 5].

To confirm the exit point of the guide pin, the medial, lateral, and posterior edges of the PCL fovea were palpated using a guide tip. A small and longitudinal skin incision was made at the medial side to the tibial tuberosity after confirming its placement. Afterward, a smooth guide pin was inserted from the anteromedial

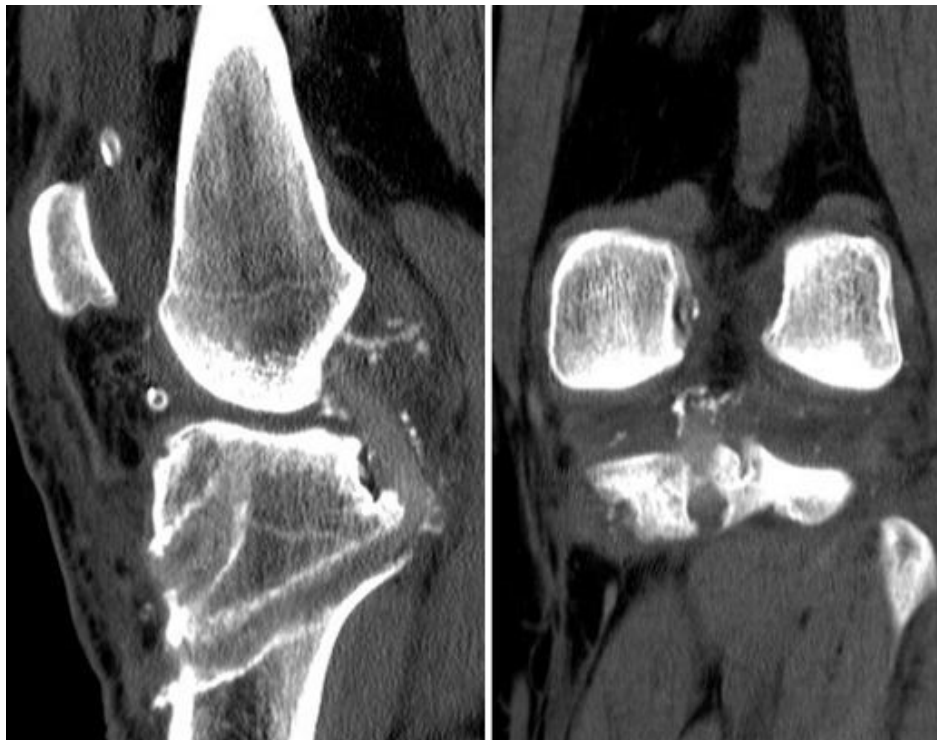

Figure 1. Distance between the center of the tibial tunnel to CGD was measured.

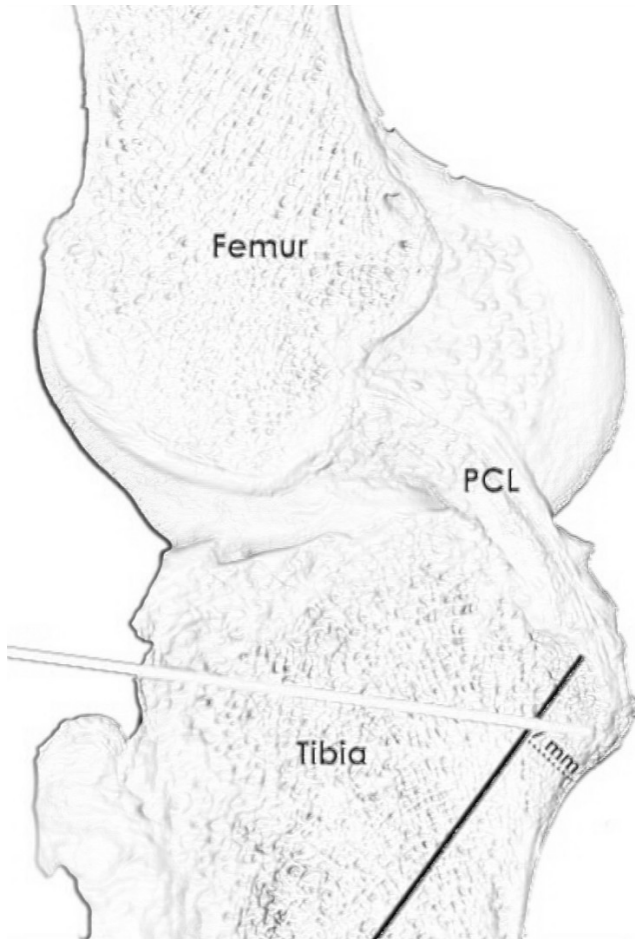


Figure 2. The guide wire should be placed 7 mm anterior to CGD.

tibial cortex, approximately 3-4cm below the joint line. The pin was angled at 55 degrees to the tibia and advanced to the posterior cortex but not through it. The pin was stopped just a little bit before reaching the aimer stopper and it was not allowed to go through the posterior cortex; therefore, the pin was placed to reach the posterior cortex; however, it did not touch or pass it [Figure 6].

In the next stage, the reaming was started and stopped just before going through the posterior cortex [Figure 7]. The reamer was moved repeatedly in and out on the pin to make sure the pin did not get stuck in the reamer while reaming. The reaming was continued to reach the size of a measured tibial tunnel, then the guide pin was extracted without removing the reamer. Eventually, the reaming continued until it came out of the posterior cortex gradually under a direct vision. It is believed that passing the reamer through posterior cortex could be viewed and sensed much easier and more predictable than the pin [Figure 8].

The reamer was stopped just when its head appeared in the PCL facet. An angle curette or hook protector of the tibial guide should be positioned to protect any neurovascular structures during the process of reaming. The danger of pin passing the posterior cortex and the possibility of vascular injury is eliminated using this technique. Finally, the rasp was used to create a smooth acute angle at the anterior margin of the tibial tunnel.

Further standard steps of arthroscopic PCL reconstruction were performed afterward. The guide pin for the PCL femoral tunnel was inserted 7 to 8 mm posteriorly to the distal border of the articular cartilage of the medial femoral condyle, which was between the 1- and 2-o'clock positions in a right knee and between the 10- and 11-o'clock positions in a left knee. Then, a tunnel was made through the medial femoral condyle using a cannulated drill with an inside-out method.

The tibialis posterior allograft was used as the PCL graft. The graft was folded into a 2-strand graft (9-10

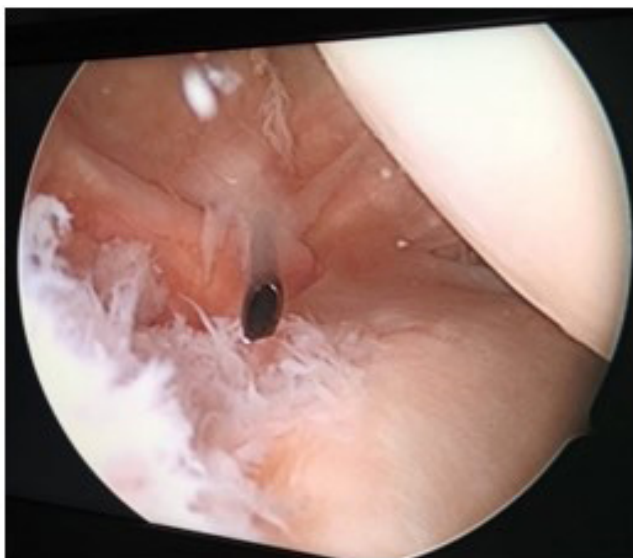


Figure 3-A. PM portal.

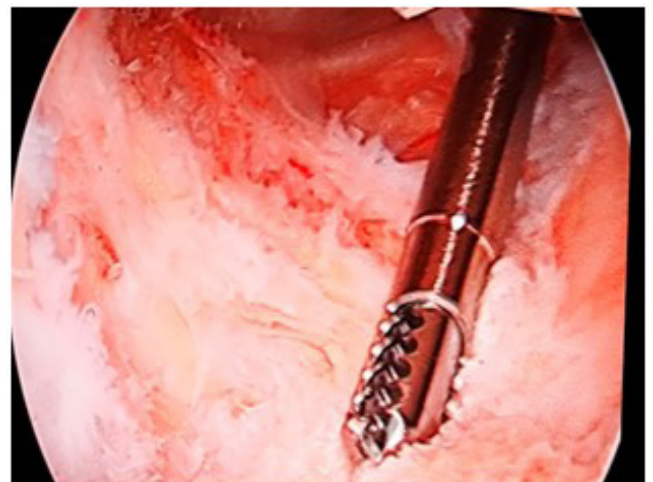


Figure 3-B. Shaver via the PM portal.

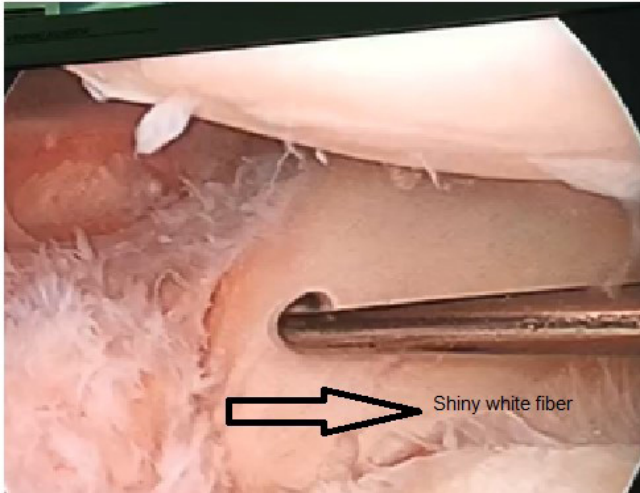

Figure 4. Tip of tibia aimer was placed 8-9 mm below shiny white fibers in PCL facet.

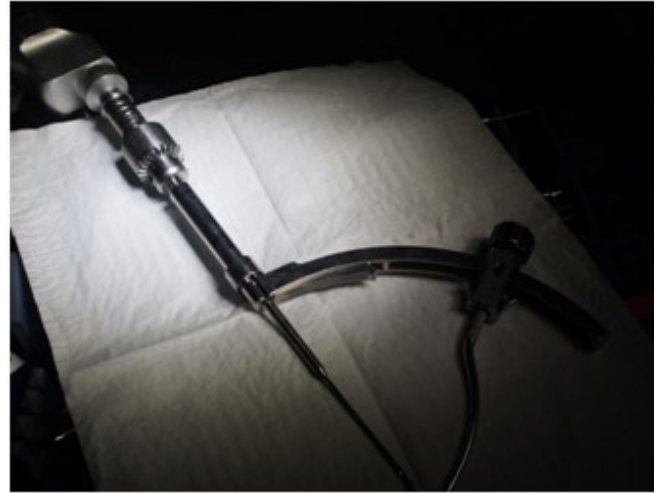

Figure 5. Drill stopper would adjust according to length of tibial tunnel.




Figure 6. Stop the pin just a little bit before reaching the aimer stopper.

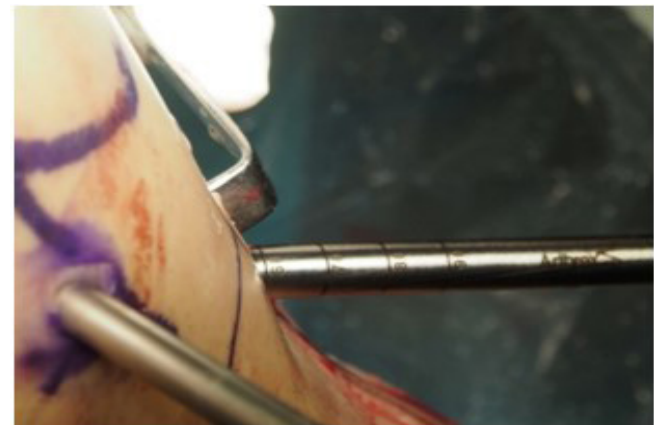


Figure 7. Reaming stopp just before going through posterior cortex.

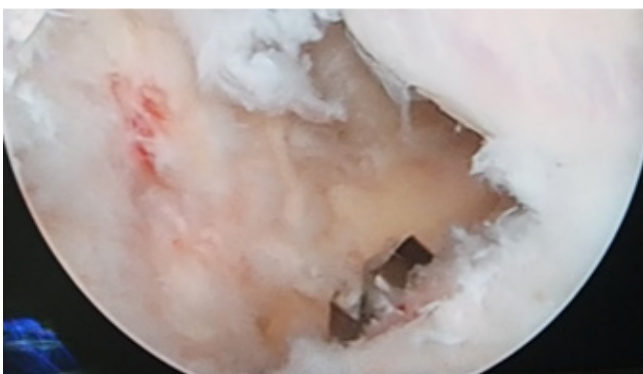


Figure 8. Passing reamer through posterior cortex could be viewed and sensed much easier and more predictable than pin.

mm in diameter and 14-15 cm in length). The end of each strand was sutured in a whipstitch fashion with a

No. 2 vicryl suture. Subsequently, the graft was passed through the tunnel sand. The femoral side was fixed by endobutton and the tibial side was fixed using an absorbable screw with proper tension.

Results

A total of 18 patients underwent PCL reconstruction surgery during a period of 12 months. All the patients were operated by the same surgeon and the same surgical technique. The mean age of the patients and the mean duration of surgery were 25 ± 3 years and 95 min, respectively. All of the tunnels were in the boundaries of PCL facet in the coronal plane. The mean distance between the center of the tibial tunnel to CGD (7) was 7.42 mm (range: 4.6-10.4 mm). There was no reported neurovascular injury following surgery.

Discussion

The PCL is one of the four main ligaments of the knee

among anterior, medial, and lateral cruciate ligaments, which is important in flexion and rotatory stability of the knee (6, 7). A torn ligament is responsible for a posterior drawer sign as well as the rotatory instability in knee flexion (7). Multiple surgical techniques have been proposed in order to correct this pathology (7).

One of the most feared complications of PCL reconstruction is an injury to the popliteal artery (8, 9). There are some case reports mentioning vascular injury which need vascular intervention (2, 9). The mean distance between the popliteal artery and the posterior tibial cortex is less than 8 mm (10). Although the popliteal artery moved away from the tibial surface during flexion in 76% of cases, the flexed knee does not always confer safety (2). The vascular injury usually occurs in three situations, namely during drilling the tibial hole, shaving and manipulation of the tissues in the posterior capsule, and creating the posteromedial portal (4).

Occasionally, the vascular injury could be a delayed-forming pseudoaneurysm or arteriovenous fistula which is not observed in the operation and the patient refers with pain and swelling signs (11).

Anatomic localization of the popliteal artery is lateral to the central axis in 94% of the cases, and the artery passes posterior to the popliteus tendon and posterior horn of the lateral meniscus (12).

Knee flexion is not always safe because the popliteal artery moved away from tibial during flexion only in 76% of cases (12). It is very important for PCL reconstruction to create the tibial tunnel exactly in its anatomical location (i.e., the center of the tunnel must be 7mm away from the top of the CGD) (6, 13). The placement of the tibial tunnel in the right anatomic position is associated with the risk of popliteal artery injury. There are several methods to reduce the risk of surgery, including the direct visualization of PCL fovea landmarks and the drill bit exiting the bone, the utilization of C-arm fluoroscopy and posteromedial safety incision, and insertion of the guide pin lateral to the tibial tuberosity (3, 4, 14, 15).

Although these techniques are used widely, each has its own drawbacks. Intraoperative C-arm fluoroscopy is usually used for the placement of the tibial tunnel guide pin during transtibial PCL reconstruction. However, intraoperative fluoroscopic identification of the tibial insertion area of the PCL is often impaired by tibial rotation and overlapping anatomic structures (3, 14). Meanwhile, there is a risk of contamination and radiation exposure in addition to being time-consuming and costly (7).

In a direct visualization of PCL fovea landmark technique, the tip of the pin is viewed in the anatomical location via the posteromedial portal (16, 17). This technique might be an alternative method to the fluoroscopic imaging technique for locating the anatomic tibial tunnel during transtibial PCL reconstruction. The sloping central depression between the medial and lateral portions of the tibial plateau has been called PCL fovea, facet, or fossa (16, 17). This technique is acceptable; however, the disadvantages include the risk of the movement of the

pin during the operation and diminished vision quality due to the scar tissue.

Another method is the use of safety incision to protect the tip of the pin with a finger; however, there are still worries about passing the pin next to the finger in addition to the risk of penetrating injury to the surgeon's finger and imposing an extra incision to the patient (15).

In a cadaveric study, it was revealed that placing the entrance of the tibial tunnel lateral to tibia tuberosity would reduce the probability of vascular injury; nonetheless, it seems not to be an assuring method (5).

Ideally, the tunnel placement should be centered one-quarter of the total facet length anterior to the posterior cortex of the tibia (7). The guidewire should be placed 7 mm anterior to CGD of the posterior cortex of the tibia as measured along the PCL facet to achieve an anatomic insertion during a PCL reconstruction (7). The placement of the tibial tunnel in the anterior surface of the facet might put the posterior horns of both menisci at risk of injury (18).

The placement of the tunnel more posteriorly will fail to reproduce anatomic characteristics of the PCL, endanger the neurovascular bundle, and make graft passage more difficult (6). Therefore, the definition of reliable and arthroscopically identifiable anatomic landmarks would be of great value for proper positioning of the tibial guide pin in an arthroscopic transtibial PCL reconstruction. The margin of the PCL fovea can be palpated with the tip of the tibial guide. Shiny white fibers of the posterior horn of medial menisci, the posterior cortex, and the medial and lateral borders of the PCL fovea are landmarks for the anatomic positioning of the tibial tunnel assisting us to place the guide pin approximately 7 mm anterior to CGD of the posterior cortex [Figure 8] (3, 7, 13).

These landmarks are time-saving and not affected by tibial rotation and overlapping anatomic structures as it appears in fluoroscopic images (3). Furthermore, additional equipment is required for the intraoperative fluoroscopic images which could increase the cost, risk of contamination, and radiation exposure.

One of the limitations of this study was the small sample size. It was a retrospective case series of a technically challenging surgery with a learning curve. Therefore, the results can be improved with more experienced surgeons and time. In addition, since the follow-up period was short, future follow-ups are necessary to evaluate the long term outcome of the procedure. Our study showed that avoiding the penetration of posterior cortex of the tibia by means of the pin during tibial tunnel preparation for PCL reconstruction is a safe, reproducible, and time-saving technique. There is no need to utilize fluoroscopy during this procedure using this technique. Moreover, it is believed that this new technique provides a safe and accurate approach to create a tibial tunnel while maintaining the proper anatomical location. Additionally, it eliminates the concern of vascular injury and reduces radiation exposure as well as the risk of contamination. Moreover, it is time-saving and

reproducible.

Future studies with long term results and larger population are required to improve the techniques that eliminate the need for fluoroscopy during tibial tunnel preparation with improved outcomes.

Conflicts of Interest: The authors declare no conflict of interest regarding the publication of this study.

S.M. Javad Mortazavi MD
Ahmad Ramezanpoor Asl MD
Hamed Jafari MD
Hojjat Asgari MD
Mohamad H. Kaseb MD
Mohammad J. Dehghanifiroozabadi MD
Joint Reconstruction Research Center, Tehran University of Medical Sciences, Tehran, Iran

References

- Moorman CT 3rd, Murphy Zane MS, Bansai S, Cina SJ, Wickiewicz TL, Warren RF, et al. Tibial insertion of the posterior cruciate ligament: a sagittal plane analysis using gross, histologic, and radiographic methods. *Arthroscopy*. 2008;24(3):269-75.
- Spiridonov SI, Slinkard NJ, LaPrade RF. Isolated and combined grade-III posterior cruciate ligament tears treated with double-bundle reconstruction with use of endoscopically placed femoral tunnels and grafts: operative technique and clinical outcomes. *J Bone Joint Surg Am*. 2011;93(19):1773-80.
- Girgis FG, Marshall JL, Monajem A. The cruciate ligaments of the knee joint. Anatomical, functional and experimental analysis. *ClinOrthopRelat Res*. 1975; 106(1):216-31.
- Makino A, Costa-Paz M, Aponte-Tinao L, Ayerza MA, Muscolo DL. Popliteal artery laceration during arthroscopic posterior cruciate ligament reconstruction. *Arthroscopy*. 2005;21(11):1396.
- Johannsen AM, Anderson CJ, Wijdicks CA, Engebretsen L, LaPrade RF. Radiographic landmarks for tunnel positioning in posterior cruciate ligament reconstructions. *AmJSports Med*. 2013;41(1):35-42.
- Chahla J, von Bormann R, Engebretsen L, LaPrade RF. Anatomic posterior cruciate ligament reconstruction: state of the art. *Joint DisordOrthop Sports Med*. 2016; 1(5):292-302.
- Lee YS, Ko TS, Ahn JH, Kang SG, Choi UH, Elazab A, et al. Comparison of tibial tunnel techniques in posterior cruciate ligament reconstruction: C-arm versus anatomic fovea landmark. *Arthroscopy*. 2016; 32(3):487-92.
- Cenni MH, do Nascimento BF, Carneiro GG, de Andrade RC, Pinheiro Júnior LF, Nicolai OP. Popliteal artery injury during posterior cruciate ligament reconstruction. *Rev BrasOrtop*. 2015;50(3):348-51.
- Zawodny SR, Miller MD. Complications of posterior cruciate ligament surgery. *Sports MedArthrosc Rev*. 2010;18(4):269-74.
- de Araujo Goes RF, Filho AC, de Oliveira Castro GN, Loures FB, Da Palma IM, Kinder A, et al. Magnetic resonance study on the anatomical relationship between the posterior proximal region of the tibia and the popliteal artery. *Rev BrasOrtop*. 2015;50(4):422-9.
- Xu D, Ji L, Zhu J, Xie Y. Popliteal pseudoaneurysm and arteriovenous fistula after arthroscopic anterior and posterior cruciate ligament reconstruction: a case report. *IntJSurg Case Rep*. 2017;40(1):50-3.
- Keser S, Savranlar A, Bayar A, Ulukent SC, Özer T, Tuncay Ib. Anatomic localization of the popliteal artery at the level of the knee joint: a magnetic resonance imaging study. *Arthroscopy*. 2006;22(6):656-9.
- Anderson CJ, Ziegler CG, Wijdicks CA, Engebretsen L, LaPrade RF. Arthroscopically pertinent anatomy of the anterolateral and posteromedial bundles of the posterior cruciate ligament. *J Bone Joint Surg Am*. 2012;94(21):1936-45.
- Fanelli GC, Orcutt DR, Edson CJ. The multiple-ligament injured knee: evaluation, treatment, and results. *Arthroscopy*. 2005;21(4):471-86.
- Piontek T, Ciemniowska-Gorzela K, Szulc A, Naczek J, Wardak M, Trzaska T, et al. Arthroscopically assisted combined anterior and posterior cruciate ligament reconstruction with autologous hamstring grafts-isokinetic assessment with control group. *PLoS One*. 2013;8(12):e82462.
- Kim MS, Koh IJ, Choi YJ, In Y. Posterior cruciate ligament reconstruction with retrograde femoral technique, posterior trans-septal portal and full tibial tunnel. *ArthroscTech*. 2017;6(4):e973-8.
- LaPrade CM, Smith SD, Rasmussen MT, Hamming MG, Wijdicks CA, Engebretsen L, et al. Consequences of tibial tunnel reaming on the meniscal roots during cruciate ligament reconstruction in a cadaveric model, part 2: the posterior cruciate ligament. *AmJSports Med*. 2015;43(1):207-12.
- Francozi CE, Albertoni LJ, Ribeiro FN, Moscon AC, Munhoz Mde A, Krause R, et al. A simple method to minimize vascular lesion of the popliteal artery by guidewire during transtibial posterior cruciate ligament reconstruction: a cadaveric study. *Arthroscopy*. 2014;30(9):1124-30.