

RESEARCH ARTICLE

Various Dosages of BMP-2 for Management of Massive Bone Defect in Sprague Dawley Rat

Achmad Fauzi Kamal, MD, PhD; Othdeh Samuel Halomoan Siahaan, MD; Jessica Fiolin, MD

Research performed at Department of Nutrition and Department of Pathological Anatomy of Faculty of Medicine Universitas Indonesia /Cipto Mangunkusumo Hospital, Jakarta, Indonesia

Received: 06 December 2017

Accepted: 03 November 2018

Abstract

Background: BMP-2 has a crucial role in the treatment of extensive bone defect. However, data about the optimal dosage of BMP-2 in the massive bone defect cases is rare.

Methods: Twenty-five SD rats were randomly allocated into a control group of hydroxyapatite (HA) alone (Group I), HA+BMP-2 1 µg/mL (Group II), HA+BMP-2 5 µg/mL (Group III), HA+BMP-2 10 µg/mL (Group IV), and HA+BMP-2 20 µg/mL (Group V). Osteotomies were performed in each group with 10 mm bone defect in the right femur, followed by fixation and filling the defect. The fracture healing was evaluated by histomorphometry, and radiographs using RUST score.

Results: We found there were significant differences in the mean total area of callus between the treatment groups ($P < 0.001$); there were significant differences in the mean area of woven bone between group II, III, IV, and V with the control group (respectively $P = 0.009$, $P = 0.016$, $P = 0.009$ and $P = 0.016$), the area of the cartilage between the treatment groups and control group (respectively $P = 0.009$, $P = 0.009$, $P = 0.009$ and $P = 0.028$). A statistically significant difference was found in the average area of fibrosis between group II and control group, group IV and control group (respectively $P = 0.047$ and $P = 0.009$). RUST scores showed significant differences between the control group and group II, III, IV, V (respectively $P = 0.005$, $P = 0.006$, $P = 0.005$ and $P = 0.006$).

Conclusion: The administration of BMP-2 stimulates the formation of bone bridging in a massive bone defect. The bone bridging filling massive bone defect depends on the dose or concentration of BMP-2. Administration of an optimal dose (10 µg/mL) of BMP-2 demonstrates better result than lower or higher dose for massive bone defect healing in SD rat.

Level of evidence: II

Keywords: BMP-2, Fracture healing, Massive bone defect, Optimum dose

Introduction

Management of massive bone defect has been a challenging problem for orthopedic surgeons (1, 2). Besides the complexity of treatment regimens, massive bone defect also has a significant morbidity on the long run (2). Currently, there are

various interventions available for orthopedic surgeons in managing massive bone defect, such as autograft, allograft, and transplantation with synthetic bone substitutes (3). Autograft remains the gold standard for managing massive bone defect, however graft substitutes

Corresponding Author: Achmad Fauzi Kamal, Department of Orthopaedic and Traumatology, Cipto Mangunkusumo National General Hospital, Faculty of Medicine Universitas Indonesia, Jakarta, Indonesia
Email: fauzikamal@yahoo.com



THE ONLINE VERSION OF THIS ARTICLE
ABJS.MUMS.AC.IR

and/or delivery of osteoinductive proteins, for example bone morphogenetic protein (BMP) family, are other considerable alternatives with proven efficacy in bone regeneration (1, 3).

There have been reports concerning the disadvantages of allograft transplantation such as the risk of disease transmission, poor osteoinductivity, incomplete or delayed graft incorporation and potential for eliciting a deleterious immune response (3). In order to avoid these difficulties regarding autograft and allograft, several synthetic bone substitutes, for instance, calcium phosphate cement, hydroxyapatite (HA) and biodegradable polymers have been developed (4, 5). Furthermore, the above mentioned synthetic bone substitutes, deliver advantages in the aspect of availability, sterility and reduced morbidity at the graft site (3).

Special skills and novel techniques along with recent knowledge are necessary for creating an effective healing (2). Although new advances in technology have broadened the alternative treatment strategies, these recent advances have been dreary, complicated and sometimes non-feasible (4, 5).

In cases of critically sized (massive) bone defect where the osteoinductive and osteoconductive components have been lost, a good bone regeneration properties could not be achieved without the application of osteogenic and osteoinductive materials (5). There are three complementary elements in the process of bone healing and these are: osteoconductive matrix, osteoinductive signal and osteogenic cells when combined together with mechanical fixation could enhance a positive osteoinductive and adequate blood flow (6).

Example of an osteoinductive agent that could be rapidly absorbed is bone morphogenetic protein-2 (BMP-2) and demineralized bone matrix (DBM) (2,4). The application of BMP-2 in a massive bone defect management plays a vital role in the proliferation, differentiation and inhibition of various cells acting in the microcellular environment and interacts with many regulatory factors (7-9). BMP-2 plays a role in the process of osteogenesis and chondrogenesis and inhibits osteoclastogenesis via the RANKL signaling (10). Several studies have suggested the increase of BMP-2 doses will accelerate the rate of bone healing up to an optimum dose which rate will go into plateau (4-6). This study aims to evaluate the effect of differences in various BMP-2 doses on the healing of the fracture with massive bone defects.

Materials and Methods

This is an experimental study in white Sprague Dawley (SD) rats with post-test control group design. All procedures conducted in the study were permitted by the ethical commission in our institution. The SD rats were aged 3-4 months, weighed 250-350 grams, were of male gender, and had no physical disability. Twenty-five SD rats were randomly allocated into five different groups. Group I (control group) went through segmental osteotomy of the femur which resulted in 10 mm bone defect, followed by internal fixation with K-wire and

application of HA to fulfill the bone defect. Similar procedures were conducted in group II to group V with additional administration of 1 mL rhBMP-2 in each group with 1 ug/mL, 5 ug/mL, 10 ug/mL, and 20 ug/mL dosage to HA for group II-V respectively at the bone defect site [Figure 1].

Surgical procedures

The SD rats were anesthetized using an intraperitoneal injection of ketamine 80 mg/kg body weight and xylazine 10 mg/kg body weight. Through anterolateral approach, biceps femoris and vastus lateralis muscles were retracted from femoral bone, however the periosteum was maintained intact. Segmental osteotomy with its periosteum of 10 mm in length was performed using a manual saw at mid-diaphysis of the femur. Additionally, through the intercondylar femur, a retrograde intramedullary 1.4 mm Kirschner (K) wire was used to fixate the osteotomy site. Granules of HA were administered at the bone defect area. The fascia and skin were sutured. Paracetamol with dose of 50 mg/kg/day for analgesic and ampicillin with dose of 100 mg/kg/day for prophylactic antibiotic were given for three days.

Radiographic examination

Radiographic examination was conducted with E7239X Rotanode Toshiba X-ray machine serial number 2A009, with a maximum exposure of 125 kV and 500 mA. Moreover, the exposure of X-ray on ventrodorsal and laterolateral projection in this study was 52 kV and 6.4 mA for 400 ms. RUST score was used to perform radiological evaluation [Table 1]. Each score in the cortex (anterior, posterior, medial, lateral) was combined to a total score of 12 (fully healed) and 4 (not yet healed).

Histomorphometry

In the period of six weeks, the rats were sacrificed and the right femur was obtained immediately. The harvested femur, with the K-wire still maintained, was fixed in 10% neutral buffered formalin for 48 hours. They were decalcified with Plank Rychlo's solution (Wako Pure Chemical Industries Ltd., Osaka, Japan). These samples were embedded in paraffin and cut transversely with a microtome for 5 µm thickness section for six times with an interval of 300 nm before being stained with hematoxylin-eosin. They were examined with a Leica microsystems IC C50 HD microscope with magnification of 40 x.

The histological imageries were collected with a digital microscope camera and merged using the help of PTGUI Pro 9.1 software for digital evaluation. Histomorphometry evaluation included the evaluation of the total area of callus, the area of ossification, cartilage and fibrosis [Figure 2]. Determination of each area was conducted manually using Image J version 1.4 software.

Statistical analysis

Statistical analysis was conducted using SPSS 21 with

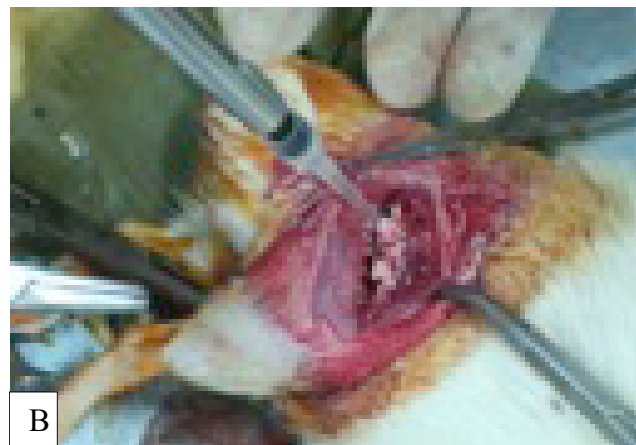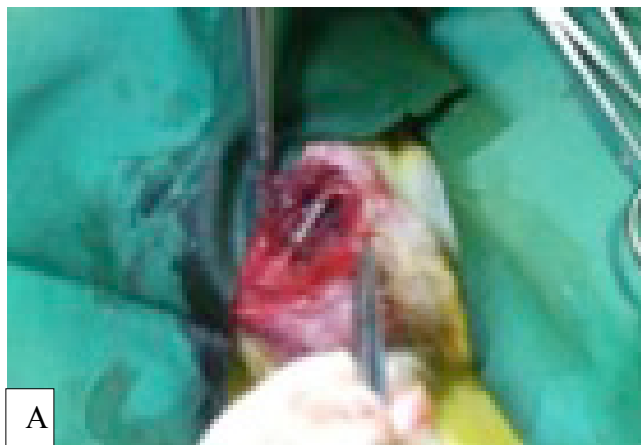


Figure 1. Surgical procedures. A) K-wire fixation after 10 mm osteotomy; B) HA and BMP-2 administration.

Tabel 1. Radiologic Criteria RUST Score		
Score per cortex	Callus	Fracture line
1	No	Yes
2	Yes	Yes
3	Yes	No

Table 2. The radiographic evaluation RUST score of all groups			
	Group	Mean ± SD	Kruskal Wallis
RUST Score	I	4.4 ± 0.9	<i>P</i> < 0.001
	II	8.2 ± 0.4	
	III	9.6 ± 0.9	
	IV	11.6 ± 0.9	
	V	10.2 ± 1.3	

Kruskal-Wallis or One Way ANOVA analysis. A *P*-value less than 0.05 implies that the differences between the means were statistically significant.

Results

In the radiographic evaluation of RUST score, Kruskal Wallis test revealed a significant difference among the groups with *P*-value of 0.001 [Table 2]. Mann Whitney test revealed a significant difference between group II and I, group III and I, group IV and I, and also group V and I with a *P*-value of 0.005; 0.006; 0.005 and 0.006 respectively. Group IV had the highest mean RUST score 11.6 while group I as a control had the lowest RUST score which was 4.4 [Figure 3].

By using the Image J software, we evaluated the area of total callus, ossification, cartilage and fibrosis [Table 3]. Group IV (10 µg/mL) had the largest total area of callus 57.8 mm², the area of ossification 52.5 mm² and area of cartilage 4.2 mm² [Figure 4]. Meanwhile, group I had the smallest total area of callus, the area of ossification and area of cartilage which were 15.8 mm², 6.7 mm², and 0.4 mm² respectively. ANOVA test showed a significant difference in the total area of callus area with a *P*-value of 0.001. The Bonferroni post hoc test revealed a significant difference between group II, III, IV, V and I with a *P*-value of 0.033; 0.001; 0.001; and 0.017 respectively.

In the area of ossification, Kruskal Wallis test revealed a significant difference among all groups with 0.001 *P*-value. Mann Whitney test revealed a significant difference between group II and I (control group), group III and I, group IV and I, and also group V and I with a

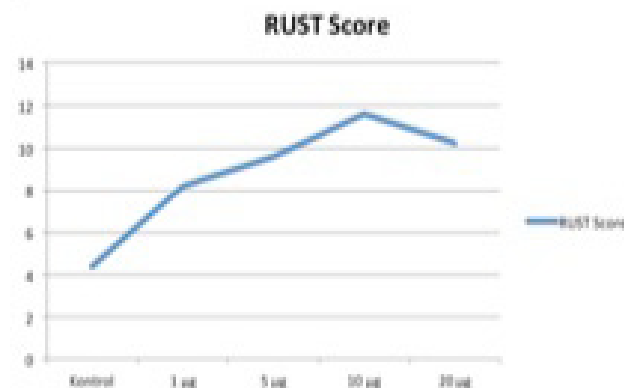


Figure 2. RUST score for each groups. Group IV had the highest mean RUST score (11.6) while group I as control had the lowest RUST score which was 4.4.

P-value of 0.009; 0.016; 0.009 and 0.016 respectively. Kruskal-Wallis test also indicated a significant difference (*P*=0.001) in the evaluation of the area of cartilage. Mann Whitney test revealed a significant difference between group II and I (control group), group III and I, group IV and I, and also group V and I with a *P*-value of 0.009; 0.009; 0.009 and 0.028 respectively. In contrast to the area of ossification and cartilage, group I had the highest

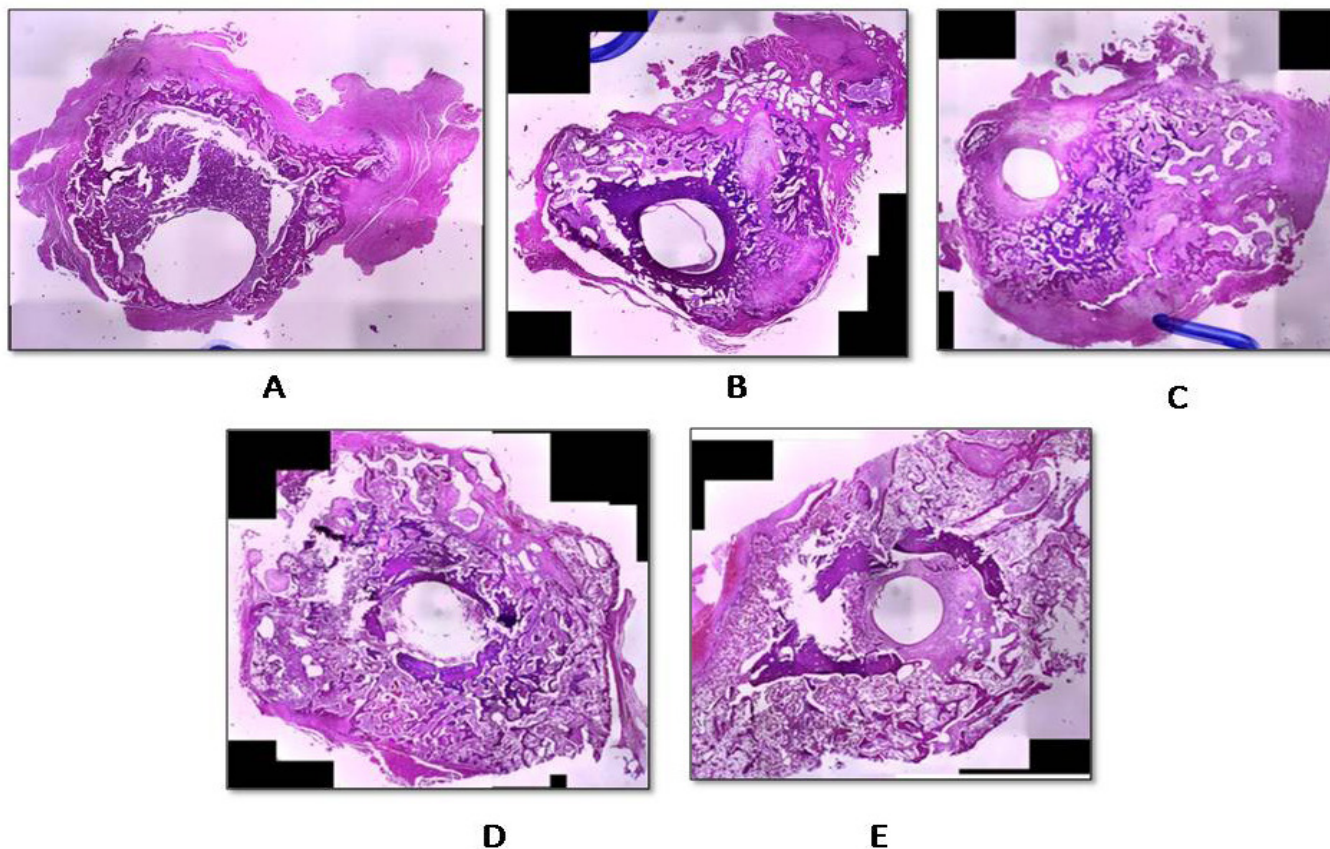


Figure 3. Histomorphometry evaluation included the evaluation of the total area of callus, the area of ossification, cartilage and fibrosis. A). Group I; B Group II; C) Group III; D) group IV and E). Group V.

Table 3. Histomorphometry of all groups evaluated using Image J								
Groups	Total Callus Area		Area of ossification		Area of cartilage		Area of fibrosis	
	Mean ± SD (mm ²)	P value	Mean ± SD (mm ²)	P value	Mean ± SD (mm ²)	P value	Mean ± SD (mm ²)	P value
Control	15,8±4,3	0,241	6,7±3,9	0,003	0,4±0,2	0,517	8,7±4,6	0,255
1 µg	28,1±6,2	0,625	22,1±7,4	0,349	1±0,2	0,954	5±2,7	0,009
5 µg	36,3±4,9	0,165	28,6±5,9	0,741	1,8± 0,2	0,038	6±2	0,377
10 µg	57,8±7	0,559	52,5±5,8	0,689	4,2±1,4	0,938	1±0,9	0,298
20 µg	29,2±6,4	0,308	24,7±8	0,139	1±0,4	0,463	3,5±1,9	0,219

fibrosis area (8.7 mm²) while the lowest area of fibrosis was found in group IV (1 mm²).

Discussion

The complicated physiological fracture healing process consists of three phases: the inflammatory phase, repair, and remodeling. It needs cooperation among some factors such as cells, growth factors, the interaction of extracellular matrix, differentiation factors, and

cytokines. All of the above are controlled mainly by the expression of members of the TGF-β (transforming growth factor) super family, such as BMPs (10-16). BMP-2 has an important role affecting chondrogenesis, osteogenesis, and re-vascularization process. BMP-2 also affects the formation of fibrotic tissue minimally and accelerates the progression of maturation and callus remodeling (10).

BMP has the potency to induce mesenchymal stem

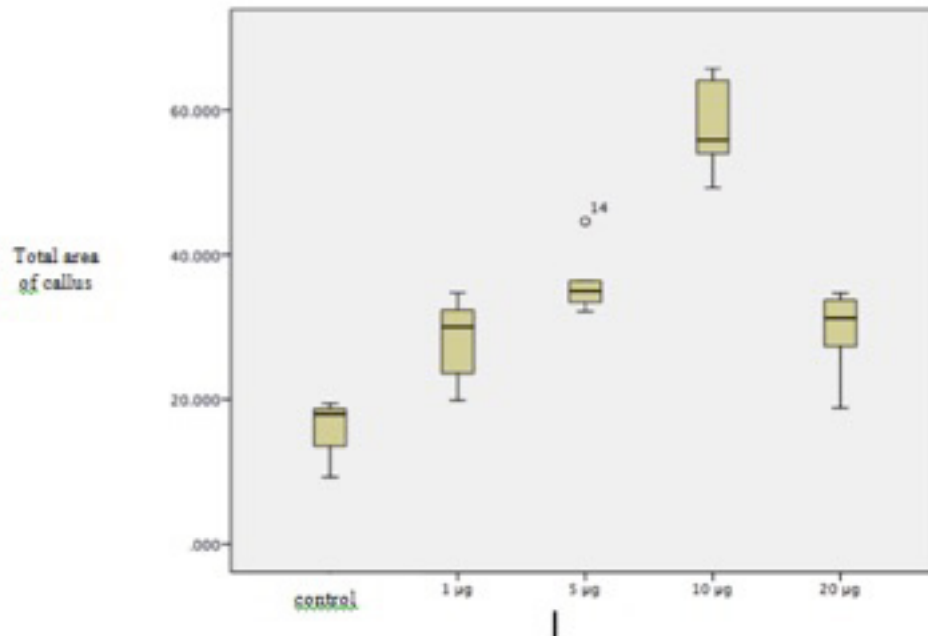


Figure 4. Histomorphometry evaluation of total area callus in all group. Group IV had the highest mean total callus area, 57.8 mm². While group I (control group) showed the lowest total callus area, 15.8 mm².

cell (MSC) differentiation into osteoblast, maintaining its maturity and enhancing endochondral ossification which includes monocyte and MSC recruitment and proliferation, MSC differentiation into chondrocyte, chondrocyte hypertrophy, cartilage matrix calcification, vascular invasion with osteoblast differentiation and bone formation to eventually new bone remodeling and bone marrow creation (17-19). In the process of callus formation, BMP-2 plays a role in the initial process so that the provision of BMP-2 in this study are given in the early phase (20-24). In this study, administration of rhBMP-2 produces extensive callus thereby creating a bridge between proximal and distal osteotomy. Groups treated by rhBMP-2 had larger total callus, ossification, and cartilage, but a smaller area of fibrosis.

Sasso et al. mentioned that BMP has osteoinductive property in massive bone defect healing (25). A study conducted using animal concerning segmental bone defect resulted in the knowledge that BMP promoted a similar or better result compared to autologous bone graft (26). Cuomo et al. reported that the inclusion of rhBMP-2 as an osteoinductive component generated more effective MSC differentiation by giving signal to the cells which produce complete healing rates (100%) (26). In addition, Kamal et al. reported that application of rhBMP-2 accelerated the healing process, averted implant failure and better bridging callus (27).

Dose or concentration of BMP-2 is an important aspect of bone formation. Moreover, in order to induce ectopic bone formation, dose of BMP-2 depends on the type of carrier material used (28). Tazaki et al. reported by using

5 µg of BMP-2 with a 9 mm³ β-tricalcium phosphate scaffold, 32% bone formation is produced, whilst HA only yielded 3% bone formation in a rat ectopic model with equal amount of BMP-2 (29).

In this study, various rhBMP-2 dosages influenced the total area of callus, ossification and cartilage. The increasing doses of BMP-2 significantly increase the formation of callus, bone (ossification) and cartilage. However, if it goes beyond the optimal dose (in this study 10 µg/mL) it would eventually decrease in the formation of callus, bone (ossification) and cartilage. In other words, the 20 µg/mL rhBMP-2 (group V) which actually resulted in counter-productive effects or biphasic dose dependant response (30).

Cheng et al. reported that, in comparison of 10 mg BMP-2 dose, 1 mg dose samples qualitatively exhibited a higher local iNOS expression within the bone defect (1). This suggests that treating defects with 1 mg dose of BMP-2 presented a prolonged local inflammation, that resulted into poor healing in these samples.

Cheng et al. also reported that 1 mg BMP-2 dose samples qualitatively seemed to have higher local iNOS expression within the bone defect compared with the 10 mg dose samples (1). This indicates that the defects treated with 1 mg BMP-2 exhibited prolonged inflammation locally, which may have contributed to the poor healing observed in these samples. Overall, the degree of ectopic bone was much lower than that observed in a previous study, involving a higher dose of BMP-2. In addition, the low-dose BMP-2 samples demonstrated only few sparse islands of new bone formation surrounded by mostly

fibrous tissue with cellular infiltrate (1).

Our evaluation also revealed 10 µg (group IV) more dense and more homogenous callus microstructure compared to group III and V. Thus, group IV showed to encourage bone formation with mineral content close to that of the cortical bone. The resemblance in the mineral microstructures between group III and V suggests a comparable progression in the mineralization. A previous study observed that the calculated ideal dose of rhBMP-2 is 12 µg, greater or less than that value, leads to less bone stimulation. Further more higher doses of rhBMP-2 could lead to a reduction in bone content by the activation of osteoclasts (30). Boyce et al. examined two separate doses of rhBMP-2 but did not notice any difference in the cure rate between the two groups (31). Jones et al. also stated a decrease or plateauing in histological examination of callus at a higher BMP-2 dosage although it was not significant (32). Sciadini et al. also stated that there was a certain individual optimal dosage for BMP-2 in each species (33).

However, administration of BMP-2 in the treatment groups produced a smaller area of fibrosis compared to the control group. This statement is coherent with the study that we previously conducted that showed the fewer area of fibrosis in the group given BMP-2 (27). We assumed that BMP-2 has an important role in all phases of fracture healing and improves the process of osteogenesis and chondrogenesis.

We found that the least area of fibrosis was in group IV compared with group II, III, and V. Group I turned up to progress into a critical sized non-union model. This finding is comparable with other studies (30). Theoretically, HA and bone mineral fraction have asimilarity regarding chemical composition. It may stimulate bone growth and fill a bone defect. HA is a non-resorbable scaffold, and it is considered as a fine substrate for proliferation, adhesion and differentiation of mesenchymal stem cells and osteoblasts. Additionally, differentiated cells would create extracellular matrix and integrated with the host tissue (34-38). Nevertheless,

according to several researchers, HA when exposed with bone marrow and soft tissue may initiate osteolysis. The HA debris stimulates phagocytosis (by macrophage), which apparently led to implant failure. Consequently there will be an inflammatory process that triggers differentiation of osteoclast precursor into mature osteoclast that causes bone remodeling impairment and concludes to osteolysis (34). In this study, all rats from group I had non union and failure fixation.

We only evaluated after 6 weeks of treatment and we could not evaluate the progress of dynamic fracture healing, which is the limitation of this study. Hence, further study at different periods of time is needed. Another limitation is the biomechanic evaluation of fracture healing that is also needed.

Administration of BMP-2 stimulates the formation of bone bridging in a massive bone defect, The bone bridging filling massive bone defect depends on the dose or concentration of BMP-2. Administration of an optimal dose (10 µg/mL) of BMP-2 demonstrates better result than lower or higher dose for massive bone defect healing in SD rate.

Conflicts of Interest: The authors state that there is no conflict of interests regarding the publication of this paper.

Acknowledgements

We would like to express our deepest gratitude to Daewoong Pharmaceutical for donating HA and rhBMP-2.

Achmad Fauzi Kamal MD PhD

Othdeh Samuel Halomoan Siahaan MD

Jessica Fiolin MD

Department of Orthopaedic and Traumatology, Cipto Mangunkusumo National General Hospital, Faculty of Medicine Universitas Indonesia, Jakarta, Indonesia

References

1. Cheng A, Krishnan L, Tran L, Stevens HY, Xia B, Lee N, et al. The effects of age and dose on gene expression and segmental bone defect repair after BMP-2 delivery. *JBMR Plus*. 2018; 3(2):e10068.
2. Rivera JC, Strohbach CA, Wenke JC, Rathbone CR. Beyond osteogenesis: an in vitro comparison of the potentials of six bone morphogenetic proteins. *Front Pharmacol*. 2013; 4(1):125.
3. Peng KT, Hsieh MY, Lin CT, Chen CF, Lee MS, Huang Y, et al. Treatment of critically sized femoral defects with recombinant BMP-2 delivered by a modified mPEG-PLGA biodegradable thermosensitive hydrogel. *BMC Musculoskelet Disord*. 2016; 17(1):286.
4. Ishida K, Haudenschild DR. Interaction between FGF21 and BMP-2 in osteogenesis. *Biochem Biophys Res Commun*. 2013; 432(4):677-82.
5. Blokhuis TJ, Calori GM, Schmidmaier G. Autograft versus BMPs for the treatment of non-unions: what is the evidence? *Injury*. 2013; 44(Suppl 1):S40-2.
6. Schwabe P, Greiner S, Ganzert R, Eberhart J, Dähn K, Stemberger A, et al. Effect of a novel nonviral gene delivery of BMP-2 on bone healing. *Sci World J*. 2012; 2012(1):542-60.
7. Schwarz C, Wulsten D, Ellinghaus A, Lienau J, Willie BM, Duda GN. Mechanical load modulates the stimulatory effect of BMP-2 in a rat non union model.

- Tissue Eng Part A. 2013; 19(1-2):247-54.
8. Yilgor P, Yilmaz G, Onal MB, Solmaz I, Gundogdu S, Sousa RA, et al. An in vivo study on the effect of scaffold geometry and growth factor release on the healing of bone defect. *J Tissue Eng Regen Med.* 2013; 7(9):687-96.
 9. Tressler MA, Richards JE, Sofianos D, Comrie FK, Kregor PJ, Obremsky WT. Bone morphogenetic protein-2 compared to autologous iliac crest bone graft in the treatment of long bone nonunion. *Orthopedics.* 2011; 34(12):e877-84.
 10. Doi Y, Miyazaki M, Yoshiiwa T, Hara K, Kataoka M, Tsumura H. Manipulation of the anabolic and catabolic responses with BMP-2 and zoledronic acid in a rat femoral fracture model. *Bone.* 2011; 42(4):777-82.
 11. Finkemeier CG. Bone-grafting and bone graft substitutes. *J Bone Joint Surg.* 2002; 84(3):454-64.
 12. Brydone A, Meek D, Maclaine S. Bone grafting, orthopaedics biomaterials, and the clinical need for bone engineering. *Proc Institut Mechan Eng J Eng Med.* 2010; 224(12):1329-43.
 13. Noldsletten L, Madsen JE. The effect of bone morphogenetic proteins in fracture healing. *Scand J Surg.* 2006; 95(2):91-4.
 14. Whelan DB, Bhandari M, Stephen D, Kreder H, McKee MD, Zdero R, et al. Development of the radiographic union score for tibial fractures for the assessment of tibial fracture healing after intramedullary fixation. *J Trauma.* 2010; 68(3):629-32.
 15. Mokbel N, Bou Serhal C, Matni G, Naaman N. Healing patterns of the critical size bony defect in rat following bone graft. *Oral Maxillofac Surg.* 2008; 12(2):73-8.
 16. Laurencin CR, El-Amin SF. Xenotransplantation in orthopaedic surgery. *J Am Acad Orthop Surg.* 2008; 16(1):4-8.
 17. Wutzl A, Rauner M, Seemann R, Milles W, Krepler P, Pietschmann P, et al. Bone morphogenetic protein 2,5 and 6 in combination stimulate osteoblasts but not osteoclasts in vitro. *J Orthop Res.* 2010; 28(11):1431-9.
 18. Garrison KR, Donell S, Ryder J, Shemit I, Mugford M, Harvey I, et al. Clinical effectiveness and cost-effectiveness of bone morphogenetic proteins in the non-healing of fractures and spinal fusion: a systematic review. *Health Technol Assess.* 2007; 11(30):1-150.
 19. Gerstenfeld LC, Wronski TJ, Hollinger JO, Einhorn TA. Application of histomorphometric methods to the study of bone repair. *J Bone Miner Res.* 2005; 20(10):1715-22.
 20. Vaccaro AR. The role of the osteoconductive scaffold in synthetic bone graft. *Orthopedics.* 2002; 25(5):S571-8.
 21. Mont MA, Ragland PS, Biggins B, Friedlaender G, Patel T, Cook S, et al. Use of bone morphogenetic proteins for musculoskeletal applications. *J Bone Joint Surg Am.* 2004; 86-A(Suppl 2):41-55.
 22. Lieberman JR, Daluiski A, Einhorn TA. The role of growth factors in the repair of bone. *J Bone Joint Surg Am.* 2002; 84(6):1032-44.
 23. Mills LA, Simpson AH. In vivo models of bone repair. *J Bone Joint Surg Br.* 2012; 94(7):865-74.
 24. Carreira AC, Zambuzzi WF, Rossi MC, Filho RA, Sogayar MC, Granjeiro JM. Bone morphogenetic proteins: promising molecules for bone healing, bioengineering, and regenerative medicine. *Vitam Horm.* 2015; 99(1):293-322.
 25. Sasso RC, LeHuec JC, Shaffrey C. Iliac crest bone graft donor site pain after anterior lumbar interbody fusion: a prospective patient satisfaction outcome assessment. *J Spinal Disord Tech.* 2005; 18(Suppl):S77-81.
 26. Cuomo AV, Virk M, Petrigliano F, Morgan EF, Lieberman JR. Mesenchymal stem cell concentration and bone repair: potential pitfalls from bench to bedside. *J Bone Joint Surg Am.* 2009; 91(5):1073-83.
 27. Fauzi Kamal A, Hadisoebroto Dilogio I, Untung Hutagalung E, Iskandriati D, Susworo R, Chaerani Siregar N, et al. Transplantation of mesenchymal stem cells, recombinant human BMP-2 and their combination in accelerating the union after osteotomy and increasing the mechanical strength of extracorporeally irradiated femoral autograft in rat models. *Med J Islam Repub Iran.* 2014; 28(1):129.
 28. Mumcuoglu D, Fahmy-Garcia S, Ridwan Y, Nicke J, Farrell E, Kluijtmans SG, et al. Injectable BMP-2 delivery system based on collagen-derived microspheres and alginate induced bone formation in a time- and dose-dependent manner. *Eur Cell Mater.* 2018; 35(1):242-54.
 29. Tazaki J, Murata M, Akazawa T, Yamamoto M, Ito K, Arisue M, et al. BMP-2 release and dose-response studies in hydroxyapatite and beta-tricalcium phosphate. *Biomed Mater Eng.* 2009; 19(2-3):141-6.
 30. Angle SR, Sena K, Sumner DR, Virkus WW, Viridi AS. Healing of rat femoral segmental defect with bone morphogenetic protein-2: a dose response study. *J Musculoskelet Neuronal Interact.* 2012; 12(1):28-37.
 31. Boyce AS, Reveal G, Scheid DK, Kaehr DM, Maar D, Watts M, et al. Canine investigation of rhBMP-2, autogenous bone graft, and rhBMP-2 with autogenous bone graft for the healing of a large segmental tibial defect. *J Orthop Trauma.* 2009; 23(10):685-92.
 32. Jones AL, Bucholz RW, Bosse MJ, Mirza SK, Lyon TR, Webb LX, et al. Recombinant human BMP-2 and allograft compared with autogenous bone graft for reconstruction of diaphyseal tibial fractures with cortical defects: a randomized controlled trial. *J Bone Joint Surg Am.* 2006; 88(7):1431-41.
 33. Sciadini MF, Johnson KD. Evaluation of recombinant human bone morphogenetic protein-2 as a bone-graft substitute in a canine segmental defect model. *J Orthop Res.* 2000; 18(2):289-302.
 34. Nandi SK, Roy S, Mukherjee P, Kundu B, De DK, Basu D. Orthopaedic applications of bone graft & graft substitutes: a review. *Indian J Med Res.* 2010; 132(1):15-30.
 35. Greenwald AS, Boden SD, Goldberg VM, Khan Y, Laurencin CT, Rosier RN, et al. Bone-graft substitutes: facts, fictions & applications. *J Bone Joint Surg Am.*

THE ARCHIVES OF BONE AND JOINT SURGERY. ABJS.MUMS.AC.IR
VOLUME 7. NUMBER 6. NOVEMBER 2019

MANAGEMENT OF MASSIVE BONE DEFECT

- 2001; 83(2):98-103.
36. Moore WR, Graves SE, Bain GI. Synthetic bone graft substitutes. ANZ J Surg. 2001; 71(6):354-61.
37. Leboucher J. Design and characterization of a scaffold for bone tissue engineering. Nat Bio J. 2003;

- 12(1):1-46.
38. Jahangir AA, Nunley RM, Mehta S. Bone-graft substitutes in orthopaedics surgery. Orthop Surg. 1995; 90(1):111-9.