

RESEARCH ARTICLE

Total Hip Arthroplasty with Modular Stem for Dysplastic Hips in South Asian Population

Deepak Gautam, MS; Rajesh Malhotra, MS, FRCS

Research performed at All India Institute of Medical Sciences, New Delhi, India

Received: 16 July 2018

Accepted: 02 October 2018

Abstract

Background: Optimum component positioning and orientation is required to optimize the functional result during total hip arthroplasty for dysplastic hips.

Methods: Sixty-two patients (66 hips) including 33 males and 29 females underwent total hip arthroplasty using modular stem prosthesis at an average age of 40.6 years (range 17 to 49 years). Nineteen hips were classified as Type I, 24 hips as Type II, 13 hips as Type III and 10 hips as Type IV dysplastic hips according to Crowe's classification. Eighteen hips (27.2%) underwent sub trochanteric osteotomy and 23 hips (34.8%) required adductor tenotomy at the time of surgery.

Results: Sixty-one patients (65 hips) were available for the latest follow up. The median follow-up was 57.4 months (range 12 to 100 months). The mean Harris Hip Score was 90.6 (range 72 to 96), which was significant improvement from the preoperative Score of 44.8 (range 38 to 62). The clinical outcome was graded as excellent in 39, good in 13, fair in 7 patients and poor in 2 patients respectively. Only one hip (1.5%) had undergone revision surgery for the stem at 18 months following the index surgery. Postoperative dislocation following a fall was seen in one hip of a female patient who was operated on both sides. The radiographs revealed that all the remaining 65 hips had stable femoral component and the osteotomy sites were healed. The Kaplan-Meier survivorship with revision as endpoint (including open reduction for dislocation) was found to be 96.4% at 100 months (95% Confidence Interval; 86.3-99.1).

Conclusion: This study in South-Asian patients using the modular stem strengthened the premise that cementless modular total hip arthroplasty provides a satisfactory outcome in treating secondary osteoarthritis due to dysplastic hips.

Level of evidence: IV

Keywords: Dysplastic hip, Modular stem, South Asia, Total hip arthroplasty

Introduction

Developmental Dysplasia of Hip (DDH) is a disorder of development where the femoral head is not concentric within the acetabulum leading to a deformed hip joint (1). The prevalence has been reported from 1.8 % to 12.8 % varying in different ethnic groups

(2). If not treated early or incorrectly treated, 25% to 50% of these patients develop secondary osteoarthritis of the hip at an early age (3-6). The patients with disabling secondary osteoarthritis are indicated for total hip arthroplasty.

Corresponding Author: Rajesh Malhotra, Department of Orthopedics, All India Institute of Medical Sciences (AIIMS), New Delhi, India
Email: rmalhotra62@gmail.com



THE ONLINE VERSION OF THIS ARTICLE
ABJS.MUMS.AC.IR

The acetabular anomaly accompanied with proximal femoral abnormality associated with limb length discrepancy poses a greatest challenge in performing total hip arthroplasty in these patients. On one hand, the acetabulum is shallow and deficient in shape as well as in orientation leading to poor coverage of the femoral head and relative lateralization of the hip centre (7). On the other hand, the femur is thinned out with small and aspherical head, increased anteversion and valgus or a varus neck (8). As majority of these patients are relatively young, care should be taken to maximize the functional results. The major concern is of postoperative dislocation and limb length discrepancy. The surgical technique and the choice of implant play an important role. Here, we present clinicoradiological outcomes following total hip arthroplasty in South Asian patients operated for secondary osteoarthritis due to dysplastic hips using a modular implant, with or without femoral osteotomy.

Materials and Methods

This is a retrospective study that included all primary total hip arthroplasties (THAs) done for secondary osteoarthritis due to dysplastic hip in Indian patients using the S-ROM® modular hip system (Depuy Orthopaedics Inc., Warsaw, IN). The Institute Ethics Committee approved the study. Between August 2008 and December 2015, 62 patients (66 hips) with no history of surgical intervention in the past underwent total hip arthroplasty for secondary osteoarthritis for dysplastic hips. The mean age of the patients at the time of surgery was 40.6 years (Range 17 to 49 years). There were 33 males and 29 females. Thirty-one patients were operated on the left side (15 males and 16 females), 27 patients on the right side (16 males and 11 females), and, 4 four patients (2 males and 2 females) were operated on both sides simultaneously for involvement of both the hips.

All the hips were classified as per the Crowe's classification (9). All the surgeries were performed via the Posterior Moore's approach (10). Placement of the acetabular component was attempted at the site of the true acetabulum wherever possible. Prerequisite were good underlying bone bed providing adequate coverage (at least 70%) without elevating the hip centre by more than 5mm. All patients were implanted with stem-sleeve modular stem of S-ROM modular hip system (Depuy Orthopaedics Inc., Warsaw, IN), while various acetabular components were used. Twenty-three patients were implanted with Pinnacle® cup (Depuy, Warsaw, IN), 35 patients with GRIPTION® coated Pinnacle cup (Depuy, Warsaw, IN), 3 patients with Continuum® cup (Zimmer Biomet, Warsaw, IN), 3 patients with cemented Dual Mobility cup (Capitole C®, Evolutis, Loire, France), one patient with Duraloc® cup (Depuy, Warsaw, IN) and one patient with Regenerex® cup (Biomet, Warsaw, IN). Forty-three femora (65.15%) were documented to have exaggerated anteversion (more than 20 degrees) when assessed intraoperatively by seeing the position of the lesser trochanter with respect to the knee flexed at 90°. The adjusted version during the trial that provided the best stability was depicted in the final definitive implantation. Twenty-one patients (23 hips, 34.8%) required adductor

tenotomy at the time of surgery. Adductor tenotomy was done with the trial implants in place as a relatively freely mobile hip rendered the palpation of taut adductor longus tendon and its percutaneous tenotomy easy. The length of the neck and soft tissue tension was assessed after the adductor tenotomy and trial components in place could be exchanged readily to achieve optimum soft tissue balance if required. Eighteen hips (27.2%) had to undergo transverse sub trochanteric osteotomy. The decision to perform sub-trochanteric osteotomy was taken intraoperatively if the trial reduction was difficult despite extensive release or the nerve was palpated to be taut after trial reduction. There was no need of additional fixation method at the osteotomy site in any of the cases. Stem sizes used (in order of frequency) were 13 (36.36%) followed by 11 (30.3%), 9 (15.15%), 7 (7.57%), 15 (7.57%) and size 8 (3.03%). Seventeen different sleeve sizes were coupled with the stem ranging from the smallest 12B SMALL size to 20F EXTRA LARGE ones. The neck sizes used were Standard 30 in 50% hips, Standard 36 in 44% hips, Standard 42 in 4.5% hips and 36+21 CR neck in only one hip (1.5%). The articulations used were Metal on Polyethylene in 29 hips (44%), Ceramic on Polyethylene in 19 hips (28.7%) and Ceramic on Ceramic in 18 hips (27.3%). However, the proximal femur preparation was done after prophylactic cerclage in the region just below the lesser trochanter to prevent splitting of the femur due to narrow canal during preparation [Figure 1]. The cancellous bone grafting with graft from the femoral head was done at the osteotomy site.

The postoperative protocol was same in all the patients with Low Molecular Weight Heparin (LMWH) till mobilization. All the patients were mobilized full weight bearing immediately except those who required sub trochanteric osteotomy. The osteotomized hips were mobilized gradually with partial weight bearing to full weight bearing by 3 months.

Patients were followed up as per our service protocol i.e. at 2 weeks, 6 weeks, 3 months, 6 months and then yearly. The patients were assessed clinically in each visit and radiologically with X-rays at 2 weeks, 3 months, 6 months and then yearly as per the patient's convenience and clinical decision. For the study purpose, all the patients were contacted telephonically to attend our Out-Patient Department (OPD) for the latest follow up in the groups of 5-6 patients a day after the regular OPD was over. The longitudinal follow-up data of the patients were collected through outpatient records, medical records and call visits analysis. All the patients who visited the OPD were independently assessed by the other author (DG). The patients signed the informed consent and completed a questionnaire, which included the modified Harris Hip Score (11). Leg Length discrepancy if any which was previously assessed by the block method in regular follow-ups and advised compensatory shoe raise was documented.

Standard Anteroposterior and lateral radiographs of the hips were taken on the same day. Radiographs were evaluated as per consensus by both the authors. The radiographs were compared with the previous radiographs on record as well. The radiographs were

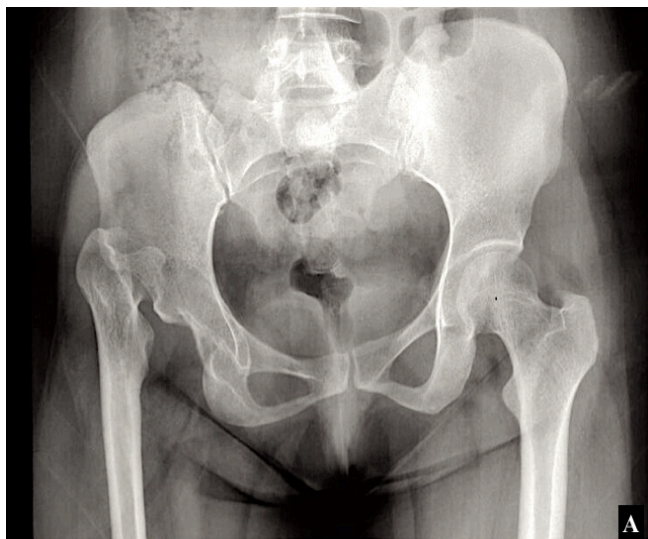


Figure 1A. X-ray of pelvis with both hips in Antero-Posterior view showing dysplastic right hip.

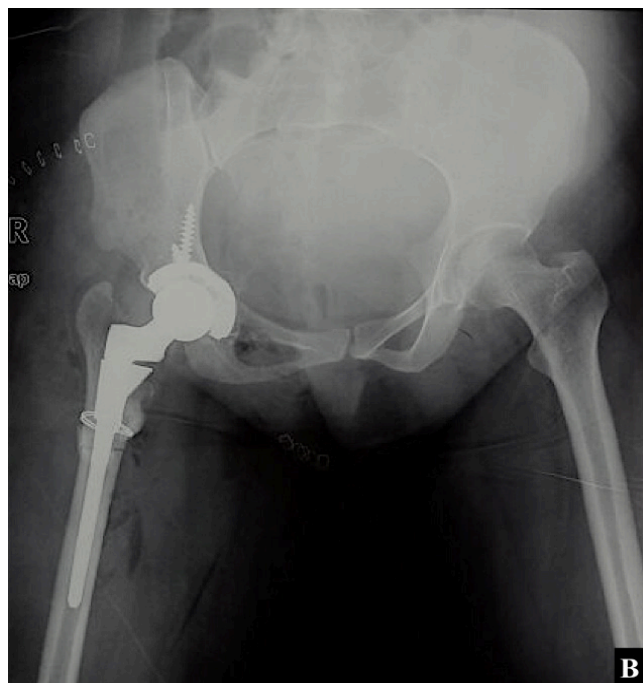


Figure 1B. Immediate post-operative X-ray of pelvis in Antero-Posterior with both hips following total hip arthroplasty. The patient had to undergo sub-trochanteric shortening osteotomy as well as adductor tenotomy. There was no requirement of additional fixation. A prophylactic cerclage wire was applied during femoral preparation.

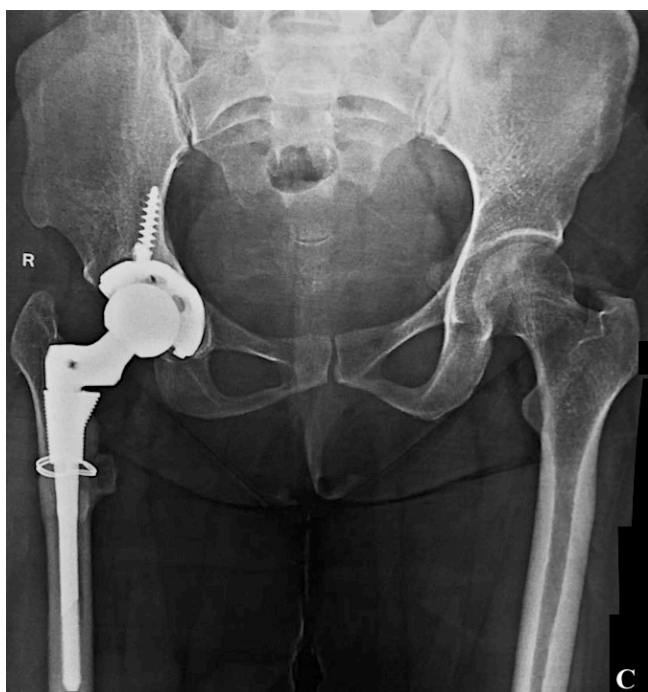

Figure 1C. Five years follow up X-ray of pelvis with both hips showing stable implants in right hip. The osteotomy site is united.

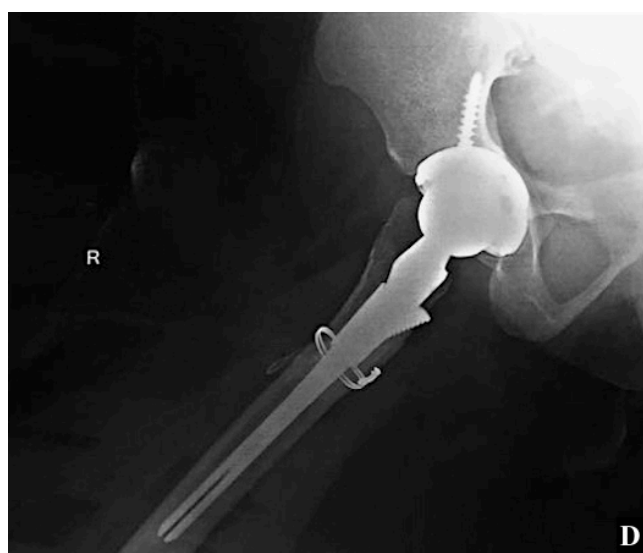

Figure 1D. Follow up X-ray of same hip in lateral view showing complete union at the osteotomy site.

assessed on the femoral side for the presence of any radiolucencies, stem-sleeve subsidence and/or loosening, and, union at the osteotomy site. Radiolucencies were assessed according to the criteria given by Gruen et al (12). Stem subsidence was assessed by using the criteria given by Loudon and Johnston et al (13, 14). Loosening of the femoral component was assessed as per the criteria

given by Engh et al (15). The acetabular components were assessed for lucencies and fixation using DeLee and Charnley's criteria (16).

The outcome of interest was survival of the femoral implant. The endpoint for survival was defined as revision for any reason, including dislocation. The Kaplan- Meier survival analysis was used to construct the cumulative survivorship of the implant.

Results

The medical record revealed that 19 hips (28.7 %) were classified as Crowe’s Type I, 24 hips (36.3%) as Crowe’s Type II, 13 hips (19.6%) as Crowe’s Type III and 10 hips (15.1%) as Crowe’s Type IV dysplastic hips. Of the 62 patients operated with S-ROM modular hip system, 61 patients (65 hips) were available for the latest follow up at the given point of time. One male patient who had undergone revision at 18 months following the index surgery did not turn up for the follow up; however, he was considered as failure to calculate the survivorship. The median follow up was 57.4 months (minimum of 12 and maximum 100 months). The number of patients under follow up at the given point of time is shown in Table 1.

On clinical examination, all the patients were pain free except three. The mean Harris Hip Score was 90.6 (Range 72 to 96). This was significant improvement from the mean preoperative Harris Hip Score of 44.8 (Range 38 to 62) as documented in the clinical record. Three patients (two at 12 months follow up and one at 18 months follow up) complaining of pain and limp while walking were found to have trochanteric bursitis, and were advised symptomatic treatment. On radiographic corroboration, all three had increased horizontal offset as compared to the contralateral normal hips. Nine other patients had similar history of trochanteric pain at 12 – 36 months’ follow-up time as documented in the clinical record. Seven of them remained asymptomatic after conservative treatment with anti-inflammatory medications and local ultrasonics, whereas two of them required local steroid injection before they were symptom free. The mean increase in leg length achieved was 3.5 cm (1.4 to 4.8 cm). However, six patients (9%) were left with limb shortening (0.5 cm to 1.5 cm), and have been managing with compensatory shoe raise as advised previously. All

the patients were walking independently without any support except one male patient who was walking with a cane. The clinical outcome was graded as excellent in 39 patients (63.9%), good in 13 patients (21.3%), fair in 7(11.4%) patients and poor in 2 patients (3.2%).

Only one hip (1.5%) had underwent revision surgery for the stem at 18 months following the index surgery. He had complaint of persistent thigh pain. There was an evidence of stem subsidence, which was confirmed intraoperatively with loose sleeve. The patient was revised with a cementless long stem while the acetabular component was retained. The radiological examination at the latest follow up revealed that all the remaining 65 hips had stable femoral components. There was no evidence of subsidence or loosening. Radiographs revealed that all the osteotomy sites were healed. No radiolucent lines exceeding 2 mm were seen in any of the zones around the acetabular shell suggesting stability of the acetabular component in situ.

Postoperative dislocation following a fall was seen in right hip of a female patient who was operated on both sides. She had trochanteric avulsion and required open reduction and trochanteric fixation with cerclage wires. She was given a hip abduction brace for six weeks. No recurrence was seen subsequently. Two patients developed infection (one during the hospital admission and other 2 weeks after the surgery). Both were successfully treated with debridement and antibiotics. Two patients (3%, both with Crowe’s Type IV dysplastic hip) developed sciatic nerve palsy after the surgery, one of which recovered by 4th month whereas the other had a permanent palsy. Asymptomatic heterotopic ossification (Brooker’s class II) was seen in two hips (17).

Kaplan-Meier Survivorship Analysis

The Kaplan-Meier survivorship with revision as endpoint (including open reduction for dislocation) was found to be 96.4% at 100 months (95% Confidence Interval; 86.3-99.1) [Figure 2].

Table 1. Table showing the follow up time of the patients who underwent total hip arthroplasty for secondary osteoarthritis due to dysplastic hip using S-ROM modular hip system.

Follow up (Months)	Number of patients
96 - 108	7
84 - 96	6
72 - 84	9
60 - 72	7
48 - 60	7
36 - 48	8
24 - 36	10
12 - 24	7

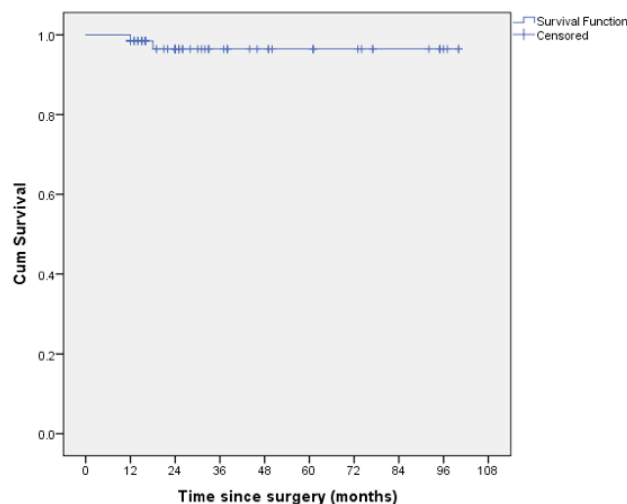


Figure 2. Kaplan-Meier Survival curve with revision as end point.

Discussion

The distorted anatomy of hip in patients with sequale of DDH poses a significant challenge to the surgeon when it comes to total hip arthroplasty. The acetabular challenge can be overcome by finding the true acetabular level with good bone stock, medialized reaming and use of small sized acetabular component with screws (18). Apart from the distorted rotation and version of the femur, there is incongruence of diameter between the medullary cavity of metaphysis and diaphysis. This aggravates the challenge to the surgeon in attaining the stability of the joint and post-operative function. The need of modularity stems is realized here (19). The S-ROM modular hip system provides 3600 of version control regardless of the anatomy of proximal femur. The proximal sleeve can be rotated and oriented to accommodate the best remaining calcar bone and optimize fixation. The slotted stem provides rotational stability in the distal femur through its splines and proximally provides independent adjustment of version, height and the offset. The distal rotational stability can also be easily achieved in case of sub-trochanteric osteotomy without any need of additional fixation methods. None of our patients required any additional fixation in the hips requiring sub trochanteric osteotomy. A variety of base neck lengths helped in providing additional versatility in equalizing the limb length as well as in fine-tuning of soft tissue around the hip. We believe that the appropriate timing of the adductor tenotomy after implantation of trial components when you have all the liberty to exchange the trial components for optimum soft tissue tension and stability is extremely important. Restricted hip motion in the diseased hip may not allow identification and adequate release of tight structures before surgery while tenotomy after implantation of the real components may leads to soft tissue laxity and compromised stability.

Only 1.5% failure in our series of 66 hips justifies the stem as a suitable implant for dysplastic hips requiring total hip arthroplasty. Our study showed a combined excellent and good result in 85.24 % of the patients. There was significant improvement in the hip function as well, as justified by the improvement in Mean Harris Hip Score from 44.8 to 88.6. Only one patient was walking with cane. He had Grade IV DDH and was operated at the age of 49 years and required osteotomy as well. The requirement of support may be due to longstanding abductor dysfunction combined with gait disturbances (20). High incidence of trochanteric bursitis (18%) in our series can be related to the relative increase in horizontal offset after the surgery. However most of them can be treated conservatively. Our series also showed that anti-inflammatory combined with local ultrasonics as the effective treatment for trochanteric bursitis.

The rationale behind the aim to implant the cup at the region with good bone and adequate coverage was to prevent loosening and hence failure (21). Sub-trochanteric osteotomy was done to allow simultaneous shortening without disturbing the proximal femoral

metaphysis, and restoring the lever arm for the abductors (22). Although non-union remains the major concern following the osteotomy, we could achieve 100% union in our patients. This was consistent with the reports by Tabak et al and Baz et al though they had used cementless femoral stems instead of modular stem (23, 24). We believe that after attaining the rotational stability by the distal fragment and compression at the osteotomy site by the stem, there is no need of additional fixation method to augment the osteotomy site. However, we used the bone grafts from the femoral head to enhance the healing. At the end of the study it was found that 65 out of the 66 femoral components (98.45 %) implanted were stable and surviving till the latest follow up. It was also found that all the acetabular components were radiologically stable.

There are reports of using a modified S-ROM stem (i.e. S-ROM-A) for Asian patients with good results (25, 26). Although all patients were of Indian origin (i.e. Asian), we achieved successful and comparable results even with the original S-ROM stems. Tamegai et al reported the clinical outcome in 196 patients (220 hips) of Asian origin who underwent Total Hip Arthroplasty for secondary osteoarthritis due to DDH using the S-ROM-A stem (25). At the mean follow up of 3.3 (2 to 5 years), it was found that 99.5% of the hips had achieved bone ingrowth fixation on X-rays. Kido et al observed no dislocation or implant fixation failure in their series of 63 hips in 52 Asian patients with DDH who were implanted with S-ROM-A stem at a short mean follow up period of 27.8 months (26). The comparable results in our series suggest that, there is no additional benefit of the modified S-ROM-A stem over the original S-ROM stem. However, a randomized study would resolve the issue. In addition, the survival rate (96.4%) at 100 months (8.3 years) reported in our study is comparable to the results provided in the latest report by Wang et al (27). They reviewed 76 hips in 62 patients who underwent cementless total hip arthroplasty with transverse sub-trochanteric osteotomy. At a mean follow up period of 10 years, there was significant improvement in Harris Hip Score from 38.8 to 86.1 and the mean limb length discrepancy was reduced from 4.3 cm to 1.0 cm. Only three patients in their series experienced post-operative dislocation. All of them were successfully treated with closed reduction. At the latest follow up, only one stem had to be revised due to loosening. They reported an overall survivorship of 97% at 10 years. The results from the various authors following implantation of S-ROM stem for the treatment of secondary osteoarthritis due to DDH are summarized in Table 2 (19, 25-34).

There are certain limitations in our study. As the main concern for using the modular stem is to prevent the post-operative dislocation in a deformed hip joint, we have only focused on the femoral stems. Acetabular inclination and version, and other factors are not considered in this study. The femoral anteversion was judged through eye-balling only without objective measurement.

This study in South-Asian patients using the original

Table 2. Table showing the results of Total Hip Arthroplasties in Developmental Dysplasia of Hip using S-ROM stem from various authors

Authors	No. of cases	Diagnosis	Mean Age at surgery	Follow Up	Mean Pre-op Clinical Score	Mean Clinical score at latest follow up	Complication/Failures	Survival
Wang et al (27)	62 patients (76 hips)	DDH	38.8 years	10 years	HHS= 38.8	HHS = 86.1	3 dislocations	97% at 10 years
Li et al (28)	17 patients (21 hips)	DDH	43.6 years	49.3 months	HHS= 30.6	HHS= 91.2	2 dislocations	-
Tamegai et al* (25)	196 patients (220 hips)	DDH	61.7 years	3.3 years	JOA= 43	JOA= 87	2 dislocations	-
Dallari et al (29)	20 hips	DDH	52 ± 10 years	88 ± 45 months	-	-	Loosening of one stem	-
Kang et al (30)	42 patients (45 hips)	DDH	48.5 years	80 months	HHS= 52.2	HHs= 85.5	2 dislocations	-
Takao et al (31)	25 patients (33 hips)	DDH	60 years	8 years	Merle D' Aubigné = 9	Merle D' Aubigné = 16	2 dislocations	97% at 8 years
Imbuldeniya et al (32)	25 patients (30 hips)	DDH	47 years	18.7years	HHS= 46	HHs= 90	One dislocation Revisions for acetabular failures	86% at 10 years 81 % at 15 years
Kido et al* (26)	52 patients (63 hips)	DDH	57.1 years	27.8 months	HHS = 47.1	HHS=91.4	No failures	-
Biant et al (33)	22 patients (28 hips)	DDH	45 years	10 years	HHS= 37	HHS= 81	No failures	-
Park et al (34)	14 hips	DDH	44.8 years	4.7 years	-	HHS= 92	One dislocation	-
Cameron H (19)	162 hips	DDH	43.7 years	11.5 years	-	-	6 dislocations 2 periprosthetic fractures 2 late sepsis One distal osteolysis	-
Current study	62 patients (66 hips)	DDH	40.6 years	57.4 months	HHS= 44.8	HHS= 90.6	Loosening of one stem One dislocation	96.% at 100 months

HHS= Harris Hip Score; JOA= Japanese Orthopedic Association Score; * The stem used was a modified S-ROM i.e SROM-A meant for Asian patients

S-ROM stems has further strengthened the premise that cementless modular total hip arthroplasty using S-ROM stem provides a satisfactory outcome in treating secondary osteoarthritis due to dysplastic hips. The implant allows the surgeon to adjust the femoral anteversion independently to maximize the intraoperative stability and functional result in the postoperative period.

Funding source: This work was funded by the Well-

come Trust/DBT India Alliance Fellowship Grant (No. IA/RTF/15/1/1003).

Deepak Gautam MS
Rajesh Malhotra MS FRCS
Department of Orthopedics, All India Institute of Medical Sciences (AIIMS), New Delhi, India

References

1. Herring JA. Developmental dysplasia of hip. Tachdjian's pediatric orthopaedics. 5th ed. New York: Elsevier; 2013. P. 483-585.
2. Kumar JN, Kumar JS, Wang VT, Das De S. Medium-

- term outcome of total hip replacement for dysplastic hips in Singapore. *J Orthop Surg (Hong Kong)*. 2010; 18(3):296-302.
3. Li PL, Ganz R. Morphologic features of congenital acetabular dysplasia: one in six is retroverted. *Clin Orthop Relat Res*. 2003; 416(1):245-53.
 4. Steppacher SD, Tannast M, Werlen S, Siebenrock KA. Femoral morphology differs between deficient and excessive acetabular coverage. *Clin Orthop Relat Res*. 2008; 466(4):782-90.
 5. Hartofilakidis G, Yiannakopoulos CK, Babis GC. The morphologic variations of low and high hip dislocation. *Clin Orthop Relat Res*. 2008; 466(4):820-4.
 6. Wu X, Li SH, Lou LM, Cai ZD. The techniques of soft tissue release and true socket reconstruction in total hip arthroplasty for patients with severe developmental dysplasia of the hip. *Int Orthop*. 2012; 36(9):1795-801.
 7. Van Bosse H, Wedge JH, Babyn P. How are dysplastic hips different? A three-dimensional CT study. *Clin Orthop Relat Res*. 2015; 473(5):1712-23.
 8. Clohisy JC, Nunley RM, Carlisle JC, Schoenecker PL. Incidence and characteristics of femoral deformities in the dysplastic hip. *Clin Orthop Relat Res*. 2009; 467(1):128-34.
 9. Crowe JF, Mani VJ, Ranawat CS. Total hip replacement in congenital dislocation and dysplasia of the hip. *J Bone Joint Surg Am*. 1979; 61(1):15-23.
 10. Moore AT. The self-locking metal hip prosthesis. *J Bone Joint Surg Am*. 1957; 39-A(4):811-27.
 11. Harris WH. Traumatic arthritis of the hip after dislocation and acetabular fractures: treatment by mold arthroplasty. An end-result study using a new method of result evaluation. *J Bone Joint Surg Am*. 1969; 51(4):737-55.
 12. Gruen TA, McNeice GM, Amstutz HC. "Modes of failure" of cemented stem-type femoral components: a radiographic analysis of loosening. *Clin Orthop Rel Res*. 1979; 141(1):17-27.
 13. Johnston RC, Fitzgerald RH, Harris WH, Poss R, Müller ME, Sledge CB. Clinical and radiographic evaluation of total hip replacement. A standard system of terminology for reporting results. *J Bone Joint Surg Am*. 1990; 72(2):161-8.
 14. Loudon JR. Femoral prosthetic subsidence after low-friction arthroplasty. *Clin Orthop*. 1986; 211(1):134-9.
 15. Engh CA, Bobyn JD, Glassman AH. Porous-coated hip replacement. The factors governing bone ingrowth, stress shielding, and clinical results. *J Bone Joint Surg Br*. 1987; 69(1):45-55.
 16. DeLee JG, Charnley J. Radiological demarcation of cemented sockets in total hip replacement. *Clin Orthop Relat Res*. 1976; 121(1):20-32.
 17. Brooker AF, Bowerman JW, Robinson RA, Riley LH Jr. Ectopic ossification following total hip replacement. Incidence and a method of classification. *J Bone Joint Surg Am*. 1973; 55(8):1629-32.
 18. Bernasek TL, Haidukewych GJ, Gustke KA, Hill O, Levering M. Total hip arthroplasty requiring subtrochanteric osteotomy for developmental hip dysplasia: 5- to 14-year results. *J Arthroplasty*. 2007; 22(6 Suppl 2):145-50.
 19. Cameron HU, Keppler L, McTighe T. The role of modularity in primary total hip arthroplasty. *J Arthroplasty*. 2006; 21(4 Suppl 1):89-92.
 20. Sanchez-Sotelo J, Berry DJ, Trousdale RT, Cabanela ME. Surgical treatment of developmental dysplasia of the hip in adults: II. Arthroplasty options. *J Am Acad Orthop Surg*. 2002; 10(5):334-44.
 21. Pagnano W, Hanssen AD, Lewallen DG, Shaughnessy WJ. The effect of superior placement of the acetabular component on the rate of loosening after total hip arthroplasty. *J Bone Joint Surg Am*. 1996; 78(7):1004-14.
 22. Krych AJ, Howard JL, Trousdale RT, Cabanela ME, Berry DJ. Total hip arthroplasty with shortening subtrochanteric osteotomy in Crowe type-IV developmental dysplasia: surgical technique. *J Bone Joint Surg Am*. 2009; 91(9):2213-21.
 23. Tabak AY, Celebi L, Muratli HH, Yagmurlu MF, Aktekin CN, Biçimoglu A. Cementless total hip replacement in patients with high total dislocation: the results of femoral shortening by sub-trochanteric segmental resection. *Acta Orthop Traumatol Turc*. 2003; 37(4):277-83.
 24. Baz AB, Senol V, Akalin S, Kose O, Guler F, Turan A. Treatment of high hip dislocation with a cementless stem combined with a shortening osteotomy. *Arch Orthop Trauma Surg*. 2012; 132(10):1481-6.
 25. Tamegai H, Otani T, Fujii H, Kawaguchi Y, Hayama T, Marumo K. A modified S-ROM stem in primary total hip arthroplasty for developmental dysplasia of the hip. *J Arthroplasty*. 2013; 28(10):1741-5.
 26. Kido K, Fujioka M, Takahashi K, Ueshima K, Goto T, Kubo T. Short-term results of the S-ROM-A femoral prosthesis operative strategies for Asian patients with osteoarthritis. *J Arthroplasty*. 2009; 24(8):1193-9.
 27. Wang D, Li LL, Wang HY, Pei FX, Zhou ZK. long-term results of cement less total hip arthroplasty with subtrochanteric shortening osteotomy in Crowe type IV developmental dysplasia. *J Arthroplasty*. 2017; 32(4):1211-9.
 28. Li L, Yu M, Yang C, Gu G. Total hip arthroplasty (S-ROM stem) and subtrochanteric osteotomy for Crowe type IV developmental dysplasia of the hip. *Indian J Orthop*. 2016; 50(2):195-200.
 29. Dallari D, Pignatti G, Stagni C, Giavaresi G, Del Piccolo N, Rani N, et al. Total hip arthroplasty with shortening osteotomy in congenital major hip dislocation sequelae. *Orthopedics*. 2018; 34(8):e328-33.
 30. Kang JS, Moon KH, Kim RS, Park SR, Lee JS, Shin SH. Total hip arthroplasty using S-ROM prosthesis for dysplastic hip. *Yonsei Med J*. 2011; 52(4):655-60.
 31. Takao M, Ohzono K, Nishii T, Miki H, Nakamura N, Sugano N. Cementless modular total hip arthroplasty with subtrochanteric shortening osteotomy for hips with developmental dysplasia. *J Bone Joint Surg Am*. 2011; 93(6):548-55.
 32. Imbuldeniya AM, Walter WL, Zicat BA, Walter WK. Cementless total hip replacement without femoral osteotomy in patients with severe developmental

THE ARCHIVES OF BONE AND JOINT SURGERY. ABJS.MUMS.AC.IR
VOLUME 7. NUMBER 6. NOVEMBER 2019

THA IN DYSPLASTIC HIPs

- dysplasia of the hip: minimum 15-year clinical and radiological results. Bone Joint J. 2014; 96-B(11):1449-54.
33. Biant LC, Bruce WJ, Assini JB, Walker PM, Walsh WR. Primary total hip arthroplasty in severe developmental dysplasia of the hip. Ten-year results using a cementless modular stem. J Arthroplasty.

- 2009; 24(1):27-32.
34. Park MS, Kim KH, Jeong WC. Transverse subtrochanteric shortening osteotomy in primary total hip arthroplasty for patients with severe hip developmental dysplasia. J Arthroplasty. 2007; 22(7):1031-6.