

RESEARCH ARTICLE

Various Surgical Treatment of Hemophilic Pseudotumor : A Case Series

Achmad Fauzi Kamal, MD, PhD; Agus Waryudi, MD; Aryadi Kurniawan, MD, PhD; Anna Mira Lubis, MD; Djayadiman Gatot, MD

Research performed at Cipto Mangunkusumo General Hospital, Jakarta, Indonesia

Received: 07 September 2018

Accepted: 06 October 2018

Abstract

Background: Bleeding episodes in severe hemophilia may occur more frequently and spontaneously after mild trauma or daily activities. An inadequate treatment of that bleeding in hemophilia may result in pseudotumor, usually in the muscle adjacent to the bone. We reported haemophilic pseudotumor treated with various surgical interventions.

Methods: This study was conducted in the Department of Orthopaedic and Traumatology at a government hospital over a period of 7 years (2010–2017). Patients Perioperative management was done in accordance with the Integrated Hemophilia Team of our institution protocol. Diagnosis and management planning of hemophilic pseudotumor was confirmed via Integrated Hemophilia Team meeting. After the surgery, all patients were asked to come for routine follow up.

Results: We reported six Haemophilia-A patients with pseudotumor in the pelvis, proximal femur and lower leg. One case in pelvic bone underwent hematoma evacuation, acetabular reconstruction using the Harrington procedure, and total hip arthroplasty. Two cases, a case in the proximal femur and another case in the distal fibula, were treated with amputation, other two cases, one was soft tissue pseudotumor in the pelvic region and was treated by hematoma evacuation, and the remaining case was managed with wide excision and followed by defect closure.

Conclusion: Surgery is a preferable treatment for pseudotumors that have been present for years. It's associated with the best outcomes especially when selected as the primary line of preventable and manageable bleeding complication. As previously published by many authors, this paper confirms that surgical excision is the treatment of choice but should only be carried out in major hemophilia centers by a multidisciplinary surgical team.

Level of evidence: IV

Keywords: Hemophilia type-A, Hemophilic pseudotumor, Surgical treatment

Introduction

Hemophilia should be suspected in patients with a history of easy bruising in early childhood, spontaneous bleeding (especially in the joints and soft tissues), excessive bleeding during trauma or surgery, and family history of bleeding. It is supported

by activated partial thromboplastin time (APTT) which is lengthened (1). Grading of hemophilia is classified based on the percentage of coagulation factor which are: severe (<1%), moderate (1% to 5%), and mild (>5%) (1, 2).

Corresponding Author: Achmad Fauzi Kamal, Department of Orthopaedic and Traumatology, Dr. Cipto Mangunkusumo General Hospital, Faculty of Medicine, University of Indonesia, Jakarta, Indonesia
Email: fauzikamal@yahoo.com



THE ONLINE VERSION OF THIS ARTICLE
ABJS.MUMS.AC.IR

Bleeding episodes in severe hemophilia may occur more frequently and spontaneously after mild trauma or daily activities (3, 4). Thus, an inadequate treatment of that bleeding in hemophilia may result in pseudotumor, usually in the muscle adjacent to a bone. The bone itself may be secondarily involved or it occurs as a complication from fracture (5).

The haemophilic pseudotumor was firstly defined by Fernandez de Valderrama and Matthews as a progressive cystic swelling involving muscle, produced by recurrent hemorrhage and accompanied by radiographic evidence of bone involvement (6). It was formed as the result of repeated episodes of bleeding at a bone fracture site or as a result of subperiosteal hemorrhage or bleeding that accumulate into a soft tissue. Inadequate resorption of extravasated blood results in an encapsulated area of clotted blood and necrosed tissue, and with successive hemorrhagic episodes, these lesions expand over time and cause a mass effect symptoms (7).

Treatment modalities of hemophilic pseudotumor include conservative treatment, surgery, embolization, and radiotherapy. Conservative treatment consists of infusion of synthetic clotting factor and immobilization of the patient (1, 4). Surgical intervention is the most effective treatment for hemophilic pseudotumor. There are multiple challenges facing this treatment such as atypical anatomy, abnormal bone structures, osteoporosis, and perioperative bleeding. In addition, the complication rates are high including pseudotumor recurrence, fistula formation, infection, inhibitor formation, and bone graft nonunion (8).

We reported six cases of haemophilic pseudotumor treated with surgical intervention such as hematoma evacuation, amputation and more complicated salvage surgery with joint reconstruction.

Materials and Methods

This study was conducted in the department of orthopedic and traumatology of a government hospital over a period of 7 years (2010 -2017). A total of six cases of hemophilic pseudotumor underwent surgical intervention by a senior orthopedic surgeon, after confirmation with clinico-radiology studies. Patients perioperative management was done in accordance with the Integrated Hemophilia team from our hospital.

Fifty percent of pseudotumor was located in the pelvic region, with one case involving the bone and the two others involving the soft tissue. The rest of pseudotumor consecutively was located at the femur with pathological fracture, soft tissue proximal tibia and distal fibula. Patients were investigated with routine laboratory studies, plain radiographs of the involved part, computed tomography (CT) scan and or magnetic resonance imaging (MRI). Diagnosis and management planning of hemophilic pseudotumor was confirmed via Integrated Hemophilia team meeting.

One case underwent hematoma evacuation, acetabular reconstruction with modified Harrington procedure, and total hip arthroplasty. Two of six cases were treated with hematoma evacuation only and the other two cases were treated with limb ablation. Another

remaining patient underwent marginal excision which was followed by soft tissue coverage.

As perioperative management, factor VIII concentrates was given prior to and during surgery, in accordance with the international standard perioperative protocol. As perioperative management, factor VIII concentrates was given prior to and during surgery, in accordance with international standard perioperative protocol. The patients were treated with factor VIII concentrates twice a day for 2 weeks, followed by 2 times a week as a maintenance dose. The patients were asked to come for routine follow up following the surgery.

Case Illustration

First case

A 30 year old mild hemophilic male was presented with a 3-years history of progressive swelling in his left pelvis. He came in with a recurrent swelling of the joints, specifically the knee and elbow joints up to 5 times a year. Upon examination, the mass was found to be solid with cystic parts, non-tender, with bluish, smooth overlying skin and an ill-defined margin. Examination of the ROM exhibited a normal range of motions of the hip joints. Laboratory assays showed an haemoglobin count of 9.3 g/dl, hematocrits level of 28%, a WBC count of 5300/mm³ and a platelet count of 402 x 10³ /mm³. Bleeding time analysis showed a prothrombin time (PT) of 11.3 seconds and activated partial thromboplastin time (APTT) of 56.4 seconds, as well as a factor VIII level of 5.6% with a negative anti-factor VIII.

Pelvic radiographs taken before the surgery showed expansile and extensive lytic lesion demarcated by calcification from the ilium to the left inferior iliac spine with cortical thinning and soft tissue swelling around it [Figure 1]. Magnetic Resonance Imaging (MRI) showed a lobulated, homogenous mass size 5.4 x 6 x 9 cm with a well-defined margin and a hyperintense appearance on T1 and T2-weighted images. On fat suppression, it was shown that the mass protruded ventrally, reaching the sacrum and destroying the acetabulum, femoral head, and left ilium, while the medial border of the pseudotumor pushed the left iliopsoas muscle [Figure 1].

The patient was diagnosed with haemophilic pseudotumor of the left ilium and was treated with 2500 units of factor VIII concentrates twice a day for 2 weeks, and was given a maintenance dose of 1000 units of the same for 2 times a week. It was decided to evacuate the hematoma and reconstruct the acetabulum with a modified Harrington procedure, as well as to perform a total hip arthroplasty. This case was presented in another journal (9).

One year following the surgery, the patient was in a good condition and was able to perform day-to-day tasks normally. Three years after the initial surgery (2013), the patient had to undergo re-debridement as the emergence of a new hematoma was causing bleeding, fistula and infection. This was due to the inadequacy of factor VII level maintenance and unrestricted daily activities. A year following after (2014), the patient underwent another debridement for the same reason, and from a follow-up period from 2015 up to 2017, it was found that

the fistula remained and the infection was progressive.

Second case

A 30-year old moderate HemophiliaA male had repetitive swelling and hematoma on the right proximal femur region for four years prior to admission. One year before admission, he was unable to walk due to proximal femoral fracture. Physical examination showed a mass in the right femur region with a bluish overlying skin, venectation, firm with the cystic part, smooth surface with ill defined without any tenderness. It was a suppurative in dimension 10x10x5 cm. Both active and passive range of movements of the hip joint was limited due to pain.

Laboratory findings showed PT of 12.8 seconds (normal 9.8-11.2 seconds), APTT of 65.8 (normal ≤ 33.3 seconds), and factor VIII activity 1 % with negative inhibitor. Femoral radiographs revealed a huge soft tissue mass in the proximal femur, a pathological fracture in the midshaft of the femur with the destruction of proximal segment (which disappeared),expansile lytic lesion with ground glass appearance on the left iliac bone, multiple septations accompanied by a soft tissue mass [Figure 2].

MRI demonstrated multiloculated cystic lesions, a heterogeneous structure with hypo-intense area resembling a blood clot. The fluid-fluidlevel was also demonstrated which was consistent with a bleeding [Figure 2]. The mass extended proximally reaching the femoral head and destroying the bone.The MRI conclusion was consistent with hemophilic pseudotumor.

The patient was diagnosed with huge hemophilic pseudotumour of the right femur with pathological fracture and ulceration. The patient refused amputation, so he underwent evacuation of the hematoma, debridement, and hemiarthroplasty of the right hip. Furthermore,1500 units of factor VIII concentrates was administered twice a day for a week, followed by 1000 units 2 times a week as a maintenance dose. One

hour before surgery, the patient was given factor VIII concentrates to increase the level to 100%. After the surgical procedure, the wound became complicated by infection. Five months later, the prosthesis was dislocated. Multiple grade II-III ulcer was seen on the sacrum region.The patient underwent hip disarticulation procedure with complete wound healing.

Third case

A 39-year-old mild Haemophilia-A was referred due to bleeding after orthopedicsurgery.There was a history of a lump on his right ankle for two years before admission. The lump progressively increased in dimension (2 cm to 12 cm) [Figure 3]. Laboratory findings revealed a hemoglobin level of 7.0 g/dL, white blood cell (WBC) count 15,200/mm³, and platelet count 553 x 10³/mm³. The radiologic study demonstrated osteolytic-geographic lesion at distal fibula, the thickening and irregularity of the tibial and fibular cortex with the periosteal reaction in the distal region [Figure 3].

The orthopedic surgeon in that hospital diagnosed as primary benign bone tumor giant cell tumor with differential diagnosis as an aneurysmal bone cyst. The patient underwent intralesional curettage for removing the lump. Unfortunately, uncontrolled bleeding from the lump and surrounding tissue occurred during surgery. The patient was referred to our hospital with severe hematoma and surgical wound dehiscence after two surgeries .Coagulation test revealed factor VIII was 23%, consistent with mild Heamophilia-A. We decided to to carry out above knee amputation.

Factor VIII concentrates was administered a week ahead of the maintenance dose. The initial dose of the factor VIIIconcentrates was 1500 units once daily. On day 2 and 3, factor VIII concentrates was given 1500 units twice daily, followed by 1000 units twice daily on day 4 to day 7.The bleeding was managed well and the surgical wound healed. The patient could go on with daily activity using a femoral prosthesis.

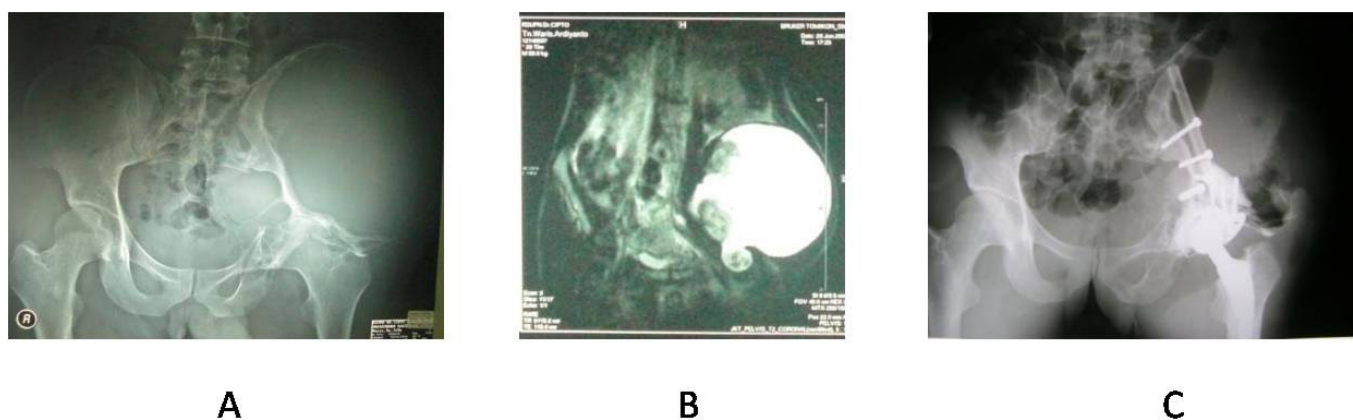


Figure 1. Radiological pictures of a 30 year old with hemophilic pseudotumor of the pelvis. A. Preoperative radiograph showing expansile lytic lesions in the left ilium; B. Coronal MRI shows a homogeneous hyperintense mass with well-defined margin and destroying the acetabulum, femoral head, and left ilium. The medial border of the pseudotumor had pushed the left iliopsoas muscle; C. Postoperative radiograph after acetabular reconstruction with Harrington procedure and total hip arthroplasty.

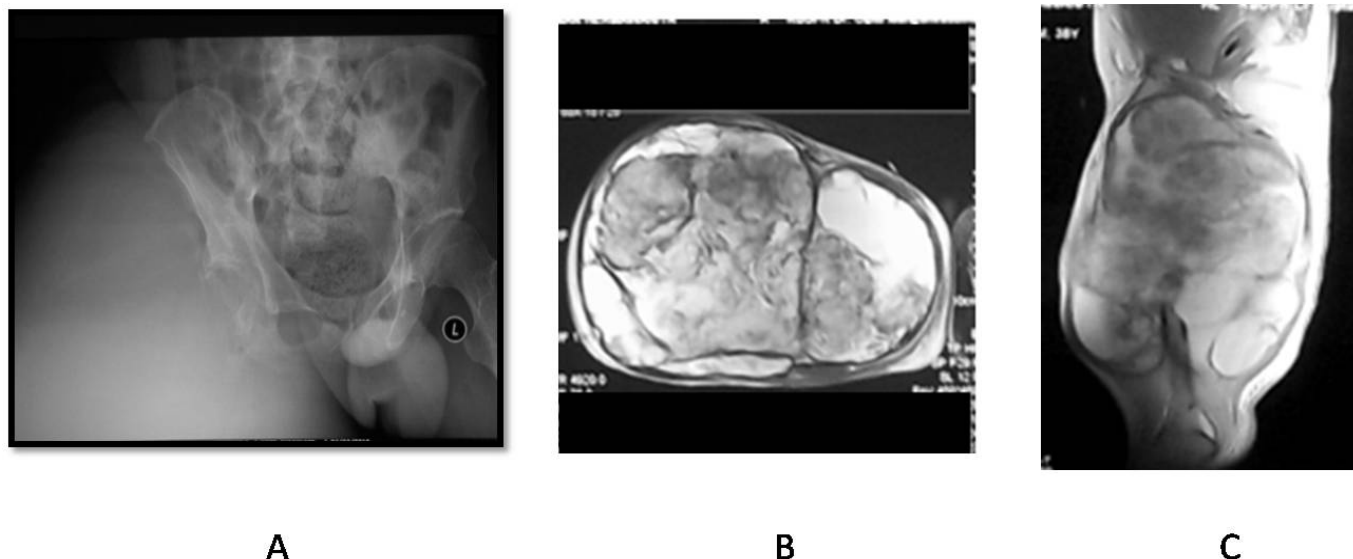


Figure 2. Radiological pictures in a 30-year old moderate Haemophilia A. A) Radiograph of the pelvis revealed the disappearance of right femoral bone with huge soft tissue mass. B and C) Axial and sagittal MRI showed multiloculated cystic masses related to each other, the heterogeneous structure with hypo-intense area in all sequences resembling a blood clot. The pictures were taken from ref no 9.

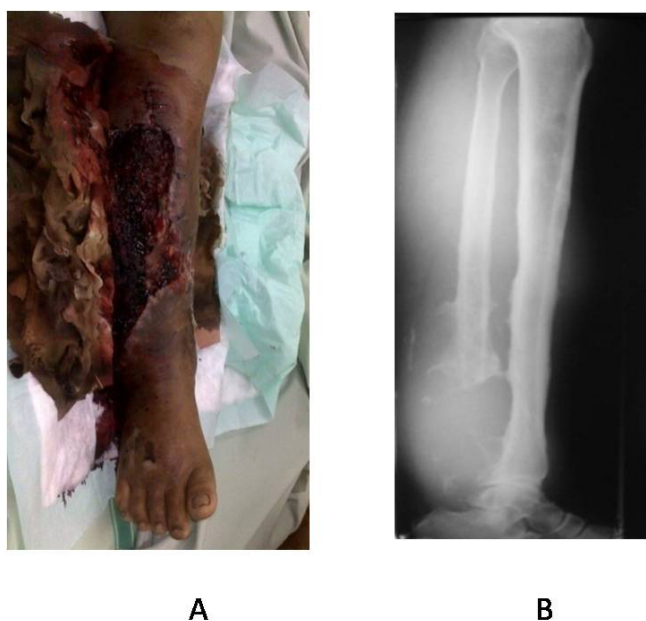


Figure 3. A. Clinical presentation of right lower leg demonstrated large ulcer on the lateral side with necrotic tissue. B. Radiograph of the lower leg demonstrated osteolytic-geographic lesion at distal fibula, thickening and irregularity of the tibial and fibular cortex with the periosteal reaction in the distal region.

Fourth case

A 15-year old male presented with hemophilic pseudotumor at the right iliopsoas muscle. The

patient was diagnosed with moderate Haemophilia A since 13 years ago and treated with the antihemophilic factor. For 1.5 years before admission, he suffered from pain in his right inguinal and progressive lump on the right hip. He had a limitation in daily activity that ended up with an inability to walk two months before admission. On physical examination, right hip and knee flexion deformity were observed. There was a mass over the lower right quadrant of the abdomen (iliopsoas muscle right to groin region), tender with smooth overlying skin and ill-defined margin.

Laboratory findings showed Hb level of 9.9 g/dL, WBC count 5,490/mm³, and platelet count 317 x 10³/mm³, PT 15.6 (normal <12), APTT 163.2 (normal <34) seconds respectively and factor VIII was 1%. Radiographic finding of the pelvis showed a soft tissue mass on right iliopsoas muscle with no evidence of bone destruction.

MRI examination revealed a lesion at the right iliopsoas muscle, hyper-intense on the peripheral area of the lesion with central isointense on T1W1, heterogenous hyper-intense on T2W1 with hypo-intense margin size 18 x 7.5 x 10 cm. The mass expansion was seen from the right intra-abdominal side of the right inguinal region, along with the right iliopsoas muscle. In conclusion, this finding resembled a prominent hematoma on the right iliopsoas muscle which widened into the right groin region. As a standard of care, the patient was managed with F VIII concentrates perioperatively.

Fifth case

A 15-year old boy with hemophilic pseudotumor at the right inguinal region. The patient was diagnosed with moderate Haemophilia A since he was 1 year old. He had an antihemophilic factor on demand routinely.

The patient presented with pain on the right inguinal since 2 days before admission. He suffered from severe persistent pain accompanied by a tingling sensation on the plantar foot and tip of toe when he attempted to straighten the hip. History of repetitive right knee and the left hip pain was noticed but the symptoms subsided spontaneously. Laboratory findings showed hemoglobin level of 13.5 g/dL, WBC count 12,630/mm³, and platelet count 337 x 10³/mm³, PT and APTT 10.6 (normal <12) and 152.2 (normal <34) seconds respectively, and factor VIII activity was 4.9%. The radiographic examination revealed no sign of fracture or any abnormalities on the pelvis. MRI demonstrated heterogeneous hyperintense lesion on T1 weighted and T2 weighted on the right iliopsoas muscle extending from the cranial into caudal with the size of 16.5 x 7.5 x 6 cm. The lesion was consistent with hematoma or haemophilic pseudotumor. The ultrasonography examination indicated internal bleeding of iliopsoas muscle. We performed the evacuation of hematoma. Adequate perioperative management with F VIII concentrates, delivered a successful surgical procedure.

Sixth case

A 13-year old boy mild hemophilia A presented with a lump on the right knee since 5 weeks prior to admission. The patient slipped and fell down while he was walking. The right knee hit the ground and there were excoriation and swelling. The physical examination showed ulceration and necrotic tissue with the size of 20x15x3 cm. There was no active bleeding and pus. The movement of the right knee was limited. Laboratory

findings revealed hemoglobin level of 8.7 g/dL, WBC count 8,510/mm³, and platelet count 435 x 10³/mm³, PT and APTT 11.6 (normal < 12) and 109 (normal < 34) seconds respectively, and factor VIII activity was 10.4%.

Radiographic examination of lower leg revealed a soft tissue mass on the anterior side, the proximal lower leg with differential diagnosis was haemophilic pseudotumor. The MRI examination revealed iso-intense in T1 weighted with few multifocal hyper-intense areas and heterogen-hyper-intense in T2W1. In conclusion, there was a soft tissue mass with various bleeding ages that suitable is for haemophilic pseudotumor with widening to the femorotibial and femoropatellar joint, erosion of the anterior epimetaphysis tibia associated with bone marrow oedema. We performed wide excision procedure and defect closure with split thickness skin graft together with FVIII perioperative management.

We summarized the demographic detail of those above patients in the following table.

Results

A total of six cases of hemophilic pseudotumor underwent surgical intervention. One case underwent hematoma evacuation, acetabular reconstruction with modified Harrington procedure, and total hip arthroplasty. Two of six cases were treated with hematoma evacuation only and the other two cases were treated with limb ablation. Another patient underwent marginal excision which was followed by soft tissue coverage.

We summarized the demographic detail of those above patients in the table 1.

Table 1. Demographic, location and type surgical intervention of the patients						
	Patient 1	Patient 2	Patient 3	Patient 4	Patient 5	Patient 6
Gender	Male	Male	Male	Male	Male	Male
Age	30	30	39	15	15	13
Pseudo-tumour location	Pelvic bones	Right Proximal femur	Right lower leg	Pelvic right iliopsoas	Pelvic right iliopsoas	Right proximal tibia
Bone or joint involvement	Destruction of left ilium and ischium	Pathological femoral fracture	Destruction of distal fibula	No bone involvement	No bone involvement	Epimetaphyseal erosion of tibia only
Management	Hematoma evacuation, acetabular reconstruction (modified Harrington procedure and total hip arthroplasty)	Long stem Austin Moore prosthesis (hemiarthroplasty) Followed by hip disarticulation due to infection and prosthesis dislocation	Transfemoral amputation due to severe soft tissue damage and infection, followed by above knee prosthesis	Hematoma evacuation and wound closure	Hematoma evacuation and wound closure	Excision and soft tissue coverage
Outcome	Good condition and could work normally. Recurrent and infection after 3 years. Patient had deridements (2x)	Wound healed after hip disarticulation	Able to do daily activity using prosthesis	No recurrence	No recurrence	No recurrence
Post Surgical Complication Factor VIII	Recurrence and infection after 3 years 5,6%	No complication 1%	No complication 23%	No complication 1	No complication 4,9%	No complication 10,4%

Discussion

Pseudotumour as a complication of hemophilia is rare, occurring in only 1% to 2% of patients (10). Hemophilic pseudotumor is as a result of repeated episodes of bleeding into a soft tissue (soft tissue pseudotumor case no 4-6), or bleeding at a bone fracture site (case no 2) or as a result of sub-periosteal hemorrhage (case no 1 and 3) (11-13). Inadequate resorption of extravasated blood results in an encapsulated area of clotted blood and necrosed tissue. With successive hemorrhagic episodes, these lesions expand over time, eventually causing clinical symptoms by mass effect (11-13).

Unfortunately, most of hemophilic pseudotumors frequently remain painless and asymptomatic, until it may enlarge and compress adjacent structures and cause pathological fractures, skin and soft-tissue necrosis, fistula, infection (5, 9). Initially, the symptoms of pseudotumors can be asymptomatic and stable for some time. Pain complaints usually are felt when there are symptoms of nerve compression, fracture, and instability. Therefore, all clinicians, especially general practitioners, internists, pediatricians and orthopedic surgeons, the presence of a slowly enlarging mass in a patient with hemophilia should raise the suspicion of a pseudotumors.

Pseudotumors hemophilia may occur in different degrees of hemophilia, especially those with severe hemophilia (4, 10). It is demonstrated with our cases, where case no 1,3, and 6; case 5; and case no 2 and 4 are classified as mild, moderate and severe respectively. Those findings were consistent with another study, Magallon et al.stated that the incidence of hemophilic pseudotumor is not significantly different among patients with mild, moderate, or severe haemophilia (12).

Beside clinical history above, radiological examinations are very important to hemophilic pseudotumor diagnosing and to differ from the other tumors or tumor like lesions. In the advanced stage, hemophilic pseudotumor is often accompanied by radiographic evidence of bone involvement. The radiological features are typical with a large soft-tissue mass and areas of adjacent bone destruction (14, 15).

On radiographs, intraosseous pseudotumors appear as well defined, unilocular or multilocular, expansile lytic lesions of variable size with geographic pattern of bone destruction. These may occur in any portion of the tubular bones, and these may be intramedullary or eccentric and may show endosteal scalloping, cortical thinning, peripheral sclerosis, as well as dystrophic calcification. The lesion may be quite destructive and completely replace the involved bone, resulting in deformity and or pathologic fracture. The various radiographic differentials that merit consideration are primary and secondary bone neoplasms (giant cell tumor, plasmacytoma, telangiectatic osteosarcoma, metastatic lesion), or tumor-like lesions (aneurysmal bone cyst, brown tumor, solitary bone cyst), and infection) (14,15). In this case series, the bone lesion

in case no.1 and 2 demonstrated similar geographic osteolytic patterns with giant cell tumor, aneurysmal bone cyst, osteomyelitis or soft tissue sarcoma with apathological fracture.

A CT scan may differentiate the pseudotumors from the other tumor. In hemophilic pseudotumor involving the bone, CT scan may help us by better depicting crossing trabeculae, cortical change, periosteal reaction, and anatomical extent. Tumor size and its extension to the adjacent bone or soft tissue is able to be demonstrated clearly. The most important thing is it may be useful in determining the stages or hemorrhage, the surgical indication and the surgical planning of hemophilic pseudotumor (15,16).

MRI has the characteristic appearance of a multiloculated lesion containing fluid components having heterogeneous signal intensity on various sequences, reflecting the presence of blood. It is a sensitive and accurate modality in diagnosing hemophilic pseudotumor. On MRI, pseudotumor shows a heterogeneous low- and high-signal intensity areas found in the pseudotumor that reflects the presence of blood supply in various stages of the disease (14, 15).

Diagnosis of pseudotumors is important to be enforced earlier before attempting some invasive diagnosis or surgical procedures such as biopsy, percutaneous drainage or more aggressive surgery. Such intervention procedure mentioned above is contraindicated to be performed due to the risk of complications followed such are life-threatening bleeding, the formation of a fistula, coagulation factor inhibitor formation, pseudotumor recurrence, pathological fracture and infection (8, 9, 14).

Treatment of hemophilic pseudotumor is still challenging, especially in patients with large masses and with extensive bone destruction (17). Currently, there is no consensus about the treatment for hemophilic pseudotumor. It depends on lesion location, size, patients' characteristics and method of management (8, 18).

Most hemophilic pseudotumors require surgical intervention (2, 8). Studies about the surgical management of hemophilic pseudotumors are scarce and the results are varied (10). Therefore, the choice of treatment should be tailored for each patient according to the size of pseudotumor, site of involvement and the presence of inhibitors (8, 17).

Conservative treatment is suitable for superficial pseudotumors (8). The indications of surgical intervention include: a lesion with an unsuccessful history of conservative treatment, enlarging of the mass after coagulation factor therapy or the necessity to do joint reconstruction, debridement of severe infection that need amputation (2, 8, 14). It is a preferable treatment for pseudotumor that has been present for years like in our case series. In addition, all the patients who came to our center had pseudotumor and had enormous mass size and deep location. Surgical decisions may be made regardless of the success of replacement therapy in the event of severe pain, drainage of spontaneous bleeding in the skin, the risk

of fracture, and a very large mass (6).

Beside its complicated nature, the surgical intervention of hemophilic pseudotumor is very expensive and has potential complications. Moreover, 25%–30% of the global population with hemophilia has no primary prophylaxis available due to its tremendous cost (19). In other words, we have to consider the thorough aspects of the treatment and patient as a whole including the type of surgery (salvage or amputation, surgical technique), antihemophilic factor doses and costs, prognosis, what the patients needs, the general condition of the patient, etc.

Previous studies mentioned that surgical intervention is curative for most pseudotumors, but is fraught with risks of massive life-threatening hemorrhage, infection, and limb amputation (8, 14, 17, 20). Given the risks associated with surgical intervention of pseudotumors, a decision to apply it to a hemophilic pseudotumors cannot be undertaken lightly. All orthopedic surgical procedures must be performed with adequate clotting factor coverage. This means that the hematologist in charge must perform the intravenous infusion of the deficient factor, plasma-derived or recombinant, at the right dose and during the right period of time, to achieve appropriate hemostasis during the entire perioperative period (19).

Ideally, pseudotumors in long bones should be excised en bloc and the bone defect stabilized. Prosthetic replacement could be considered for a massive bone and joint defect (8). Should the salvage surgery be indicated (case no 1,4,5 and), we conducted intralesional excision “evacuation of the hematoma” completely as possible and decreased death space by suturing “relatively healthy tissue” or filled the defect with bone graft or bone cement and followed bone or joint reconstruction. However, in case no 2 and 3 where those patients had an old fracture with huge pseudotumor, severe infection, and extensive soft tissue involvement, amputation was considered the best option. Previous studies mentioned old fracture with huge pseudotumor, severe infection, and extensive soft tissue involvement (deficient muscle coverage) should be considered for amputation (10).

Eliminating the dead space after resection of the cyst is difficult. Many methods had been employed, including filling it with fibrin glue, the use of muscles, Dexon mesh, and bone grafting (8, 21-23). In our case series, we also filled the dead space based on the previous study, but didn't use mesh or omentum. Bone cement had been used to fill the dead space at the pseudotumor of the pelvis. Unfortunately, the fistula recurred, and the pedicled rectus abdominis muscle flap was used to obliterate the dead space. Bone cement is not advocated to obliterate the dead space. Resection of the iliac rim could decrease dead space to a minimum. Alternatively, transposition of omentum into the dead space or free transfer of the latissimus dorsi muscle might also be carried out 3 years after surgery. It's also reported by Heeg et al (21).

Furthermore, surgical excision should be carried out only at major hemophilic centers by a multidisciplinary

surgical team, including hematologists, orthopedic surgeons, physical medicine and rehabilitation physicians, physiotherapists and specialized nurses (23). If this is achieved, orthopedic surgical procedures (19, 24). The six patients treated at our center were treated in an integrated manner with a hematologic expert.

There has been reported treatment modalities other than surgical resection with varying degrees of success including; radiation therapy, combination of radiation with factor replacement, embolization and puncture and aspiration of the pseudotumor either alone or in combination with human fibrin and rifampicin, or with an osteal graft without removing the pseudocapsule (17, 24-28). It is hoped that with the advent of widespread maintenance therapy, pseudotumors will be less common in the future. It is important that they are diagnosed early, and prevention of muscular hematoma is key to reducing their incidence (29).

Surgery, limb salvage or amputation, is a preferable treatment for pseudotumors that have been present for years. It's associated with the best outcomes, especially when selected as the primary line of treatment. The main concern associated with limb salvage or amputation is determined by soft tissue involvement. The risk of uncontrollable hemorrhage during surgery is preventable with the availability of Factor VIII or IX concentrates. Recurrence after surgery occurs in the surrounding tissues left after pseudotumor removal. Thus, this review may provide a better understanding of this disease and consequently help in managing and preventing recurrence of this clinical problem. As previously published by many authors, this paper confirms that surgical excision is the treatment of choice but should only be carried out in major hemophilia centers by a multidisciplinary surgical team.

Conflict of interests: The authors declare that there is no conflict of interests regarding the publication of this paper.

Acknowledgements

Writing support was provided by Rheza Fabianto, MD.

Achmad Fauzi Kamal MD PhD

Aryadi Kurniawan MD PhD

Department of Orthopaedic and Traumatology Dr.Cipto Mangunkusumo General Hospita, Faculty of Medicine, University of Indonesia, Jakarta, Indonesia
Integrated Hemophilia Team Dr. Cipto Mangunkusumo General Hospital, Faculty of Medicine, University of Indonesia, Jakarta, Indonesia

Agus Waryudi MD

Department of Orthopaedic and Traumatology Dr.Cipto Mangunkusumo General Hospita, Faculty of Medicine, University of Indonesia, Jakarta, Indonesia

Anna Mira Lubis MD
Department of Internal Medicine Dr.Cipto Mangunkusumo
General Hospital, Faculty of Medicine, University of
Indonesia, Jakarta, Indonesia
Integrated Hemophilia Team Dr. Cipto Mangunkusumo
General Hospital, Faculty of Medicine, University of
Indonesia, Jakarta, Indonesia

Djayadiman Gatot MD
Department of Paediatric Dr.Cipto Mangunkusumo
General Hospital, Faculty of Medicine, University of
Indonesia, Jakarta, Indonesia
Integrated Hemophilia Team, Dr. Cipto Mangunkusumo
General Hospital, Faculty of Medicine University of
Indonesia, Jakarta, Indonesia

References

- Rodriguez-Merchan EC. Musculoskeletal complications of hemophilia. *HSS J*. 2010; 6(1):37-42.
- World Federation of Hemophilia. 2nd Guidelines for the management of hemophilia. Montreal: World Federation of Hemophilia; Blackwell Publishing Ltd; 2005.
- Ghosh K. Management of haemophilia and its complications in developing countries. *Clin Lab Haem*. 2004; 26(4):243-51.
- Garcia-Perez R, Torres-Salmeron G, Sanchez-Bueno F, Garcia-Lopez A, Parrilla-Paricio P. Intraabdominal hemophilic pseudotumor: case report. *Rev Esp Enferm Dig*. 2010; 102(4):275-80.
- Rodriguez-Merchan EC, Goddard NJ. Muscular bleeding, haematomas, and pseudotumours. In: Rodriguez-Merchan EC, Goddard NJ, Lee CA, editors. *Musculoskeletal aspects of hemophilia*. Oxford: Blackwell Science; 2000. P. 85-90.
- Panotopoulos J, Ay C, Trieb K, Funovics PT, Stockhammer V, Lang S, et al. Surgical treatment of the haemophilic pseudotumour: a single centre experience. *Int Orthop*. 2012; 36(10):2157-62.
- Duarte ML, Duarte ER, Solorzano EB. Hemophilic pseudotumor – a rare complication. *Rev Bras Hematol Hemoter*. 2017; 39(1):84-5.
- Dagli M, Kutlucan A, Abusoglu S, Basturk A, Sozen M, Kutlucan L, et al. Evaluation of bone mineral density (BMD) and indicators of bone turnover in patients with hemophilia. *Bosnian J Basic Med Sci*. 2018; 18(2):206.
- Kamal AF, Sukrisman L, Dilogo IH, Priyamurti H, Qomaruzzaman MN. Pelvic haemophilic pseudotumour: a case report. *J Orthop Surg*. 2014; 22(2): 263-8.
- Park JS, Ryu KN. Haemophilic pseudotumour involving the musculoskeletal system: spectrum of radiologic findings. *Am J Roentgenol*. 2004; 183(1):55-61.
- Kamal AF, Pradana AS, Prabowo Y. Bilateral iliopsoas haemophilic “soft tissue pseudotumours”: a case report. *Inter J Surg Case Rep*. 2015; 13(1):19-23.
- Magallon M, Monteagudo J, Altisent C, Ibanez A, Rodriguez-Perez A, Riba J, et al. Hemophilic pseudotumor: multicenter experience over a 25-year period. *Am J Hematol*. 1994; 45(2):103-8.
- He Y, Zhou X, Cui H, Qiu G, Weng X, Zhang B, et al. Surgical management of haemophilic pseudotumors: experience in a developing country. *J Invest Surg*. 2017; 32(2):127-36.
- Kerr R. Imaging of musculoskeletal complications of hemophilia. *Semin Musculoskelet Radiol*. 2003; 7(2):127-36.
- Maclachlan J, Gough-Palmer A, Hargunani R, Farrant J, Holloway B. Haemophilia imaging: a review. *Skelet Radiol*. 2009; 38(10):949-57.
- Pettersson H, Ahlberg A. Computed tomography in hemophilic pseudotumor. *Acta Radiol Diagn (Stockh)*. 1982; 23(5):453-7.
- Espandar R, Heidari P, Rodriguez-Merchan EC. Management of haemophilic pseudotumours with special emphasis on radiotherapy and arterial embolization. *Haemophilia*. 2009; 15(2):448-57.
- Lim MY, Nielsen B, Ma A, Key NS. Clinical features and management of hemophilic pseudotumors: a single US centre experience over a 30-year period. *Hemophilia*. 2014; 20(1):e58-62.
- Rodriguez-Merchan EC. What’s new in orthopedic surgery for people with hemophilia. *Arch Bone J Surg*. 2018; 6(3):157-60.
- Keller A, Terrier F, Schneider PA, Bianchi S, Howarth N, De Moerloose P. Pelvic hemophilic pseudotumor: management of a patient with high level of inhibitors. *Skeletal Radiol*. 2002; 31(5):550-3.
- Meer JV, Horn JV. Excision of a haemophilic pseudotumour of the ilium, complicated by fistulation. *Haemophilia*. 1998; 4(2):132-5.
- Dagli M, Kutlucan A, Abusoglu S, Basturk A, Sozen M, Kutlucan L, et al. Evaluation of bone mineral density (BMD) and indicators of bone turnover in patients with hemophilia. *Bosn J Basic Med Sci*. 2018; 18(2):206-10.
- Kang JO, Cho YJ, Yoo MC, Hong SE. Hemophilic pseudotumor of the ulna treated with low dose radiation therapy: a case report. *J Korean Med Sci*. 2000; 15(5):601-3.
- Rodriguez-Merchan EC. Haemophilic cysts (pseudotumours). *Haemophilia*. 2002; 8(3):393-401.
- Rodriguez-Merchan EC. The haemophilic pseudotumour. *Haemophilia*. 2002; 8(1):12-6.
- Ozbek N, Unsal M, Kara A, Gumruk F, Gurgey A. Treatment of hemophilic pseudotumor with low-dose radiotherapy. *Turk J Pediatr*. 1996; 38(1):91-4.
- Issaivanan M, Shrikande MP, Mahapatra M, Choudhry VP. Management of hemophilic pseudotumor of thumb in a child. *J Pediatr Hematol Oncol*. 2004; 26(2):128-32.

THE ARCHIVES OF BONE AND JOINT SURGERY. ABJS.MUMS.AC.IR
VOLUME 7. NUMBER 6. NOVEMBER 2019

SURGICAL TREATMENT OF HEMOPHILIC PSEUDOTUMOR

28. Pisco JM, Garcia VL, Martins JM, Mascarenhas AM. Hemophilic pseudotumor treated with transcatheter arterial embolization: case report. *Angiology*. 1990; 41(12):1070-4.

29. Bellinazzo P, Silvello L, Caimi MT, Baudo F, deCataldo F. Novel surgical approach to pseudotumour of ilium in haemophilia. *Lancet*. 1989; 2(8675):1333-4.