

RESEARCH ARTICLE

Epidemiologic Characteristics, Clinical Behavior, and Outcome of the Giant Cell Tumor of the Bone: A Retrospective Single-center Study

Khodamorad Jamshidi, MD; Amin Karimi, MD; Alireza Mirzaei, PhD

Research performed at Baharestan Square, Shafa Orthopedic Hospital, Tehran, Iran

Received: 25 September 2018

Accepted: 15 October 2018

Abstract

Background: Giant cell tumor of bone (GCTB) is a locally aggressive lesion with an unpredictable behavior. Herein, the aim of this study was to evaluate the epidemiological characteristics, as well as clinical and functional outcomes of GCTB in a relatively large series of patients.

Methods: Patients with the diagnosis of GCTB were included in this retrospective study. Whenever the preservation of the articular surface was possible, surgical options included extended curettage; otherwise, wide resection was implemented. In case of extended curettage, the cavity was filled with cement or bone graft. In addition, the functional and oncologic outcomes of these surgical strategies were compared. The functional outcome of the patients was assessed using the Musculoskeletal Tumor Society (MSTS) scoring system.

Results: A total of 120 GCTB patients, including 55 males (45.8%) and 65 females (54.2%), were evaluated. The three involved locations with highest frequency included distal femur (26%), distal radius (22%), and proximal tibia (19%). At a mean follow-up of 125.5±49.2 months, two pulmonary metastases (1.6%) and 12 (10%) local recurrences were observed. In addition, 6 out of 12 (50%) local recurrences occurred in distal radius ($P=0.04$). The recurrence rate was significantly higher in extended curettage than in wide resection ($P=0.05$), and the same pattern was observed for allograft, compared to cement filling ($P=0.05$). The mean MSTS scores for extended curettage and wide resection were 94.7 and 89.1, respectively ($P=0.04$). Furthermore, the mean MSTS scores for bone graft filling and cement augmentation were obtained as 96 and 93.1, respectively ($P=0.07$).

Conclusion: Based on the findings, wide resection of GCTB was associated with superior oncologic outcome, as well as inferior functional outcome. In extended curettage, cement augmentation resulted in superior oncologic outcome when compared with allograft filling.

Level of evidence: IV

Keywords: Epidemiologic characteristics, Functional outcome, Giant cell tumor of bone, Oncologic outcome

Introduction

Giant cell tumor of bone (GCTB) is an osteolytic tumor which was first described by Cooper and Travers in 1818 (1). It accounts for approximately

6% of all primary bone tumors (2). Although generally considered as a benign tumor, GCTB is a locally aggressive lesion with an unpredictable behavior. It is histologically

Corresponding Author: Amin Karimi, Bone and Joint Reconstruction Research Center, Shafa Ortopaedic Hospital, Iran University of Medical Science, Tehran, Iran
Email: aminkarimi79@yahoo.com



THE ONLINE VERSION OF THIS ARTICLE
ABJS.MUMS.AC.IR

characterized by multinucleated giant cells in the context of mononuclear stromal cells (3). In spite of its benign nature, it has a recurrence rate of 0-65% depending on the local presentation of the tumor and the type of treatment (4).

The GCTB is also associated with histologically benign pulmonary metastases, which is estimated to occur in 1-4% of GCTB patients (4). Most of the GCTB cases occur in adults aged 20-40 years (2, 5). Distal femur, proximal tibia, and distal radius are considered as the three most common locations of GCTB, respectively (6). Several reports have highlighted a slight predominance of GCTB incidence in women in comparison with that in men (5).

Although rarely lethal, GCTB might be associated with a substantial destruction of the local bony structure. This tumor could be troublesome to manage, particularly in pre-articular regions (5). The treatment is aimed to eradicate the tumor, preserve limb function, and prevent local recurrence and distant metastasis. Historically, GCTB has been managed with intralesional curettage, with a recurrence rate of as high as 60%. On the contrary, wide excision has been associated with a lower risk of local recurrence (0-12%), while having poorer functional outcomes (5, 7, 8). However, the behavior of GCTB is unpredictable and is not always associated with surgical, radiographical, or histological characteristics of the lesion (9).

With this background in mind, the present study was conducted to evaluate the epidemiologic characteristics, clinical behavior, and functional and clinical outcomes of GCTB in a single-center study. To this end, two different surgical strategies, including wide resection and extended curettage, were adopted in this study.

Materials and Methods

The current study was approved by the review board of our institute. Informed consent was obtained from the patients or their parents for publishing their medical data. The medical records of patients diagnosed with GCTB, who were referred to our center and underwent surgery between 1996-2016, were retrospectively reviewed. The inclusion criteria were: 1) histological diagnosis of GCTB and 2) a minimum follow-up of 18 months. On the other hand, the exclusion criteria were: 1) previous surgical treatment of GCTB at other centers and 2) GCTB of the axial skeleton.

Out of a total of 156 patients, 25 cases were referred from other centers as a result of local recurrence; however, these patients were excluded from our study. Nine patients were removed from the study due to having a follow-up of fewer than 18 months and incomplete medical data. Moreover, two patients were diagnosed with axial skeleton GCTB and were excluded from the study. Consequently, the study was continued with 120 patients.

The demographic, clinical, and radiological characteristics of the patients, in addition to their functional and oncologic outcomes were evaluated. Preoperative imaging, included plain radiographs of the lesion, computed tomography (CT) scan, magnetic resonance imaging (MRI), and chest radiography. The tumor was radiologically graded, using the Campanacci

staging system (10). Plain radiographs were also used to determine the width of the lesion diameter in relation to the host bone.

In the present study, surgical options included extended curettage or wide resection. Articular surface was attempted to be saved whenever possible. To this aim, extended curettage was applied to the majority of cases. Otherwise, in spite of observing an inferior functional outcome, wide resection and reconstruction were used to reduce the local recurrence rate.

Surgical techniques

For extended curettage, a longitudinal approach was chosen, depending on the most affected cortex. For type III Campanacci lesions, the soft tissue component over the involved area was removed with a margin of 5 mm. The cortical window was widened to access the entire tumor area and avoid overhanging bone ridges. The tumor was then removed with a curette, and the margin was expanded by high-speed burring about 5 mm into the normal cancellous bone and 1 mm into the normal cortical bone. There was an exception for the articular cartilage aspect when the subchondral bone was exposed.

After extended curettage, we used hydrogen peroxidase V10 as a chemical adjuvant therapy and a better visualization of the cavity. Following the extended curettage, the cavity was filled with cement or bone graft [Figure 1]. Bone graft was not used from 2008 based on the recent literature, which recommended cement augmentation, following the intralesional surgery of giant cell tumors (11).

If the cement was used as the filling agent in cases with less than 10-mm intact subchondral bone, the articular surface was supported by a 10-mm flat fresh frozen cancellous allograft (mostly from the femoral head); [Figure 2]. A similar layer of bone graft was utilized to promote the healing of pathologic fracture after reduction and cementation without hardware fixation.

En bloc wide resection was performed to manage cases in which reconstruction was not possible with extended curettage. It included tumors with more than one half of circumferential cortical loss, tumors with articular loss or defect, presence of pathologic femoral neck fracture, and tumors of expendable bones (the proximal part of the fibula or distal part of the ulna). Prostheses, osteoarthicular allografts, or allograft-prosthesis composites were used to reconstruct the bone defects after resection.

Postoperative protocol

The patients' follow-up was performed every 3 months for the first two years after the surgery, every 6 months until the fifth year, and every year afterward. At each follow-up session, the plain radiographs of the involved area and a chest X-ray were taken. The functional outcome of each patient was assessed using the Musculoskeletal Tumor Society (MSTS) scoring system at the last follow-up session.

Statistical analysis

Data analysis was performed in SPSS software

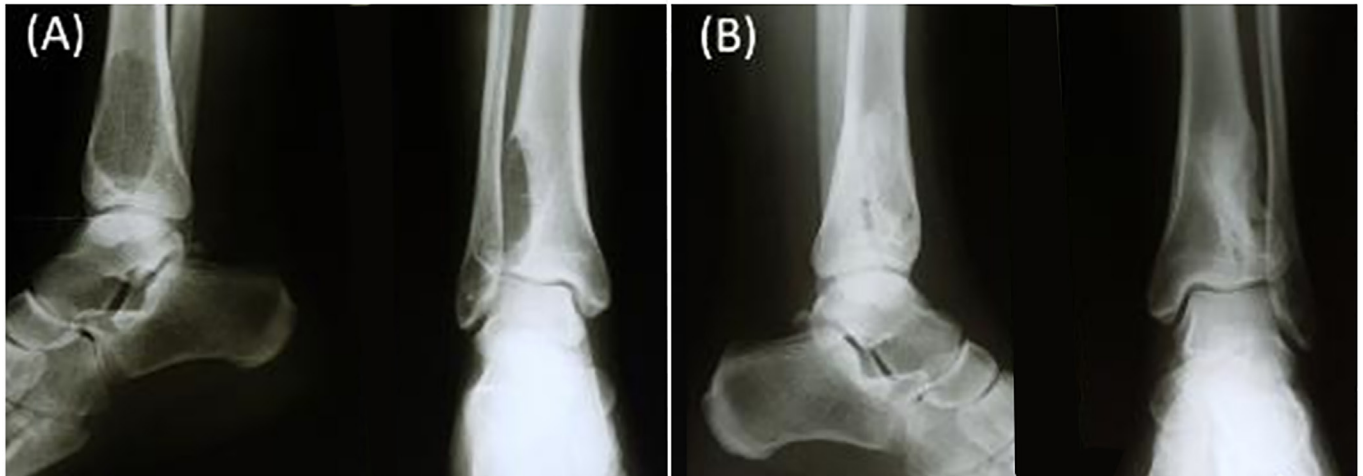

Figure 1. A) Anteroposterior and lateral radiograph of a 25-year-old female with distal tibia giant cell tumor (of bone) B) Two years after extended curettage and bone graft.

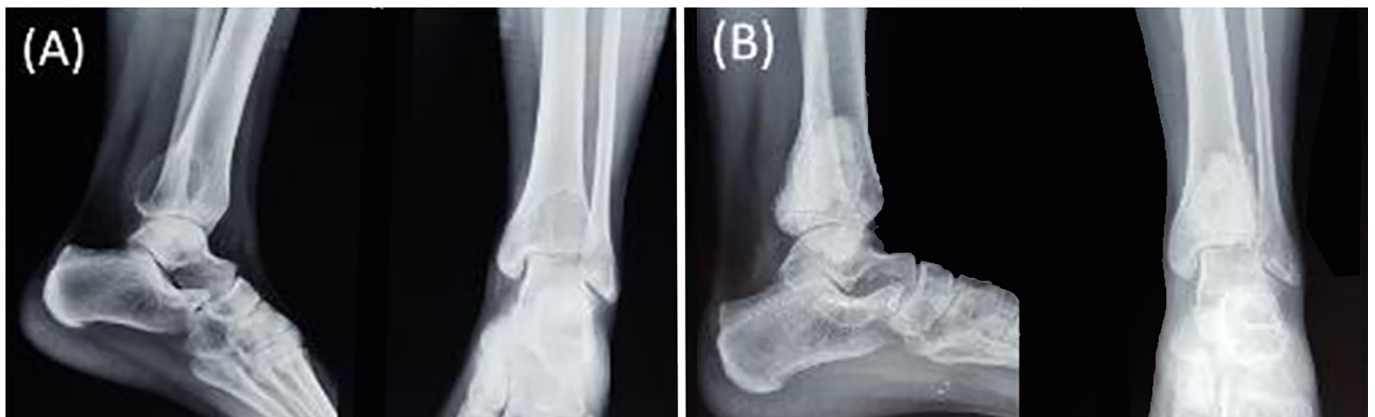

Figure 2. (A) Anteroposterior and lateral radiograph of a 21-year-old female with giant cell tumor of the distal tibia B) Two years after undergoing extended curettage and subchondral bone graft and cementing.

(version 16). The data were descriptively presented as mean±standard deviations or number and percentage. Independent t-test or its non-parametric counterpart (i.e., Mann-Whitney U test) was used for the comparison of the mean differences between the quantitative variables. In addition, the Chi-square test was used for the analysis of the potential association between two qualitative variables. Spearman's correlation coefficient test was also utilized to evaluate potential correlations.

The measurement of the overall and recurrence-free survival of the patients was accomplished using the Kaplan-Meier survival test. Additionally, the log-rank test was used to compare the recurrence-free survival rate of different treatments. In our investigation, a *P-value* less than 0.05 was considered statistically significant.

Results

A total of 65 females (54.2%) and 55 males (45.8%)

with the diagnosis of GCTB were evaluated in this study (a female to male ratio of 1.2:1). The mean age of the patients at the time of the diagnosis was 29.9±11.4 years (age range: 13-69 years). Based on the results, 80 (66.7%) GCTB cases were located at the lower extremity, while the remaining 40 (33.3%) cases were presented at the upper extremity. Distal femur (26%), distal radius (22%), and proximal tibia (19%) were the most three frequent locations, respectively. The mean follow-up period of the patients was 125.5±49.2 months (range: 18-240 months), and the mean width of bone involvement was 73.3±22.6% (range: 25-100%). The clinical and demographic characteristics of the patients are demonstrated in Table 1.

In this study, extended curettage was performed in 99 (82.5%) patients. The defects were augmented with cement and bone graft in 44 (36.7%) and 55 (45.8%) patients, respectively. Wide resection and reconstruction

Table 1. Clinical and demographic characteristics of patients with giant cell tumor of bone

Variable	Mean±SD or Number (%)
Age (year)	29.9±11.4
Bone involvement level (%)	73.3%±22.6%
Gender	
Male	55 (45.8%)
Female	65 (54.2%)
Location	
Lower extremity	80 (66.7%)
Upper extremity	40 (33.3%)
Involved bone	
Distal femur	32 (26.7%)
Distal radius	27 (22.5%)
Proximal tibia	23 (19.2%)
Proximal femur	8 (6.7%)
Distal tibia	7 (5.8%)
Proximal humerus	6 (5%)
Pelvis	6 (5%)
Other	11 (9.1%)
Campanacci grade	
I	29 (24.2%)
II	27 (22.5%)
III	64 (53.3%)
Treatment	
Extended curettage	99 (82.5%)
Wide resection	21 (17.5%)
Filling agent	
Cement	44 (36.7%)
Bone graft	55 (45.8%)
Follow-up (months)	125.5±49.2

Table 2. Distribution of local recurrence with respect to the clinical and demographic characteristics of patients

Variable	Local recurrence Number (%)	P-value
Gender		
Male	8/55 (14.5%)	0.11
Female	4/65 (6.1%)	
Location		
Upper extremity	7/40 (17.5%)	0.1
Lower extremity	5/80 (6.3%)	
Involved bone		
Distal femur	1/33 (3%)	0.04
Distal radius	6/27 (22.2%)	
Proximal tibia	1/23 (4.3%)	
Other	4/37 (16.2%)	
Campanacci grade		
I	1/29 (3.4%)	0.03
II	1/27 (3.7%)	
III	10/64 (15.6%)	
Treatment		
Extended curettage	11/99 (11.1%)	0.05
Wide resection	1/21 (4.7%)	
Filling agent		
Cement	3/44 (6.8%)	0.05
Bone graft	8/55 (14.5%)	

were performed on the remaining 21 (17.5%) patients, 3 cases (14.2%) of the resection group were done in patients presented with the GCTB of expendable bones (distal ulna or proximal fibula). Pathologic fractures were managed with wide resection in two cases and extended curettage in three patients.

In total, 12 (10%) local recurrences were observed in our series. The local recurrence rate was 14.5% (8 out of 55 patients) and 6.1% (4 out of 65 patients) in male and female patients, respectively. This difference was not statistically significant ($P=0.11$). The local recurrence rates were estimated at 3.4% (1 out of 29 patients), 3.7% (1 out of 27 patients), and 15.6% (10 out of 64 patients) in Campanacci grades I, II, and III, respectively ($P=0.03$). In addition, 6 out of 12 (50%) local recurrences were observed in the distal radius, while the remaining 6 (50%) local recurrences were observed in other anatomic locations ($P=0.04$).

The local recurrence rates were obtained as 11.1% (11 out of 99 patients) and 4.7% (1 out of 21 patients) in extended curettage and wide resected tumors,

respectively ($P=0.05$). Moreover, in extended curettage group, a significant association was observed between the local recurrence and filling agent ($P=0.05$). In this respect, 8 out of 11 recurrences of extended curettage occurred in bone graft augmented tumors. Table 2 demonstrates the local recurrence rate with respect to the clinical and demographic characteristics of the patients. Local recurrence was managed with curettage cementation in nine patients and wide resection in the other three patients.

No significant correlation was observed between the rate of local recurrence and age of the patients ($r=0.081$, $P=0.37$). Moreover, local recurrence had no significant correlation with patient follow-up period ($r=0.085$, $P=0.35$) and the width of involvement ($r=0.115$, $P=0.21$). Pulmonary metastasis was seen in two patients, one of whom was diagnosed with distal femur GCT and the other with proximal tibia lesion. However, both of them were managed with a thorax surgeon for metastasectomy, and are still alive.

The total mean MSTS score of the patients was 93.7%. In addition, with regard to extended curettage and wide resection, these mean scores were obtained as 94.7 and 89.1, respectively ($P=0.04$). Regarding the filling agent, the mean MSTS scores for bone graft filling and cement augmentation were estimated at 96 and 93.1, respectively ($P=0.07$).

The 5- and 10-year recurrence-free survival rates of the

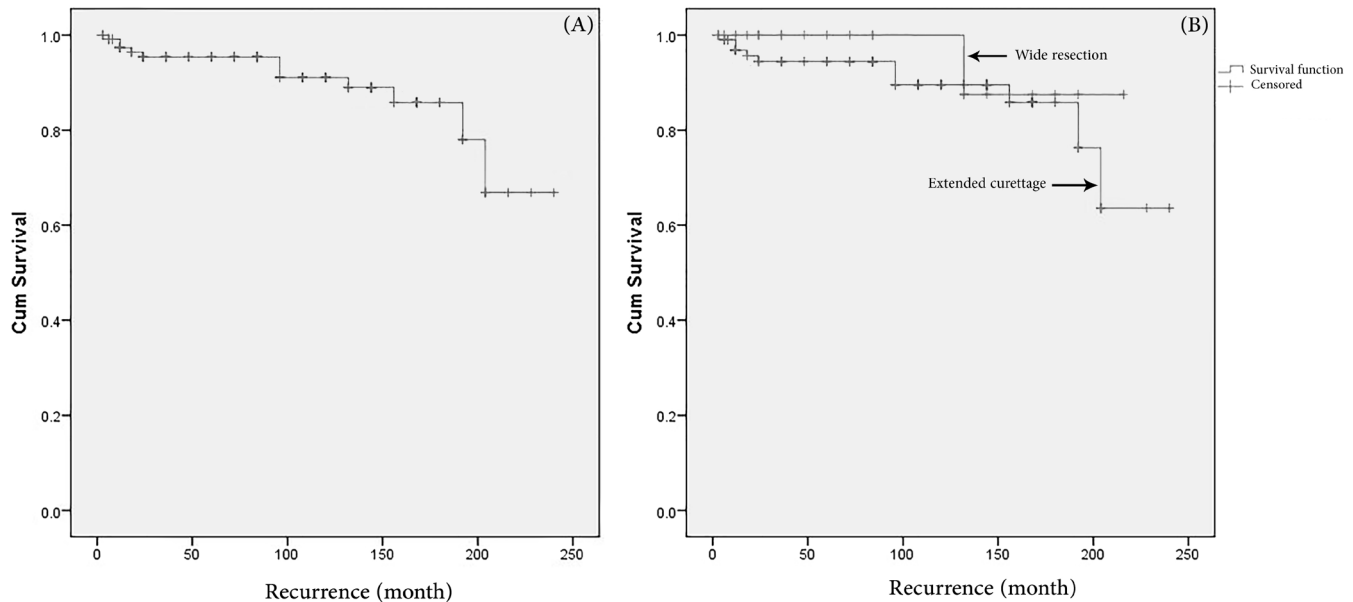


Figure 3. A) Total recurrence-free survival of patients with giant cell tumor of bone, B) recurrence-free survival rate of extensive curettage versus the wide resection of giant cell tumor of the bone.

patients were 94.5% and 91%, respectively [Figure 3A]. In terms of the extended curettage, the 5- and 10-year recurrence-free survival rates were obtained as 94.5% and 89%, respectively. Furthermore, the 5- and 10-year recurrence-free survival of wide resection was 100%. Recurrence-free survival rate was not significantly different between extended curettage and wide resection [$P=0.4$; Figure 3B].

Post-operative complications

Infection occurred 3 months after the surgery in one patient with GCTB of proximal tibia, which was initially treated by extended curettage and cementation. In this respect, the cement was removed and after the irrigation of the infection site, the cavity was refilled with the antibiotic-loaded cement. In this regard, no other post-operative complications were observed in our cohort.

Discussion

The clinical behavior of GCT is still unpredictable, and its correlation with histopathology and treatment is still an enigma (12). Histologically, GCTs are divided into three categories, including typical, aggressive, and malignant. Nevertheless, many authors believe that histology alone is a poor index for the prognosis and clinical behavior of a tumor (13, 14). Recently, many efforts have been made to identify the risk factors which might affect the aggressiveness of GCT. In this respect, age, pathologic fracture, and location of tumor have been associated with the increased risk of local recurrence and metastasis of GCT in many investigations (4, 15-17).

As attempts continue to codify the clinical behavior of GCT, cohort studies evaluating the long-term behavior

of the tumor are of great value. In the present study, the epidemiologic and clinical characteristics of GCTB were assessed, in addition to the oncologic and functional outcomes of the surgery, in a cohort of GCTB patients.

The incidence of GCTB has been reported to be slightly higher in females than in males (4, 18, 19). Such predilection has also been observed in our population, with a male to female ratio of 1:1.2. The mean age of GCTB patients is reported to range within 20-40 years. In accordance with the results of earlier reports, the mean age of our patients was 29.9 years.

Distal femur, proximal tibia, and distal radius are considered the most three common locations of GCTB involvement in a decreasing order, respectively (6). These sites were the most three common locations of GCTB involvement in our cohort, as well. Furthermore, in our series, the distal radius involvement was more common than the proximal tibial involvement (22.5% vs. 19.2%).

The local recurrence rate of GCTB has been reported to be 0-65% depending on the type of treatment and local presentation of the tumor (4). In this regard, the local recurrence rate in our study was measured at 10%. Although the histological grade is not considered a reflection of the aggressiveness of the tumor, various authors have reported an increased rate of local recurrence in grade III lesions (5, 20, 21). From a total of 12 local recurrences of our cohort, 10 cases occurred in patients with Campanacci grade III, which was significantly higher than that in other grades. A higher rate of local recurrence (22.2%) was observed in the distal radius GCTB of our series, which could be justified with the higher percentage of Campanacci grade III in this group.

In a study performed by Miszczyk et al., the size of the tumor was attributed to the risk of the local recurrence of GCTB, while such association was not observed in our series. In this regard, pathologic fracture has also been attributed to the higher aggressiveness of GCT (22-24). Five cases of our series were presented with pathologic fracture, and the tumor recurred in one of them (20%).

In extended curettage, the choice of filling agent was significantly associated with the rate of local recurrence. Therefore, a considerably higher rate of local recurrence was observed in patients whose defects were filled with bone graft. Similar results of previous studies have led to a shift from the bone graft to cement afterward (11, 25). The functional outcome was not associated with the choice of filling agent (cement vs. bone graft) in our study. However, Gao et al. revealed a superior functional outcome when cement was used as the filling agent (25). Similar results were obtained in other studies as well (26, 27). While the oncologic outcome was superior in the wide resection, the functional outcome of the patients was considerably superior in extended curettage than in wide resection. The obtained result is in line with the results of earlier investigations (28, 29).

The main weakness of this study was the small number

of recurrence, which might have affected the power of our statistical analysis. This issue also did not allow the implementation of multivariate statistical analysis. Hence, it is suggested to evaluate a larger series of Iranian GCTB patients in the future.

The epidemiological and clinical characteristics of our series were similar to earlier reported ones. Our study re-confirmed the superior functional and inferior oncologic outcomes of extended curettage in comparison with those of wide resection. Our results also highlighted the application of cement instead of bone graft to fill the cavity, which was used whenever the extended curettage is performed. Moreover, the results obtained provided a better oncologic outcome.

Khodamorad Jamshidi MD

Amin Karimi MD

Alireza Mirzaei PhD

Bone and Joint Reconstruction Research Center, Shafa Ortopaedic Hospital, Iran University of Medical Science, Tehran, Iran

References

- Cooper A, Travers B. Surgical essays. London: Cox & Son and Longman & Co; 1818. P. 195.
- Beebe-Dimmer JL, Cetin K, Fryzek JP, Schuetze SM, Schwartz K. The epidemiology of malignant giant cell tumors of bone: an analysis of data from the surveillance, epidemiology and end results program (1975–2004). *Rare Tumors*. 2009; 1(2):e52.
- Jaffe HL. Giant cell tumor of bone: its pathologic appearance, grading, supposed variants and treatment. *Arch Pathol*. 1940; 30(5):993-1031.
- Klenke FM, Wenger DE, Inwards CY, Rose PS, Sim FH. Giant cell tumor of bone: risk factors for recurrence. *Clin Orthop Relat Res*. 2011; 469(2):591-9.
- Sobti A, Agrawal P, Agarwala S, Agarwal M. Giant cell tumor of bone-an overview. *Arch Bone Jt Surg*. 2016; 4(1):2-9.
- Turcotte RE. Giant cell tumor of bone. *Orthop Clin North Am*. 2006; 37(1):35-51.
- Lopez-Pousa A, Broto JM, Garrido T, Vázquez J. Giant cell tumour of bone: new treatments in development. *Clin Transl Oncol*. 2015; 7(6):419-30.
- Singh AS, Chawla NS, Chawla SP. Giant-cell tumor of bone: treatment options and role of denosumab. *Biologics*. 2015; 9(1):69-74.
- Campanacci M. Bone and soft tissue tumors. New York: Springer; 2013.
- Campanacci M. Giant-cell tumor and chondrosarcomas: grading, treatment and results (studies of 209 and 131 cases). *Recent Results Cancer Res*. 1976; 54(1):257-61.
- Kivioja AH, Blomqvist C, Hietaniemi K, Trovik C, Walloe A, Bauer HC, et al. Cement is recommended in intralesional surgery of giant cell tumors: a Scandinavian Sarcoma Group study of 294 patients followed for a median time of 5 years. *Acta Orthop*. 2008; 79(1):86-93.
- Gupta A, Nath R, Mishra M. Giant cell tumor of bone: multimodal approach. *Indian J Orthop*. 2007; 41(2):115-20.
- Dahlin DC, Cupps RE, Johnson EW Jr. Giant-cell tumor: a study of 195 cases. *Cancer*. 1970; 25(5):1061-70.
- Goldenberg RR, Campbell CJ, Bonfiglio M. Giant-cell tumor of bone: an analysis of two hundred and eighteen cases. *J Bone Joint Surg Am*. 1970; 52(4):619-64.
- Júnior RC, Pereira MG, Garcia PB, Santos PA, Cavalcanti Ados A, Meohas W. Epidemiological study on giant cell tumor recurrence at the Brazilian National Institute of Traumatology and Orthopedics. *Rev Bras Ortop*. 2016; 51(4):459-65.
- Donthineni R, Boriani L, Ofluoglu O, Bandiera S. Metastatic behaviour of giant cell tumour of the spine. *Int Orthop*. 2009; 33(2):497-501.
- Jeys L, Suneja R, Chami G, Grimer R, Carter S, Tillman R. Impending fractures in giant cell tumours of the distal femur: incidence and outcome. *Int Orthop*. 2006; 30(2):135-8.
- Zorlu F, Selek U, Soylemezoglu F, Oge K. Malignant giant cell tumor of the skull base originating from clivus and sphenoid bone. *J Neurooncol*. 2006; 76(2):149-52.

19. Dahlin DC. Caldwell lecture. Giant cell tumor of bone: highlights of 407 cases. *Am J Roentgenol.* 1985; 144(5):955-60.
20. O'Donnell RJ, Springfield DS, Motwani HK, Ready JE, Gebhardt MC, Mankin HJ. Recurrence of giant-cell tumors of the long bones after curettage and packing with cement. *J Bone Joint Surg Am.* 1994; 76(12):1827-33.
21. Teixeira L, Vilela J, Miranda RH, Gomes AH, Costa FA. Giant cell tumors of bone: nonsurgical factors associated with local recurrence. *Acta Orthop Traumatol Turc.* 2014; 48(2):136-40.
22. Miszczyk L, Wydmański J, Spindel J. Efficacy of radiotherapy for giant cell tumor of bone: given either postoperatively or as sole treatment. *Int J Radiat Oncol Biol Phys.* 2001; 49(5):1239-42.
23. Dreinhofer K, Rydholm A, Bauer H, Kreicbergs A. Giant-cell tumours with fracture at diagnosis. Curettage and acrylic cementing in ten cases. *J Bone Joint Surg Br.* 1995; 77(2):189-93.
24. Cheng DD, Hu T, Zhang HZ, Huang J, Yang QC. Factors affecting the recurrence of giant cell tumor of bone after surgery: A clinicopathological study of 80 cases from a single center. *Cell Physiol Biochem.* 2015; 36(5):1961-70.
25. Gao ZH, Yin JQ, Xie XB, Zou CY, Huang G, Wang J, et al. Local control of giant cell tumors of the long bone after aggressive curettage with and without bone cement. *BMC Musculoskelet Disord.* 2014; 15(1):330.
26. Fraquet N, Faizon G, Rosset P, Phillipeau JM, Waast D, Gouin F. Long bones giant cells tumors: treatment by curettage and cavity filling cementation. *Orthop Traumatol Surg Res.* 2009; 95(6):402-6.
27. Kafchitsas K, Habermann B, Proschek D, Kurth A, Eberhardt C. Functional results after giant cell tumor operation near knee joint and the cement radiolucent zone as indicator of recurrence. *Anticancer Res.* 2010; 30(9):3795-9.
28. Liu H, Wang J. Treatment of giant cell tumor of bone: a comparison of local curettage and wide resection. *Changgeng Yi Xue Za Zhi.* 1998; 21(1):37-43.
29. Puri A, Agarwal M. Treatment of giant cell tumor of bone: current concepts. *Indian J Orthop.* 2007; 41(2):101-8.