

LETTER TO THE EDITOR

Challenges of Plate Fixation for Vancouver Type-C fractures after a Well-fixed Hip Arthroplasty Femoral Stem

Reza Ganji, MD

Received: 29 November 2018

Accepted: 29 April 2019

Dear Editor

The fixation of distal femoral fractures (Vancouver type-C fractures; Figure A) following a well-fixed hip arthroplasty femoral stem has become a challenging issue for orthopedic surgeons due to the interprosthetic biomechanical effects (e.g., negative, positive, and torsional strains). Surgeons have adopted a range of constructs, such as distal femoral locking plate, to overcome these difficulties (1, 2).

To minimize the risk of interprosthetic fracture between the femoral stem and femoral plate, many surgeons prefer to overlap the lateral plate with the tip of the well-fixed femoral stem or the proximal femoral component, along with soft tissue sparing techniques using long plates [Figure B]. On the other hand, other surgeons prefer to separate (non-overlap) the plate from the femoral stem. However, the superiority of overlapping the plate over non-overlapping is not well demonstrated in any high-quality studies.

It is probable that the heterogeneity of these fractures, particularly with regard to the length of fracture, has limited research to support the better method. For example, a short fracture is likely to be well-treated by a non-overlapping plate (separate fixation). However, in these cases, the precise distance and position between the end of the lateral femoral plate and the tip of the well-fixed hip arthroplasty femoral stem remained unclear, thereby requiring further research (1, 4-6). In distal femoral fractures, the plate is typically placed as distal as possible to maximize the implant fixation in the distal fragment.

Arthroplasty component design can certainly affect the most distal position available for the plate; however, variable angle plates may allow flexibility for directing screws around a stem or box of the femoral component without compromising distal fixation. In the setting of interprosthetic femoral fractures, the use of a short

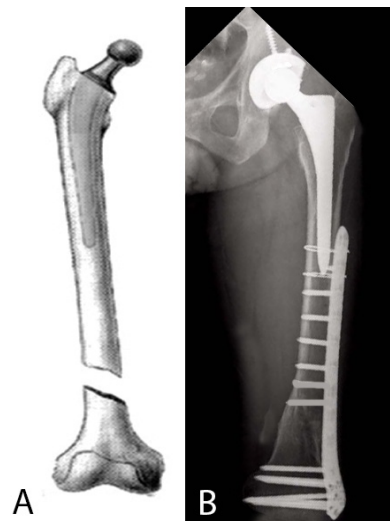


Figure 1. A) Postoperative Vancouver type-C periprosthetic femoral fracture (adapted from an Open Access article by Hwang KT and Kim YH (3), B) anteroposterior radiograph of the left hip of a 67-year-old male with a Vancouver type-C fracture following hip arthroplasty.

plate is accompanied by concerns. In this regard, the space between the plate and femoral component causes excessive stress. Accordingly, there is evidence showing that shorter plates are associated with a higher rate of complication (7).

For the fixation of Vancouver type-C fractures, several attempts have been made to determine an optimal location for a lateral locking plate relative to a well-fixed

Corresponding Author: Reza Ganji, Department of Orthopedic Surgery, School of Medicine, North Khorasan University of Medical Sciences, Bojnurd, Iran
Email: drrezaganji@yahoo.com

THE ONLINE VERSION OF THIS ARTICLE
ABJS.MUMS.AC.IR

femoral stem. For example, Kempthorne et al. found that overlapping the femoral stem by two or more stem diameters with the femoral plate could not only reduce the interprosthetic torsional, compressive, and tensile strains but also provide better protection for secondary intra- and peri-prosthetic fractures (5). In contrast, Kubiak et al., observing no significant difference between the 8-cm gap and the overlapped construct, concluded that it is possible to leave a distance of more than 8 cm between the locking plate and femoral stem in the absence of regional osteopenia. In addition, Kubiak et al. recommended that overlapping the two implants could decrease strain and increase strength in a falling model (8).

In conclusion, the plate fixation of distal femoral fractures (Vancouver type-C fractures) following a well-fixed hip arthroplasty femoral stem is a challenging practice. However, there is a paucity of evidence in this domain to support surgeons. Consequently, several questions remain to be answered by future studies. In this regard, the following questions need to be resolved:

- How much interprosthetic space between implants is safe?
- Is it necessary to overlap the distal tip of the femoral stem with the plate?
- What is the best configuration of plate fixation screws regarding the femoral stem?

- How far should the proximal plate construct extend between the plate and the stem?

It should be also noted that each case must be considered on an individual basis and that no single approach can address all fractures. Surgeons must individualize several issues, including fracture location, surrounding bone structure, stability of the implant, poor bone stock, and patient functionality.

Conflicts of interest: The author declares that there is no conflict of interest.

Funding: This study was conducted under no financial grant.

Acknowledgements

This research letter received no specific grant from any funding agency in the public, commercial, or not-for-profit sectors.

Reza Ganji MD
Department of Orthopedic Surgery, School of Medicine,
North Khorasan University of Medical Sciences, Bojnurd,
Iran

References

1. Smith JR, Halliday R, Aquilina AL, Morrison RJ, Yip GC, McArthur J, et al. Distal femoral fractures: the need to review the standard of care. *Injury*. 2015; 46(6):1084-8.
2. Elmi A, Rohani AR, Tabrizi A, Esmaili SM. Comparison of outcome of femoral shaft fracture fixation with intramedullary nail in elderly patient and patients younger than 60 years old. *Arch Bone Jt Surg*. 2014; 2(2):103-5.
3. Hwang KT, Kim YH. Treatment of periprosthetic femoral fractures after hip arthroplasty. *J Korean Fract Soc*. 2011; 24(1):121-30.
4. Sepehri B, Taheri E, Ganji R. Biomechanical analysis of diversified screw arrangement on 11 holes locking compression plate considering time-varying properties of callus. *Biocybernetics Biomed Eng*. 2014; 34(4):220-9.
5. Kempthorne J, Kieser DC, Walker CG. Optimal plate fixation of distal femoral fractures in the presence of a well fixed cemented hip arthroplasty femoral stem. *HIP Int*. 2018; 28(6):657-62.
6. Shin YS, Han SB. Periprosthetic fracture around a stable femoral stem treated with locking plate osteosynthesis: distal femoral locking plate alone versus with cerclage cable. *Eur J Orthop Surg Traumatol*. 2017; 27(5):623-30.
7. Ricci WM, Streubel PN, Morshed S, Collinge CA, Nork SE, Gardner MJ. Risk factors for failure of locked plate fixation of distal femur fractures: an analysis of 335 cases. *J Orthop Trauma*. 2014; 28(2):83-9.
8. Kubiak EN, Haller JM, Kemper DD, Presson AP, Higgins TF, Horwitz DS. Does the lateral plate need to overlap the stem to mitigate stress concentration when treating vancouver C periprosthetic supracondylar femur fracture? *J Arthroplasty*. 2015; 30(1):104-8.