

RESEARCH ARTICLE

Transverse Anterior Approach to the Elbow for Pediatric Displaced Lateral Humeral Condyle Fractures

Francisco Soldado F. MD, PhD¹; Pedro Domenech-Fernandez, MD, PhD¹; Sergi Barrera-Ochoa, PhD²; Josep M. Bergua-Domingo, MD¹; Paula Diaz-Gallardo, MD¹; Felipe Hodgson, MD³; Jorge Knorr, MD¹

Research performed at UCA Unit, Vithas San Jose, Barcelona, Spain

Received: 15 April 2018

Accepted: 19 January 2019

Abstract

Background: The anterior approach to the elbow for pediatric lateral condyle fractures (LCF) would provide a better visualization of the articular fracture resulting in better functional results, less complications and a more cosmetically-appealing scar than usually seen with the lateral approach.

Methods: Retrospective study of children undergoing an open reduction and internal fixation of a displaced LCF via an anterior approach with a transverse incision. Bilateral elbow range of motion (ROM), upper limb alignment and complications were registered. A 4-point ordinal Likert-type scale was employed for parents to rate their level of satisfaction with the cosmetic appearance of the scar.

Results: Eighteen children of mean age 76 months (range 27 to 101 months) were included. Fractures were classified as Jackob's Type II in 14 cases and Milch's type II in all cases. Mean follow-up was 12 (range 4 to 19) months. Successful condral fracture visualization and reduction was achieved in every case. No intra-operative or post-operative complications occurred. In all cases bone union was obtained 4 to 5 weeks after surgery and at final follow-up, active elbow ROM of at least 90%, was obtained. All parents claimed to be "very satisfied" with their child's scar. A lateral spur was identified in 66.7% of patients.

Conclusion: The anterior approach to the elbow was both a feasible and safe allowing full anatomical cartilage reduction. Complications after this technique might decrease compared to the lateral approach but need future comparative studies. The rate of lateral spur did not decrease. Cosmetic scar results seem to be a clear advantage of this approach compared to the classical lateral approach.

Level of evidence: IV

Keywords: Elbow anterior approach, Lateral humeral condyle fracture, Pediatric elbow

Introduction

Lateral humeral condyle fractures (LCF) are one of the most common elbow fractures in children (1, 2). Since these are articular fractures, full anatomical or near-anatomical reduction has been recommended, with the lateral approach to the elbow considered standard (3, 4).

We used an anterior approach to the elbow for open reduction and internal fixation (ORIF) of displaced LCF

using a transverse incision along the lateral aspect of the antecubital fossa. The purpose of the current study was to test four hypotheses pertaining to this approach. The hypotheses are that the anterior approach will: (1) improve functional outcomes and decrease the rate of malunion, since enhanced chondral exposure and fracture reduction is achieved; (2) decrease the incidence of lateral spurs, since the lateral part of the humerus is

Corresponding Author: Francisco Soldado, Pediatric Hand Surgery and Microsurgery, UCA Unit, Vithas San Jose, Barcelona, Spain

Email: drsoldado@cirugiamanoinfantil.com



THE ONLINE VERSION OF THIS ARTICLE
ABJS.MUMS.AC.IR

not exposed and, thereby, left untouched; (3) decrease the risk of osteonecrosis, since the more vascular posterior aspect of the humerus also remains untouched; and, finally, (4) generate a more cosmetically-appealing scar than usually seen with the lateral approach.

Materials and Methods

This was a retrospective study, for which clinical and radiographic data were obtained on all children in our department who had undergone ORIF of a displaced LCF (>2 mm), via an anterior approach, over the three-year period extending from November 2012 through November 2015. Each fracture was classified in accordance with the classification systems proposed by Jakob (type I, fracture line courses lateral to the trochlea; type II, fracture line that extends into the trochlea) and by Milch (type I, nondisplaced fracture; type II, displaced non-rotated condylar fragment ; type III, displaced and rotated condylar fragment) (5, 6). The clinical assessment included formal measurement bilateral active elbow range of motion (ROM) and upper limb alignment (i.e., carrying angle), and asking parents for their subjective evaluation of the scar’s appearance.

Range of motion was measured with a goniometer using standard techniques. The relative arc of motion of the affected elbow was calculated as a percentage of that in the contra-lateral elbow. Loss of range of motion was compared between the groups of patients with Jakob’s type II and III fractures using the Pearson chi- square test. An 4-point ordinal Likert-type scale was employed for parents to rate their level of satisfaction with the final cosmetic appearance of their child’s scar: not satisfied, 0; satisfied, 1; very satisfied, 2; extremely satisfied; 3.

Surgical technique

All patients underwent surgical treatment under general anesthesia.

Stepwise, the procedure proceeded as follows. First, a transverse incision was created over the lateral half of the elbow flexion crease anteriorly, within the antecubital

fossa. The cephalic vein, lateral antebrachial cutaneous nerve, and biceps tendon were then identified and retracted medially. The radial nerve also was identified deep in the lateral bicapital canal between the brachialis and brachioradialis/extensor carpi radialis longus (ECRL) muscles, and retracted laterally. The brachialis muscle was then detached from the anterior capsule, which was sectioned transversally to augment exposure of the fractured cartilage. The joint then was irrigated to both clean away and aspirate the profuse hematoma. The lateral condyle fragment was decoapted and, using a periosteal elevator, moved in a volar direction to reduce the fracture [Figure 1]. Once the cartilage was anatomically reduced, two 1.5 or 1.8mm K-wires were inserted percutaneously in a divergent fashion. The K-wires then were cut and left exposed. Finally, the subcutaneous tissue and skin were closed with resorbable sutures, after which a long-arm cast splint was applied. This splint and the K-wires were removed 4 to 5 weeks after surgery. No formal postoperative therapy was scheduled.

Results

Epidemiology

Eighteen children of mean age 76 months (6 years, 4 months; range 27 to 101 months) were included in the study. There were 10 males and 8 females. In six patients, the injury was on the patient’s right side; while, in 12, it was on the left side. Fourteen of the fractures were classified as Jakob’s Type II, while four were considered type III 3. All fractures were classified as Milch’s type II. Mean follow-up was 12.6 (range 8 to19) months.

Intraoperative findings

The brachioradialis and ECRL muscles were always found to be infiltrated with blood, while the lateral aspects of the brachialis and anterior capsule were lacerated. Complete visualization of the chondral line of the fracture was always possible. The lateral condyle fragment was always found to be displaced posteriorly, but successful reduction was achieved in every case. No intra-operative

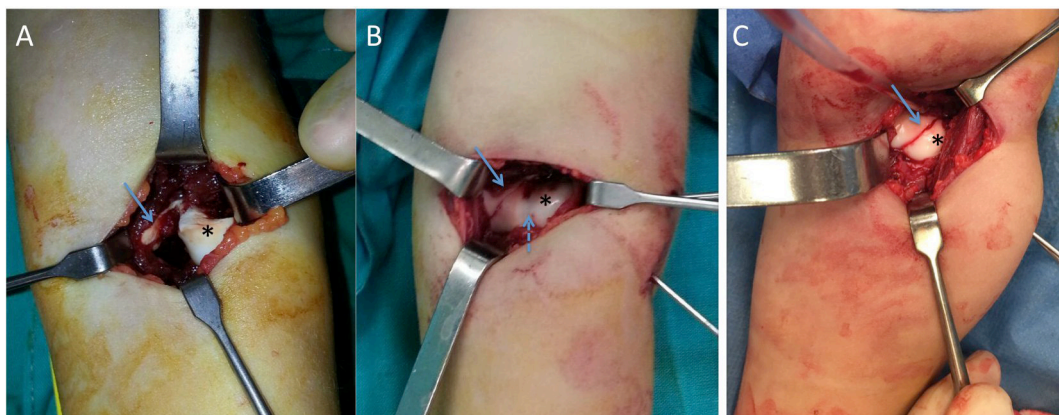


Figure 1. Anterior approach to the elbow . A-B) Type-2 Milch lateral condyle fracture in a 6 y-o child. An anterior window allows for complete visualization of the chondral fracture assuring an anatomical joint reduction. C) Reduced Type-1 Milch lateral condyle fracture. Note: line fracture (arrow); condilothrochlear sulcus (broken arrow); lateral condyle fragment (*).

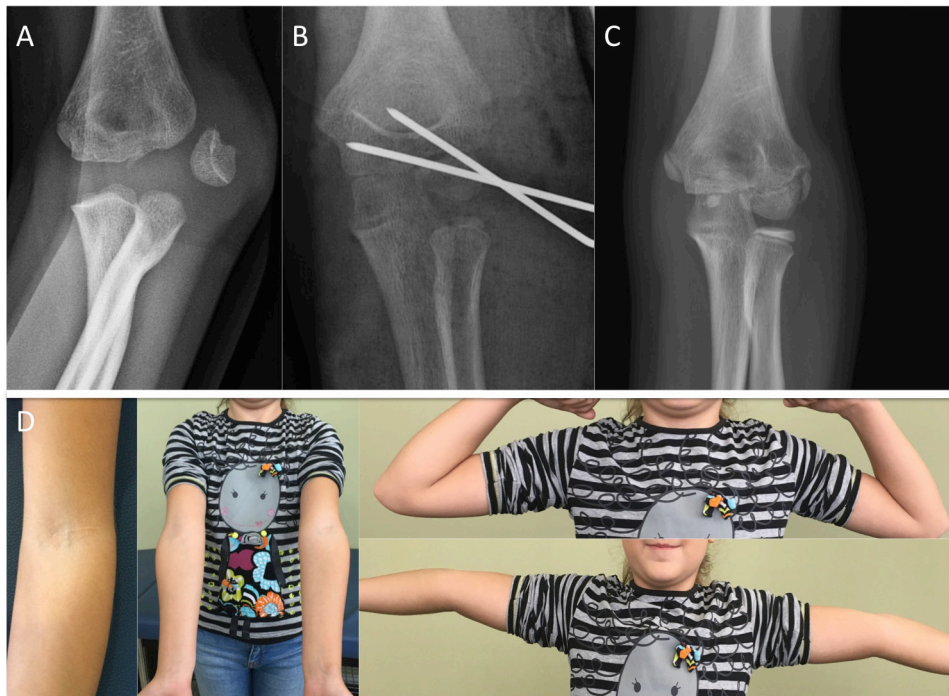


Figure 2. Type-2 Milch lateral condyle fracture in a 9 y-o girl. (A) Radiographs showing (A) a displaced and rotated fragment (Jakob type-3), (B) fracture reduction and fixation with KW, (C) result 12 months after treatment. (D) At final follow-up, symmetrical elbow ROM and alignment was obtained and an almost imperceptible scar.

or post-operative complications were documented.

Clinical assessment

In all cases, at final follow-up, active elbow ROM of at least 90%, relative to the contralateral elbow, was obtained, with a mean ROM of 94.5% (range 90% to 100%). For Jakob's type II fractures, loss of flexion averaged 3.4° (range 0°-15°) and loss of extension averaged 5.2° (range 0°-15°) while for Jakob's type III fractures, loss of flexion averaged 3.8° (range 0°-15°) and loss of extension averaged 5.5° (range 0°-20°). No statistically significant differences were found comparing loss of range of motion between both groups ($P=0.2$). The carrying angle was symmetrical in all patients. All parents claimed to be "very satisfied" with their child's scar. No pin related complication or nerve injury occurred. No forearm rotation restriction was registered.

Radiographic assessment

In all cases, radiographs obtained 4 to 5 weeks after surgery demonstrated callus formation or complete bone union [Figure 2]. A lateral spur ultimately was identified in 12 of the 18 children (66.7%) [Figure 3].

Discussion

Using an anterior approach to the elbow by making a transverse incision was both a feasible and safe technique that allowed for full anatomical reduction of the fractured cartilage in all cases. It also yielded good functional and

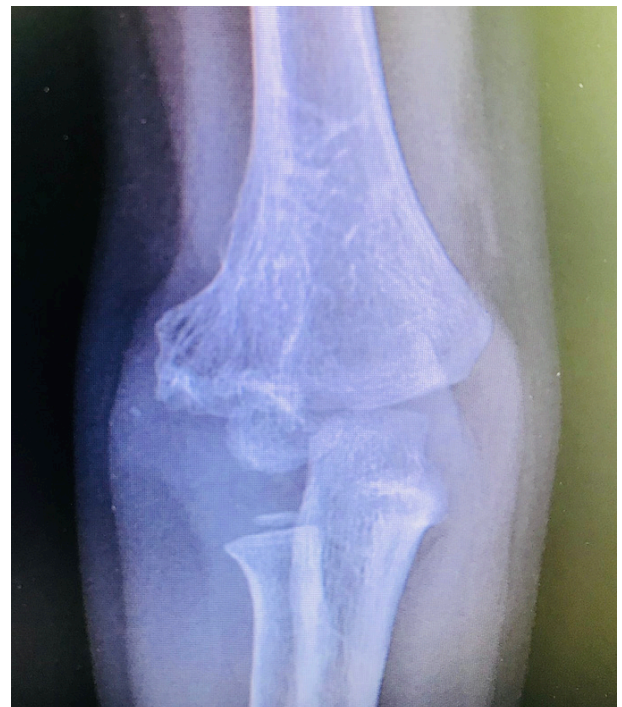

Figure 3. Radiograph showing a lateral spur secondary to a lateral condyle fracture.

excellent cosmetic outcomes in all patients.

Our a priori belief, and the justification for the current study, was that there are four hypothetical advantages of the anterior approach for the surgical management of displaced lateral humeral condyle fractures.

The first of these four conjectured advantages was that an anterior approach to the elbow would provide a more direct window and, thereby, better visualization of the chondral fracture, allowing for better joint reduction and potentially better functional outcomes. Similarly, an anterior elbow approach has been used for distal humeral coronal shearing fractures, an approach that is justified by providing a more direct window and exposure for chondral reduction relative to the standard lateral approach (7). The lateral approach to the elbow, although simple and straightforward, does not permit proper visualization of the most medial aspect of fractures that involve the articular surface. Thus, chondral reduction is indirectly assumed as lateral cortical bone reduction is obtained. Shortcomings of the anterior approach might be the fact of working through a narrow space and the risk of radial nerve injury.

Despite obtaining perfect chondral reduction, the functional outcomes and range of motion in our series were similar to those obtained in previous series using the standard lateral approach (2). Arthroscopy of the elbow has also been used to better visualize cartilage reduction. However, it also has not been shown to yield better functional outcomes than those reported for a series of laterally-approached LCF (8).

The classical principle of anatomical joint reduction of a lateral condylar fracture, an intra-articular fracture, might be questionable, because those who utilize closed methods to reduce and fix these injuries accept up to 2mm of displacement, yet achieve excellent clinical outcomes (1, 3, 9).

No malunion or nonunion occurred in our series, contrary to other series using a lateral approach in which a rate of these complications of from one to three percent has been reported (2, 10, 11). On the other hand, the small number of subjects we studied and the relatively short time patients were followed limits our ability to identify differences between our series and others in either functional outcomes or the incidence of complications.

Our second hypothesis was that the anterior approach would lessen the risk of lateral condyle osteonecrosis, since the posterior portion of the lateral condyle, where the vascular supply is located, is not violated (12). In recent series, the risk of avascular necrosis following ORIF by a lateral approach has been reported to be between 0.6 and 3% (2, 11). Again, the small number of patients in our study, in conjunction with its short follow-up, limits our capacity to render any conclusion regarding the incidence of this complication with the anterior approach.

Third, we theorized that an anterior approach to the elbow would diminish the risk of a lateral spur, since the lateral periosteum is not surgically manipulated. However, in our series, 66% of the patients developed a lateral spur, figures that are similar to those reported elsewhere (2, 11, 13). It is now believed that the likelihood of a lateral spur correlates with the degree of

initial fracture displacement, rather than being impacted significantly by the surgical approach employed (2, 11). Supporting this last conjecture is that the rate of lateral spur formation in patients with an LCF is similar, whether they are treated via closed or open reduction (2).

The last theoretical advantage of using an anterior approach was that a transverse anterior approach should result in a less unsightly scar than the usual prominent scars that result on the lateral elbow (2). The disadvantages of lateral elbow scars have rarely been discussed in the literature. However, in our experience, parents and children usually are dissatisfied with them (2, 14). Thomas reported that 68% of children having a lateral approach for LCF had prominent scars that were >2 mm wide (15). All the parents in our series were very satisfied with the cosmetic appearance of the resulting transverse anterior scar on the elbow. One major drawback of our study is that we did not compare satisfaction between parents whose children have a lateral versus anterior scar. Ersan compared cosmetic results with a lateral versus anterior approach to the elbow in the treatment of supracondylar fractures, and found that the lateral approach sometimes resulted in a hypertrophic scar, while medial transverse anterior scars in the antecubital fossa were barely noticeable (14).

Many of the weaknesses of our present study have already been mentioned. In addition, ours was a retrospective study of a small group with no comparison group. Nonetheless, we note that the cosmetic result with the anterior approach was always excellent, which we know, from our own experience and the experience of others in the literature, is not the case when a lateral approach is used. We also note that we observed no instances of osteonecrosis, nonunion or malunion, which clearly warrants future comparisons between this and the lateral approach to determine if any real advantages exist pertaining to these complications and others.

The anterior approach to the elbow was both a feasible and safe allowing full anatomical cartilage reduction. Complications after this technique might decrease compared to the lateral approach but need future comparative studies. The rate of lateral spur did not decrease. Cosmetic scar results seem to be a clear advantage of this approach compared to the classical lateral approach.

Francisco Soldado F. MD PhD¹

Pedro Domenech-Fernandez MD PhD¹

Sergi Barrera-Ochoa PhD²

Josep M. Bergua-Domingo MD¹

Paula Diaz-Gallardo MD¹

Felipe Hodgson MD³

Jorge Knorr MD¹

1 Pediatric Hand Surgery and Microsurgery, UCA Unit, Vithas San Jose, Barcelona, Spain

2 ICATMA Hand and Microsurgery Unit; ICATME, Hospital Universitari Quiron-Dexeus, Barcelona, Spain

3 Department of Orthopaedic Surgery, School of Medicine, Pontificia Universidad Católica de Chile, Santiago, Chile

References

1. Beaty JH. Fractures of the lateral humeral condyle are the second most frequent elbow fracture in children. *J Orthop Trauma*. 2010; 24(7):438.
2. Silva M, Cooper SD. Closed reduction and percutaneous pinning of displaced pediatric lateral condyle fractures of the humerus: a cohort study. *J Pediatr Orthop*. 2015; 35(7):661-5.
3. Mintzer CM, Waters PM, Brown DJ, Kasser JR. Percutaneous pinning in the treatment of displaced lateral condyle fractures. *J Pediatr Orthop*. 1994; 14(4):462-5.
4. Song KS, Shin YW, Oh CW, Bae KC, Cho CH. Closed reduction and internal fixation of completely displaced and rotated lateral condyle fractures of the humerus in children. *J Orthop Trauma*. 2010; 24(7):434-8.
5. Jakob R, Fowles JV, Rang M, Kassab MT. Observations concerning fractures of the lateral humeral condyle in children. *J Bone Joint Surg Br*. 1975; 57(4):430-6.
6. Milch H. Fractures and fracture dislocations of the humeral condyles. *J Trauma*. 1964; 4(1):592-607.
7. Imatani J, Morito Y, Hashizume H, Inoue H. Internal fixation for coronal shear fracture of the distal end of the humerus by the anterolateral approach. *J Shoulder Elbow Surg*. 2001; 10(6):554-6.
8. Hausman MR, Qureshi S, Goldstein R, Langford J, Klug RA, Radomisli TE, et al. Arthroscopically-assisted treatment of pediatric lateral humeral condyle fractures. *J Pediatr Orthop*. 2007; 27(7):739-42.
9. Song KS, Waters PM. Lateral condylar humerus fractures: which ones should we fix? *J Pediatr Orthop*. 2012; 32(Suppl 1):S5-9.
10. Bauer AS, Bae DS, Brustowicz KA, Waters PM. Intra-articular corrective osteotomy of humeral lateral condyle malunions in children: early clinical and radiographic results. *J Pediatr Orthop*. 2013; 33(1):20-5.
11. Weiss JM, Graves S, Yang S, Mendelsohn E, Kay RM, Skaggs DL. A new classification system predictive of complications in surgically treated pediatric humeral lateral condyle fractures. *J Pediatr Orthop*. 2009; 29(6):602-5.
12. Haraldsson S. On osteochondrosis deformans juvenilis capituli humeri including investigation of intra-osseous vasculature in distal humerus. *Acta Orthop Scand*. 1959; 30(sup38):5-232.
13. Pribaz JR, Bernthal NM, Wong TC, Silva M. Lateral spurring (overgrowth) after pediatric lateral condyle fractures. *J Pediatr Orthop*. 2012; 32(5):456-60.
14. Ersan O, Gonen E, İlhan RD, Boysan E, Ates Y. Comparison of anterior and lateral approaches in the treatment of extension-type supracondylar humerus fractures in children. *J Pediatr Orthop B*. 2012; 21(2):121-6.
15. Thomas DP, Howard AW, Cole WG, Hedden DM. Three weeks of Kirschner wire fixation for displaced lateral condylar fractures of the humerus in children. *J Pediatr Orthop*. 2001; 21(5):565-9.