

RESEARCH ARTICLE

Surgical Excision as the First Therapeutic Choice in Single-muscle Hemangiomas: a Case Series

Khodamorad Jamshidi, MD¹; Milad Haji Agha Bozorgi, MD¹; Hassan Assad Kassir, MD¹; Alireza Mirzaei, PhD¹

Research performed at Bone and Joint Reconstruction Research Center, Shafa Orthopedic Hospital, Iran University of Medical Sciences, Tehran, Iran

Received: 26 May 2019

Accepted: 24 August 2019

Abstract

Background: Conservative management is generally the primary treatment for intramuscular hemangiomas. However, many patients will require surgery later in their life, after suffering a long period of pain. We aimed to evaluate the oncologic and functional outcomes of surgery as the initial treatment of single-muscle hemangiomas.

Methods: Medical profiles of 17 patients with hemangiomas of vastus medialis for whom surgery was selected as the initial treatment were reviewed. The indication for surgery was a bothersome pain. Postoperative muscle strength was assessed with manual muscle testing (range 0-5). The postoperative pain was measured by a visual analog scale (VAS) for pain (range 0-10). Lyshölm-Tegner knee scoring scale was used for the evaluation of knee function.

Results: The mean age of the patients was 25.9±8.6 years. Surgery was performed as wide resection in 13 cases and as marginal resection in 4 cases. At a mean follow-up of 55.76±30 months, two local recurrences (11.8%) were observed. At the last evaluation session, muscle strength grade was 5/5 in 13 patients and 4/5 in four patients. Postoperative pain was noticed in four patients (VAS=1). Knee function was excellent in 13 patients and good in four patients. Both of the local recurrences occurred in marginally resected lesions. Three out of four cases with reduced muscle strength, postoperative pain, and reduced function were also treated with marginal resection.

Conclusion: If a wide surgical margin is achievable without compromising the limb function, surgical resection could be considered as the primary choice of treatment for single-muscle hemangiomas.

Level of evidence: IV

Keywords: Conservative treatment, Intramuscular hemangiomas, Surgery

Introduction

Hemangiomas are abnormal proliferation of vessels, comprising almost 7% of all benign soft-tissue tumors. However, since the majority of lesions are small and asymptomatic, the exact incidence is not known (1-3). Although approximately 20% of hemangiomas can be linked to trauma, their pathogenesis is still not well understood (1, 4). It occurs before the age of 30 years in nearly 90% of cases, and the course of the disease includes the growth, fibroadipose

replacement, intravascular clotting, atrophy, and involution (1). The choice of treatment is based on the characteristic features of the lesion and the patient's degree of functional impairment. Accordingly, a wide range of therapeutic strategies are available that include observation, nonoperative management, and surgical excision (5). Even with the surgical resection, the risk of recurrence remains remarkable (6, 7).

Intramuscular hemangiomas account for almost 0.8% of

Corresponding Author: Alireza Mirzaei, Bone and Joint Reconstruction Research Center, Shafa Orthopedic Hospital, Iran University of Medical Sciences, Tehran, Iran
Email: mirzaei.ar@iums.ac.ir



THE ONLINE VERSION OF THIS ARTICLE
ABJS.MUMS.AC.IR

all hemangiomas (8-11). Chronic pain and palpable mass are the most common symptoms. Pain is present in 60% of cases, most frequently in long and narrow muscles. The pain is usually deteriorated with exercises (12).

Treatment of benign soft-tissue neoplasms could be challenging based on the location and type of the tumor (13-15). Hemangiomas cannot be excluded from this scenario as well. The best treatment option is not clear for intramuscular hemangiomas as the outcome is variable. Recurrence rates ranging from 18% to 61% have been reported for these lesions. (6).

It is acknowledged that highly localized, well-circumscribed single-muscle hemangiomas are better surgical candidates, while multiple-muscle hemangiomas are better managed non-surgically, as surgical resection might impair the function of the involved limb (5). Almost 24% of patients with intramuscular hemangiomas who were initially managed non-operatively needed surgery at two years and 44% at five years (6). Putting the evidence together suggests surgery as the first treatment option in patients with well-circumscribed single-muscle hemangiomas to avoid suffering a long period of pain.

In this study, we aimed to evaluate the oncologic and functional outcomes of surgery as the initial treatment of single-muscle hemangiomas. Since the vastus medialis was the most common single-muscle involvement of hemangioma at our center, we selected this muscle as the representative of the single-muscle hemangiomas. To the best of our knowledge, this is the first study evaluating the treatment outcomes in a series of patients with single-muscle hemangiomas.

Materials and Methods

This retrospective study was approved by the review board of our institute. From January 2007 to June 2016, a total of 107 patients with pathologically confirmed diagnosis of intramuscular hemangiomas were identified in tumor database of our center. Of these, hemangioma of vastus medialis muscle was detected in 21 (19.6%)

cases. Patients with the lesions extended to vastus intermedialis, or rectus femoris (two patients) and follow-up of fewer than two years (two patients) were excluded. The remaining 17 patients who were initially managed with surgery were included in this study. The indication for surgery was a bothersome pain.

Radiologic evaluation of the cases was performed using plain radiographs and magnetic resonance imaging (MRI). Plain radiographs were used for the identification of phlebolith or calcification [Figure 1A]. The initial diagnosis was based on magnetic resonance imaging (MRI). In this respect, a heterogenic intramuscular mass with irregular borders and a high and/or low-intensity signal on T1-weighted MRI and a high-intensity signal on T2-weighted MRI, in addition to a lobulated or serpiginous signal on T2-weighted MRI was suspected as the intramuscular hemangiomas [Figure 1B; C]. Ultrasonography was also performed for all patients to investigate the echo and vascularity pattern [Figure 2]. The diagnosis was confirmed through the histopathological examination of the excised lesion. Clinical and demographic characteristics of the patients were extracted from the patients' medical files and included age at presentation, gender, initial complaint, history of trauma, size, and site of the lesion, duration of symptoms, and follow-up period. The greatest tumor dimension in the pathologic report was considered as the size of the tumor.

Surgical procedure

The surgery included wide excision of the lesion whenever possible and marginal resection of the lesion whenever the anatomical limitations did not allow the wide excision. We excised with 1-cm of the surrounding healthy tissue as the margin in wide excision. At first, the point of maximum tenderness was found and marked with the help of the patients [Figure 3A]. Under general anesthesia and at the supine position, the limb was elevated for two minutes

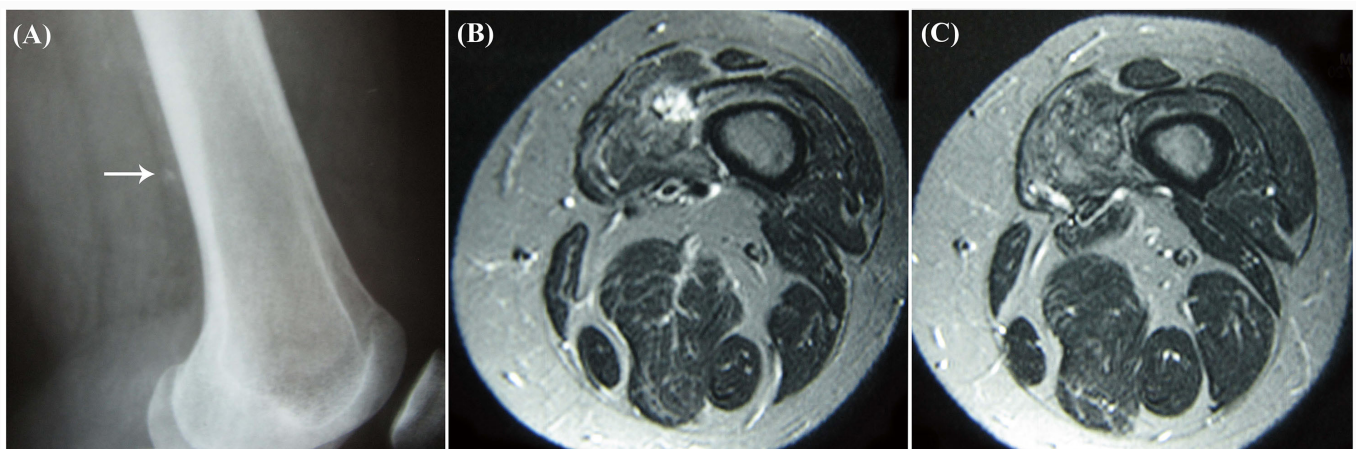


Figure 1. (A) Radiograph of a cavernous hemangioma of vastus medialis showing an ill-defined calcification; (B) T2-weighted MRI showing an infiltrative mass of high-intensity lobulated signal; (C) T1-weighted MRI showing an infiltrative mass of intermediate signal intensity within the muscles.

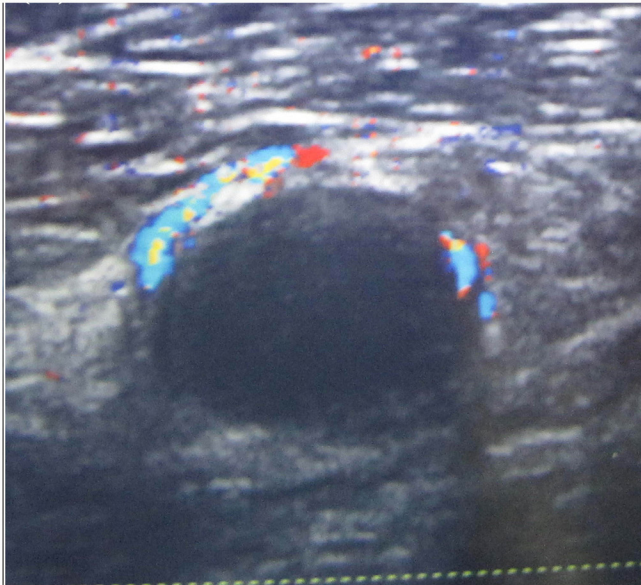


Figure 2. Doppler ultrasound examination showing an avascular hypoechoic mass and vascularity with blood flowing around the mass.

to allow blood discharge from the involved vessels. Then the tourniquet was implicated by the pressure of 350-400 mmHg that made the lump untouchable due to the further discharge of blood flow. Then the patient's leg was located in the figure-of-four position, and a longitudinal incision with the length of 7 to 10 cm was performed on the marked area. Through the fascia

of vastus medialis and some of its muscular fibers, the intramuscular lesion was extracted [Figure 3B]. Then, the tourniquet was turned off, and homeostasis was done. Finally, the fascia, muscles, subcutaneous, and cutaneous tissues were repaired, and a sterile dressing was applied. The patients were discharged the day after the surgery.

Follow-up evaluations

Follow-up of the patients was performed two weeks after the surgery, every three months for the first year, and every six months for the second year. In each follow-up session, pain relief and mass disappearance were investigated. Follow-up MRI was obtained in case a local recurrence was suspected. The patients were invited for a final evaluation session in which the muscle strength, postoperative pain, and knee function were evaluated. Manual muscle testing (MMT) system was used for the grading of muscle strength at a range of 0-5, in which 0/5 grade is attributed to no visible or palpable contraction and 5/5 grade is attributed to a full range of motion against gravity and maximum resistance (16). The postoperative pain level was measured with visual analog scale (VAS) for pain with a range of 0-10, where 0 would mean "no pain" and 10 would mean "worst possible pain" (17). The knee function was assessed using Lyshölm-Tegner knee scoring scale (18) and accordingly classified as excellent (95-100), good (84-94), fair (65-83), and the poor (<64).

Results

Descriptive characteristics

The study population comprised of eight females and nine males with the mean age of 25.9±8.6 years (range

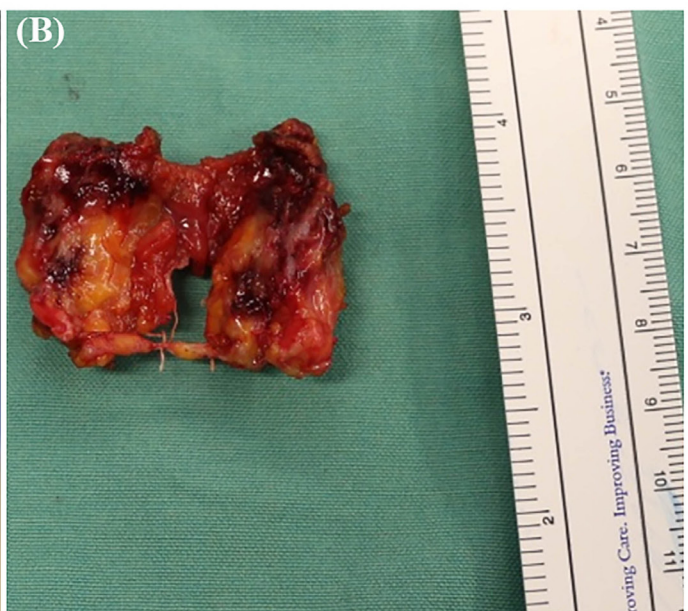
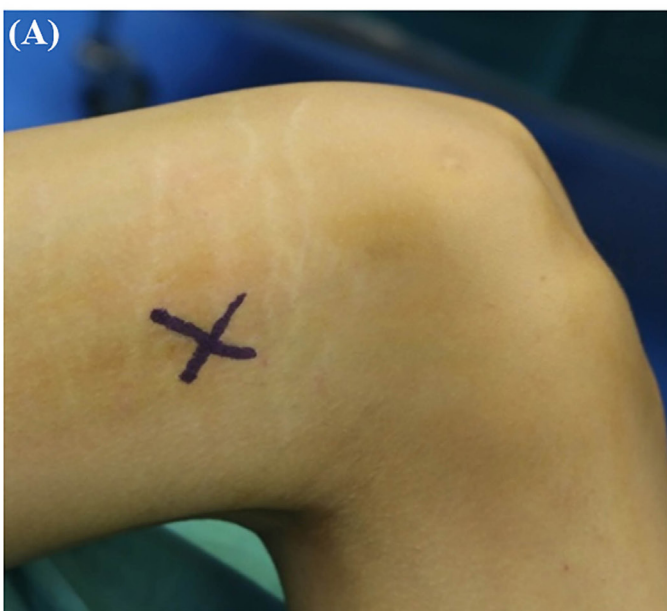


Figure 3. (A) Preoperative highlighting the maximum point of tenderness; (B) an excised cavernous hemangioma of vastus medialis.

8-46 years). The mass was in the left side in 10 cases (58.8%) and right side in the remaining seven cases (41.2%). A history of trauma was present in four cases (23.5%). The pain was the main symptom that was present in all cases. The mass was touchable in five cases (29.4%). The mean size of the tumor was 5.8±3.8 cm (range 1.5-15 cm). The mean duration of symptoms was 27.5±18.4 months (range 2-72 months). The mean follow-up period of the patients was 55.76±30 months (range 24-120 months). According to the pathology report, the tumor type was cavernous in 16 cases (94.1%) and mixed type (capillary + cavernous) in one case (5.9%). The demographic and clinical characteristics of the patients are presented in detail in Table 1.

Oncologic outcomes

The surgery was performed as wide resection in 13 cases (76.5%) and marginal resection in four cases (23.5%). In total, two local recurrences (11.8%) were observed during the follow-up period. The mean time to local recurrence was 6.5±4.9 years (range 3 to 10 years). Based on these results, 100% of the patients were recurrence-free at two years, while 94.1% and 88.2% were recurrence-free at five years and ten years, respectively. All of the recurrences occurred in marginally resected hemangiomas (2 out of 4 cases, 50%). The recurrences were managed with wide resection. The oncologic outcomes of the patients are presented in detail in Table 2.

Functional outcomes

At the last evaluation session, muscle strength was grade 5/5 in 13 (76.5%) patients and grade 4/5 (Full ROM against gravity, moderate resistance) in four (23.5%) patients. The postoperative VAS for pain was 1 in four (23.5%) patients and 0 in the others. The knee function was excellent in 13 (76.5%) patients and good in four (23.5%) patients. Three out of four (75%) patients with reduced muscle strength, postoperative pain, and decreased knee function were treated with marginal resection [Table 2]. All patients had a normal gait and returned to previous sports activities.

Discussion

Although conservative management is generally accepted as the primary treatment of choice for most intramuscular hemangiomas, the best treatment option is still unclear, in part due to the lack of well-evidenced investigations (5, 6, 19). Thus, further studies are needed to remove the uncertainties regarding the optimal management of intramuscular hemangiomas. Evaluating the treatment outcomes in hemangiomas of single muscles such as vastus medialis could be regarded as one of the valuable approaches to resolve these uncertainties.

In this study, we evaluated the outcomes of hemangiomas of vastus medialis in a series of 17 patients who were primarily treated with surgery to reduce the preoperative pain period. Based on our results, surgical excision successfully controlled the

Table 1. The demographic, clinical, surgical and outcome data of the patients with hemangioma of vastus medialis

ID	Age (year)	Gender	Side	Follow-up (months)	Tumor Size (cm)	History of trauma	Symptom	Symptom duration(months)	Surgery
1	26	Female	Left	96	10	No	Pain, mass	24	Marginal resection
2	24	Female	Left	84	2	No	Pain	36	Wide resection
3	30	Male	Right	84	5	No	Pain	15	Wide resection
4	16	Male	Left	60	10	No	Pain, mass	18	Marginal resection
5	27	Female	Right	36	9	Yes	Pain, mass	24	Wide resection
6	30	Male	Left	36	4	No	Pain	48	Wide resection
7	27	Female	Left	24	6	No	Pain	48	Wide resection
8	32	Male	Right	36	4	No	Pain	36	Wide resection
9	26	Female	Right	24	4	No	Pain	24	Wide resection
10	15	Male	Left	24	7	Yes	Pain	22	Wide resection
11	46	Female	Right	48	2.5	No	Pain	72	Wide resection
12	25	Female	Left	60	3	No	Pain	18	Wide resection
13	27	Male	Left	120	2.5	No	Pain	21	Wide resection
14	21	Female	Left	96	10	Yes	Pain, mass	48	Marginal resection
15	23	Male	Right	48	3	No	Pain	2	Wide resection
16	8	Male	Right	48	15	Yes	Pain, mass	6	Marginal resection
17	37	Male	Left	24	1.5	No	Pain	6	Wide resection

Table 2. The outcome measures of the patients with hemangioma of vastus medialis

ID	MMT	VAS	**Knee function	Recurrence
1	5	1	Excellent	No
2	5	0	Excellent	No
3	5	0	Excellent	No
4	4	0	Good	No
5	4	1	Good	No
6	5	0	Excellent	No
7	5	0	Excellent	No
8	5	0	Excellent	No
9	5	0	Excellent	No
10	5	0	Excellent	No
11	5	0	Excellent	No
12	5	0	Excellent	No
13	5	0	Excellent	No
14	4	1	Good	After 10 years
15	5	0	Excellent	No
16	4	1	Good	After 3 years
17	5	0	Excellent	No

*MMT: Manual muscle testing; VAS: visual analog scale for pain.

** Lyshölm-Tegner knee scoring scale

lesion in 15 cases (88.2%). Local recurrence occurred in two cases (11.8%), in both of which the lesion was large and marginal resection was done to avoid damaging the adjacent structures. The postoperative pain, decreased muscle strength, and decreased knee function was noticed in four patients (23.5%). Three out of these four patients were treated with marginal resection due to the large size of the lesion.

According to the literature, hemangiomas of the soft-tissue are benign lesions in which a more aggressive surgery such as a wide excision usually is not warranted. However, surgical removal of symptomatic hemangiomas yields satisfactory results for pain relief, functional recovery, and local control of the lesion (7).

Bella et al. evaluated the outcomes of intramuscular hemangiomas in 110 patients who were initially treated with or without surgery. According to their results, 76% of patients who were initially managed without surgery were surgery-free at two years and 66% at five years. For patients who were primarily treated with surgery, 86% and 73% remained recurrence-free at two and five years, respectively (6). In line with our hypothesis, the study of Bella et al. revealed that a considerable number of the patients would require a surgical resection later in their life if the surgery is not selected as the initial choice of treatment.

Tang et al. reviewed the outcomes of surgical resection

in 89 patients with soft-tissue hemangiomas. All the patients had intralesional or marginal excision as primary treatment. Local recurrence occurred in 10% of the patients of their study. A poor function was reported in 2% of patients. After the operation, 29 patients (37%) still had mild pain (7). Similar to the study of Tang et al., reduced knee function and mild postoperative pain were seen in a subset of patients of this series, mainly following the marginal resection of large lesions. Also, the tumor recurrence was only observed in marginally resected lesions.

Bella et al. considered surgical margins and tumor size as the risk factors for recurrence so that recurrence rate was considerably higher in tumors resected with intralesional excision (6). In accordance with the study of Bella et al., all the recurrences of the present series occurred in lesions with large size that were resected marginally.

Wu et al. reviewed the results of intramuscular hemangiomas in 20 cases who underwent marginal to wide excision. One local recurrence occurred in their series two years after the surgery. The tumor was marginally resected in this case. Accordingly, they concluded that wide excision is necessary to avoid recurrence (20). Similar to the study of Wu et al., no case of recurrence was observed following the wide excision of hemangiomas in our series, whereas the tumor recurred in 50% (two out of four) of cases who were treated with marginal resection. These observations further highlight the role of free margin in the local control of hemangiomas. It can also be concluded that surgical resection might be inadequate in tumors in which a wide surgical margin is not achievable, as the risk of recurrence following the surgery is high in these patients. In addition to the higher risk of recurrence, the present study reveals that the risk of reduced function, reduced muscle strength, and postoperative pain is also higher in large intramuscular hemangiomas in which the lesion resection, even marginally, could impair the adjacent infrastructures.

Our study had some limitations that should be taken into account. The small number of our patients did not allow the statistical analysis of the results that could be regarded as the main limitation of this study. The retrospective nature of the study could be regarded as the other limitation of this study. Thus, further prospective large-scale studies are needed to confirm our findings.

If the intra-muscular hemangioma is confined to a single muscle and wide surgical margin is achievable without compromising the limb function, surgical excision could be selected as the initial strategy of choice for the treatment. This approach prevents a long period of pain experienced by many patients following the nonoperative treatment. However, if the lesion is large with multiple-muscle involvement so that wide resection of the tumor is not possible, both the functional and oncological outcomes of the patient could be impaired following the surgical treatment, and therefore, conservative treatment is a more reasonable

treatment.

Patient consent: Informed consent was obtained from the patients to use their medical data for publication.

Disclosure: The authors report no conflict of interest concerning the materials or methods used in this study or the findings specified in this paper.

Khodamorad Jamshidi MD¹
Milad Haji Agha Bozorgi MD¹
Hassan Assad Kassir MD¹
Alireza Mirzaei PhD¹

¹ Bone and Joint Reconstruction Research Center, Shafa Orthopedic Hospital, Iran University of Medical Sciences, Tehran, Iran

References

- Enzinger F. Benign tumors and tumorlike lesions of blood vessels. Soft tissue tumors. St. Louis: Mosby; 1995.
- Wojcicki P, Wojcicka K. Epidemiology, diagnostics and treatment of vascular tumours and malformations. *Adv Clin Exp Med*. 2014; 23(3):475-84.
- Sami SH, Jamshidi K, Shoushtarizadeh T. Intraarticular synovial cavernous hemangioma: a case report and review of the literature. *Shafa Orthop J*. 2014; 1(2):26-8.
- Marchuk DA. Pathogenesis of hemangioma. *J Clin Invest*. 2001; 107(6):665-6.
- Wierzbicki JM, Henderson JH, Scarborough MT, Bush CH, Reith JD, Clugston JR. Intramuscular hemangiomas. *Sports Health*. 2013; 5(5):448-54.
- Bella GP, Manivel JC, Thompson RC Jr, Clohisy DR, Cheng EY. Intramuscular hemangioma: recurrence risk related to surgical margins. *Clin Orthop Relat Res*. 2007; 459(1):186-91.
- Tang P, Hornicek FJ, Gebhardt MC, Cates J, Mankin HJ. Surgical treatment of hemangiomas of soft tissue. *Clin Orthop Relat Res*. 2002; 399(1):205-10.
- Cohen AJ, Youkey JR, Clagett GP, Huggins M, Nadalo L, d'Avis JC. Intramuscular hemangioma. *JAMA*. 1983; 249(19):2680-2.
- Allen P, Enzinger F. Hemangioma of skeletal muscle. An analysis of 89 cases. *Cancer*. 1972; 29(1):8-22.
- Beham A, Fletcher C. Intramuscular angioma: a clinicopathological analysis of 74 cases. *Histopathology*. 1991; 18(1):53-9.
- Jamshidi K, Jafari D, Shirazi MR, Pahlevansabagh A, Shoushtaryzadeh T. An unusual presentation of ossified intramuscular hemangioma: a case report. *Acta Med Iran*. 2014; 52(4):319-22.
- Fergusson I. Haemangiomas of skeletal muscle. *Br J Surg*. 1972; 59(8):634-7.
- Jamshidi K, Karimi A, Bagherifard A, Mirzaei A. Aneurysmal bone cysts of the clavicle: a comparison of extended curettage and segmental resection with bone reconstruction. *J Shoulder Elbow Surg*. 2019; 28(9):1654-7.
- Jamshidi K, Mirkazemi M, Izanloo A, Mirzaei A. Locking plate and fibular strut-graft augmentation in the reconstruction of unicameral bone cyst of proximal femur in the paediatric population. *Int Orthopaedics*. 2018; 42(1):169-74.
- Jamshidi K, Bagherifard A, Mirzaei A, Bahrabadi M. Giant cell tumor of the sacrum: series of 19 patients and review of the literature. *Arch Bone Jt Surg*. 2017; 5(6):443-50.
- Mendell JR, Florence J. Manual muscle testing. *Muscle Nerve*. 1990; 13(S1):S16-20.
- Hawker GA, Mian S, Kendzerska T, French M. Measures of adult pain: visual analog scale for pain (Vas Pain), numeric rating scale for pain (NRS Pain), mcgill pain questionnaire (MPQ), short-form mcgill pain questionnaire (SF-MPQ), chronic pain grade scale (CPGS), short form-36 bodily pain scale (SF-36 BPS), and measure of intermittent and constant osteoarthritis pain (ICOAP). *Arthritis Care Res*. 2011; 63(Suppl 11):S240-52.
- Negahban H, Mostafae N, Sohani SM, Mazaheri M, Goharpey S, Salavati M, et al. Reliability and validity of the Tegner and Marx activity rating scales in Iranian patients with anterior cruciate ligament injury. *Disabil Rehabil*. 2011; 33(22-23):2305-10.
- Brozzetti S, Polistena A, De Angelis M, Bononi M, Miccini M, Mazzoni G, et al. Treatment of giant intramuscular hemangioma: a multistep approach in three patients. *Anticancer Res*. 2005; 25(3C):2417-21.
- Wu JL, Wu CC, Wang SJ, Chen YJ, Huang GS, Wu SS. Imaging strategies in intramuscular haemangiomas: an analysis of 20 cases. *Int Orthop*. 2007; 31(4):569-75.