

## RESEARCH ARTICLE

# Two-stage Total Knee Arthroplasty for Treatment of Surgical Failure of Septic Arthritis in Degenerative Knee Joints

Mohammad Naghi Tahmasebi, MD<sup>1</sup>; Arash Sharafat Vaziri, MD<sup>1</sup>; Seyed Hossein Miresmaeili, MD<sup>1</sup>; Mohammad Reza Bozorgmanesh MD<sup>1</sup>; Shahin Mirkarimi, MD<sup>1</sup>; Mohammad Javad Zehtab, MD<sup>1</sup>; Mohammad Tahami, MD<sup>1,2,3</sup>

Research performed at Orthopedic Department, Shariati Hospital, Tehran University of Medical Sciences, Tehran, Iran

Received: 19 September 2019

Accepted: 17 March 2020

## Abstract

**Background:** The ultimate goal of the treatment of infectious knee arthritis is to protect the articular cartilage from adverse effects of infection. Treatment, however, is not always hundred percent successful and has a 12% failure rate. Persistent infection is more likely to happen in elderly patients and those with underlying joint diseases, particularly osteoarthritis. Eradication of infection and restoration of function in the involved joint usually are not possible by conventional treatment strategies. There are few case series reporting two-stage primary knee arthroplasty as the salvage treatment of the septic degenerative knee joint; however, the treatment protocol remains to be elucidated.

**Methods:** Based on a proposed approach, patients with failure of common interventions for treatment of septic knee arthritis and underlying joint degeneration were treated by two-stage TKA and intervening antibiotic loaded static cement spacer. Suppressing antibiotic therapy was not prescribed after the second stage.

**Results:** Complete infection eradication was achieved with mean follow up of 26 months. All cases were balanced with primary total knee prosthesis. The knee scores and final range of motions were comparable to other studies.

**Conclusion:** The two-stage total knee replacement technique is a good option for management of failure of previous surgical treatment in patients with septic arthritis and concomitant joint degeneration. Our proposed approach enabled us to use primary prosthesis in all of our patients with no need for suppressive antibiotic therapy.

**Level of evidence:** IV

**Keywords:** Degenerative joint, Septic knee arthritis, Total knee replacement, Two stage arthroplasty

## Introduction

Management of acutely infected knee generally focuses on joint decompression via adequate and prompt drainage of the infected synovial fluid, debridement of the loculations and infected synovial tissue, and administration of appropriate antimicrobial therapy. The ultimate goal of the treatment is to protect

the articular cartilage from adverse effects of infection that may otherwise lead to a degenerative destruction of cartilage (1). Treatment, however, is not always a hundred percent successful and permanent chronic infection endures the standard therapies in 12% of the cases (2). Permanent infection causes irreversible

**Corresponding Author:** Mohammad Tahami, Department of orthopedics, Shariati Hospital, Tehran University of Medical Sciences, Tehran, Iran; Bone and Joint Research Center, Shiraz University of Medical Sciences, Shiraz, Iran  
Email: tahami@sums.ac.ir; mohammad.tahami@yahoo.com



THE ONLINE VERSION OF THIS ARTICLE  
ABJS.MUMS.AC.IR

damage to the joint. Persistent infection is more likely to happen in elderly patients and those with underlying joint diseases, particularly osteoarthritis (1, 3). Destruction of the articular cartilage in degenerated knee joint will expose the underlying subchondral bone to the synovial fluid. When the septic arthritis occurs in these situations the chance of persistent infection will increase subsequently.

Comorbidities, namely diabetes, rheumatoid arthritis, and obesity may impose more problems on the treatment of septic joints (4). Inability to control the infection will increase the risk of peri-articular bone involvement, which will also complicate the treatment process by converting the septic arthritis to osteomyelitis (5). Bony involvement needs more extensive interventions for infection to be controlled and when this occurs in prearticular areas of knee joint there are limited treatment options available. Arthrodesis is a good option in failed cases, but, has some complications and permanent morbidities. There is still a chance of nonunion, malunion, and recurrence of infection. The functional limitation is prominent, especially in elderly patients with concomitant other comorbidities and underlying diseases. Conversion of knee arthrodesis to total knee arthroplasty is also challenging and less successful (6).

Above-knee amputation is another solution, but, only 50 percent of patients are able to walk after this kind of treatment (7). Considering the functional results joint replacement provides much better outcomes than arthrodesis or amputation (8).

Two-stage total knee arthroplasty (TKA) has long been practiced as the best choice for the treatment of prosthetic joint infection (PJI). However, despite the favorable results, reports of case series on two-stage primary arthroplasty as a standard treatment of septic degenerative knee joint remain to be elucidated.

To the best of our knowledge, there is no consensus or any widely accepted guideline for the treatment of septic arthritis in the presence of a degenerative joint

Conclusive recommendations are hard to reach upon by tapping into the currently available data, mainly because of the heterogeneity in the population under the study, the intervals between the stages, the devices used, and the diversity in the post-operative care. As such, we are reporting our four-year experience with two-stage TKA for treatment of failure of degenerative infectious knee arthritis.

### Materials and Methods

Between January 2014 and June 2018, all patients with underlying joint degeneration and failure of surgical treatment of acute knee joint septic arthritis were included in our study. The diagnosis of septic arthritis was made by combination of joint tap cell counts, acute inability of patient for weightbearing on involved extremity, recent joint swelling, and hotness. Our hospital protocol for the treatment of septic arthritis is arthroscopic debridement and synovectomy. Three patients with treatment failures were referred from other centers; two of whom had arthroscopic

debridement and one patient had two sessions of open arthrotomy. Open debridement and synovectomy was performed in these cases. Other patients were treated as primary cases in our hospital. The amount of cartilage destruction was evaluated during arthroscopic or open debridement. If they had end-stage osteoarthritic knees during the first operation that was performed in our center, without considering the present infection, it was recorded in patient's file.

Failure of surgical intervention was suspected by persistent joint swelling, warmth, and erythema, progressive radiological pre-articular osteopenia, and persistent elevation of inflammatory markers of infection.

All patients with above mentioned criteria and end-stage osteoarthritis were included in our study. No other surgical debridement and irrigation were performed.

### Surgical technique

#### First stage

The knee joint was exposed using longitudinal midline or modified incision in case of previous arthrotomy; joint tap was done and the articular fluid was sent for culture; and subsequently medial parapatellar arthrotomy was performed. Extensive synovectomy was done and some tissues were sent for culture.

The center of ipsilateral femoral head was defined under C-arm control and marked by a chest lead to be palpated over surgical draping. Extramedullary jig with predetermined valgus correction angle according to pre-operative three joint alignment view was double checked with the center of the femoral head marker and the distal femoral cut was conducted four mm less than that of the standard according to the preoperative plan. Proximal tibial cut was also performed by extramedullary jig in order to remove two mm of the cartilage from the most intact side. Medial and lateral meniscectomy were performed. Cultures were also sent from distal femoral and proximal tibial bone cuts.

Femoral sizing was performed and recorded for the second stage. A four-in-one femoral cutting block was placed parallel to trans-epicondylar axis and the anterior cortical cut was done in order to decrease the pressure over the patellofemoral joint after the insertion of the static cement spacer and also to have anterior cortical cut as a reference for the placement of four-in-one femoral cutting block in the second stage. The posterior condyles were not cut and only the cartilage was removed by curette, so that the tension over the posterior capsule could be maintained. The articular surface of patella was also refreshed and reshaped by a surgical saw and rongeur. No resurfacing was performed.

The joint space was kept open by two laminae spreaders, and after adding four grams of vancomycin to each 40-gram cement pack, the cement was placed into the joint and over the cut surfaces. The articular surface of patella was also embedded in cement and then protected during cement hardening. After the hardening of the cement, the joint was irrigated and closed in layers over a drain. Afterwards, a cylindrical cast was applied [Figure 1].

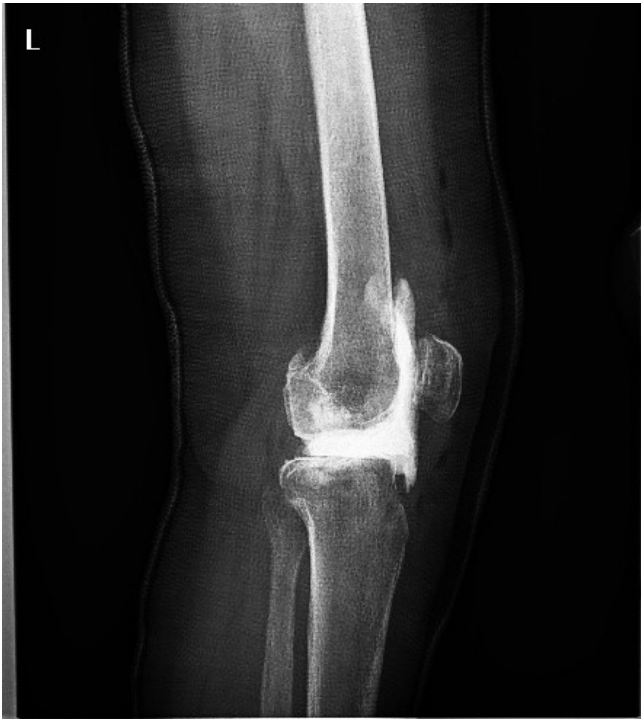

Figure 1. Static cement spacer after performing of anterior and distal femoral cut and proximal tibial cut.

The patient was ambulated with the aid of a walker to bear weight as tolerated.

For the first two weeks, the patients received intravenous antibiotics based on the culture results of the first stage samples, which were continued orally for another four weeks. Patients were followed up during this period by serial quantitative CRP check. Increase or failure of decrease of CRP values necessitated another session of debridement and spacer exchange.

### Second stage

After six weeks of antibiotic therapy, the patients were followed by CRP level during the next two weeks without antibiotics, and implantation of prosthesis was scheduled when the CRP level was below 10 mg/L. No joint tap was performed prior to this stage of treatment.

All the operations were done by the support of more constrained prosthesis as backup.

The knee joint was exposed using medial parapatellar approach. After the removal of cement spacer, three samples from the tibial and femoral surfaces as well as the posterior capsule were sent for culture. Extensive synovectomy and distal femoral re-cut were performed using intramedullary guide according to predetermined femoral size in the first stage and anterior cut. The proximal tibial re-cut was done by an extramedullary jig. Component implantation and ligament balancing were done as usual. Finally, full range of motion was achieved by adequate release [Figure 2].

Antibiotic treatment was continued according to the

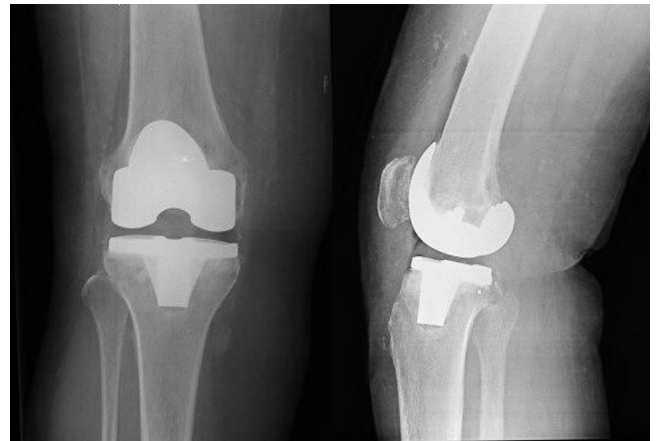


Figure 2. Primary prosthesis implementation during the second stage.

previous cultures until the results of the newly sent cultures were available. If the results were negative no antibiotic regimen was prescribed. In case of positive cultures, the patient will receive antibiotics for at least six weeks according to antibiogram. All patients were followed in outpatient clinic with serial check of CRP and ESR for the first three months after discharge and the clinical and radiological signs of infection afterwards. All patients were treated by the same physical therapy protocol after primary assessments.

### Results

Four women and two men were enrolled in our study with a mean age of 50.5 years (25 to 64). Five patients had comorbidities [Table 1].

Ten surgeries were performed on six knees. The first debridement was performed within three days of the onset of signs of septic arthritis in all of the cases. The average time from the last debridement till the first stage of treatment was two months (one to four months).

Joint aspiration culture prior to the first stage was positive in only two patients. In contrast, the bone cultures that were sent during the first stage were all positive [Table 2].

All patients received antibiotics between the two stages for six weeks. The removal of the cement spacer and prosthesis implantation was carried out at eight weeks. All the cultures that were sent during the second stage were negative and the patients were discharged without any suppressive antibiotics after the results were available. In all cases, knee joints were stable and balanced with primary prosthesis with the thickest polyethylene (14 mm) without the use of any augments or stems. The mean follow-up period was 26 months (12 to 40 months).

There were no signs of recurrence of infection in our cases. The mean knee joint range of motion was (0-14-104) which was improved to (0-123) at the final follow-up. The average KOOS score was 84.8 (75 to 95) at the last follow-up [Table 3].

**Table 1. Epidemiological Data and comorbidities distribution of patients**

| Comorbidities<br>Age-Sex | Steroid injection | RA   | DM   | Lupus | Other                    |
|--------------------------|-------------------|------|------|-------|--------------------------|
| 58 -F                    | ****              | +    | ---- | ----- | Asthma<br>Hypothyroidism |
| 25-F                     | -----             | ---- | ---- | +     | -----                    |
| 64-F                     | *****             | +    | +    | ----- | HTN<br>CAD               |
| 52-M                     | **                | ---- | +    |       |                          |
| 60-M                     |                   |      | +    |       |                          |
| 44-F                     | ***               | +    |      |       |                          |

\*: Number of intra-articular injection

F: Female M: Male

HTN: Hypertension CAD: Coronary artery disease

**Table 2. Procedures, cultures and interval time for first stage**

|   | Previous surgery          | *Culture prior to FS | Culture from FS                             | Interval between debridement and FS |
|---|---------------------------|----------------------|---|-------------------------------------|
| 1 | arthroscopy               | -----                | Enterococci                                 | months 4                            |
| 2 | Arthroscopy<br>Arthrotomy | Staph. Aureus        | Staph. Aureus                               | month 1                             |
| 3 | Three arthrotomies        | —                    | **Staph. Coagulase -ve<br>Gram -ve bacillus | months 2                            |
| 4 | Arthroscopy               | Staph. Aureus        | Staph. Aureus                               | month 1                             |
| 5 | Arthroscopy               | -----                | Staph. Aureus                               | month 1                             |
| 6 | Arthroscopy<br>Arthrotomy | -----                | Staph. Coagulase -ve                        | months 3                            |

\*: First Stage

\*\* :Negative

**Table 3. ROM and KOOS Score at final follow up**

|   | ROM before FS | Final ROM | Duration of F//U-Months | KOOS Score |
|---|---------------|-----------|-------------------------|------------|
| 1 | 10-110        | 0-110     | 12                      | 90         |
| 2 | 30-80         | 0-110     | 18                      | 95         |
| 3 | 15-130        | 0-140     | 30                      | 75         |
| 4 | 25-75         | 5-135     | 32                      | 83         |
| 5 | 5-120         | 5-125     | 40                      | 78         |
| 6 | 0-120         | 0-120     | 28                      | 88         |

### Discussion

Our results show that using our approach for performing two-stage total knee arthroplasty can yield promising

short-term outcomes in patients with prior surgical treatment failure of septic knee arthritis and preexisting

joint degeneration.

Current approaches to the treatment of knee joint septic arthritis in patients with underlying joint degeneration is not always successful (1). To the best of our knowledge, few studies have described two-stage total knee arthroplasty as the treatment of choice in patients with failure of surgical debridement of infected arthritis of knee joint with preexisting joint degeneration, none of which were prospective nor capable of proposing a protocol (6, 8, 9). Eighty three percent of our patients had comorbidities, which is similar to 78-100 percent prevalence in reports suggested by other studies (6, 8, 10). Although these comorbidities predispose the joint to be susceptible to infection they are not considered risk factors for poor response to treatment. Pre-existing joint degeneration is considered to be among the factors that weaken the prognosis of infectious arthritis, which was present in all of our patients (1, 4).

Joint fluid aspiration has proved to be useful for the detection of acute knee joint septic arthritis; nevertheless, the accuracy decreases in chronic situations (3). Nazarian et al. and Yi et al. reported positive joint tap cultures in 60 percent of their patients prior to the first stage (6, 11). In our study, there were only two positive cultures (33 %). This difference may be due to the different culture techniques (12). It should also be noted that the interval between the last surgical intervention and the first stage in our study was two months, during which five of our patients received antibiotics, which is shorter compared to other studies.

As suggested in the literature, the primary failure in current study was suspected and sought based on the persistence of the clinical symptoms of pain, swelling, and hotness ; raised inflammatory markers, and progressive narrowing of joint spaces in X-rays (6, 8-10).

Although constrained prosthesis has been suggested in the same setting implementing strategies such as cutting four mm less than usual for distal femoral and proximal tibial resections and also use of four-in-one cutting jig in order to determine the final femoral size and anterior chamfer cuts makes it possible to preform primary total knee arthroplasty with the maximum polyethylene thickness of 14 mm in all of our patients (6, 10). It seems that this approach can decrease the economic burden of more constrained prostheses for the treatment of these patients.

Use of antibiotic cement spacer as static or dynamic is a matter of debate in literature with no significant difference have been observed except for a better amount of range of motion for dynamic ones (13-15). In the current study, static spacers were used with immobilization in plaster. The mean final range of motion obtained in the current study was 123 degrees which is higher than those observed in previous studies regardless of the spacer type (dynamic vs. static) (6, 9-11). This finding might be rooted in the shorter period of time between the two stages of treatment. The mean time interval was similar to that reported in Hochreiter, Bauer, and Kirpalani studies, but, it was shorter compared to that by Nazarian and Shaikh, which may be due to the fact that in both

of these studies patients with chronic long-lasting knee joint infection were also included and this may be due to bone involvement, which will prolong the treatment process (5, 6, 8-10, 16).

. Yi et al. included patients with acute presence of septic arthritis in their study and reported a mean time interval of 16.8 weeks between the two stages of treatment, which is far from our time interval (11). This long interval time may be due to the huge amount of bacterial load in the presence of acute phase or use of cement beads instead of spacers.

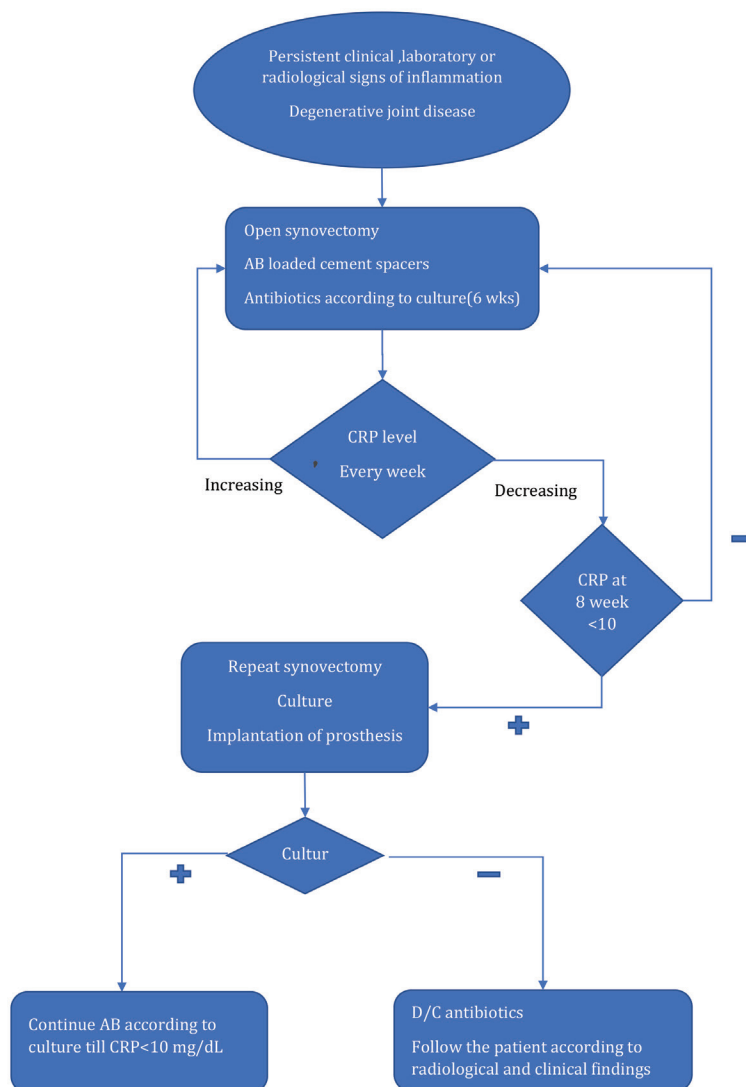
All patients were given broad spectrum antibiotics, pending the result of culture obtained during the second stage of procedure. All specimens were found to be culture-negative and all patients were discharged from the hospital with no extended antibiotics. Although it has been a common practice to have patients with two-stage TKA on an extended course of antibiotics of varying duration, recently, Hoad-Reddick et al., who treated infected total knee arthroplasty with no extended period of antibiotic administration after two-stage total knee arthroplasty, concluded that there is no need for prolonged course of antibiotic treatment (6, 9-11, 17, 18).

No complication emerged in the present study. However, it has been reported that comorbidity in the broad sense (associated defects, immunosuppression) is a factor of increased risk of recurrence of infection following arthroplasty (8, 19).

Using two-stage total knee replacement is a good option for the management of previous surgical treatment failure of patients with septic arthritis and concomitant joint degeneration (8, 19). The stage of joint infection evolution and the degree of bone involvement are certainly also to be taken into account in assessing the risk of failure. Jerry et al. reported a 4% recurrence rate of infection after arthroplasty for simple septic arthritis and 15% for osteomyelitis (20). According to Kim et al, the longer the symptom-free interval between initial joint infection and implantation, the higher the success rate will be (21).

According to all discussions, we propose that selecting cases of failure of septic knee joint arthritis by clinical and paraclinical judgment can be treated safely following a protocol.

Our findings need to be interpreted in the light of their limitations and strengths. Firstly, our sample size was small and it is to be considered in the short term, which is a common shortcoming to all experimental studies in this field. This calls for future long-term studies to determine the long-term outcomes of such strategies. Secondly, all of the patients were examined and followed by the surgeons that were involved in the research and there was no blinded examiner in the study. Facing these issues, we had designed an algorithm and protocol for the treatment of failure of septic arthritis cases in presence of degenerative arthritis in our hospital and all of these patients were treated by the same strategy. However, pending larger future studies with longer follow-ups, and perhaps meta-analyses, we cannot, currently, manage to find any evidence that could ascribe inferior long-term



Algorithm 1.

outcomes to our protocol as compared to the currently practiced counterparts. One of the strengths of our study is using custom-made cement spacers, which reduces the costs of articulating industrial samples. Using less tibial and femoral cuts enables us to perform primary total knee arthroplasty in all of our cases and the last but the most important is that we do not prescribe suppressive antibiotic therapy after the second stage. We hope that as the protocol presented herein draws attention of orthopedic surgeons, more data will be available in the future and more definitive evaluation will be possible.

In conclusion, using two-stage total knee replacement is a good option for management of failure of previous surgical treatment in patients with septic arthritis and concomitant joint degeneration. We have introduced our preferred algorithm to treat these patients

[Algorithm 1].

Mohammad Naghi Tahmasebi MD<sup>1</sup>  
Arash Sharafat Vaziri MD<sup>1</sup>  
Seyed Hossein Miresmaeili MD<sup>1</sup>  
Mohammad Reza Bozorgmanesh MD<sup>1</sup>  
Shahin Mirkarimi MD<sup>1</sup>  
Mohammad Javad Zehtab MD<sup>1</sup>  
Mohammad Tahami MD<sup>1,2,3</sup>

1 Department of Orthopedics, Tehran University of Medical Sciences, Tehran, Iran

2 Bone and Joint Research Center, Shiraz University of Medical Sciences, Shiraz, Iran

3 Department of Orthopedics, Shariati Hospital, Tehran University of Medical sciences, Tehran, Iran

## References

1. Kaandorp CJ, Krijnen P, Moens HJ, Habbema JD, van Schaardenburg D. The outcome of bacterial arthritis. A prospective community-based study. *Arthritis & Rheumatism: Official Journal of the American College of Rheumatology*. 1997; 40(5):884-92.
2. Wirtz D, Marth M, Miltner O, Schneider U, Zilkens K. Septic arthritis of the knee in adults: treatment by arthroscopy or arthrotomy. *International orthopaedics*. 2001; 25(4):239-41.
3. Ferrand J, El Samad Y, Brunschweiler B, Grados F, Dehamchia-Rehailia N, Séjourne A, et al. Morbimortality in adult patients with septic arthritis: a three-year hospital-based study. *BMC infectious diseases*. 2016; 16(1):239.
4. Mathews CJ, Kingsley G, Field M, Jones A, Weston VC, Phillips M, et al. Management of septic arthritis: a systematic review. *Annals of the rheumatic diseases*. 2007; 66(4):440-5.
5. Farrell JM, Bryan RS. Total knee arthroplasty after septic arthritis. *The Orthopedic clinics of North America*. 1975; 6(4):1057-62.
6. Nazarian DG, de Jesus D, McGuigan F, Booth Jr RE. A two-stage approach to primary knee arthroplasty in the infected arthritic knee. *The Journal of arthroplasty*. 2003; 18:16-21.
7. Rodriguez-Merchan EC. Knee fusion or above-the-knee amputation after failed two-stage reimplantation total knee arthroplasty. *Archives of Bone and Joint Surgery*. 2015; 3(4):241.
8. Bauer T, Lacoste S, Lhotellier L, Mamoudy P, Lortat-Jacob A, Hardy P. Arthroplasty following a septic arthritis history: a 53 cases series. *Orthopaedics & Traumatology: Surgery & Research*. 2010; 96(8):840-3.
9. Hochreiter B, Strahm C, Behrend H. Short-interval two-stage approach to primary total knee arthroplasty for acutely septic osteoarthritic knees. *Knee Surgery, Sports Traumatology, Arthroscopy*. 2016; 24(10):3115-21.
10. Shaikh AA, Ha CW, Park YG, Park YB. Two-stage approach to primary TKA in infected arthritic knees using intraoperatively molded articulating cement spacers. *Clinical Orthopaedics and Related Research*. 2014; 472(7):2201-7.
11. Yi C, Yiqin Z, Qi Z, Hui Z, Zheru D, Peiling F, et al. Two-stage primary total knee arthroplasty with well-designed antibiotic-laden cement spacer block for infected osteoarthritic knees: the first case series from China. *Surgical infections*. 2015; 16(6):755-61.
12. von Essen RO, Hölttä A. Improved method of isolating bacteria from joint fluids by the use of blood culture bottles. *Annals of the Rheumatic Diseases*. 1986; 45(6):454-7.
13. Durbhakula SM, Czajka J, Fuchs MD, Uhl RL. Antibiotic-loaded articulating cement spacer in the 2-stage exchange of infected total knee arthroplasty. *The Journal of arthroplasty*. 2004; 19(6):768-74.
14. Emerson Jr RH, Muncie M, Tarbox TR, Higgins LL. Comparison of a static with a mobile spacer in total knee infection. *Clinical Orthopaedics and Related Research*. 2002; 404:132-8.
15. Pivec R, Naziri Q, Issa K, Banerjee S, Mont MA. Systematic review comparing static and articulating spacers used for revision of infected total knee arthroplasty. *The Journal of arthroplasty*. 2014; 29(3):553-7.
16. Kirpalani PA, In Y, Choi NY, Koh HS, Kim JM, Han CW. Two-stage total knee arthroplasty for non-salvageable septic arthritis in diabetes mellitus patients. *Acta Orthop Belg*. 2005; 71(3):315-20.
17. Mirza AH, Noble J, Teanby D. Infected knee treated by total knee arthroplasty. *The Knee*. 2000; 7(3):171-4.
18. Hoad-Reddick DA, Evans CR, Norman P, Stockley I. Is there a role for extended antibiotic therapy in a two-stage revision of the infected knee arthroplasty? *The Journal of bone and joint surgery. British volume*. 2005; 87(2):171-4.
19. Lee GC, Pagnano MW, Hanssen AD. Total knee arthroplasty after prior bone or joint sepsis about the knee. *Clinical Orthopaedics and Related Research*. 2002; 404:226-31.
20. Jerry JG, Rand JA, Ilstrup D. Old sepsis prior to total knee arthroplasty. *Clinical orthopaedics and related research*. 1988 (236):135-40.
21. Kim YH, Oh SH, Kim JS. Total hip arthroplasty in adult patients who had childhood infection of the hip. *JBJS*. 2003 Feb 1;85(2):198-204.