

## RESEARCH ARTICLE

# Reliability of Postoperative Radiographies in Ankle Fractures

Mohammadreza Abbasian, MD<sup>1,2</sup>; Farsad Biglari, MD<sup>3</sup>; Mehrdad Sadighi, MD<sup>3</sup>; Adel Ebrahimpour, MD<sup>3</sup>

Research performed at Akhtar Hospital, Shahid Beheshti University of Medical Sciences, Tehran, Iran

Received: 17 September 2019

Accepted: 26 April 2020

## Abstract

**Background:** The accuracy of reduction of ankle fractures using postoperative plain radiographies (x-ray) remains widely controversial. Some authors have demonstrated that postoperative computed tomography (CT) scan can be useful for these patients. In current study, the efficacy of x-rays after fixation of ankle fractures was investigated based on the CT scan findings.

**Methods:** A total of 73 patients with ankle fractures who were subjected to open reduction internal fixation (ORIF) were enrolled. After surgery, if the reduction was acceptable based on the x-rays according to standard measurements, the patient was referred for CT scanning. Forty four patients were included in the study. Undesirable CT scan findings including malreduction of fragments or articular surfaces, device malpositioning, missed fractures, and undetected intra-articular fragments were documented.

**Results:** Undesirable CT findings were seen in 25 patients (56.8%). CT scan showed acceptable reduction without device malpositioning in 19 patients. The most prevalent findings in CT images were malreduction and device malpositioning in 17 and 16 patients, respectively. There was no abnormal finding in CT imaging of lateral malleolar fractures. In two thirds of the injured syndesmosis, device malpositioning, and malreduction were detected in CT scan.

**Conclusion:** Despite acceptable postoperative x-rays, a considerable number of patients with ankle fractures had inappropriate reduction or undesirable findings in their postoperative CT scan. It seems necessary to use CT scan after ORIF of ankle fractures in order to examine the accuracy of reduction. Further validation of postoperative CT scan in ankle fracture surgery should be investigated.

**Level of evidence:** IV

**Keywords:** Ankle fracture, Computed tomography, Device malpositioning, Malreduction, Plain radiography, Syndesmosis

## Introduction

Ankle injury is one of the most common injuries among sport-related injuries. Ankle fracture has a prevalence of approximately 174 per 100,000 people per year (1). It has been reported to account for approximately 6.7% to 10% of all fractures (2, 3). The high prevalence of these fractures and consequences of

inappropriate treatment necessitates the use of the most reliable and efficacious treatment techniques. At present, open reduction and internal fixation (ORIF) using various implants such as plate, screws, or cerclage is considered the most acceptable treatment method (4, 5). ORIF provides the surgeon with direct visuals of the fracture

**Corresponding Author:** Adel Ebrahimpour, Department of Orthopedic Surgery, Shohada Tajrish Hospital, Shahid Beheshti University of Medical Sciences, Tehran, Iran  
Email: a.ebrahimpour@sbm.ac.ir



THE ONLINE VERSION OF THIS ARTICLE  
ABJS.MUMS.AC.IR

site and quality of reduction. The goals of ankle fracture surgery include restoration of anatomy and stability for early movement, complete functional recovery and prevention of posttraumatic osteoarthritis (OA) (6). It has been reported that post injury complications such as posttraumatic OA and chronic pain can be occurred either with or without malreduction (7, 8). Congruency of the joint surfaces should be carefully evaluated when the components are anatomically reduced and stable. One of the most significant problems with ankle fracture is that even if postoperative radiographies (x-rays) indicate an anatomical reduction, it does not necessarily indicate good clinical and functional outcomes (9). It has been suggested that the undetectable death of chondrocytes from trauma and osteochondral injuries could be responsible for the poor outcomes (10). Furthermore, some previous studies have demonstrated that radiologic assessments are not accurate enough to detect malreduction or other problems after ORIF of ankle fractures, especially in the case of syndesmosis injuries (11-16). Since plain radiography does not provide axial view, it is likely that does not reflect necessarily the actual circumstances of the joints and fracture site. For a variety of reasons including high availability and low cost plain radiography is currently the most prevalent technique of assessing the reduction and implant positioning after various orthopedic surgeries. However, there are some limitations that need to be addressed. For example, swelling and postoperative pain can influence proper limb positioning during radiography and greatly reduce the patient's ability to interact (11). Measurement of medial clear space may be affected by the degree of axial rotation of the limb, image magnification, and ankle plantar flexion (17-20). On the other hand, CT scan has advantages that greatly increase the ability of surgeons in post-surgical investigations. Several studies have demonstrated superior diagnostic efficacy of CT images in various fractures before and after surgery (21, 22). Currently, there are limited studies that compared the efficacy of plain radiography and CT scan in detecting malreduction after ORIF of ankle fracture (11, 13-15). In the current study, the diagnostic efficacy of postoperative plain radiography was compared to CT scanning in detecting malreduction or other problems in patients with ankle fractures with or without syndesmosis injury.

### Materials and Methods

In current prospective study, patients underwent ORIF for treatment of ankle fractures (medial malleolar, lateral malleolar, posterior malleolar, bi- or trimalleolar fracture) with or without syndesmosis injury during 2016 and 2017 were evaluated. Before the study, patients got familiar with the methods and objectives of the study and signed an informed consent. All patients were treated in Akhtar hospital, Shahid Beheshti University of Medical Sciences, Tehran, Iran. Patients with anatomical or acceptable post-operative reduction according to the standard radiologic measurements were included in the study. Cases with obvious malreduction on standard postoperative radiographies were not enrolled in the study. Furthermore pilon, open, pathologic, and physical fractures as well as patients with a history of previous ankle fracture or osteoarthritis on the same ankle

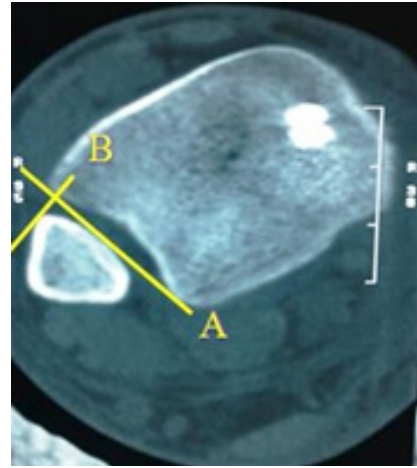


Figure 1. Examining method for presence of anteroposterior subluxation and diastasis in syndesmosis. (23).

were excluded. After initial physical examinations and radiologic assay, the eligible patients underwent ORIF surgery. The surgical technique and type of implant were selected based on the location and type of injury. All steps of surgeries were done under fluoroscopic imaging with anteroposterior, lateral, and mortis view. Postoperatively, the limb was immobilized in a short leg splint. On the second postoperative day, radiologic studies in standard ankle views were done. The criteria for acceptable reduction on x-rays included step-off of joint surfaces <2 mm, displacement of fragments <2 mm, medial clear space <4 mm, no disruption in ball sign (fibular length), tibiofibular overlap >5 mm on anteroposterior view, no talar tilt, no osteochondral loose body or missed fracture, congruency of the ankle mortise and no malpositioned implant. If reduction was either optimal or acceptable according to the radiographic measurements, the patient was referred for CT scanning. CT scan was performed on three axial, coronal, and sagittal planes with 2 mm thickness. The criteria for acceptable reduction on CT images were exactly the same as x-ray. Furthermore, presence of malrotation or subluxation in syndesmosis and the position of syndesmosis screw were investigated on axial CT images [Figure 1-3] (23, 24). For detecting any malreduction of syndesmosis, line A was drawn along the most lateral aspect of the anterior and posterior tubercles of the incisura fibularis. line B was drawn perpendicular to line A at the anterior tubercle. Lateral displacement of fibula more than 2 mm relative to line A was considered as diastasis of syndesmosis. Fibula displacement more than 2 mm relative to line B toward either anterior or posterior was considered as syndesmosis subluxation [Figure 1] (23). Any malrotation was diagnosed with more than 2 mm differences between the lines drawn from the center of distal tibia to anterior and posterior parts of fibula [Figure 2] (24). All measurements were made 10 mm proximal to the tibial plafond and parallel to the tibial side of ankle joint on the axial plane of CT scan. The results were recorded based on the type and location of injury and statically analyzed.

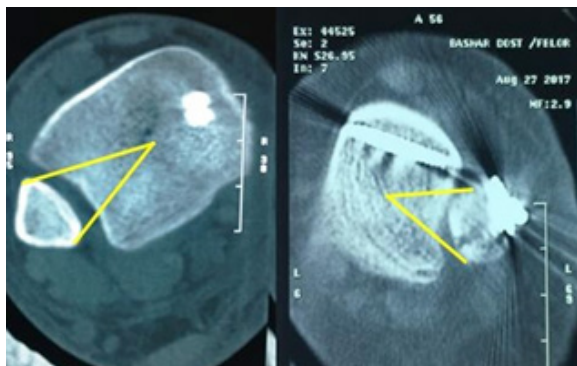


Figure 2. Examining method for presence of malrotation in syndesmosis (24).

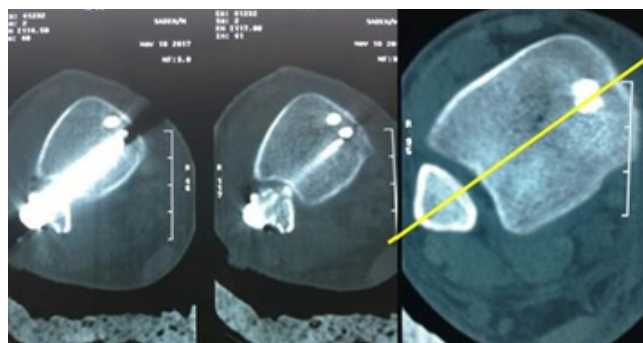


Figure 3. Examining method for syndesmosis screw position.

**Results**

In total, 73 patients with ankle fracture were investigated. Twenty-nine patients were excluded due to unacceptable postoperative x-rays or presence of exclusion criteria and the study was completed with a total of 44 patients (25 males and 19 females). The patients aged 41.2±9.1 (Range: 23-57). Figure 4 shows

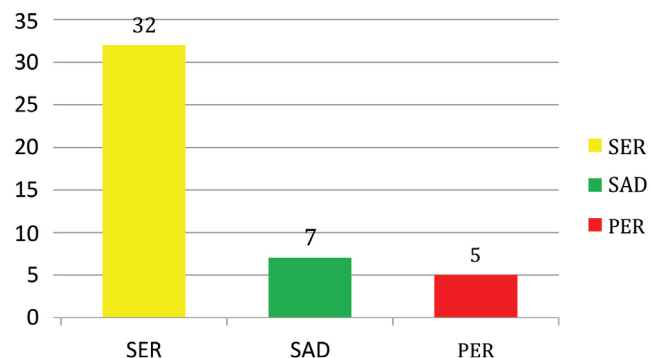


Figure 4. The incidence of mechanism of injury (SER: supination external rotation, SAD: supination adduction, PER: pronation external rotation ).

the incidence of mechanism of injury in patients. As expected, the most prevalent mechanism of ankle fracture was supination external rotation. The frequency of location of injury is shown in Figure 5 and the number of injuries per patient is shown in Figure 6. Although all patients had acceptable reduction on x-rays, CT images revealed reduction problems in 25 patients (56.8%). In other words, the reduction was only acceptable in 19 (43.2%) patients based on the CT findings. The most common abnormal CT finding was malreduction in 17 patients followed by implant malpositioning in 16 patients [Figure 7]. All the 12 cases with malposition of syndesmosis screw led to malrotation of fibula in incisura. The incidence of abnormal CT findings based on the location of the injury is shown in Figure 8. The number of parameters includes isolated and combined injuries. No abnormal CT scan findings was in lateral malleolus fractures either isolated or combined with other injuries while in medial malleolus, CT scan showed abnormal findings in eight patients (malreduction in six patients and device malpositioning in four patients). In other words, malreduction and device malpositioning were present in two patients, concurrently. Twelve patients among eighteen cases with syndesmosis injury have malreduction or device malpositioning (five malreduction and 12 device malpositioning). One-third of

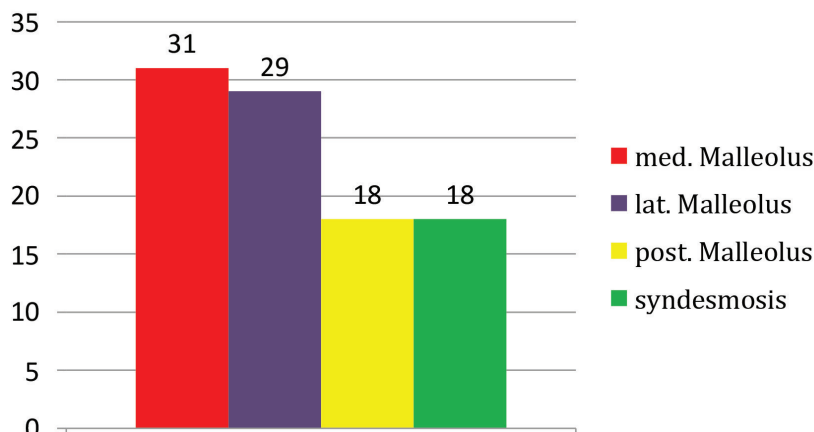


Figure 5. The frequency of injury location.

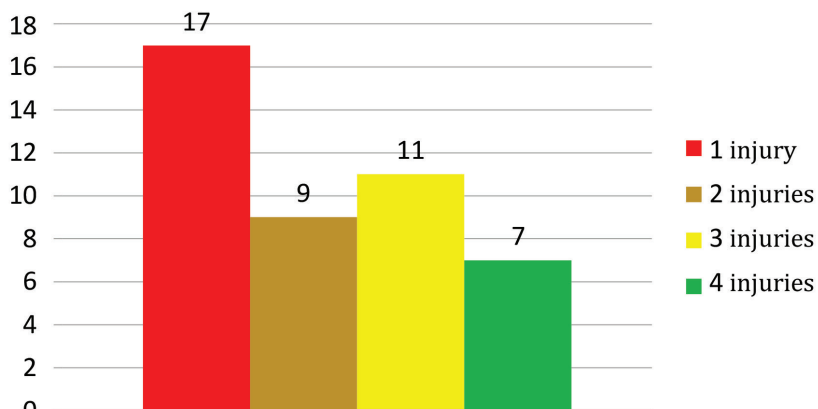


Figure 6. The frequency of injuries in patients.

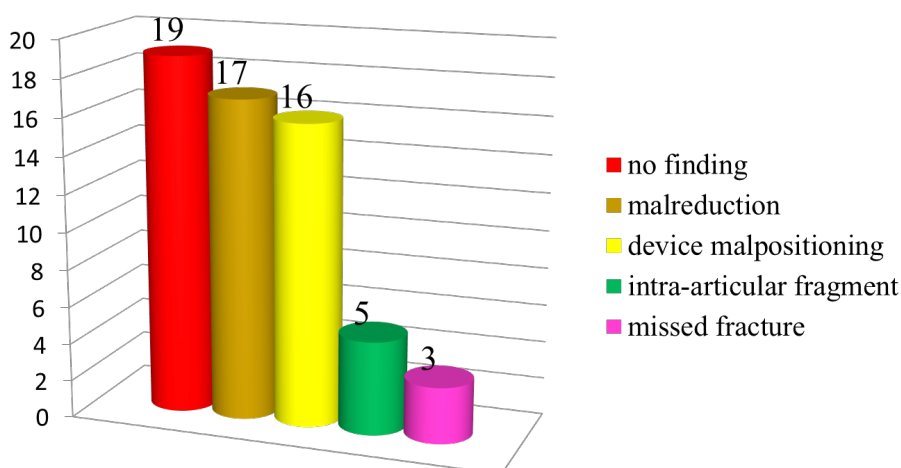


Figure 7. The incidence of abnormal CT findings.

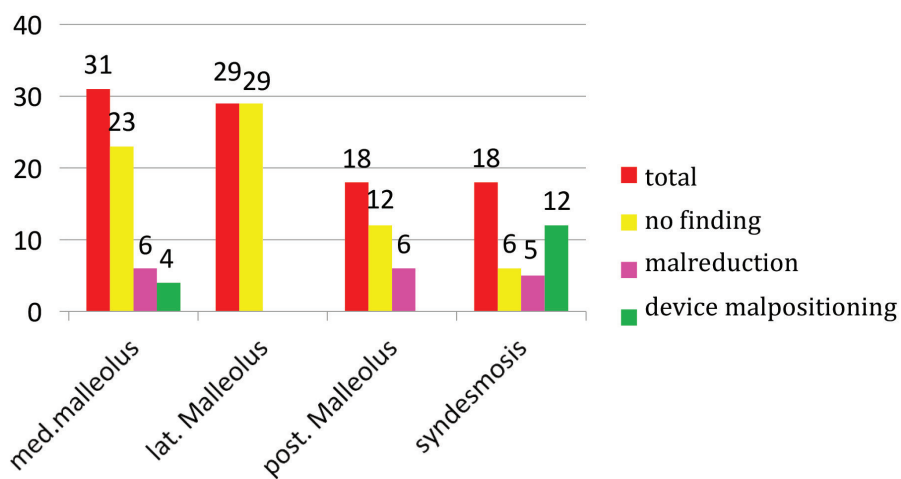


Figure 8. The incidence of abnormal CT findings in different injury location.

patients with posterior malleolar fractures suffered from malreduction.

### Discussion

Considering the need for anatomical reduction of ankle fractures for proper functioning of patients' and prevention of subsequent complications, it is clear that finding an appropriate technique for evaluation of ankle fracture surgery is very important. On the other hand, it seems that radiography, despite being an easy, fast, and accessible technique, does not have the required efficacy to evaluate diastasis and malreduction of syndesmosis, especially after surgery (11-16, 25). Post-operative radiography has several limitations including improper limb position due to post operation pain or inappropriate splint position and magnification of imaging which affect the radiographic measurements. Especially excessive axial rotation and plantar flexion of ankle affect the radiographic parameters. Furthermore low visual quality of studies occurs because of soft tissue swelling and splint materials (11, 17-20). In cases where lateral malleolus is fixed with a plate, posterior malleolus cannot be observed in simple radiography. Fluoroscopic imaging during surgery has the same limitations such as lack of axial view and being disturbed by limb or x-ray beam rotation. Simple radiographic constraints make the task much more complicated when reduction of syndesmosis is examined owing to the fact that there are currently no specific quantitative parameters for the investigation and detection of tibiofibular joint syndesmosis instability, and therefore requires more clinical studies on a large number of samples (26-28). In a study about detecting malreduction of tibiofibular syndesmosis in 25 cases of ankle fracture with syndesmotom instability, the patients were investigated by post operation standard ankle radiographies and ankle CT scanning. Post-operative CT scan revealed syndesmosis malreduction in 13 cases (%56) which were not detected in post-operative radiologic studies. Excessive internal rotation of fibula in incisura fibularis was the most abnormal finding in those cases. The authors calculated a sensitivity of %31 and specificity of %83 for post-operative radiographic studies. They concluded that post operation radiologic parameters are not accurate enough for detecting syndesmosis malreduction (13). Sagi et al. found that 39% of patients had malreduction after surgery (compared to the CT scan of the opposite limb) and stated that surgeons should carry out CT scan on both the damaged and healthy sides after reduction. They also stated that syndesmosis of both sides should be compared with each other (16). In confirmation of the recommendation of Sagi et al., we can mention two studies of Dikos and Mukhopadhyay (27, 28). Dikos et al. investigated the properties of normal syndesmosis in tCT scan and stated that due to many individual differences, using CT scan is the best option for examination of syndesmosis (27). Mukhopadhyay et al. stated that use of 2 mm criterion (the difference in distance between the anterior and posterior folds incisura and fibula) is not a reliable and feasible technique in all patients. They recommended that each individual should be examined

separately (28). However, it should be noted that this can expose patients to ionizing radiation and as such may not be used in the clinic. These harmonious results, as well as lack of sufficient studies prompted the present study on the accuracy and efficacy of simple radiography in the diagnosis of malreduction after ORIF of the ankle fracture. In fact, considering the cost and complexities of CT, we aimed to ascertain whether it was necessary to use it after the ankle reduction or not. This is in variance with the goals of the study conducted by Gardner et al. (13) and Sagi et al. (16). In addition to syndesmosis, reduction of other ankle sections was also examined.

In the current study, it has been well established that simple radiography after ORIF of ankle fracture cannot show problems of reduction and residual damages. In the current study, nearly 57% of patients had malreduction or problems that were not visible in simple radiography. The most significant complication in patients subjected to CT scan was malreduction and device malpositioning; the second complication was significantly common in syndesmosis damages. Malreduction was observed in syndesmosis and posterior malleolus fracture. However, simple radiography was feasible and reliable in evaluating lateral malleolus fracture fixation. In some previous studies, results that are in consonance with our results have been obtained. For example, Chen et al. in a study of 168 patients in 2015, stated that the overall interobserver and intraobserver agreements in CT scan after surgery were significantly better than simple radiography. In addition, they stated that CT allowed detection of the left articular step, displacement of parts and undesirable internal fixation after ORIF of ankle fracture better than simple radiography (11). In another study by Palmanovich et al. in 2016, 29% of patients undergoing CT scan after anesthetic fracture surgery, experienced revision surgery during the first week after surgery. In the CT scan of these patients, there were syndesmosis malreduction, malreduction of the posterior lip, and intra-articular parts, while there was no issue with the outcomes of simple radiography (15). CT has the benefits of more accurate examination of damages. For example, CT scans can be employed to evaluate tibial plafond. In addition, with CT, we can scrutinize implant and bone status. CT scan shows very small movements of fractures, articular displacement of pilon fracture, and size of posterior malleolus fractures in conditions of subcortical damages. Using CT, it is possible to observe some areas that cannot be seen in simple radiography, as well as assessing the reduction of syndesmosis (29-32). Artifacts caused by metallic implants in CT scan can be very problematic and reduce the quality of the image (11) and requires more precision at imaging time. One of the important issues in the evaluation of syndesmosis with CT is that there are no acceptable numerical criteria for determining its malreduction or subluxation. To resolve these issues, we used methods proposed by Phisitkul et al. (23) and Tang et al. (24) which were briefly explained in the materials and methods section. It is clear that the diagnostic value of these techniques needs to be further examined; however, since there is inadequate information in this field, we used these two methods.

Regarding to the materials and results of this study, it seems that the use of fluoroscopy with dynamic mode instead of standard anteroposterior and lateral views at the time of ORIF of ankle fractures can be very important and efficacious in obtaining suitable and sufficient reduction. Since syndesmosis damages are not reduced properly and correctly in many patients, researchers have recommended that the joint should be opened surgically. Additionally, it is necessary to perform routine CT scan after surgery in patients with ankle injury, so that revision surgeries can be taken in cases where serious issues or malreduction is of paramount importance. Like other studies, the current study had limitations. Although some studies have suggested that the best way to evaluate syndesmosis is CT of the healthy side; we did not do this for ethical reasons and cost saving. Lastly, the number of patients in this study was not enough; more patients should be examined in subsequent studies.

The results of this study showed that simple radiography after ORIF of the ankle fracture with or without syndesmosis injury does not have the desired efficacy in diagnosing malreduction and other surgical problems such as device malpositioning. It seems necessary to use CT scan after ORIF of ankle fractures in order to examine the accuracy of reduction. Further validation of postoperative CT scan in ankle fracture surgery should

be investigated.

**Conflict of interests:** The authors declare no conflict of interest regarding this manuscript.

All procedures performed in studies involving human participants were in accordance with the ethical standards of the institutional and/or national research committee and with the 1964 Helsinki declaration and its later amendments or comparable ethical standards.

Informed consent was obtained from all individual participants included in the study.

Mohammadreza Abbasian MD<sup>1,2</sup>

Farsad Biglari MD<sup>3</sup>

Mehrdad Sadighi MD<sup>3</sup>

Adel Ebrahimpour MD<sup>3</sup>

1 Department of Orthopedic Surgery, Akhtar Hospital, Shahid Beheshti University of Medical Sciences, Tehran, Iran

2 Center for Advanced Orthopedic Studies, BIDMC, Harvard Medical School, Boston, MA, USA

3 Department of Orthopedic Surgery, Shohada Tajrish Hospital, Shahid Beheshti University of Medical Sciences, Tehran, Iran

## References

1. Kannus P, Palvanen M, Niemi S, Parkkari J, Jrvinen M. Increasing number and incidence of low-trauma ankle fractures in elderly people: Finnish statistics during 1970-2000 and projections for the future. *Bone*. 2002; 31(3):430-3.
2. Court-Brown CM, Caesar B. Epidemiology of adult fractures: a review. *Injury*. 2006; 37(8):691-7.
3. Zhang Y. Clinical epidemiology of orthopedic trauma. Thieme; 2012.
4. Ostrum RF, Avery MC. Open reduction internal fixation of a bimalleolar ankle fracture with syndesmotic injury. *Journal of orthopaedic trauma*. 2016; 30:S43-4.
5. Gonzalez TA, Macaulay AA, Ehrlichman LK, Drummond R, Mittal V, DiGiovanni CW. Arthroscopically assisted versus standard open reduction and internal fixation techniques for the acute ankle fracture. *Foot & ankle international*. 2016; 37(5):554-62.
6. Mak MF, Stern R, Assal M. Repair of syndesmosis injury in ankle fractures: Current state of the art. *EFORT Open Reviews*. 2018; 3(1):24-9.
7. Thordarson DB, Motamed S, Hedman T, Ebramzadeh E, Bakshian S. The effect of fibular malreduction on contact pressures in an ankle fracture malunion model. *JBJS*. 1997; 79(12):1809-5.
8. Pretterklieber ML. Anatomy and kinematics of the human ankle joint. *Der Radiologe*. 1999; 39(1):1-7.
9. Mont MA, Sedlin ED, Weiner LS, Miller AR. Postoperative radiographs as predictors of clinical outcome in unstable ankle fractures. *Journal of orthopaedic trauma*. 1992; 6(3):352-7.
10. Ono A, Nishikawa S, Nagao A, Irie T, Sasaki M, Kouno T. Arthroscopically assisted treatment of ankle fractures: arthroscopic findings and surgical outcomes. *Arthroscopy: The Journal of Arthroscopic & Related Surgery*. 2004; 20(6):627-31.
11. Chen Y, Zhang K, Qiang M, Li H, Dai H. Comparison of plain radiography and CT in postoperative evaluation of ankle fractures. *Clinical radiology*. 2015; 70(8):e74-82.
12. Miniaci-Coxhead SL, Martin EA, Ketz JP. Quality and utility of immediate formal postoperative radiographs in ankle fractures. *Foot & Ankle International*. 2015; 36(10):1196-201.
13. Gardner MJ, Demetrakopoulos D, Briggs SM, Helfet DL, Lorich DG. Malreduction of the tibiofibular syndesmosis in ankle fractures. *Foot & ankle international*. 2006; 27(10):788-92.
14. Ebraheim NA, Lu J, Yang H, Mekhail AO, Yeasting RA. Radiographic and CT evaluation of tibiofibular syndesmotic diastasis: a cadaver study. *Foot & ankle international*. 1997; 18(11):693-8.
15. Palmanovich E, Brin YS, Kish B, Nyska M, Hetsroni I. Value of early postoperative computed tomography assessment in ankle fractures defining joint congruity and criticizing the need for early revision surgery. *The Journal of Foot and Ankle Surgery*. 2016; 55(3):465-9.
16. Sagi HC, Shah AR, Sanders RW. The functional

- consequence of syndesmotic joint malreduction at a minimum 2-year follow-up. *Journal of orthopaedic trauma*. 2012; 26(7):439-43.
17. Goergen TG, Danzig LA, Resnick D, Owen CA. Roentgenographic evaluation of the tibiotalar joint. *JBJS*. 1977; 59(7):874-7.
  18. Kragh Jr JF, Ward JA. Radiographic indicators of ankle instability: changes with plantarflexion. *Foot & ankle international*. 2006; 27(1):23-8.
  19. Pneumaticos SG, Noble PC, Chatziioannou SN, Trevino SG. The effects of rotation on radiographic evaluation of the tibiofibular syndesmosis. *Foot & ankle international*. 2002; 23(2):107-11.
  20. Saldua NS, Harris JF, LeClere LE, Girard PJ, Carney JR. Plantar flexion influences radiographic measurements of the ankle mortise. *JBJS*. 2010; 92(4):911-5.
  21. Li H, Chen Y, Qiang M, Zhang K, Jiang Y, Zhang Y, et al. Evaluation of computed tomography post-processing images in postoperative assessment of Lisfranc injuries compared with plain radiographs. *Journal of orthopaedic surgery and research*. 2017; 12(1):91.
  22. Leung KH, Fang CX, Lau TW, Li Leung FK. Preoperative radiography versus computed tomography for surgical planning for ankle fractures. *Journal of Orthopaedic Surgery*. 2016; 24(2):158-62.
  23. Phisitkul P, Ebinger T, Goetz J, Vaseenon T, Marsh JL. Forceps reduction of the syndesmosis in rotational ankle fractures: a cadaveric study. *JBJS*. 2012; 94(24):2256-61.
  24. Tang CW, Roidis N, Vaishnav S, Patel A, Thordarson DB. Position of the distal fibular fragment in pronation and supination ankle fractures: a CT evaluation. *Foot & ankle international*. 2003; 24(7):561-6.
  25. Pettrone FA, Gail M, Pee D, Fitzpatrick T, Van Herpe LB. Quantitative criteria for prediction of the results after displaced fracture of the ankle. *JBJS*. 1983; 65(5):667-77.
  26. Liu X, Yu G. Progress in diagnosis and treatment of distal tibiofibular syndesmosis injury. *Zhongguo xiu fu chong jian wai ke za zhi= Zhongguo xiu fu chongjian waik e zazhi= Chinese journal of reparative and reconstructive surgery*. 2012; 26(5):612-6.
  27. Dikos GD, Heisler J, Choplin RH, Weber TG. Normal tibiofibular relationships at the syndesmosis on axial CT imaging. *Journal of orthopaedic trauma*. 2012; 26(7):433-8.
  28. Mukhopadhyay S, Metcalfe A, Guha AR, Mohanty K, Hemmadi S, Lyons K, et al. Malreduction of syndesmosis—are we considering the anatomical variation?. *Injury*. 2011; 42(10):1073-6.
  29. Magid D, Michelson JD, Ney DR, Fishman EK. Adult ankle fractures: comparison of plain films and interactive two-and three-dimensional CT scans. *AJR. American journal of roentgenology*. 1990; 154(5):1017-23.
  30. Grigoryan M, Lynch JA, Fierlinger AL, Guermazi A, Fan B, MacLean DB, et al. Quantitative and qualitative assessment of closed fracture healing using computed tomography and conventional radiography1. *Academic radiology*. 2003; 10(11):1267-73.
  31. Calhoun PS, Kuszyk BS, Heath DG, Carley JC, Fishman EK. Three-dimensional volume rendering of spiral CT data: theory and method. *Radiographics*. 1999; 19(3):745-64.
  32. Kuszyk BS, Heath DG, Bliss DF, Fishman EK. Skeletal 3-D CT: advantages of volume rendering over surface rendering. *Skeletal radiology*. 1996; 25(3):207-14.