

## CASE REPORT

# A Rare Case of Flexor Digitorum Accessorius Longus Muscle Presenting as Tarsal Tunnel Syndrome

Hossein Ettehadi, MD<sup>1,2</sup>; Nikiforos Pandelis Saragas, MBBCh, FCS (SA) Ortho MMed, Ortho Surg Wits PhD (Wits)<sup>1,2</sup>;  
Paulo Ferrao, MBChB, FCS (SA) Ortho<sup>1,2</sup>

Research performed at Netcare Linksfield Hospital, Johannesburg, South Africa

Received: 10 April 2020

Accepted: 19 November 2020

## Abstract

Tarsal tunnel syndrome (TTS) is a relatively uncommon nerve entrapment neuropathy. Many pathologies are reported as possible causes for TTS. The diagnosis of TTS can be difficult and often missed. We present a rare case of TTS due to an accessory flexor digitorum longus muscle. Together with a high index of suspicion, MRI is the investigation of choice in making the diagnosis. These patients are best managed with excision or transposition of the flexor digitorum accessorius longus (FDAL) and neurolysis of the posterior tibial nerve and its branches.

**Level of evidence:** IV

**Keywords:** Flexor digitorum muscle, Plantar fasciitis, Tarsal tunnel syndrome

## Introduction

Tarsal tunnel syndrome (TTS) is a relatively uncommon nerve entrapment neuropathy, which involves the posterior tibial nerve or one of its branches. Kopell and Thompson were the first to describe this pathology, which was later named by both Keck in 1962 and Lam in 1967 in separate articles (1-3).

The tarsal tunnel (TT) includes the tibialis posterior tendon, flexor hallucis longus, flexor digitorum longus, and posterior tibial nerve and artery (4). The various causes described for TTS include ganglion of the tendon sheaths, lipoma, neural tumors, exostosis or fracture fragments, venous enlargement, severe pronation, intrinsic nerve pathologies, medial talocalcaneal bar, and accessory muscles within the TT, such as accessory soleus or flexor digitorum longus (5, 6).

Patients with TTS have difficulty in describing their pain. They often report diffuse plantar and medial ankle pain, which may be described as burning, stabbing, shooting, shocking, or electric in nature. Pain is increased with

prolonged standing or walking and often aggravates at night. In one-third of patients, proximal migration of the medial pain is described (7-9). On physical examination, they may have posteromedial tenderness at the ankle. Percussion over the tarsal tunnel may elicit pain along with the distribution of the medial and lateral plantar nerves, known as Tinel's test. Sensitivity and specificity for the Tinel test range from 25%-75% and 70%-90%, respectively (10).

The dorsiflexion-eversion test involves passively dorsiflexing and everting the ankle to the end range of motion and holding that position for 10 sec. Reproduction of symptoms is a positive sign due to the compression of the posterior tibial nerve in this position. This test is positive in 82% of patients with TTS (10). Nevertheless, the sensory deficit is not always obvious, and patients may have numbness and dysesthesia. It is very difficult to detect any motor weakness in TTS; however, atrophy of the abductor hallucis muscle can be present (7, 8).

**Corresponding Author:** Hossein Ettehadi, Department of Orthopaedic Surgery, University of the Witwatersrand, Johannesburg, South Africa  
Email: camran\_itehadi@yahoo.com



THE ONLINE VERSION OF THIS ARTICLE  
ABJS.MUMS.AC.IR

Radiologic evaluation should be performed to rule out other pathologies, including stress fractures, bone lesions, or arthritis. Ultrasonography is useful for detecting any space-occupying lesion. Magnetic resonance imaging (MRI) scans can detect many extrinsic and intrinsic causes (11-13).

Electrodiagnostic studies should be conducted on all patients suspected of TTS. Nerve conduction velocity (NCV) and electromyography (EMG) are often abnormal, which may include delayed nerve conduction and decreased amplitude of motor action potentials in the intrinsic muscles of the foot. Sensory NCV is more likely to be abnormal than motor NCV; therefore, the sensory NCV study is probably more sensitive. A positive result is not necessary to diagnose TTS as the diagnosis is based on clinical examination (9, 14).

Treatment starts with conservative management, including nonsteroidal anti-inflammatory drugs, oral Vitamin B, selective serotonin reuptake inhibitors, anti-seizure medications, physical therapy, and bracing. Although published papers have reported 420 case series on the various conservative treatment modalities, there is a lack of quantifiable empirical evidence of efficacy (15, 16). If the symptoms do not resolve with conservative management, surgical decompression and neurolysis are recommended. The outcome of surgery is variable and dependent on the causative pathology. Patients with identifiable compressive neuropathy have more favorable outcomes post-surgery. This study presented a rare case of TTS due to a flexor digitorum accessorius longus muscle (FDAL). Informed consent was obtained from the patient to publish this clinical case, including the use of intraoperative photographs.

### Case presentation

A 55-year-old female presented to our consultation clinic with a 2-year history of right plantar foot pain. She was initially diagnosed with plantar fasciitis and managed conservatively for 6 months. Despite appropriate conservative management, the subject continued to have persistent pain. She subsequently had a medial head of gastrocnemius release done. Unfortunately, her symptoms remained unchanged for 6 months after the surgery. Due to her persistent symptoms, she was informed that her plantar fasciitis was being aggravated by a heel spur. Therefore, she then had a plantar fascia release and excision of the bony spur. Subsequent to her last surgery, she felt that her symptoms had progressively worsened. She subsequently had a computed tomography scan and MRI of the right foot which reported no abnormalities besides some scarring visible around the area of the plantar fascia release, however, with no increased signal to suggest inflammation. She was then referred for pain management which included using Pregabalin.

She referred again 7 months after the second surgery. She described a burning pain radiating under the sole of her right foot, especially the medial half. Her symptoms aggravated at night. She was struggling with any kind of closed shoe wear and was severely limited in doing her daily activities.

She has a fair alignment of both feet clinically and

walked with an antalgic gait on the right and loaded on the lateral border of the foot as the medial plantar surface was too sensitive. The ankle and hindfoot joints were mobile and non-tender. She had significant tenderness to palpation over the tarsal tunnel area with a positive Tinel's test radiating into the sole of the foot. She also had altered sensation along with the distribution of the medial plantar and calcaneal nerve branches. There were good palpable pulses in the foot. The rest of the foot was asymptomatic.

Nerve conduction studies reported active denervation on EMG in the right abductor hallucis and abductor digiti quinti pedis muscles and reduced compound muscle action potential amplitude of the right medial plantar nerve. An ultrasound of the tarsal tunnel area reported no obvious compressive mass of the nerve in the area. A diagnosis of tarsal tunnel syndrome was provided. The option of surgical decompression and neurolysis was discussed with the patient. The patient agreed and wanted to proceed with surgery.

A medial incision was marked out 1 cm posterior to the medial malleolus extending proximally 10 cm and curving distally approximately 5 cm. The skin incision was made and slowly deepened down to the flexor retinaculum. The flexor retinaculum was then opened under direct vision [Figure 1]. A muscle belly was identified directly under the sheath, which was not expected to be there. The muscle belly, which was found during the dissection, was identified as an FDAL muscle. This muscle was enveloping the posterior tibial nerve. The muscle was carefully released off the posterior tibial nerve [Figure 2]. The muscle belly could easily be transposed posteriorly to the nerve relieving the pressure; consequently, it was not resected [Figure 3]. Neurolysis of the posterior tibial nerve was conducted. The nerve was then dissected distally to where it branched into the medial and lateral plantar nerves. The medial branch was first dissected out distally to where it dived deep to the abductor hallucis muscle. The fascia of the abductor hallucis muscle was released around the nerve. Afterward, the lateral branch was dissected out deep into the sole of the foot. A neurolysis of the first branch of the lateral plantar nerve was also performed. Careful hemostasis was achieved, and the superficial layers of the wound were closed in layers. The leg was placed in a back slab. The patient's MRI was carefully re-evaluated, resulting in the

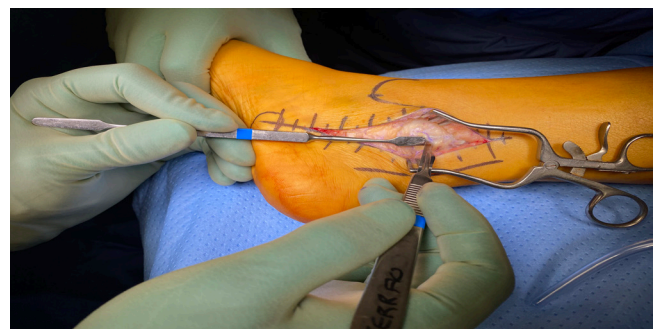

Figure 1. Flexor retinaculum being opened under direct vision.

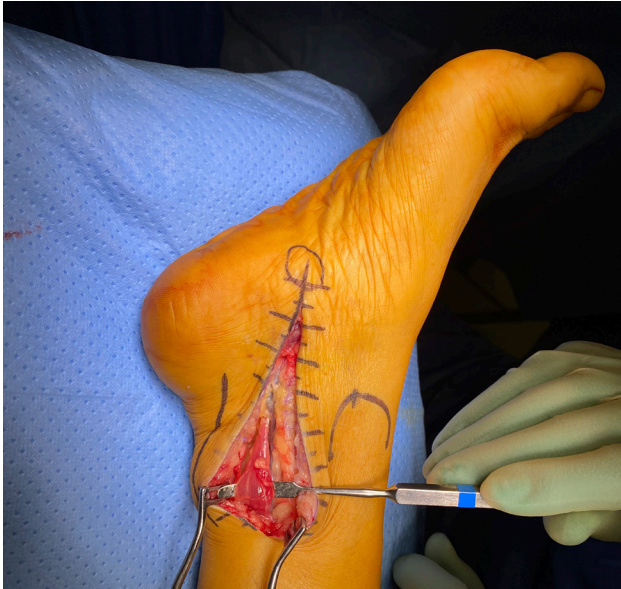

Figure 2. Flexor digitorum accessorius longus muscle being carefully released off the posterior tibial nerve.

include the FDAL, accessory soleus, peroneocalcaneus internus, and tibiocalcaneus internus. Flexor digitorum accessorius longus muscle is predominantly found in

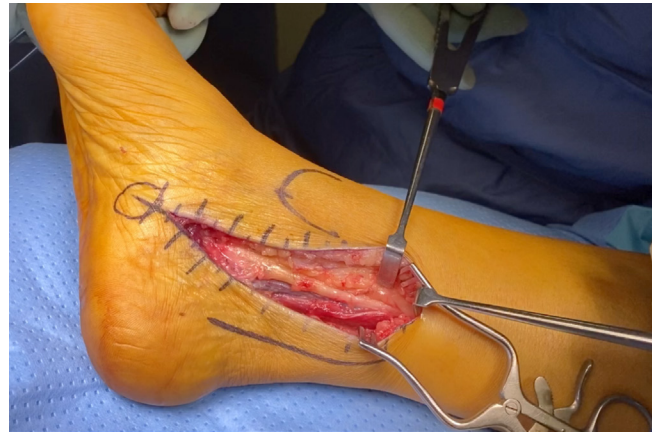


Figure 3. Muscle belly being possibly easily transposed posteriorly to the nerve relieving the pressure.

identification of FDAL [Figure 4] (20, 21).

Postoperatively, she was immobilized non-weight bearing in the back slab for 4 weeks, of which the first 2 weeks were strict bed rest with elevation. She was placed in a moon boot and allowed to weight bear as tolerated at 4 weeks. Physiotherapy was started at 4 weeks focusing on desensitization and intrinsic muscle strengthening. She transitioned into supportive shoes at 8 weeks. At the 12-week follow-up, she no longer had any burning pain in the foot and the numbness was improving. At 6 months, she was wearing normal shoes and performing her normal daily activities. Ethics were observed and informed consent was obtained for this case report.

**Discussion**

Chronic heel pain is one of the most common orthopedic problems that has various causes. It can be highly difficult to define the exact etiology. Plantar fasciitis and TTS can have similar signs and symptoms. The first branch of the lateral plantar nerve (FBLPN) or calcaneal nerve compression can specifically present symptoms similar to plantar fasciitis. The patient in our case was managed for 2 years for suspected plantar fasciitis. It is not uncommon to have these dual pathologies presenting at the same time. Oztuna et al. reported that up to 88% of cases with chronic heel pain have some degrees of entrapment of the FBLPN and/or the medial plantar nerve from the inflamed plantar fascia based on the result of objective electrodiagnostic findings (17). Therefore, patients with plantar fasciitis, who fail conservative treatment and require surgery, are advised to perform a tarsal tunnel release with the release of the FBLPN and calcaneal nerve. The results of studies have indicated that a tarsal tunnel release combined with a partial plantar fasciotomy leads to better clinical outcomes of pain and function in selected patients with plantar fasciitis (18, 19).

Tarsal tunnel syndrome has a variety of causes, including the compression of the nerve by an accessory muscle, which is one of the rare causes. The muscles that can compress the posterior tibial nerve or its branches

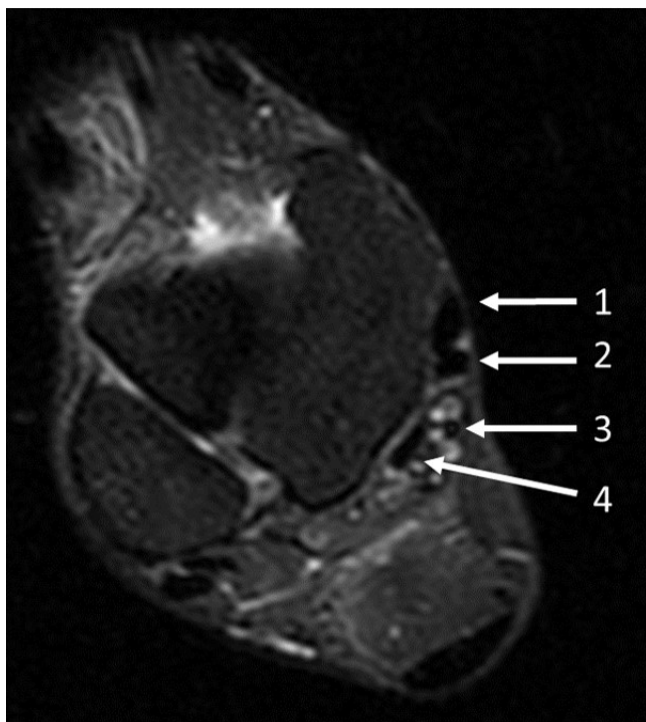


Figure 4. Axial magnetic resonance imaging showing the flexor digitorum accessorius longus; 1: Tibialis posterior tendon, 2: Flexor digitorum longus tendon, 3: Flexor digitorum accessorius longus tendon, and 4: Flexor hallucis longus tendon.



males with a prevalence of 1.6%-8%, while the patient in our case was a female, making the diagnosis even less common.

With regards to the anatomy, the origin of the FDAL muscle is inferior to the popliteal fossa, near the origins of the long digital flexors, and the fascia overlying popliteus muscle. Flexor digitorum accessorius longus muscle can be single- or double-headed. Single-headed FDAL is more common and originates from either the tibia or fibula. The double-headed FDAL has the origin of the long head in the upper third of the leg and the short head in the lower third of the leg. Insertion is on the lesser toes or quadratus plantae.

The course of FDAL in the tarsal tunnel is usually tendinous and posterior to the flexor hallucis longus (FHL). There are some reports in the literature regarding the FDAL being anterior to the FHL with a low-lying muscle belly, which may cause compression of the posterior tibial nerve, as was evident in our case study (11, 22, 23, 24). Other theories that describe why the FDAL causes TTS include trauma, hypertrophy of the muscle, varied origin and insertion, and exercise-induced expansion (muscle engorgement) (25). The gold standard for diagnosing an FDAL pre-operatively is with MRI scans using the axial cuts. However, most case reports did not routinely perform an MRI scan prior to surgery (26). In the literature, only a few cases are reporting TTS due to FDAL compression (11, 26).

Conservative management is suggested as the first step in the management of these patients; nevertheless, there are only 30% success reports (27, 28). The majority of patients will require surgical intervention, which includes decompression of the tarsal tunnel with the release of the lacinate ligament and transposition or excision of the FDAL. The consensus between surgeons regarding surgical treatment is the resection of the FDAL rather than transposition. Based on the literature review, the majority of authors reported that they could not accurately identify the origin and sometimes even

the insertion of FDAL; as a result, the resection of FDAL was often performed at the musculotendinous junction (22, 25, 26). Only in one study, which was carried out by Sammarco and Conti, the researchers identified the origin of the FDAL and resected the muscle from there (29). In our case, the muscle was easily transposed away from the posterior tibial nerve, and it was decided not to resect the muscle.

Reported outcomes for TTS surgery in the presence of accessory musculature are less favorable, as compared to other space-occupying lesions. Wittmayer et al. reported less improvement in cases due to accessory muscles in comparison with other compressive etiologies and suggested that this could be attributed to the longstanding nature of the pathology with accessory muscles. Sammarco and Conti, however, reported good results in their study (22, 29). Our patient recovered with a resolution of her symptoms at 6 months.

Flexor digitorum accessorius longus is a rare cause of TTS, which should be considered as a diagnosis of TTS where no obvious causes can be identified. Magnetic resonance imaging, with a high index of suspicion, is the investigation of choice in diagnosing TTS due to FDAL. Such patients are best managed with excision or transposition of the FDAL and the neurolysis of the posterior tibial nerve and its branches.

Hossein Etehad MD<sup>1,2</sup>

Nikiforos Pandelis Saragas MBCh FCS (SA) Ortho MMed  
Ortho Surg Wits PhD (Wits)<sup>1,2</sup>

Paulo Ferrao MBChB FCS (SA) Ortho<sup>1,2</sup>

1 The Orthopaedic Foot and Ankle Unit, Netcare Linksfield Hospital, Johannesburg, South Africa.

2 Department of Orthopaedic Surgery, University of the Witwatersrand, Johannesburg, South Africa

## References

1. Kopell HP, Thompson WA. Peripheral entrapment neuropathies of the lower extremity. *New England Journal of Medicine*. 1960; 262(2):56-60.
2. Keck C. The tarsal-tunnel syndrome. *JBJS*. 1962; 44(1):180-2.
3. Lam SJ. Tarsal tunnel syndrome. *The Journal of bone and joint surgery. British volume*. 1967; 49(1):87-92.
4. Hansen JT. *Netter's Clinical Anatomy*, 3rd ed. 2014.
5. Tladi MJ, Saragas NP, Ferrao PN, Strydom A. Schwannoma and neurofibroma of the posterior tibial nerve presenting as tarsal tunnel syndrome: review of the literature with two case reports. *The Foot*. 2017; 32:22-6.
6. Cimino WR. Tarsal tunnel syndrome: review of the literature. *Foot & ankle*. 1990; 11(1):47-52.
7. Gould JS. Tarsal tunnel syndrome. *Foot and ankle clinics*. 2011; 16(2):275-86.
8. Doty JF, Coughlin MJ, Alvarez RG. *Toenails. Mann's Surgery of the Foot and Ankle*. 9th ed. Philadelphia, PA: Saunders/ Elsevier; 2014:641-648.
9. Neary KC, Chang E, Kreulen C, Giza E. Tarsal tunnel syndrome secondary to accessory musculature: a case report. *Foot & ankle specialist*. 2019; 12(6):549-54.
10. Kiel J, Kaiser K. *Tarsal Tunnel Syndrome*. Treasure Island (FL): StatPearls Publishing; 2020 Jan.-2019 Feb 4.
11. Cheung YY, Rosenberg ZS, Colon E, Jahss M. MR

- imaging of flexor digitorum accessorius longus. *Skeletal radiology*. 1999; 28(3):130-7.
12. Clemenshaw LM, Bui-Mansfield LT. Accessory muscles of the ankle, how to recognize them on MRI, and their clinical relevance. *Contemporary Diagnostic Radiology*. 2011; 34(14):1-7.
  13. Coraci D, Ioppolo F, Di Sante L, Santilli V, Padua L. Ultrasound in tarsal tunnel syndrome: Correct diagnosis for appropriate treatment. *Muscle & nerve*. 2016; 54(6):1148-9.
  14. Kaplan PE, Kernahan Jr WT. Tarsal tunnel syndrome: an electrodiagnostic and surgical correlation. *The Journal of bone and joint surgery. American volume*. 1981; 63(1):96-9.
  15. Ahmad M, Tsang K, Mackenney PJ, Adedapo AO. Tarsal tunnel syndrome: a literature review. *Foot and Ankle Surgery*. 2012; 18(3):149-52.
  16. McSweeney SC, Cichero M. Tarsal tunnel syndrome—a narrative literature review. *The Foot*. 2015; 25(4):244-50.
  17. Öztuna V, Özge A, Eskandari MM, Çolak M, Gölpinar A, Kuyurtar F. Nerve entrapment in painful heel syndrome. *Foot & ankle international*. 2002; 23(3):208-11.
  18. Conflitti JM, Tarquinio TA. Operative outcome of partial plantar fasciectomy and neurolysis to the nerve of the abductor digiti minimi muscle for recalcitrant plantar fasciitis. *Foot & ankle international*. 2004; 25(7):482-7.
  19. Davies MS, Weiss GA, Saxby TS. Plantar fasciitis: how successful is surgical intervention?. *Foot & ankle international*. 1999; 20(12):803-7.
  20. Sookur PA, Naraghi AM, Bleakney RR, Jalan R, Chan O, White LM. Accessory muscles: anatomy, symptoms, and radiologic evaluation. *Radiographics*. 2008; 28(2):481-99.
  21. Al-Himdani S, Talbot C, Kurdy N, Pillai A. Accessory muscles around the foot and ankle presenting as chronic undiagnosed pain. An illustrative case report and review of the literature. *The Foot*. 2013; 23(4):154-61.
  22. Wittmayer BC, Freed L. Diagnosis and surgical management of flexor digitorum accessorius longus-induced tarsal tunnel syndrome. *The Journal of foot and ankle surgery*. 2007; 46(6):484-7.
  23. VanCourt RB, Siesel KJ. Flexor digitorum accessorius longus muscle. *Journal of the American Podiatric Medical Association*. 1996; 86(11):559-60.
  24. Gümüşalan Y, Kalaycıoğlu A. Bilateral accessory flexor digitorum longus muscle in man. *Annals of Anatomy-Anatomischer Anzeiger*. 2000; 182(6):573-6.
  25. Kinoshita M, Okuda R, Morikawa J, Abe M. Tarsal tunnel syndrome associated with an accessory muscle. *Foot & ankle international*. 2003; 24(2):132-6.
  26. Deleu PA, Bevernage BD, Birch I, Maldague P, Gombault V, Leemrijse T. Anatomical characteristics of the flexor digitorum accessorius longus muscle and their relevance to tarsal tunnel syndrome: A systematic review. *Journal of the American Podiatric Medical Association*. 2015; 105(4):344-55.
  27. Duran-Stanton AM, Bui-Mansfield LT. Magnetic resonance diagnosis of tarsal tunnel syndrome due to flexor digitorum accessorius longus and peroneocalcaneus internus muscles. *Journal of computer assisted tomography*. 2010; 34(2):270-2.
  28. Ho VW, Peterfy C, Helms CA. Tarsal tunnel syndrome caused by strain of an anomalous muscle: an MRI-specific diagnosis. *Journal of computer assisted tomography*. 1993; 17(5):822-3.
  29. Sammarco GJ, Conti SF. Tarsal tunnel syndrome caused by an anomalous muscle. *The Journal of bone and joint surgery. American volume*. 1994; 76(9):1308-14.