

## Original Article

# Intravenous Drug Sedation for MRI in Children; a Randomized Controlled Trial

Mehrdad Mesbah Kiaei<sup>1\*</sup> , Arash Jafarih<sup>2</sup>, Abolghasem Yoosefi<sup>2</sup>

## Abstract

**Background:** Performing magnetic resonance imaging (MRI) in children is a matter of concern and needs adequate sedation because patients should be completely motionless to provide a good quality of imaging. The aim of this study was to compare the effects of Sodium thiopental and Propofol + Lidocaine to provide sedation in children undergoing brain MRI.

**Methods and materials:** This was a randomized, blinded trial including 250 patients aged 3 months to 13 years who were candidate for elective brain MRI. Participants were divided into two groups. Group 1 received Sodium thiopental and group 2 received Propofol + Lidocaine. Demographic characteristics were recorded. Unconsciousness time, scan time and discharge time were compared between the two groups. Data was analyzed using SPSS version 16 by Chi-square, ANOVA, Man-Whitney and T-test ( $p < 0.05$ ).

**Results:** Totally 250 patients were assigned randomly to two groups of Propofol + Lidocaine and Sodium thiopental, each including 125 patients. There was no meaningful difference regarding demographic factors of age, gender or ASA class between the two groups. There was no meaningful statistically difference regarding unconsciousness time ( $P$  value=0.655), scan time ( $P$  value=0.324) and discharge time ( $P$  value=0.436) between the Propofol + Lidocaine and Sodium thiopental group. Some minor adverse effects occurred in the Propofol + Lidocaine group. No major complication occurred.

**Conclusion:** Sodium thiopental was superior to Propofol + Lidocaine regarding lower adverse effects, lower costs, no need for an infusion pump and not lowering seizure threshold. It can be considered safe for sedation in children undergoing brain MRI, especially those with a history of seizure.

**Keywords:** Sodium thiopental; Propofol; Lidocaine; MRI; Sedation

**Please cite this article as:** Mesbah Kiaei M, Jafarih A, Yoosefi A. Intravenous Drug Sedation for Performing MRI in Children; a Randomized Controlled Trial. *J Cell Mol Anesth.* 2019;4(4):121-7.

1. Department of Anesthesiology and Pain Medicine, Hasheminejad Hospital, Iran University of Medical Sciences, Tehran, Iran
2. Department of Anesthesiology, Tehran University of Medical Sciences, Amir Alam Hospital Complex, Tehran, Iran

**Corresponding Author:** Mehrdad Mesbah Kiaei, Department of Anesthesiology and Pain Medicine, Hasheminejad Hospital, Iran University of Medical Sciences, Tehran, Iran.

**Email:** [mehrdadmehbahkiaei@gmail.com](mailto:mehrdadmehbahkiaei@gmail.com)

## Introduction

Magnetic resonance imaging (MRI) is recently

used widely as a safe, noninvasive and radiation-free procedure for patients either children or adults (1). The mechanism of device is to produce a magnetic field

140000 times of the Earth magnetic power, which triggers energy absorbing by the protons. The absorbed energy is then eliminated and produces the MRI image (2).

The procedure lasts for about 10 to 30 minutes in a quite noisy pipe, which could be annoying for children or those suffering claustrophobia. These patients become severely agitated during the procedure and move their body, which disrupts the MRI image and produces artifacts. Therefore, patients must be stiff during the procedure, which is rather difficult, especially in children (3). Therefore, sedation in children with anesthetics is necessary.

The magnetic field produced by the MRI machine absorbs all metal objects around it; hence, medical devices must have special characteristics to be used in the MRI room (4). Pulse oximetry, monitoring blood pressure, electrocardiography and any other device necessary for intubation should be available in the radiology room to provide sedation for patients. These devices should be compatible with the MRI machine (5). Magnetic resonance imaging is popular in children as well as adults as it provides better diagnosis of diseases, especially brain disorders such as seizure, malformations or tumors. The children who need imaging might also have some underlying problems like seizure or mental retardation, which make the imaging difficult.

Many agents are used for sedation outside the operation room in the recent years. Some trials exist assessing the effect of propofol outside the operating room to provide sedation in children for different imaging. Propofol has been used intravenously in patients undergoing MRI (6-11). Failure of sedation in children depends on different factors such as the drug efficacy, individual characteristics unwanted complications. Failure of sedation in children during imaging has been reported as 1% to 16% in different studies. Complications during sedations include hypoxia, aspiration, emesis, respiratory distress, need for intubation, decreased blood oxygenation and some others, which have been reported as null up to 10% in different investigations (9-12).

Another drug used for sedation is Sodium thiopental, also known as Sodium thiopental. It is a rapid-onset short-acting barbiturate used for general anesthesia or sedation. Sodium thiopental has been

used rectally for sedation in radiologic procedures widely (13, 14). However, limitation for titration and delayed recovery time have been reported by trans-rectal use (15, 16). Sodium thiopental is used widely in the operation room as intravenously to provide general anesthesia. However, there is limited experience about its use to provide sedation without intubation with spontaneous patient ventilation.

There are some reports of decreasing the threshold of seizure by propofol and lidocaine in specific doses in patients at risk of seizure (17-19). Therefore, there is an attempt to substitute them with safer medications. Hence, in the study we aimed to compare the effects of Propofol + Lidocaine and Sodium thiopental for sedation in children who undergo brain MRI in our center.

## Methods

This was a randomized, blinded trial study including patients aged 3 months to 13 years, who were candidate for elective brain MRI under sedation. The study was performed in a private hospital on all patients referred from 2015 to 2019 who fulfilled the inclusion and exclusion criteria. Most of participants were those who needed assessment for epilepsy diagnosis, treatment or follow-up. Exclusion criteria were as follows; American society of anesthesiology (ASA) class more than 3, porphyria disease, or history of drug sensitivity to the agents used in this trial, those who did not consent to participate in the study, those with major organ failures who might not tolerate sedation, those with known history of respiratory failure or any disease that might threat children if mechanical ventilation was necessary. Also sensitivity to egg was another exclusion criterion.

All patients in the study period who fulfilled the inclusion and exclusion criteria entered the study. A written informed consent was obtained from children guardians as well after complete explanation of the study protocol.

**Sedation protocol:** patients were randomly allocated to two groups using random numbers. Group 1 received Sodium thiopental and group 2 received Propofol + Lidocaine. Group 1, Sodium thiopental was first administered 1-3 mg/kg and patient response was then assessed. A repeated dose was also injected if needed. A 5-6 seconds apnea was occurred usually.

The concentration of Sodium thiopental was 12.5mg/mL. In children, more than 20 kg, 1mg midazolam was injected 5 minutes before placing patients in MRI machine. If patient moved during the procedure or if the imaging lasted unusually, additional 1-2 mg/kg Sodium thiopental was injected. Imaging lasted 10-20 minutes commonly and patients did not usually need maintenance doses during the procedure.

In Propofol + Lidocaine group, children received an initial dose of 0.5-1 mg/kg mixed with lidocaine to alleviate patient pain due to injection. Propofol was diluted to one-third by distilled water. In addition, 0.5 mg lidocaine was added per each milliliter of propofol. The dose was repeated every 60 seconds until eyelid reflex was absent. Additional doses of 0.25 mg/kg might be needed to reach the desirable level of sedation. If participants moved during the procedure, bolus doses of Propofol (0.5 mg/kg) were given and infusion rate was gradually augmented maximally up to 15 mg/kg per hour. Each milliliters of Lidocaine contained 1mg Lidocaine. Each Milliliters of Propofol contained 0.5 mg of Propofol. An infusion pump was needed for Propofol while it was not needed for Sodium thiopental group.

During the sedation and all over the procedure patients were closely monitored by heart rate and pulse oximetry. In addition, blood pressure was measured three times before the procedure, after the procedure and before discharge. Respiratory rate was counted 4-5 times during the procedure. The level of sedation was accepted if the imaging was performed with a good quality and without participant movement. The procedure was failed if the patient did not reach a desirable level of sedation or major complications such as hypoxia, bradycardia, apnea or hypotension occurred. We had no infusion pump compatible with MRI machine, therefore, the infusion pump was kept out of the room and an infusion extension line was used.

An expert anesthesiologist in the field of pediatrics and an anesthesiology technician performed all the stages mentioned above and provided care for participants to avoid any complication such as decreased O2Sat, airway problems, etc. All devices of mechanical ventilation were also present if needed. After the end of procedure, children were discharged if complete consciousness was returned, O2Sat was

desirable, blood pressure was acceptable and no complication present.

**Data collection:** a questionnaire was filled with the help of participants' parents including age, gender, and medical history, reason for admission, presence of neurological deficit, drug history and reason for imaging. Some other variables were recorded including the time elapsed from the first injected dose of sedative drug to complete unconsciousness to perform the imaging as unconsciousness time (UT). In addition, the scan time (ST) was the time between placing the participant on the MRI machine table until the end of procedure. The time between the end of imaging and participant discharge was also recorded as discharge time (DT).

**Data analysis:** SPSS software version 16 (IBM Chicago, The USA) was used to analyze data. A Kolmogorov-Smirnov test was used to check normality of data. Descriptive and analytics statistics were used. Chi-2, Student T-test, Man Whitney and ANOVA used where appropriate. A p value less than 0.05 was considered as statistically significant difference.

## Results

Totally 250 patients were assigned randomly to two groups of Propofol + Lidocaine and Sodium thiopental. The study flow chart presented in flowchart 1.

We used a random table of numbers to allocate patients in the two groups. The efficacy of randomization was assessed by comparing the demographic factors between the two groups. There was no meaningful difference regarding demographic factors of age, gender, ASA class between the two groups as shown in Table 1.

Mean used dosage of Sodium thiopental was 4-5 mg/kg and for Propofol 1-2 mg/kg. No major adverse event occurred in our patients and all the participants completed the study protocol. There was no meaningful statistically difference regarding unconsciousness time between the Propofol + Lidocaine compared to the Sodium thiopental group (P value=0.655). There was no meaningful statistically difference regarding scan time between the Propofol + Lidocaine compared to the Sodium thiopental group (P value=0.324). There was no meaningful statistically

**Table 1:** Demographic Characteristics of the Study Population.

	Propofol group N=125	Sodium thiopental group N=125	P value
Age, Mean $\pm$ SD, Year	6.3 $\pm$ 2.6	6.4 $\pm$ 1.7	0.566
Gender, Male	70 (125)	68 (125)	0.444
ASA class 1	89	88	0.711
ASA class 2	26	28	0.536
ASA class 3	10	9	0.632
Number of patients with cognitive disorders	7	5	0.433

**Table 2:** Duration of Sedation in the Both Groups.

	Propofol group	Sodium thiopental group	P value
Unconsciousness time <sup>1</sup> , seconds	17 $\pm$ 3.4	19 $\pm$ 2.2	0.655
Scan time <sup>2</sup> , min	19.34 $\pm$ 4.5	20.15 $\pm$ 5.21	0.324
Discharge time <sup>3</sup> , min	28.45 $\pm$ 5.2	30.43 $\pm$ 4.6	0.436

1. The time between the first injections of medications till readiness to put the patient on the MRI machine
2. Total time of imaging in the machine
3. The time between the end of imaging and readiness for discharge

difference regarding discharge time between the Propofol + Lidocaine compared to the Sodium thiopental group (P value=0.436). Unconsciousness time, scan time and discharge time of participants in the two groups are shown in Table 2.

Twenty-one patients (16.8%) in the Propofol+ Lidocaine group had some minor complications during the procedure. Sixteen patients (12.8%) experienced temporary decrease in blood pressure and 5 (4%) experienced respiratory depression. Chin tilt and jaw thrust maneuvers together with oxygenation was enough to reverse respiratory depression. Fortunately, no patient needed intubation. In addition, those who experienced decreased blood pressure were managed with serum therapy and no patient excluded from the analyses.

In the Sodium thiopental group no major adverse events were found, however, some participants experienced minor complications as nausea, dizziness,

tinnitus, headache, transient myoclonus, which were managed with anti-emetics.

## Discussion

Our results demonstrated no significant difference regarding unconsciousness time, scan time and discharge time between the two groups and both sedation protocol provided the same efficacy to perform the imaging. However, Propofol + Lidocaine needed an infusion pump, while Sodium thiopental did not. However, seizure like phenomenon (SLP) has been reported as one of the complications of Propofol in the literature (20). In a systematic review by Walder et al, it was concluded that SLP may occur in patients receiving Propofol with or without a history of epilepsy. They suggested that a change in cerebral

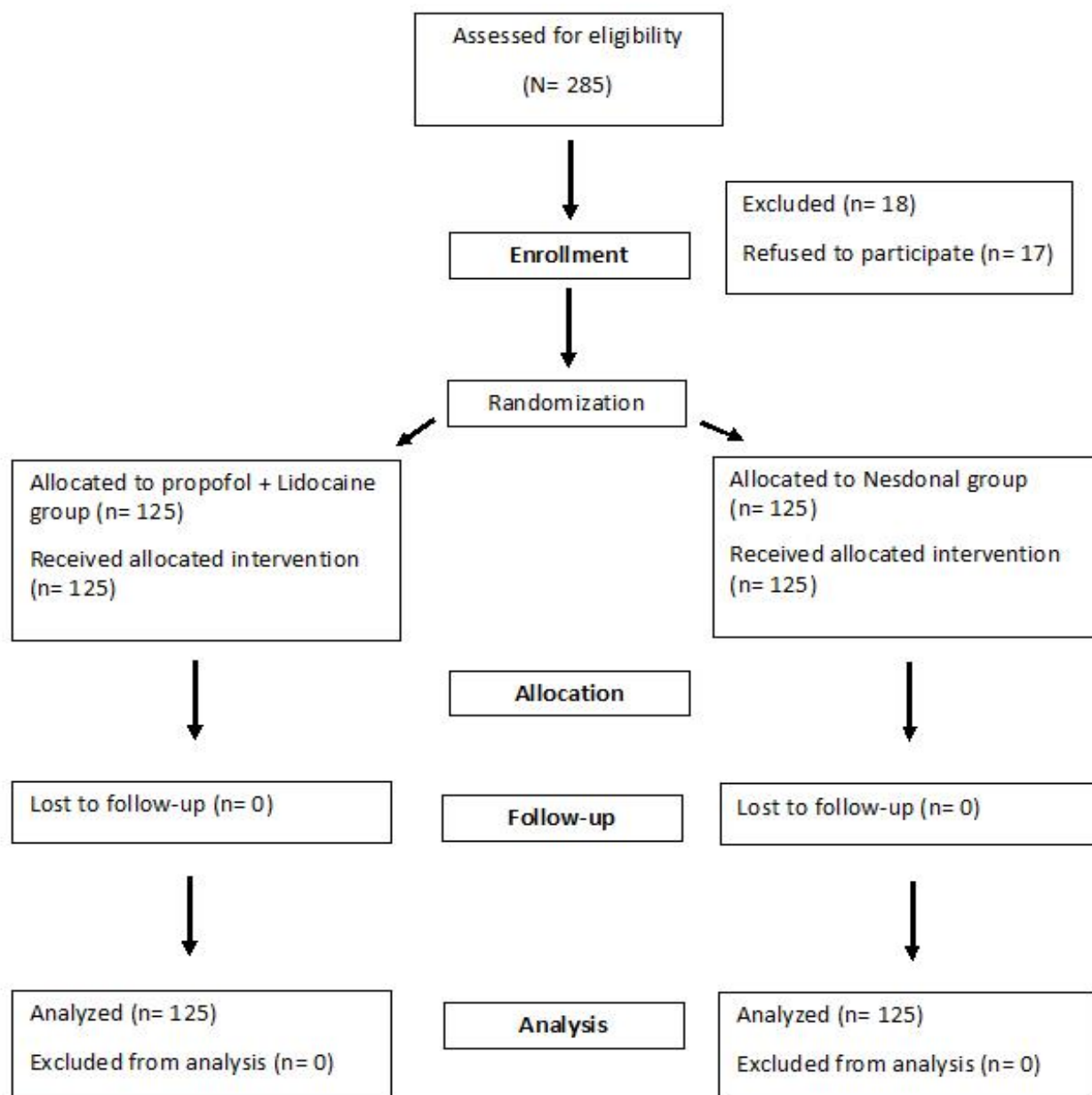


Figure 1. The Study Flowchart.

concentration of propofol may be causal in such a phenomenon (20). It is also suggested that Propofol might induce temporal lobe epilepsy, however, there are still few evidences to support this (21, 22). As our study included some patients who had a history of epilepsy, Propofol should be administered with caution.

However, in another study, it was shown that propofol possesses significant seizure-shortening characteristics and does not elevate seizure threshold

in patients with schizophrenia who underwent electroconvulsive therapy compared to Etomidate (23). In a case report and review of literature in 2019 by Lu et al, A 16-year-old Chinese girl known to have benign epilepsy with centrotemporal spikes underwent general anesthesia during a plastic surgery procedure and developed refractory status epilepticus induced by propofol. They suggested being aware of propofol for patients with a history of seizure as well (24).

In another systematic review by Sutherland,

they mentioned that despite anticonvulsant activity of propofol, it might produce an involuntary movement disorder, in certain patients. They mentioned that while propofol is proven as a very good medication, convulsive phenomena create a degree of concern about its use in some patients, especially in those with a history of seizures (17).

Moreover, lidocaine is administered concurrently with propofol to reduce its pain. There are some reports showing that lidocaine might also induce seizure in some cases. In a study by DeToledo et al., concentration-dependent effect of lidocaine on seizures has been proposed. They reported that lidocaine at concentrations above 5 µg/mL might provoke seizures. However, lower doses could suppress clinical and electroencephalographic manifestations of seizures (19). Therefore, combining propofol and lidocaine might not be suggested in children with a history of seizures. Despite the fact, in our study, we had no report of provoking seizures in the Propofol + Lidocaine group.

On the other hand, Sodium thiopental has been used for sedation during imaging in many studies. Yunus O. Atalay et al. studied the effects of intravenous thiopental for sedation during magnetic resonance imaging in pediatric patients. A total of 300 (American Society of Anesthesiology I-II status) pediatric patients received IV thiopental for sedation during MRI. They found that IV thiopental is an effective, safe, and inexpensive medication for sedation in children undergoing MRI (25).

In another investigation, propofol, thiopentone and ketamine were compared for pediatric MRI sedation. This study concluded that thiopentone plus ketamine combination resulted in lower repetition rate while propofol plus ketamine offers shorter recovery period. However, respiratory distress was reported to be almost similar (26). It is consistent with our results that patients in the Sodium thiopental group did not need repetitive doses of medication; however, those in the Propofol + lidocaine needed an infusion pump for sedation maintenance. Due to lower half-life of Propofol, patients were ready for discharge earlier; despite the fact, there was no meaningful difference between the two groups regarding discharge time in our study.

In another investigation, sedative effects of

midazolam-ketamine combination and thiopental in pediatric patients undergoing magnetic resonance imaging were assessed and it was concluded that thiopental was a safe alternative to Midazolam plus ketamine combination for sedation during MRI. High image quality, anesthesia induction time and short recovery time make Sodium thiopental as a safe and cost-benefit medication to provide adequate sedation in children undergoing imaging (27). This is also in line with our study showing the superiority of Sodium thiopental due to its very few adverse effects and low costs.

In our study, there was no meaningful statistically significant difference regarding discharge time and unconsciousness time between Propofol and Sodium thiopental. Besides, the total cost of a mixture of lidocaine and propofol was much higher than Sodium thiopental. It also suggests the superiority of Sodium thiopental to propofol.

There were some limitations in our investigation. Firstly, the physician who administered propofol or Sodium thiopental was not blinded to the study groups, which might affect assessing the results, i.e. they might have recorded complications related to each group with bias, however, it was tried to be avoided. Second, we only compared Propofol and Sodium thiopental and other medications in other studies were not assessed. It is suggested to perform larger studies comparing other medications as well.

## Conclusion

Sodium thiopental was superior to Propofol + Lidocaine regarding lower adverse effects, lower costs, and no need for an infusion pump and not lowering seizure threshold. Therefore, it can be considered for sedation in children undergoing brain MRI, especially those with a history of seizure.

## Acknowledgment

We would like to thank the personnel of MRI division who helped us to perform the study. In addition, we would like to thank the anesthesiology

technician who helped for sedation. Without whom performing the investigation was not possible.

## Conflicts of Interest

The authors declare that they have no conflict of interest.

## References

- Kitt E, Friderici J, Kleppel R, Canarie M. Procedural sedation for MRI in children with ADHD. *Paediatr Anaesth*. 2015;25(10):1026-32.
- Schulte-Uentrop L, Goepfert MS. Anaesthesia or sedation for MRI in children. *Curr Opin Anaesthesiol*. 2010;23(4):513-7.
- Bharti B, Malhi P, Khandelwal N. MRI Customized Play Therapy in Children Reduces the Need for Sedation--A Randomized Controlled Trial. *Indian J Pediatr*. 2016;83(3):209-13.
- Boriosi JP, Eickhoff JC, Klein KB, Hollman GA. A retrospective comparison of propofol alone to propofol in combination with dexmedetomidine for pediatric 3T MRI sedation. *Paediatr Anaesth*. 2017;27(1):52-59.
- Rudder BS, Easley SJ, Robinson AL, Noel-MacDonnell JR, Nielsen DB. Effects of an MRI Try Without program on patient access. *Pediatr Radiol*. 2019;49(13):1712-1717.
- Powers KS, Nazarian EB, Tapyrik SA, Kohli SM, Yin H, van der Jagt EW, Sullivan JS, Rubenstein JS. Bispectral index as a guide for titration of propofol during procedural sedation among children. *Pediatrics*. 2005;115(6):1666-74.
- Kang R, Shin YH, Gil NS, Oh YN, Hahm TS, Jeong JS. A retrospective comparison of propofol to dexmedetomidine for pediatric magnetic resonance imaging sedation in patients with mucopolysaccharidosis type II. *Paediatr Anaesth*. 2018;28(12):1116-22.
- Fang H, Yang L, Wang X, Zhu H. Clinical efficacy of dexmedetomidine versus propofol in children undergoing magnetic resonance imaging: a meta-analysis. *Int J Clin Exp Med*. 2015;8(8):11881-9. eCollection 2015.
- Nagoshi M, Reddy S, Bell M, Cresencia A, Margolis R, Wetzel R, Ross P. Low-dose dexmedetomidine as an adjuvant to propofol infusion for children in MRI: A double-cohort study. *Paediatr Anaesth*. 2018;28(7):639-46.
- Kamat PP, Karaga MK, Wisniewski BL, McCracken CE, Simon HK, Sidhu R, Grunwell JR. Outpatient Procedural Sedation of Patients with Autism Spectrum Disorders for Magnetic Resonance Imaging of the Brain Using Propofol. *J Child Neurol*. 2018;33(5):313-9.
- Schmitz A, Weiss M, Kellenberger C, O'Gorman Tuura R, Klaghofer R, Scheer I, Makki M, Sabandal C, Buehler PK. Sedation for magnetic resonance imaging using propofol with or without ketamine at induction in pediatrics-A prospective randomized double-blinded study. *Paediatr Anaesth*. 2018;28(3):264-74.
- Kang R, Shin YH, Gil NS, Kim KY, Yeo H, Jeong JS. A comparison of the use of propofol alone and propofol with midazolam for pediatric magnetic resonance imaging sedation - a retrospective cohort study. *BMC Anesthesiol*. 2017;17(1):138.
- Ustun YB, Atalay YO, Koksall E, Kaya C, Ozkan F, Sener EB, Polat AV. Thiopental versus ketofol in paediatric sedation for magnetic resonance imaging: A randomized trial. *J Pak Med Assoc*. 2017;67(2):247-51.
- Jahangirifard A, Salajegheh S, Arab S, Mirtajani SB, Farzanegan B. Thiamine could decrease Lactate and Creatinine level after Coronary Artery Bypass Surgery in Patients with Mild Systolic Dysfunction. *J Cell Mol Anesth*. 2018;3(4):136-42.
- Alp H, Orbak Z, Güler I, Altinkaynak S. Efficacy and safety of rectal thiopental, intramuscular cocktail and rectal midazolam for sedation in children undergoing neuroimaging. *Pediatr Int*. 2002;44(6):628-34.
- Salvo I, Cucchi C, Camporesi A, Borghi B, Grasso F, Silvani P. [Sedation with magnetic resonance imaging in pediatric patients]. *Minerva Anesthesiol*. 2002;68(5):414-9.
- Sutherland MJ, Burt P. Propofol and seizures. *Anaesth Intensive Care*. 1994;22(6):733-7.
- Ayas M, Işık B. Does Low Dose Lidocaine Cause Convulsions? *Turk J Anaesthesiol Reanim*. 2014;42(2):106-8.
- DeToledo JC. Lidocaine and seizures. *Ther Drug Monit*. 2000;22(3):320-2.
- Walder B, Tramèr MR, Seeck M. Seizure-like phenomena and propofol: a systematic review. *Neurology*. 2002;58(9):1327-32.
- Szantoch M, Bala A, Rysz A, Żyłkowski J, Marchel A. Experience of adverse events with cerebral propofol testing in patients with drug resistant epilepsy. *Sci Rep*. 2019;9(1):592.
- Voss LJ, Andersson L, Jadelind A. The general anesthetic propofol induces ictal-like seizure activity in hippocampal mouse brain slices. *Springerplus*. 2015; 4:816
- Gábor G, Judit T, Zsolt I. Comparison of propofol and etomidate regarding impact on seizure threshold during electroconvulsive therapy in patients with schizophrenia. *Neuropsychopharmacol Hung*. 2007;9(3):125-30.
- Lu L, Xiong W, Zhang Y, Xiao Y, Zhou D. Propofol-induced refractory status epilepticus at remission age in benign epilepsy with centrotemporal spikes: A case report and literature review. *Medicine (Baltimore)*. 2019;98(27): e16257.
- Atalay YO, Leman T, Tobias JD. Efficacy and safety of intravenous thiopental for sedation during magnetic resonance imaging in pediatric patients: A retrospective analysis. *Saudi J Anaesth*. 2017;11(2):185-9.
- Tobias JD, Leder M. Procedural sedation: A review of sedative agents, monitoring, and management of complications. *Saudi J Anaesth*. 2011;5(4):395-410.
- Rosati A, L'Erario M, Ilvento L, Cecchi C, Pisano T, Mirabile L, Guerrini R. Efficacy and safety of ketamine in refractory status epilepticus in children. *Neurology*. 2012 11;79(24):2355-8.