

## Case report

## Acute and Critical Care for Rabies Bitten Patients and the Different Outcomes in a Family: A Post Exposure Prophylaxis (PEP) Failure Report

Sara Nouri Basirat<sup>1</sup>, Rouzbeh Bashar<sup>2</sup>, Behzad Pourhossein<sup>3</sup>, Nasim Niknam<sup>4</sup>, Mojtaba Sanji Rafsanjani<sup>5</sup>, Mohammad Reza Shirzadi<sup>6</sup>, Farzaneh Sheikholeslami<sup>2</sup>, Reza Farzad<sup>2</sup>, Maryam Fazeli<sup>2\*</sup> 

### Abstract

Rabies is a zoonotic viral disease that spread via infected animal saliva. Rabies virus belongs to Lyssavirus genus (Rhabdoviridae family) and the disease is endemic in Iran. The disease causes a fatal encephalomyelitis by infecting the nervous system. Dogs are the most common source of human rabies cases. In this presentation, we had a 58-year-old man who had a dog bitten history on his face and hands with his other two family members with the same dog at the same time. They received post-exposure prophylaxis (PEP) as soon as possible (from day 0). Eighteen days after bitten the man hospitalized and died of rabies three days after hospitalization. Other two relatives were healthy without any rabies symptom. The man was an Iranian veteran with residual body insults during the attacks of chemical warfare from the combat front. Obtained data in this study suggested that the direct inoculation of the virus to the nerve and immune system inability in virus clearing system were possible etiologies of PEP failure in the reported case.

**Keywords:** Rabies Virus, Immunoglobulin, Pre-Exposure Prophylaxis (PrEP), Immunosuppression

**Please cite this article as:** Nouri Basirat S, Bashar R, Pourhossein B, Niknam N, Sanji Rafsanjani M, Shirzadi MR, Sheikholeslami F, Farzad R, Fazeli M. Acute and Critical Care for Rabies Bitten Patients and the Different Outcomes in a Family: A Post Exposure Prophylaxis (PEP) Failure Report. J Cell Mol Anesth. 2019;4(4):148-51.

### Introduction

Rabies is a zoonotic fatal Lyssavirus-induced disease that causes acute encephalitis in humans and other mammals (1). Following the introduction of the virus as a result of a bite, the virus enters the nerve and travels towards the central nervous system (CNS). The clinical course of the disease is divided into five

phases: (1) the incubation period, (2) the prodromal phase, (3) an acute neurologic phase, (4) coma, and (5) death (2).

The endemic canine form of rabies kills approximately 59,000 humans per year, which mainly occurs in rural areas of Asia and Africa (3). Infection with the virus must be considered and treated as soon

1. Regenerative Medicine and Biomedical Innovation Lab, Pasteur Institute of Iran, Tehran, Iran
2. Virology Department, Pasteur Institute of Iran, Tehran, Iran
3. Department of Virology, School of Public Health, Tehran University of Medical Sciences, Tehran, Iran
4. Department of Internal Medicine, School of Medicine, Alborz University of Medical Science, Shahid Rajaei Heart Center, Karaj, Alborz, Iran
5. Emergency Department, Ali Ebn Abitaleb Hospital, Faculty of Medicine, Rafsanjan University of Medical Science, Rafsanjan, Kerman, Iran
6. Zoonosis Control Department, Center for Communicable Diseases Control, Ministry of Health and Medical Education, Tehran, Iran

**Corresponding Author:**

Maryam Fazeli, the National Center for Reference and Research on Rabies, Virology Department, Pasteur Institute of Iran, 12 Farvardin St., Tehran, Iran. Tel: +98-21-66403496.

**Email:** m\_fazeli@pasteur.ac.ir

as possible (4). The post-exposure prophylaxis (PEP) measurement consists of wound cleansing with administration of rabies immunoglobulin and the rabies vaccine (4). Failure of the rabies PEP will usually result in the disease progression and death. In some cases, despite this measurement, PEP failure occurs. The purpose of this report was to present the different outcomes in three patients bitten by the same stray dog despite the same vaccine treatment as a PEP failure report.

## Case Report

A 58-year-old man was admitted to one of an academic hospital in Rafsanjan city (Kerman province, South of Iran) in 2018.02.04 at 22:05 night with severe frontal and right temporal headache, dizziness, vertigo, dyspnea, fever, itching, and a one-day history of difficulty in swallowing. On arrival, the patient appeared anxious, alert and co-operative. His pulse rate was 102/min (tachycardia), blood pressure 90/60 mmHg; he was tachypneic with a respiratory rate of 28/min. His oxygen saturation (SpO<sub>2</sub>) was 47% on the air room, improved to 90% on continuous positive airway pressure (CPAP) ventilation.

After treating dehydration, his blood pressure reached 100/70 mmHg. His hemoglobin was 12.1 g/dl, and platelet counts 160 ×1000/cumm. Arterial blood gases were suggestive of metabolic respiratory alkalosis. Other blood parameters and chest X-rays were normal. Initial electrocardiography (EKG) was normal.

The patient's past medical history was significant for psychological problems because he was a chemical Iranian veteran (Iran-Iraq war). He used bronchodilator spray and inhaled corticosteroids due to COPD (chronic obstructive pulmonary disease) for almost 30 years.

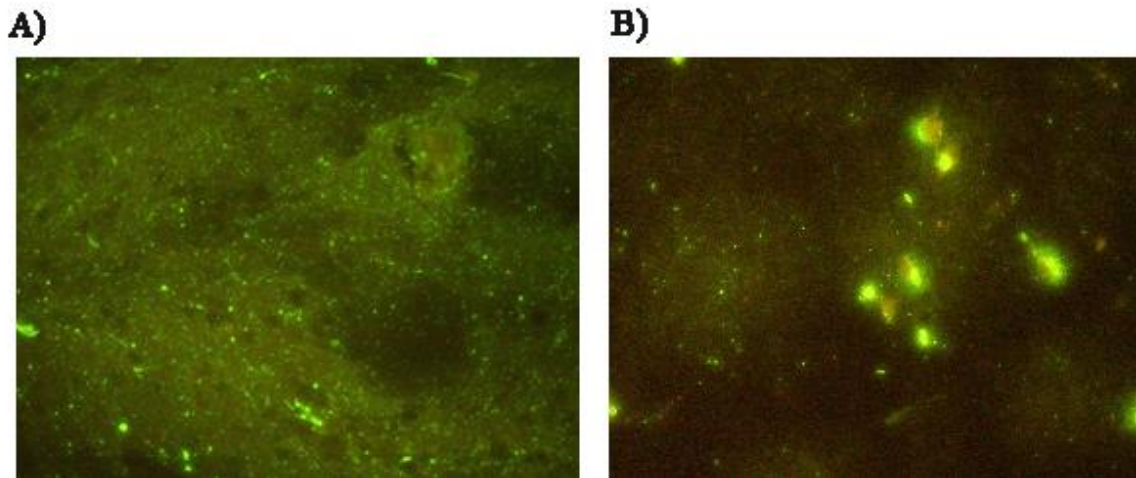
There was a history of a dog-bite 18 days previously in 2018.15.03 on his head and face (Category III). At the same time, the dog had also bitten his two family members; a 5-year-old girl had bitten on her face and head (Category III) and a 33-year-old man had bites on legs (Category III) at the same time. The dog had been trapped and killed at the time of the bite. The dog brain sample had been sent to the laboratory of the National Center for Reference and

Research on Rabies, Pasteur Institute of Iran. Two days after, the laboratory confirmed the presence of rabies virus antigen using FAT (Figure 1A), the method recommended by the WHO (5).

The patient relatives confirmed that all victims received a full course of PEP consist of local wound region care, administration of human RIG (Berirab® P), (20 IU/kg body weight), infiltrated at site of exposure immediately after the attack (day 0) and intramuscular rabies vaccination (Verorab®, Sanofi Pasteur Ltd. France). According to their vaccination card, they completed a full course of standard vaccines (a four-dose vaccination regimen on days 0, 3, 7, 14).

On the second day of hospitalization, his body temperature gradually rose from 36.5°C on admission to 38°C, and he became more unsteady. He received a diagnosis of encephalitis and was treated with Cefepime, Vancomycin, Acyclovir, and Ampicillin. IV Haloperidol was started to him, in addition, Biperiden and Diazepam for his agitation. Laboratory tests included a complete blood count was done. Abnormal test results included white blood cells (WBCs) count of 9000 cells/μl with 78% neutrophils. Infectious disease specialist was consulted because of neutrophil leukocytosis.

During the period, he developed acute respiratory distress, hypotension, high fever, nausea, vomiting. Eventually, he developed a mild coma, cardiac failure, and respiratory arrest; Cardiopulmonary resuscitation (CPR) was performed successfully and consequently, he got intubated and mechanically ventilated and was transferred to an intensive care unit (ICU). Dopamine drip was started to him at the rate of 5 mcg/kg/min and gradually increase to 20 mcg/kg/min for stabilizing blood pressure. He was treated with supportive treatment, including intravenous rehydration and maintenance of adequate electrolyte balance. Within one hour, he had progressively worsening hemodynamic parameters and cardiac condition and went into asystolic cardiac arrest. CPR was again initiated and Atropine and Epinephrine were given to him. But, he lost cardiac output 30 min later and progressed to true asystole. Despite further resuscitation, there was no improvement and ultimately CPR was stopped and he died after heart failure 21 days since having been



**Figure 1.** (A) FAT result of the dog's brain sample that bites our case study; (B) FAT result of the case study brain sample. The apple green spots indicate antigens reactions with FITC (Fluorescein Isothiocyanate)-conjugated rabies antibodies in this method.

bitten. An autopsy was performed and the patient brain sample sent to the laboratory of the National Center for Reference and Research on Rabies for diagnosis of rabies virus. The laboratory detected the virus antigen by FAT (Figure 1B). The follow-up showed that two other victims have no symptoms or illness after receiving the rabies PEP.

## Discussion

In this case, despite the application of the PEP measurements, the patient bitten on his face and head succumbed to encephalitis of rabies. Histopathologic and clinical findings confirmed this diagnosis.

The incubation period for the disease is typically 2–3 months, but, it may vary from one week to one year depends on factors such as the location of virus entry and viral load (6). The incubation period was less than 30 days (18 days) in the patient-reported.

Based on our knowledge, the virus is highly sensitive to the active or passive immune response of the host before entering the nerve ending adjacent (7). Therefore, rabies disease is preventable using immediate effective measures including wound washing, wound treatment with local RIG infiltration and vaccine therapy. Though, if the disease left untreated and clinical signs to develop, it is almost 100% fatal (8). However, in our case, it seems that there are some exceptions based on the patient's health condition.

The patient is an Iranian chemical veteran by sulfur mustard gas (MS). MS veterans suffer from the long-term effect of mustard gas, which includes cutaneous, respiratory, cardiovascular, neuromuscular, ocular complications and pulmonary complications resulting in disability in affected patients (9). Respiratory physiotherapy, inhaled bronchodilators, inhaled and systemic steroids, as well as an antibiotic treatment against respiratory infections, are the principles of treatment for chronic pulmonary complications (10). In addition, a study (2002) suggests that mustard gas can lead to impairment of the cellular and humoral immune functions (11). In this case report, failure to increase the WBC count (9000 cells/ $\mu$ l) relative to the normal range of these cells (>11000 cells/ $\mu$ l) can also be a sign of immune deficiency.

In this study, the history of the case reports long term use of corticosteroids. Some studies showed that corticosteroids, other immunosuppression drugs, antimalarial drugs and diseases that cause immunosuppression interferes with active immunization after vaccination (12, 13). Pre-exposure prophylaxis (PrEP) is recommended to prescribe for immunocompromised patients, especially knowing that the immune response may not be adequate after PEP vaccination.

A study suggests that one of the causes of the PEP failure may be wounds in richly innervated areas (such as the face and hands) due to the possibility of

the direct virus inoculation into neurotransmitter terminals (3). In our report, it seems that the virus enters directly to the nervous tissue based on the location and deep of the bite and as a result, the insufficient immune response was generated and therefore, he died.

## Conclusion

The case reported in this study was a Ms. Veteran that had several wounds in his head and face and in spite of medical treatment, died from the rabies disease. It is suggested to perform PrEP measurements for immunocompromised patients in endemic areas and their antibodies levels after that should be check. If the level of the antibody does not increase sufficiently after the vaccination, the subject should be reported to the Center for Diseases Control (CDC). In addition, the current therapeutic knowledge of the PEP may not provide sufficient confidence to public health experts. Therefore, establishing a collaborative international rabies registry, with special emphasis on these patients, could provide evidence that could help decide on the appropriate vaccination protocol.

## Acknowledgment

We would like to thank the Zoonoses Control Department, Center for Communicable Diseases Control, Ministry of Health and Medical Education, Tehran, Iran for their supports and all colleagues in the National center for reference and research on rabies, Pasteur Institute of Iran involved in this study.

## Conflicts of Interest

The authors declare that there are no conflicts of interest.

## References

1. Warrell MJ, Warrell DA. Rabies and other lyssavirus diseases. *Lancet*. 2004;363(9413):959-69.
2. Hemachudha T, Laothamatas J, Rupprecht CE. Human rabies: a disease of complex neuropathogenetic mechanisms and diagnostic challenges. *Lancet Neurology*. 2002;1(2):101-9.
3. Organization WH. WHO expert consultation on rabies: third report: World Health Organization; 2018.
4. Shantavasinkul P, Wilde H. Postexposure prophylaxis for rabies in resource-limited/poor countries. *Adv Virus Res*. 2011;79:291-307.
5. Bourhy H, Rollin PE, Vincent J, Sureau P. Comparative field evaluation of the fluorescent-antibody test, virus isolation from tissue culture, and enzyme immunodiagnosis for rapid laboratory diagnosis of rabies. *J Clin Microbiol*. 1989;27(3):519-23.
6. Fisher CR, Streicker DG, Schnell MJ. The spread and evolution of rabies virus: conquering new frontiers: *Nat Rev Microbiol*. 2018;16(4):241-255.
7. Koyuncu OO, Hogue IB, Enquist LW. Virus infections in the nervous system. *Cell Host Microbe*. 2013;13(4):379-93.
8. Cleaveland S, Hampson K. Rabies elimination research: juxtaposing optimism, pragmatism and realism. *Proc Biol Sci*. 2017;284(1869). pii: 20171880.
9. Razavi SM, Ghanei M, Salamati P, Safiabadi M. Long-term effects of mustard gas on respiratory system of Iranian veterans after Iraq-Iran war: a review. *Chin J Traumatol*. 2013;16(3):163-8.
10. Flume PA, Mogayzel PJ Jr, Robinson KA, Goss CH, Rosenblatt RL, Kuhn RJ, Marshall BC; Clinical Practice Guidelines for Pulmonary Therapies Committee. Cystic fibrosis pulmonary guidelines: treatment of pulmonary exacerbations. *Am J Respir Crit Care Med*. 2009;180(9):802-8.
11. Ghotbi L, Hassan Z. The immunostatus of natural killer cells in people exposed to sulfur mustard. *Int Immunopharmacol*. 2002;2(7):981-5.
12. Enright JB, Goggin JE, Frye FL, Franti CE, Behymer DE. Effects of corticosteroids on rabies virus infections in various animal species. *J Am Vet Med Assoc*. 1970;156(6):765-9.
13. Satyanarayanasetty D, Pawar K, Nadig P, Haran A. Multiple Adverse Effects of Systemic Corticosteroids: A Case Report. *J Clin Diagn Res*. 2015;9(5):FD01-2.