


Case report

Twin Pregnant Woman with COVID-19: a Case Report

Seyedpouzhia Shojaei¹, Mehran Kouчек¹, Mir Mohammad Miri¹, Sara Salarian¹, Mohammad Sistanizad¹, Shideh Ariana², Maryamsadat Hosseini², Simindokht Shoaee³, Mehrdad Haghighi³, Mahmood Nabavi³, Mohammad Farahbakhsh³, Padideh Ansari⁴, Mahsaalsadat Mirhadi², Fahimeh Hadavand^{3*} 

Abstract

A pregnant woman (Gravida 2, Abortion 1, twin pregnancy with microinjection, Gestational Age: 23 weeks and 3 days) was referred to a tertiary referral hospital with complaints of fever, dry cough and dyspnea. She was admitted with a diagnosis of COVID-19. During her hospitalization, O₂ saturation progressively declined, which required acute respiratory care and support leading to intubation and mechanical ventilation. Gradual recovery occurred through treatment processes and finally the patient was extubated. However, there was another episode of respiratory failure leading to reintubation after 5 days. Meanwhile, serum liver enzymes increased significantly and led to intrauterine death of both fetus followed by a critical decline in cardiac output to less than 10% and cardiac arrest followed by unsuccessful resuscitation within hours.

Keywords: COVID-19, Twin pregnancy, Coronavirus, SARS-COV-2, 2019 novel coronavirus, Pregnancy, IUFD, Coronavirus disease (COVID-19), Myocarditis

Please cite this article as: Shojaei S, Kouчек M, Miri MM, Salarian S, Sistanizad M, Ariana S, et al. Twin pregnant woman with COVID-19: a case report. *J Cell Mol Anesth.* 2020;5(1):43-6.

Introduction

The outbreaks of COVID-19 that emerged late 2019 in China, resulted in a widespread ongoing transmission worldwide including Iran (1). Novel Coronavirus, rapidly develops into alveolar injury and progressive respiratory failure (2, 3).

In the meantime, the health of pregnant women has become particularly important because maternal organs undergo many changes due to the effects of pregnancy. In china, all studies of COVID-19 pregnant women included single fetuses and no maternal deaths were reported by the virus (4, 5). A 38 years old woman with twin pregnancy was admitted to Imam Hossein

1. Anesthesiology and Critical Care Medicine Department, Imam Hossein (A.S.) Medical and Educational Center, Shahid Beheshti University of Medical Sciences, Tehran, Iran
2. Department of Obstetrics and Gynecology, Imam Hossein (A.S.) Medical and Educational Center, Shahid Beheshti University of Medical Sciences, Tehran, Iran
3. Department of Infectious Disease, Imam Hossein (A.S.) Medical and Educational Center, Shahid Beheshti University of Medical Sciences, Tehran, Iran
4. Anesthesiology Research Center, Shahid Beheshti University of Medical Sciences, Tehran, Iran

Corresponding Author: Fahimeh Hadavand, MD, Assistant Professor, Department of Infectious Disease, Imam Hossein (A.S.) Medical and Educational Center, Madani Ave, Tehran, Iran
Tel/Fax: 0098-21-7755 8001
Email:
Fahimehadavand140@gmail.com

(A.S.) hospital with complaints of fever, dry cough and dyspnea who were later diagnosed with COVID-19. This study indicates that multiple pregnancy mothers suffering from COVID-19 deemed to be poor prognosis cases. The study proposal was assessed and approved by Research Ethics Committee, Shahid Beheshti University of Medical Sciences, Tehran, Iran; coded: IR.SBMU.RETECH.REC.1399.021.

Case Report

A pregnant woman (Gravida 2, Abortion 1, twin pregnancy with microinjection, with Gestational Age of 23 weeks plus 3 days) was referred to Imam Hossein

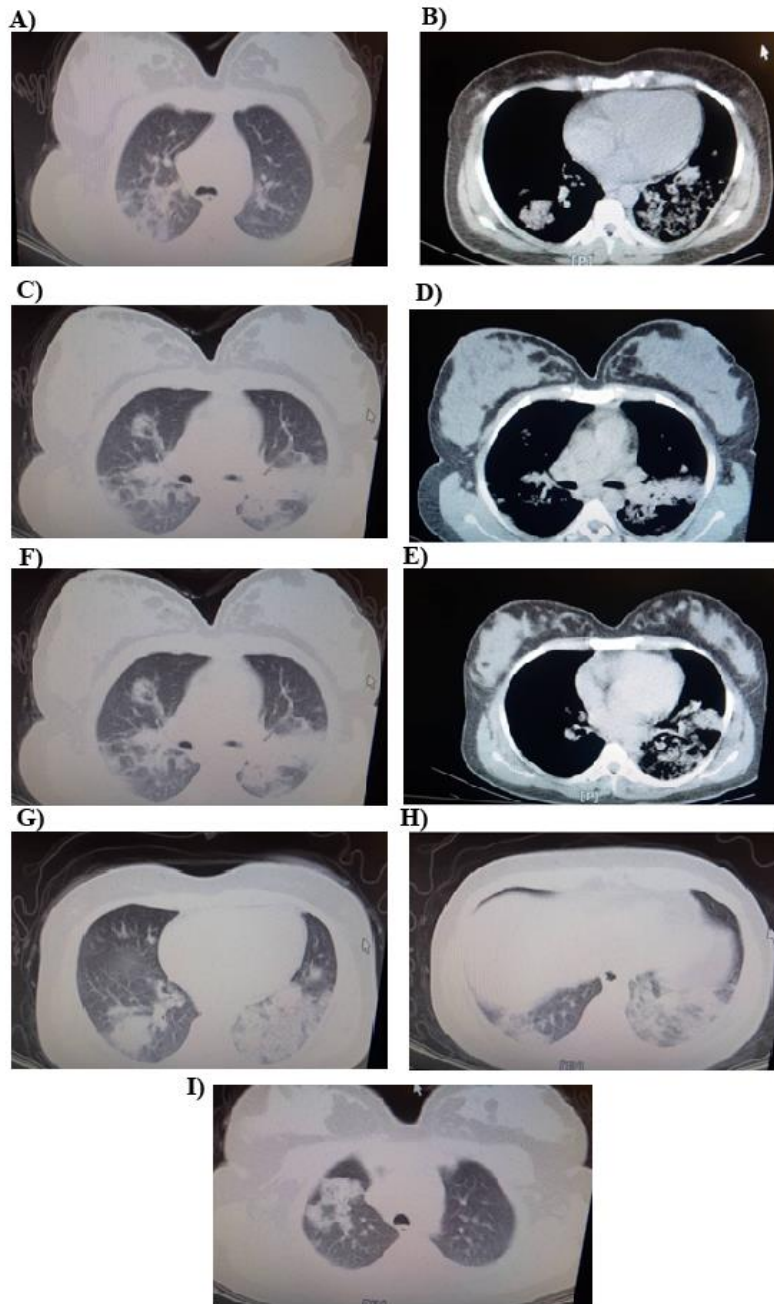


Figure 1. Serial images of the Chest CT scanning (A to I).

(A.S.) Hospital, a tertiary university center in Tehran, Iran with complaints of fever, dry cough and dyspnea. She had no significant past medical disease. She had pulse rate of 92, respiratory rate of 21, with oral temperature of 37.5, O₂ sat: 91% in room air and 94% with nasal flow O₂ upon arrival. Obstetric ultrasound was performed and both fetuses were normal.

Spiral lung and mediastinal CT scan without

contrast injection was performed that showed no pulmonary nodules and pleural lesions. Pericardium was normal. The areas of patchy consolidation in both lungs, especially left lower lobe, with mild effusion on the left, were primarily suggestive of COVID-19 pneumonia (Figure 1). Portable Chest X Ray was taken in which bilateral patchy airspace opacities were reported (Figure 2).

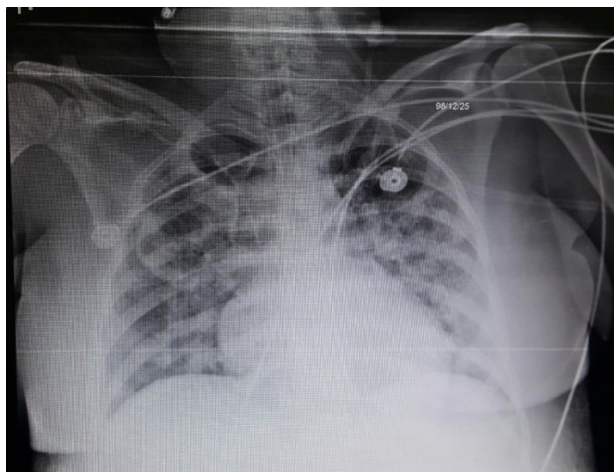


Figure 2. Portable Anteroposterior Chest X Ray.

The results of the initial tests were as follows: WBC: 6600/ μ L (Lymph: 9.5%), Hb: 86 g/L, PLT: 191000/ μ L, Urea: 0.12 g/L, Cr: 0.008 g/L, CRP: 0.068 g/L, ESR: 69 mm/Hr, PT: 11.4 seconds, TT: 24.6 seconds, INR: 1.05, AST: 29 U/L, ALT: 11.3 U/L, ALKP: 131 U/L, **Urine Analysis:** Protein: negative, WBC: 1-2/High Power Field, RBC: 1-2/High Power Field, EPI Cell: 12-14/High Power Field, **Venous Blood Gas Analysis:** pH: 7.46, PvCO₂: 30.8 torr

HCO₃⁻: 215 meq/L), with suspicion diagnosis of Coronavirus, we started treatment with oral Oseltamivir, Ceftriaxone, Hydroxychloroquine, Azithromycin, Lopinavir/ritonavir (Kaletra) and supplemental O₂ therapy with mask. Nasopharyngeal secretion swab sampling was taken and sent for assessment of COVID-19 RT-PCR test, which was confirmed.

After 24 hours, the patient's condition worsened and O₂ saturation dropped to 84%. The patient was transferred to the intensive care unit. After 36 hours in the ICU, due to progressive decline in respiratory status including increased respiratory rate to 40 breaths/min and decreased O₂ saturation to 65%, the patient was intubated using fentanyl and propofol injection and mechanical ventilation was started. Using synchronized intermittent mechanical ventilation (SIMV) with a frequency of 18/minute, PEEP=10 mmHg and a tidal volume of 6 ml/Kg. Afterwards, the heart rate and O₂sat recovered to 120 beats/min and 82%, respectively.

Then Cisatracurium and propofol infusion was started for the patient. Ventilator setting changed to

controlled mechanical ventilation (CMV) with Tidal Volume=5 mL/Kg; Frequency=24/minute and positive end expiratory pressure (PEEP)=14 mmHg. However, two days after intubation, Cisatracurium infusion was tapered and then it was discontinued. Due to the deterioration of the patient's condition, a multidisciplinary team was formed with the participation of anesthesiologist, perinatologist, infectious medicine specialist, intensivist and forensic medicine specialist, which held a consultation meeting to decide, whether to terminate the pregnancy, which was contradicted.

During the next days, hemoglobin concentration dropped to 69 g/L and the patient received one unit of isogroup packed blood cell. On the fourth day of admission, a 3 day-trial of intravenous immunoglobulin (IVIG) was started; 20 mg per day. Again, with a drop in hemoglobin, another unit of isogroup packed blood cell transfused.

As the patient's lung, involvement worsened, with a high degree of suspicion towards hospital-acquired pneumonia, a combination of intravenous standard dose of vancomycin and Meropenem were started. While azithromycin and ceftriaxone were tapered and then discontinued. After a week of hospitalization, the patient's general condition improved.

After 12 days, with the improvement of O₂ saturation, the patient was weaned from the mechanical ventilator support and then alternately placed on spontaneous ventilation, which tolerated well. On the 13th day of hospitalization the patient's sedation was totally discontinued, the patient was extubated, and high flow nasal cannula (HFNC) was used. Meanwhile, fetal heart rate of both fetuses were monitored regularly and continually to take the necessary measures would there be any change.

Five days after extubation, the patient's condition deteriorated, leading again to intubation and mechanical ventilation. Bedside echocardiography and portable chest X ray demonstrated cardiomegaly and a modest decline in left ventricular ejection fraction (about 35%). Further imaging studies demonstrated an extensive recurring involvement of the lung tissues; while they had been in the course of delivery; the possibility of cardiogenic pulmonary edema was in the top of the differential diagnosis list. The lab tests

deteriorated; especially the results of hepatic tests and the coagulation profile. Two units of fresh frozen plasma were transfused. Besides, fetal heart rate monitoring aggravated with a very rapid decline towards asystole. Again, the multidisciplinary consult team was set up emergently within minutes and decided to terminate pregnancy with a high probability of intrauterine fetal death. In addition, the team strongly considered the possibility of myocardial injury and myocarditis due to COVID-19 infection. Meanwhile, episodes of refractory hypotension was observed, mandating norepinephrine infusion with moderate dose. Bedside monitoring of the cardiac function by transthoracic echocardiography demonstrated severe decline in cardiac function with an ejection fraction about 10-15%. Pregnancy was terminated through induction by intravenous infusion of misoprostol; however, the patient's general and hemodynamic status aggravated and a sudden cardiac arrest led to unsuccessful cardiopulmonary bypass and death.

Discussion

Our experience with this patient demonstrated that twin pregnancy in patients with COVID-19 might end in a poor prognosis. It is also important to note that improvement in lung disease is not associated with relief of the risk for myocarditis or involvement of other organs; since the process of myocardial inflammation and injury due to COVID-19 is really a lethal one (6). Still the best recommendation for pregnant women is to consider strict quarantine, especially in women with multiple fetuses.

Conclusion

Pregnancy is undoubtedly a risk factor for immune system defense against COVID-19. There is robust evidence that these patients need much more sophisticated care.

Acknowledgment

The authors acknowledge the kind cooperation of all physicians and nurses in related wards of Imam Hossein (A.S) hospital for their kind cooperation and support.

Conflicts of Interest

The authors declare that there are no conflicts of interest.

References

1. Takian A, Raofi A, Kazempour-Ardebili S. COVID-19 battle during the toughest sanctions against Iran. *Lancet*. 2020;1.
2. Rasmussen SA, Smulian JC, Lednický JA, Wen TS, Jamieson DJ. Coronavirus Disease 2019 (COVID-19) and Pregnancy: What obstetricians need to know. *Am J Obstet Gynecol*. 2020.
3. Chen H, Guo J, Wang C, Luo F, Yu X, Zhang W, et al. Clinical characteristics and intrauterine vertical transmission potential of COVID-19 infection in nine pregnant women: a retrospective review of medical records. *Lancet*. 2020;395(10226):809-15.
4. Yang H, Wang C, Poon LC. Novel coronavirus infection and pregnancy. *Ultrasound Obstet Gynecol*. 2020.
5. Qiao J. What are the risks of COVID-19 infection in pregnant women? *Lancet*. 2020;395(10226):760-2.
6. Guo T, Fan Y, Chen M, Wu X, Zhang L, He T, et al. Cardiovascular Implications of Fatal Outcomes of Patients With Coronavirus Disease 2019 (COVID-19). *JAMA Cardiol*. 2020.