

Case Report



Management of a critically ill child with severe COVID 19 infection: A case report

Amir Hossein Jafari-Rouhi^{1*}, Hamid Soltani Zangbar^{2,3}, Solmaz Fallahi^{3,4}, Leyla Eslamian Ghadim⁵¹Tuberculosis and Lung Disease Research Center, Tabriz University of Medical Sciences, Tabriz, Iran²Department of Neuroscience, Faculty of Advanced Medical Sciences, Tabriz University of Medical Sciences, Tabriz, Iran³Student Research Committee, Tabriz University of Medical Sciences, Tabriz, Iran⁴Department of Physiology, Faculty of Medicine, Tabriz University of Medical Sciences, Tabriz, Iran⁵Faculty of Medicine, Tabriz University of Medical Sciences, Tabriz, Iran

Article info

Article History:

Received: 16 June 2020

Accepted: 29 Aug. 2020

e-Published: 10 Sep. 2020

Keywords:

- COVID-19
- Pediatric
- PICU

Abstract

Coronavirus disease 2019 (COVID-19) is an emerging global disease that severely affects patient's respiratory system and requires respiratory support through mechanical ventilation in the intensive care unit (ICU). The disease has also had effects on the pediatric community, even though its symptoms are found to be milder in children. In this study, an 8-year-old child's health management report, infected with COVID-19, is presented. The patient had a critically ill condition without a previous history of respiratory disease, and underwent mechanical ventilation in the pediatric intensive care unit (PICU). After performing the treatment protocols, the patient was discharged from the ICU after 12 days with a good condition, without any side effects.

Introduction

Coronavirus disease 2019 (COVID-19), caused by a new type of coronavirus, SARS-CoV-2, severely affects the respiratory system of the patients. Following the identification of the disease in Wuhan, it rapidly spread throughout the world. The manifestations of COVID-19 in children are milder compared to adults, and include symptoms like fever and cough.^{1,2}

From January 28 to February 26, 2020, about 1391 children with symptoms have been assessed, of which a sum of 171 (12.3%) were recognized to have SARS-CoV-2 infection. During hospitalization, three of them needed invasive mechanical ventilation, and critical care supports; additionally, they all had an underlying disorder (leukemia with chemotherapy, hydronephrosis, and intussusception).³ A 10-month-old child was the only one who died four weeks after admission with intussusception and multi-organ failure, on March 8, 2020.³

This case report was conducted to review the management of a child with severe lung involvement and severe respiratory failure due to COVID-19 infection who was referred to the Tabriz Children Hospital, Tabriz University of Medical Sciences, Tabriz, Iran.

Case Presentation

An 8-year-old boy without a previous history of respiratory disease was presented to the Tabriz Children Hospital

PICU with a critically ill condition and was intubated on March 18, 2020. Just before referring to this hospital, he was admitted to the emergency department of another general hospital in Tabriz, where a chest x-ray (CXR) was obtained (Figure 1A). Following the patient's referral to the Children Hospital's pediatric intensive care unit (PICU), he was intubated due to persistent hypoxemia. On arrival to the PICU, CXR was performed (Figure 1B). He had a history of alopecia areata and nail changes from 6 months ahead of admission (Figure 2). The topical medications, betamethasone and Eucerin, had been utilized for the past few months. The Laboratory findings are listed in Table 1. Mechanical ventilation strategy was pressure regulated volume control (PRVC) mode; with FiO₂/PEEP titration (we applied PEEP 5 cmH₂O and FiO₂ 100%). Tidal volume was limited to 7 mL/kg, peak pressure <30 cmH₂O, respiratory rate 30 breaths/min with inspiratory time of 0.6 seconds and 25 breathes/min with inspiratory time inspiration of 0.7 seconds after 12 hours. Sedation was performed with midazolam and fentanyl infusion. Intravenous ceftriaxone and clindamycin were changed to meropenem and vancomycin after 12 hours, and oseltamivir and azithromycin were started through nasogastric tube. Dextrose-saline as the maintenance intravenous fluid was given for the patient. Intratracheal and nasopharyngeal swabs were obtained for the detection of SARS-CoV-2 RNA and type A and B Influenza viruses

*Corresponding Author: Dr. Amir Hossein Jafari-Rouhi, Tel: +98 41 333378626, Email: jafarirouhi@tbzmed.ac.ir

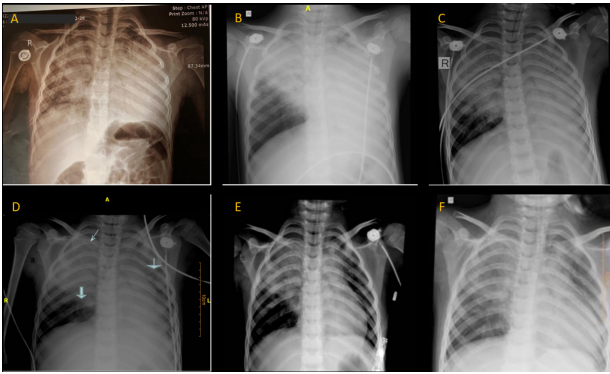


Figure 1. Chest x- rays of the patient. (A) Bilateral alveolar opacity with more preference on left side (obtained in the general hospital). (B) Full opacity on the left and middle lobe consolidations. (C) Full opacity on the left and opacity progression on the right lobes with air bronchograms. (D) Gradual improvement in lung involvement (downwards arrow), CVL (south west arrow). (E) Significant improvement. (F) Significant improvement

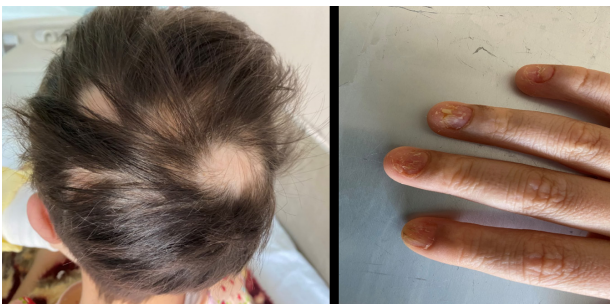

Figure 2. Alopecia areata, nail changes and finger hypopigmented spots.

with established methods.

Following about 30 hours, the patient's status gradually worsened and he had patient-ventilator asynchrony and a decrease in of O₂sat to 40%. The CXR revealed findings on the worsening of his condition (Figure 1C). We changed the ventilator parameters to PEEP 8-10 cmH₂O, tidal volume was limited to 4-7 mL/kg, peak pressure <35 cmH₂O, FiO₂ 100%, respiratory rate 30 with inspiratory time of 0.6 seconds. The O₂sat was maintained at about 88% to 94%. Permissive hypercapnia was acceptable. Low dose intravenous norepinephrine infusion was started and continued for 6 days. We also used 2 g/kg of IVIG divided into 4 days, and 1 mg/kg/d methylprednisolone was used for 3 days. Lung protective mechanical ventilation strategies, which aim to minimize tidal volume and plateau pressure, were the effective intervention associated with our patient's improved survival. Forty-eight hours after admission, on March 20, 2020, it was confirmed that the patient had SARS-CoV-2 infection. After this confirmation, hydroxychloroquine, Kaletra and ribavirin were added and continued for 10 days. Hemodynamic and urinary outputs were monitored.

As the patient's condition improved, the PEEP and respiratory rate, which were modified on a daily basis,

were gradually reduced. On the sixth day of admission, a central venous line was inserted, and a CXR was performed after CV line insertion (Figure 1D). The plateau pressure gradually decreased from day six, and CXR revealed a significant improvement on the tenth day (Figure 1E). Due to excessive ventilator asynchrony, midazolam was temporarily changed to propofol. The ventilator mode was changed to CPAP plus PS on the 11th day, and the patient met the weaning criteria on the 12th day of admission, but given the risk of contact in re-intubation, CXR was performed for further confirmation (Figure 1F). The patient was extubated, and oxygen was provided through a face mask. After one day, he met the criteria for discharge from the PICU.

Discussion

In this outbreak, children are believed to be of milder symptoms and better prognosis, compared with adult cases, yet children with background diseases in their medical conditions and special healthcare needs might be at a higher risk for severe illness^{1,4}

This presentation showed that on a number of occasions, children without a severe underlying medical condition might develop a critical illness caused by the coronavirus. However, it is unclear whether there was a relationship between the mild autoimmune disease of alopecia areata or taking topical steroids, and the progression of pulmonary involvement. Moreover, the effect of Intravenous immunoglobulin (IVIG) in the improvement of the patient's condition remains unclear. Corticosteroids are usually applied as topical anti-inflammatory drugs in dermatology, whose notable amounts can be absorbed into the blood circulation and suppress the natural immune system.^{5,6} Alopecia, an immunodeficiency disorder, is defined by complete lack of hair with limited hair growth, accompanied by problems with the immune system.⁷

Considering the child's suffering from alopecia and the use of corticosteroid medications, he might be infected with COVID-19 due to a weakened immune system. The administration of excessive amounts of fluid may induce capillary leakage raising the accumulation of extravascular lung fluid.⁸ Therefore, the fluid infusion was limited in the management of this patient. In some cases, considering the strict dependency of right ventricular contractility to the right coronary perfusion pressure, it is suggested to employ certain pulmonary vasodilators, like an inhaled nitric oxide, or systemic vasopressors, such as norepinephrine.⁸ Since there was no noninvasive hemodynamic monitoring available in our PICU setting, norepinephrine infusion was used with the onset of increased PEEP and the likelihood of the need for lung recruitment and the possibility of lowering blood pressure.

The prone position is a reliable and safe approach to ventilation, which decreases mortality in subjects with critically reduced oxygenation.⁹ However, due to less involvement of the right lower lobe and heterogeneous

Table 1. The list of laboratory findings obtained during the child's hospitalization in the intensive care unit

Measure	Ref range	Day 1	Day 2	Day 3	Day 4	Day 5	Day 6	Day 7	Day 8	Day 9	Day 10	Day 11	Day 12
Hb g/dL	12-16	11.0	9.5	10.0	9.6	9.5	9.9	9.3	9.4	9.5	10.1	NA	NA
WBC / μ L	4.1-10.1	10.7	11.8	4.75	6.30	6.1	9.26	8.0	6.6	8.8	15.2	NA	NA
Lymph / μ L	1.1-4.8	1.3	3.6	1.40	2.31	1.6	2.50	1.7	1.5	3.3	5.0	NA	NA
Plt, 1000/ μ L	150-400	220	301	185	157	202	264	291	308	313	368	NA	NA
Na, mEq/L	135-145	128	133	133	132	134	135	138	133	134	NA	133	NA
K, mEq/L	3.5-5	5.7	4.9	5	5.2	4.9	5.1	4.6	4.5	4.4	NA	5.2	NA
Cr mg/dl	0.3-1	0.8	NA	0.6	0.5	0.6	0.5	0.7	0.5	0.6	NA	0.4	NA
CRP	-	++	NA	NA	NA	NA	NA	NA	NA	NA	NA	NA	NA
CPK, u/L	39-308	NA	NA	NA	NA	3240	NA	NA	NA	NA	NA	NA	NA
CK-MB, IU/L	< 24	NA	NA	NA	NA	55	NA	NA	NA	NA	NA	NA	NA
CTNI ng/mL	0.04-0.3	NA	NA	NA	NA	0.1	NA	NA	NA	NA	NA	NA	NA
AST, u/L	5-40	55	NA	NA	88	NA	NA	38	NA	NA	NA	31	NA
ALT u/ L	5-40	23	NA	NA	25	NA	NA	34	NA	NA	NA	27	NA
PT, s	12-14	12.8	NA	NA	13.5	NA	NA	14	NA	NA	NA	12	NA
PTT, s	27-45	34	NA	NA	35.1	NA	NA	33	NA	NA	NA	40	NA
LDH, u/ L	70-160	NA	NA	NA	NA	1430	NA	NA	NA	NA	NA	NA	NA
PH (VBG)	7.35-7.45	7.43	7.44	7.36	7.39	7.38	7.44	7.45	7.43	7.56	7.35	7.44	7.39
Pco2 (VBG)	35-45	46.5	31.5	40.7	38.0	66.5	47.1	26.8	48.5	30.5	47.3	46.2	53.7

NA; Not Applicable, Hb; Hemoglobin, WBC; White Blood Cell, Lymph; Lymphocyte, Plt; Platelet, Na; Sodium, K; Potassium, Cr; Creatinine, CRP; C-Reactive Protein, CPK; Creatine Phosphokinase, CK-MB; Creatine Kinase-MB, CTNI; Cardiac Troponin I, AST; Aspartate Transaminase, ALT; Alanine Transaminase, PT; Prothrombin Time, PTT; Partial Thromboplastin Time, LDH; Lactate Dehydrogenase, PH; Power of Hydrogen, Pco2; Partial Pressure of Carbon dioxide.

lung involvement, herein, the patient was placed alternately supine or left side up to reduce shunting and dead space ventilation, and there was no need to the prone position.

Certain reports suggest using pressure targeted ventilation and pressure-regulated volume control ventilation in pediatric patients.¹⁰ Initially, patient ventilation management strategy was low tidal volume ventilation to apply high PEEP. However, considering inadequate response to high PEEP (>10 cmH2O), there was a need to increase driving pressure to improve tidal volume and oxygenation despite increasing PEEP, which demonstrated that the compliance of the respiratory system and lung recruitment ability was low. Accordingly, the lung-protective mechanical ventilation strategies have been used to prevent further ventilator-associated lung injury, but inevitably with a temporary high FiO₂. Pan C et al. showed this in 19 intubated adult patients with ARDS caused by COVID-19 disease with high driving pressure and low respiratory system compliance. In addition, the majority of patients were poorly recruitable with high PEEP, but the recruiting ability seemed to change when altering body position.^{11,12}

The goal of oxygenation was maintaining the peripheral oxygen saturation above 88 percent, and Permissive hypercapnia was acceptable. The rationale behind this approach was that it might reduce the frequency of ventilator adjustments requiring staff entry into the room, thereby increasing the risk concerning staff's healthcare, although there are not enough data to support it.

Severe pulmonary involvement and acute respiratory distress syndrome may develop in children due to COVID

19 infection. However, therapies based on respiratory system support and precise adjustments of the mechanical ventilation along with the pharmacotherapy protocols mentioned in the case representation, can be beneficial in the process of treatment and full recovery of the critically ill children with severe COVID-19 infection admitted to the PICUs. Considering the low incidence of critically ill children suffering from COVID-19 infection, a proper understanding of its management and prognosis requires experiences from other PICUs around the world.

Various alternative approaches to the management of COVID-19 and the relevant strategies include pathogen-targeting strategies, host-targeting strategy, immunity modifiers and symptomatic treatment strategies. The pathogen-targeting strategies use antivirals, anti-malarials and anti-rheumatics. Host-targeting strategy-immunity modifiers consider natural killer cells, monoclonal antibodies, interferon- α , corticosteroids, and miscellaneous agents. Symptomatic treatment strategies are useful in mild infections, COVID-19 pneumonia, COVID-19 ARDS, and septic shock. Recent strategies include antithrombotic therapy and convalescent plasma/immunoglobulin utilization.^{13,14}

Conflict of Interest

There is no conflict of interest.

Funding

None.

References

1. World Health Organization (WHO). Clinical Management

- of Severe Acute Respiratory Infection When Novel Coronavirus (nCoV) Infection is Suspected: Interim Guidance, 25 January 2020. WHO; 2020.
- Ong JSM, Tosoni A, Kim Y, Kissoon N, Murthy S. Coronavirus disease 2019 in critically ill children: a narrative review of the literature. *Pediatr Crit Care Med*. 2020;21(7):662-6. doi: 10.1097/pcc.0000000000002376.
 - Lu X, Zhang L, Du H, Zhang J, Li YY, Qu J, et al. SARS-CoV-2 infection in children. *N Engl J Med*. 2020;382(17):1663-5. doi: 10.1056/NEJMc2005073.
 - Joseph T, Ashkan M. COVID-19. 2020 .
 - Coutinho AE, Chapman KE. The anti-inflammatory and immunosuppressive effects of glucocorticoids, recent developments and mechanistic insights. *Mol Cell Endocrinol*. 2011;335(1):2-13. doi: 10.1016/j.mce.2010.04.005.
 - Ghosh A, Coondoo A. Systemic side effects of topical corticosteroids. In: Lahiri K, ed. *A Treatise on Topical Corticosteroids in Dermatology*. Singapore: Springer; 2018. p. 241-9. doi: 10.1007/978-981-10-4609-4_25.
 - Gilhar A, Etzioni A, Paus R. Alopecia areata. *N Engl J Med*. 2012;366(16):1515-25. doi: 10.1056/NEJMra1103442.
 - Fuhrman BP, Zimmerman JJ. *Pediatric Critical Care E-Book*. Elsevier Health Sciences; 2011.
 - Mora-Arteaga JA, Bernal-Ramírez OJ, Rodríguez SJ. The effects of prone position ventilation in patients with acute respiratory distress syndrome. A systematic review and metaanalysis. *Med Intensiva*. 2015;39(6):359-72. doi: 10.1016/j.medin.2014.11.003.
 - Chernick V. *Kendig's Disorders of the Respiratory Tract in Children*. Philadelphia: Saunders; 1990.
 - Pan C, Chen L, Lu C, Zhang W, Xia JA, Sklar MC, et al. Lung recruitability in COVID-19-associated acute respiratory distress syndrome: a single-center observational study. *Am J Respir Crit Care Med*. 2020;201(10):1294-7. doi: 10.1164/rccm.202003-0527LE.
 - Shen K, Yang Y, Wang T, Zhao D, Jiang Y, Jin R, et al. Diagnosis, treatment, and prevention of 2019 novel coronavirus infection in children: experts' consensus statement. *World J Pediatr*. 2020;16(3):223-31. doi: 10.1007/s12519-020-00343-7.
 - Jamshaid H, Zahid F, Din IU, Zeb A, Choi HG, Khan GM, et al. Diagnostic and treatment strategies for COVID-19. *AAPS PharmSciTech*. 2020;21(6):222. doi: 10.1208/s12249-020-01756-3.
 - Wiersinga WJ, Rhodes A, Cheng AC, Peacock SJ, Prescott HC. Pathophysiology, transmission, diagnosis, and treatment of coronavirus disease 2019 (COVID-19): a review. *JAMA*. 2020. doi: 10.1001/jama.2020.12839.