

## Original Article



# Evaluation of inflammatory miRNA155 and 146a expression in heart tissue of ovalbumin-sensitized male rats

Mehdi Hassanpour<sup>1,2,3</sup>, Akbar Darbin<sup>2</sup>, Rana Keyhanmanesh<sup>4,5</sup>, Mahdi Ahmadi<sup>4,5\*#</sup>, Reza Rahbarghazi<sup>4,6\*#</sup><sup>1</sup>Department of Clinical Biochemistry and Laboratory Medicine, Tabriz University of Medical Sciences, Tabriz, Iran<sup>2</sup>Cardiovascular Research Center, Tabriz University of Medical Sciences, Tabriz, Iran<sup>3</sup>Student Research Committee, Tabriz University of Medical Sciences, Tabriz, Iran<sup>4</sup>Drug Applied Research Center, Tabriz University of medical sciences, Tabriz, Iran<sup>5</sup>Tuberculosis and lung Diseases Research Center, Tabriz University of Medical Sciences, Tabriz, Iran<sup>6</sup>Department of Applied Cell Science, Faculty of Advanced Medical Sciences, Tabriz University of Medical Sciences, Tabriz, Iran**Article info****Article History:**

Received: 29 Aug. 2020

Accepted: 4 Oct. 2020

e-Published: 15 Mar. 2021

**Keywords:**

- Asthma
- Cardiovascular injury
- Inflammatory miRNAs

**Abstract**

**Introduction:** Asthma is a chronic pulmonary inflammation occurred in response to different allergens, leading to respiratory system insufficiency. The production of different inflammatory factors and enhanced immune system response may affect the function of other organs. The aim of this study was to investigate the expression of inflammatory microRNAs in cardiac tissue in asthmatic rat models.

**Methods:** In this study, the animals were allocated into control and asthmatic rats (n=8). To induce asthma, rats were challenged with ovalbumin (OVA). Fourteen days after induction of asthma, rats were euthanized and hematoxylin-eosin (H&E) staining was performed to assess pathological changes in their pulmonary tissue. Serum levels of cardiac enzymes were measured using ELISA kits. Finally, transcription level of inflammatory miRNAs, miRNA-146a and -155, were measured using real-time polymerase chain reaction (PCR) analysis.

**Results:** Based on our findings, histological examination indicated the existence of pathological changes in pulmonary tissue after asthma induction. Bright-field analysis revealed an existence of inflammatory response and cytotoxicity in cardiac tissue. Also, the serum levels of creatine phosphokinase-MB (CpK-MB), alanine aminotransferase (ALT), and aspartate aminotransferase (AST) were significantly higher in the serum of asthmatic group compared to control group ( $P < 0.05$ ). Finally, asthmatic condition induced the expression of (2-fold) miRNA-146a and (1.5-fold)-155 in cardiac tissue, respectively.

**Conclusion:** As a conclusion, it could be concluded that asthmatic condition induces systemic inflammation in cardiac tissue. On a more general note, we propose that therapeutical approaches directed to inflammatory pathway may be required to preserve cardiac injuries caused of asthma.

**Introduction**

Asthma is a chronic pulmonary inflammatory disease with profound structural alteration in lungs and airway conduits, contributing to airway obstruction.<sup>1,2</sup> The emergence of chronic inflammatory response, not only, could affect the function of respiratory system, but also affect the physiological behavior of tissues which functionally are in close relation with respiration.<sup>3</sup> Evidences have shown the potency of asthma inflammatory factors in the progression of atherosclerosis and cardiovascular disease (CVD).<sup>4</sup> Based on the released facts from cohort studies, there is a close association between asthma and CVDs, in which an increased risk of CVDs has been reported in asthmatic patients.<sup>5</sup> However, there is no consolidated agreement

on the reciprocal association of CVD and asthmatic changes and underlying mechanisms are still unknown.<sup>6</sup> It is thought that the increase of acute phase proteins and inflammatory mediators in asthmatic patients such as including interleukin-1 (IL-1), tumor necrosis factor-alpha (TNF- $\alpha$ ), interleukin-6 (IL-6), C-reactive protein (CRP), platelet-activating factor, etc., can play a role in the progression of atherosclerosis and CVD.<sup>7</sup> Along with these changes, the level of leukotriene is increased after initiation of inflammation in cardiac and pulmonary tissues.<sup>8</sup>

miRNAs are small non-coding RNAs, ranging from 18 to 25 nucleotides, and regulate gene expression by the inhibition of mRNA translation or degradation.<sup>9</sup>

\*Corresponding Authors: Reza Rahbarghazi, Email: Rezarahbardvm@gmail.com; Mahdi Ahmadi, Email: Mahdi59866@gmail.com

# Reza Rahbarghazi and Mahdi Ahmadi contributed equally to this work.

© 2021 The Author(s). This is an open access article distributed under the terms of the Creative Commons Attribution License (<http://creativecommons.org/licenses/by/4.0/>), which permits unrestricted use, distribution, and reproduction in any medium, provided the original work is properly cited.

Literature reviews demonstrated that level of distinct microRNAs could be changed in cardiac disorders, and could be consider as a biomarker for heart tissue injury.<sup>10</sup> In this respect, experiments highlighted the increase of miRNA-155 and -146a in acute myocardial infarction and inflammatory diseases.<sup>11</sup> However, there is a controversial debate regarding miRNA-155 expression in asthmatic animals compared to normal subjects.<sup>12</sup> This miRNA targets critical inflammatory genes including c-Fos, C-Maf, and INF- $\gamma$  receptor.<sup>12,13</sup> The promotion of asthmatic changes in rats and mice by ovo-albumin induced the expression of miRNA-155 in the lungs.<sup>14-16</sup> As a result, targeting specific miRNAs could supplement instrumental data in the control of allergic asthma and asthma-derived pathology in non-pulmonary tissues such as heart.

Despite the great importance of asthma in disrupting cardiac pathophysiology, few studies have been conducted yet. The aim of this study was to investigate the expression level of inflammatory microRNAs in cardiac tissue of asthmatic rats.

**Material and methods**

**Asthma induction and animal groups**

Sixteen adult male Wistar rats, weighting approximately 200 g, were enrolled in this study. The animals were kept in standard cages under 12:12 light-dark cycle at 18-22°C with free access to water and food. After adaptation to the new condition, rats were allocated into control and asthmatic rats (n=8). In order to induce asthmatic changes, rats were exposed to ovalbumin (OVA; Sigma-Aldrich, USA) for a period of 32  $\pm$  1 days according to our previous studies.<sup>17</sup>

Each animal received 1 mg OVA and 200 mg aluminum hydroxide (as adjuvant) intra-peritoneally dissolved in 1 mL normal saline from the days 1 to 8. On day 14, the sensitized rats were challenged daily with aerosolized condition of 4% OVA formed by a nebulizer for 5 minutes (CX3, Omron Co., Netherlands), for 18  $\pm$  1 days without any interruption. This exposure was induced in a special sealed box with dimensions of 30  $\times$  20  $\times$  20 cm<sup>3</sup>. In the healthy subjects, the same vehicle type was injected instead of OVA with the same manner. One day after the completion of sensitization protocol, all assays

was performed. After completion of asthma procedure, animals were euthanized by using the combination of ketamine and xylazine. Following the completion of asthma induction, the animals were anesthetized using ketamine (75 mg/kg bw)/xylazine (3 mg/kg bw) solution intraperitoneally and scarified. Both hearts and lungs were removed and subjected to the histological examination and genomic analysis.

**Histological examination**

To confirm the promotion of asthmatic changes in pulmonary tissue and assess the effect of asthma on cardiac tissue, we performed hematoxylin-eosin (H&E) staining. To this end, left ventricle tissue was excised and kept in 10% buffered-formalin solution (Merck, Germany). Samples were dehydrated, cleared by xylol, and paraffin-embedded. 4  $\mu$ m-thick sections were prepared using microtome (Leica) and stained by H&E solution. Cardiac samples were evaluated for the existence of necrosis and inflammation. In pulmonary tissue, we monitored different pathologies such as immune cell infiltration, edema, emphysema, and atelectasis and bronchioles epithelial detachment.

**Investigation of cardiac enzymes**

The activity levels of creatine phosphokinase-MB (CpK-MB), alanine aminotransferase (ALT), and aspartate aminotransferase (AST) in the serums were measured using commercial kits according to manufacture protocol (Pars Azmun, Iran).

**Real-time polymerase chain reaction assay**

To assess the transcription of miRNA-146a and -155, real-time polymerase chain reaction (PCR) analysis was performed. On this basis, left ventricle was quickly chopped and RNA content isolated using TRIzol (Roche, Germany) according to the manufacturer’s protocols. RNA concentration and integrity were measured by using a Picodrop 1000 Spectrophotometer (Thermo Scientific, USA). The sequence of target gene was designed using Gene-Runner Software (Ver. 3.05) (Table 1). To synthesize cDNA, reverse transcription was carried out by cDNA Synthesis Kit (TaKaRa). Real-time PCR assay was conducted by cocktail of cDNA sample (1  $\mu$ L), SYBR

**Table 1.** Primer list

Gene	Sequence	Ref
miRNA-146a	Forward: CGTGCTGTGACCTATGCTG Universal Reverse: CCAGTGCAGGGTCCGAGGTA Stem loop: GTCGTATCCAGTGCAGGGTCCGAGGTATTCCGACTGGATACGACTTCCCT	18
miRNA-155	Forward: CGGCGCTTAATGCTAATCGTGATAG Universal Reverse: GTGCAGGGTCCGAGGT Stem loop: GTCGTATCCAGTGCAGGGTCCGAGGTATTCCGACTGGATACGACACCCCT	18
U6-6p	Forward: GCTTCGGCAGCACATATACTAAAAT Reverse: CGCTTACGAATTTGCGTGTCTAT Stem loop: GTCGTATCCAGTGCAGGGTCCGAGGTATTCCGACTGGATACGACAAAAATAT	18

Green master mix (5  $\mu$ L; TaKaRa), DEPC water (3.7  $\mu$ L) and primers (0.3  $\mu$ L) on a Rotor-Gene 6000 instrument (Corbett, Australia). The amount of PCR products was normalized to housekeeping U6. The  $2^{-\Delta\Delta Ct}$  method was used to calculate relative-quantitative expression of miRNA.

### Statistical analysis

The analysis was done using GraphPad software (version Prism 8). We checked the data distribution normality using the Kolmogorov–Smirnov test. All quantitative data were presented as mean  $\pm$  SD and analyzed using Student t test. Statistical significance was considered at  $P < 0.05$ .

### Results

#### Asthma promoted pathological changes in pulmonary and cardiac tissues

Histological examination revealed the promotion of pathological changes in pulmonary tissue after induction of asthma. According to our data, asthma promoted immune cell recruitment and occurrence of interstitial bronchopneumonia (Figure 1). Immune cells were infiltrated into the alveolar sacs and space between the alveoli, leading to thickening of alveolar walls. The lymphoid tissue in the proximity of bronchioles (termed BALT) underwent hyperplasia. Different sites of lungs showed atelectasis and emphysema. The bronchioles epithelium was detached and shed into the airway conduit (Figure 1).

Bright-field imaging revealed an existence of inflammatory response and cytotoxicity in cardiac tissue

(Figure 1). Data showed the occurrence of necrotic changes and focal hyperemia in cardiac tissue in asthmatic rats. These data showed that the promotion of asthmatic changes contribute to the occurrence of inflammatory response in the cardiac tissue.

#### Asthma increased serum levels of cardiac enzymes

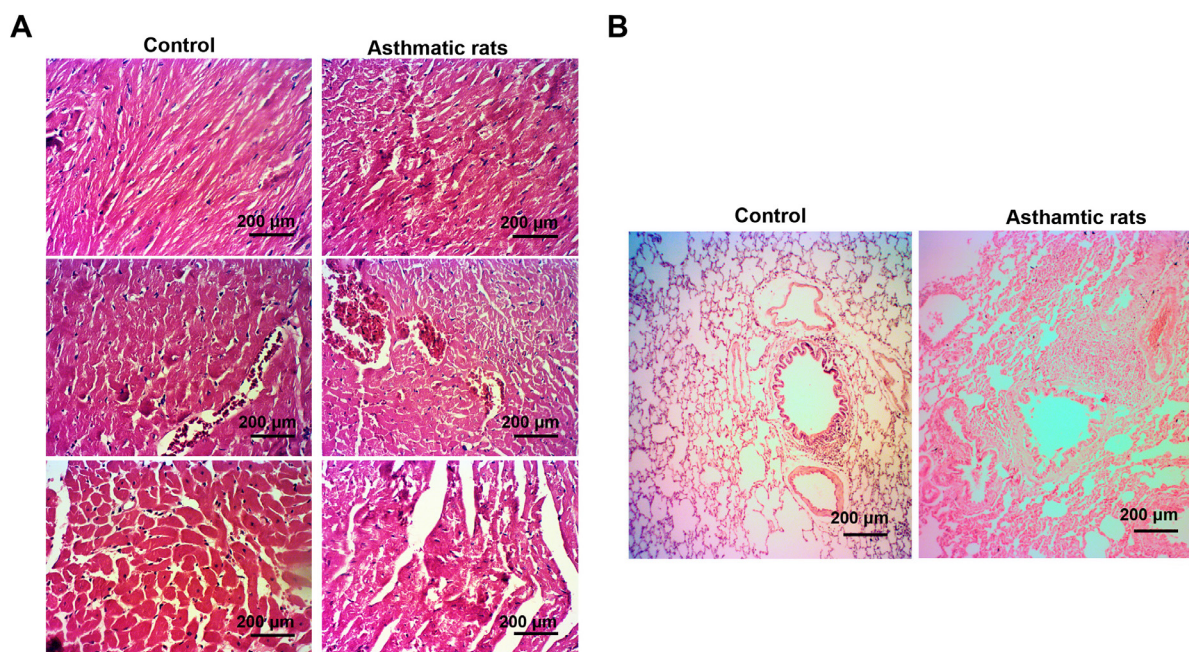
For evaluating the effect of asthmatic condition to the myocardium, the serum levels of cardiac enzymes were measured in asthmatic group and compared to the control rats (Figure 2). According to our data, asthmatic condition could damage the myocardium indicated by elevated levels of enzymes CpK-MB, ALT, and AST. These data showed that the asthmatic condition could alter serum levels of enzymes such as CpK-MB, ALT, and AST.

#### Asthma induced the expression of miRNA-146a and -155

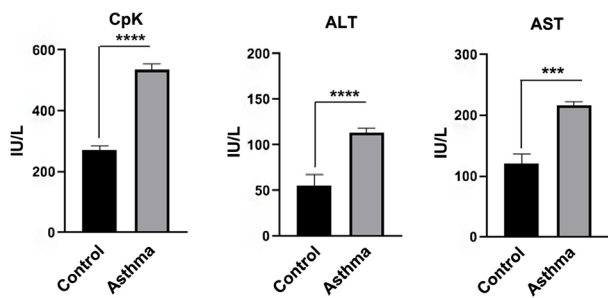
Real-time PCR assay revealed the induction of both miRNA-146a and -155 in cardiac tissues compared to the control samples. Based on the data, the transcription of miRNA-146a (2-fold) and -155 (1.5-fold) was increased after the completion of asthma in cardiac tissue, showing that asthma could directly change the level of distinct miRNA in cardiac tissue (Figure 3).

### Discussion

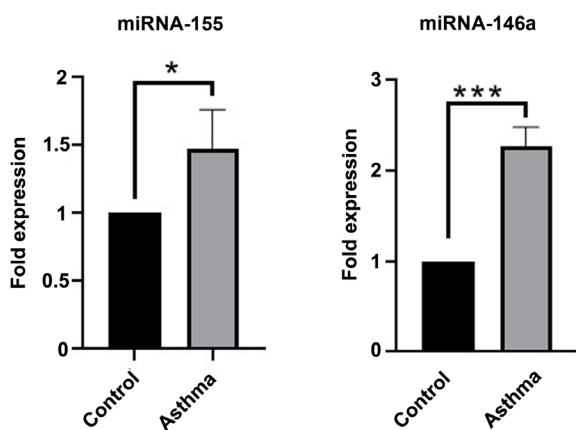
More than a decade, studies have suggested that different dysfunctional conditions, such as asthma, lead to CVDs.<sup>19-21</sup> The present study was designed to determine the effect of asthma on inflammatory status in heart tissue of the experimental rat model. To this end,



**Figure 1.** Bright field-images from pulmonary tissue sections ( $\times 50$ ; H&E). As shown, alveolar hemorrhage, epithelial cell shedding, and goblet cell hyperplasia were seen in rats from asthmatic groups, indicating successful induction asthmatic condition (B). Based on our data obtained from imaging, asthmatic context leads to the inflammation in the heart tissue and consequently cardiac tissue injury (A).



**Figure 2.** Evaluating the serum levels of cardiac enzymes. As shown, the serum levels of CpK-MB, ALT, and AST were significantly higher in the serum of asthmatic group compared to control group ( $P < 0.05$ ). \*\*\*  $P < 0.001$ ; \*\*\*\*  $P < 0.0001$ .



**Figure 3.** Real-time PCR analysis. Based on our data, the levels of miRNA-146a and -155 were increased after induction of asthma in cardiac tissue, showing that asthma directly changes the level of inflammatory miRNAs in cardiac tissue (\* $P < 0.05$ ; \*\*\*  $P < 0.001$ ).

32 days OVA injection have recruit of immune cells, resulting in thickening of alveolar walls and occurrence of interstitial bronchopneumonia. This period of OVA injections revealed significant pathological changes in pulmonary tissue, validating successful induction of asthmatic changes. Some evidences have shown that myocardium involvement is more common in asthma patients comparing the healthy persons.<sup>22</sup> In this respect, based on our results, bright-field imaging discovered an inflammatory response and cytotoxicity in cardiac tissue. Our data demonstrated that the necrotic changes and focal hyperemia was seen in cardiac tissue of asthmatic rats, indicating the promotion of asthmatic modifications contribute to the inflammatory response of the cardiac tissue. There is a large body of evidence indicating CpK-MB, ALT, and AST overproduction in CVDs patients.<sup>23</sup> Along these, based on our results, we decided that levels of CpK-MB, ALT, and AST drastically have increased in sera of asthmatic rats comparing with normal subjects. Our data must have revealed the induction of cardiac injury in asthmatic myocardium.

Inflammation process is the one of hallmarks of asthma pathogenesis, resulting to asthmatic complications.<sup>2</sup>

Another important finding was that miRNA-146a and -155 levels in lung tissues increased as a result of asthmatic condition, indicating inflammation response has been launched against asthmatic status.<sup>24</sup> These data demonstrated that conditions such as asthma induces inflammation process by increasing inflammatory MicroRNAs.<sup>25</sup> In authorize of this claim, it was demonstrated that CVDs is a common comorbidity of pulmonary disease and is possibly related to increased systemic inflammation and worse prognosis.<sup>26,27</sup> Moreover, Sobko et al showed a relationship between asthma and heart dysfunction.<sup>28</sup> Thus, it could be concluded that asthmatic condition induces systemic inflammation in many tissues including heart contexts. On a more general note, we propose that therapeutically approaches directed to inflammatory pathway may be required to preserve cardiac injuries caused of asthma. There is a scarcity of studies on the involved mechanisms of cardiac dysfunction in asthmatic patients and so, their relationship with asthma and CVDs is not clear yet. Therefore, more work is required for clarifying underlined mechanism of cardiac insufficiency in asthmatic status.

#### Conflict of Interest

The authors declare that there is no conflict of interest.

#### Ethical Approval

All phases of the present study were conducted in compliance with the criteria and guidelines published by the National Institutes of Health for Laboratory Animal Care (NIH Publication No. 85-23, revised 1996). This study was approved by the Ethics Committee of Tabriz University of Medical Sciences (No: IR.TBZMED.VCR.REC.1398.313).

#### Authors' Contribution

MH and AD performed all methods of manuscript. RR conceived and designed the topic. MH and RK wrote the manuscript. MA supervised and edited the final manuscript.

#### Acknowledgements

The authors would like to express appreciation to the staff of Stem Cell Research Center, Tabriz University of Medical Sciences, Tabriz, Iran.

#### Funding

Pulmonary Research Center, Tabriz University of Medical Sciences, Tabriz, Iran (Grant No: 63738).

#### Study Highlights

##### What is current knowledge?

- Asthmatic condition can promote the injury of cardiac tissue.

##### What is new here?

- Changes in transcription of certain miRNAs lead to cardiac tissue injury during asthmatic changes

## References

1. Nakawah MO, Hawkins C, Barbandi F. Asthma, chronic obstructive pulmonary disease (COPD), and the overlap syndrome. *J Am Board Fam Med.* 2013;26(4):470-7. doi: 10.3122/jabfm.2013.04.120256.
2. Rahbarghazi R, Keyhanmanesh R, Aslani MR, Hassanpour M, Ahmadi M. Bone marrow mesenchymal stem cells and condition media diminish inflammatory adhesion molecules of pulmonary endothelial cells in an ovalbumin-induced asthmatic rat model. *Microvasc Res.* 2019;121:63-70. doi: 10.1016/j.mvr.2018.10.005.
3. Ramakrishnan RK, Mahboub B, Hamid Q. Asthma-chronic obstructive pulmonary disease overlap: a distinct pathophysiological and clinical entity. In: Bernstein JA, Boulet LP, Wechsler ME, eds. *Asthma, COPD, and Overlap: A Case Based Overview of Similarities and Differences.* Boca Raton: CRC Press; 2018. p. 55-66.
4. Tattersall MC, Guo M, Korcarz CE, Gepner AD, Kaufman JD, Liu KJ, et al. Asthma predicts cardiovascular disease events: the multi-ethnic study of atherosclerosis. *Arterioscler Thromb Vasc Biol.* 2015;35(6):1520-5. doi: 10.1161/atvbaha.115.305452.
5. Iribarren C, Tolstykh IV, Miller MK, Sobel E, Eisner MD. Adult asthma and risk of coronary heart disease, cerebrovascular disease, and heart failure: a prospective study of 2 matched cohorts. *Am J Epidemiol.* 2012;176(11):1014-24. doi: 10.1093/aje/kws181.
6. Cepelis A, Brumpton BM, Laugsand LE, Dalen H, Langhammer A, Janszky I, et al. Asthma, asthma control and risk of acute myocardial infarction: HUNT study. *Eur J Epidemiol.* 2019;34(10):967-77. doi: 10.1007/s10654-019-00562-x.
7. Barnes PJ. Cellular and molecular mechanisms of asthma and COPD. *Clin Sci (Lond).* 2017;131(13):1541-58. doi: 10.1042/cs20160487.
8. Ahmadi M, Rahbarghazi R, Shahbazfar AA, Baghban H, Keyhanmanesh R. Bone marrow mesenchymal stem cells modified pathological changes and immunological responses in ovalbumin-induced asthmatic rats possibly by the modulation of miRNA155 and miRNA133. *Gen Physiol Biophys.* 2018;37(3):263-74. doi: 10.4149/gpb\_2017052.
9. Gebert LFR, MacRae IJ. Regulation of microRNA function in animals. *Nat Rev Mol Cell Biol.* 2019;20(1):21-37. doi: 10.1038/s41580-018-0045-7.
10. Viereck J, Thum T. Circulating noncoding RNAs as biomarkers of cardiovascular disease and injury. *Circ Res.* 2017;120(2):381-99. doi: 10.1161/circresaha.116.308434.
11. Su Q, Yang H, Li L. Circulating miRNA-155 as a potential biomarker for coronary slow flow. *Dis Markers.* 2018;2018:6345284. doi: 10.1155/2018/6345284.
12. Kai W, Qian XU, Qun WU. MicroRNAs and asthma regulation. *Iran J Allergy Asthma Immunol.* 2015;14(2):120-5.
13. Banerjee A, Schambach F, DeJong CS, Hammond SM, Reiner SL. Micro-RNA-155 inhibits IFN-gamma signaling in CD4+ T cells. *Eur J Immunol.* 2010;40(1):225-31. doi: 10.1002/eji.200939381.
14. Malmhäll C, Alawieh S, Lu Y, Sjöstrand M, Bossios A, Eldh M, et al. MicroRNA-155 is essential for T(H)2-mediated allergen-induced eosinophilic inflammation in the lung. *J Allergy Clin Immunol.* 2014;133(5):1429-38. doi: 10.1016/j.jaci.2013.11.008.
15. Ahmadi M, Rahbarghazi R, Shahbazfar AA, keyhanmanesh R. Monitoring IL-13 expression in relation to miRNA-155 and miRNA-133 changes following intra-tracheal administration of mesenchymal stem cells and conditioned media in ovalbumin-sensitized rats. *Thai J Vet Med.* 2018;48(3):347-55.
16. Solberg OD, Ostrin EJ, Love MI, Peng JC, Bhakta NR, Hou L, et al. Airway epithelial miRNA expression is altered in asthma. *Am J Respir Crit Care Med.* 2012;186(10):965-74. doi: 10.1164/rccm.201201-0027OC.
17. Keyhanmanesh R, Rahbarghazi R, Aslani MR, Hassanpour M, Ahmadi M. Systemic delivery of mesenchymal stem cells condition media in repeated doses acts as magic bullets in restoring IFN- $\gamma$ /IL-4 balance in asthmatic rats. *Life Sci.* 2018;212:30-6. doi: 10.1016/j.lfs.2018.09.049.
18. Shademan B, Nourazarian A, Nikanfar M, Avci CB, Hasanpour M, Isazadeh A. Investigation of the miRNA146a and miRNA155 gene expression levels in patients with multiple sclerosis. *Journal of Clinical Neuroscience.* 2020; 78: 189-93.
19. Pollevick ME, Xu KY, Mhango G, Federmann EG, Vedanthan R, Busse P, et al. The relationship between asthma and cardiovascular disease: an examination of the Framingham offspring study. *Chest.* 2020. doi: 10.1016/j.chest.2020.11.053.
20. Dogra S, Ardern CI, Baker J. The relationship between age of asthma onset and cardiovascular disease in Canadians. *J Asthma.* 2007;44(10):849-54. doi: 10.1080/02770900701752391.
21. Burge MR, Aldrete KL, Ehrhart M, Murray-Krezan C. 439-P: Assessing the Relationship between Asthma and Cardiovascular Disease Risk in Type 2 Diabetes Using Revised Risk Estimates. *Diabetes.* 2019;68(Suppl 1):439. doi: 10.2337/db19-439-P.
22. Ingebrigtsen TS, Marott JL, Vestbo J, Nordestgaard BG, Lange P. Coronary heart disease and heart failure in asthma, COPD and asthma-COPD overlap. *BMJ Open Respir Res.* 2020;7(1):e000470. doi: 10.1136/bmjresp-2019-000470.
23. Pochhi M, Muddeshwar M. Serum enzymes markers in myocardial infarction: a study of rural area. *Asian J Med Sci.* 2017;8(2):34-7. doi: 10.3126/ajms.v8i2.16313.
24. Mousavi SR, Ahmadi A, Jamalkandi SA, Salimian J. Involvement of microRNAs in physiological and pathological processes in asthma. *J Cell Physiol.* 2019;234(12):21547-59. doi: 10.1002/jcp.28781.
25. Heffler E, Allegra A, Pioggia G, Picardi G, Musolino C, Gangemi S. MicroRNA profiling in asthma: potential biomarkers and therapeutic targets. *Am J Respir Cell Mol Biol.* 2017;57(6):642-50. doi: 10.1165/rcmb.2016-0231TR.
26. Chen W, Thomas J, Sadatsafavi M, FitzGerald JM. Risk of cardiovascular comorbidity in patients with chronic obstructive pulmonary disease: a systematic review and meta-analysis. *Lancet Respir Med.* 2015;3(8):631-9. doi: 10.1016/s2213-2600(15)00241-6.
27. Müllerova H, Agusti A, Erqou S, Mapel DW. Cardiovascular comorbidity in COPD: systematic literature review. *Chest.* 2013;144(4):1163-78. doi: 10.1378/chest.12-2847.
28. Sobko EA, Solov'eva IA, Kraposhina A, Riazanova NG, Vtiurina SS, Salmina AB, et al. [Relationship between endothelial dysfunction and mechanisms of systemic inflammation in left heart remodeling in patients with bronchial asthma]. *Klin Med (Mosk).* 2014;92(11):43-8.