

Original Article



Computed tomography findings of isolated peripheral pulmonary artery aneurysms

İlyas Dündar¹, Ensar Türko¹

Department of Radiology, Faculty of Medicine, Van Yuzuncu Yil University, 65080, Van, Turkey

Article info

Article History:

Received: 29 May 2021

Accepted: 10 July 2021

e-Published: 23 Dec. 2021

Keywords:

- Peripheral pulmonary artery aneurysm
- Behcet disease
- Hughes Stovin syndrome
- Pulmonary artery embolism
- Deep venous thrombosis
- Rupture

Abstract

Introduction: In this study, we aimed to evaluate computed tomography (CT) findings of peripheral pulmonary artery aneurysms (PPAA) associated with Behcet's disease (BD), Hughes Stovin syndrome (HSS), and idiopathic origin.

Methods: Contrast-enhanced CT scans of the patients were retrospectively reviewed regarding PPAA. The patients with PPAA were classified into BD, HSS, and idiopathic groups according to the etiology. The groups were compared for demographical features including age and gender, multiplicity, distribution of thrombosis and accompanying pulmonary artery embolism (PAE), and deep venous thrombosis (DVT) history.

Results: A total of 30 PPAA (25.4±13.4 [11-62] mm) were detected in 10 (2.3%) (mean age 39.8±22-1.0 [8-73] years, female/male:3/7) among 4391 patients reviewed. In 7 patients, multiple aneurysms were detected, while a solitary lesion was seen in 3 patients. Most commonly, lower lobes (right 8-left 8, 53.2%) involvement was observed. A thrombosis was detected within 19 (63.4%) aneurysms. Among 10 patients with PPAA, 4 subjects (40%) had BD, 2 (20%) HS and 4 (40%) idiopathic origin. In 5 patients (50%), there was accompanying PAE and 3 patients had (30%) DVT history. Patients with BD and HSS tended to have multiple lesions than those with idiopathic origin. Accompanying PAE was observed in 2 (100%) of patients with HSS, 2 (50%) with BD, and 1 (25%) patient in the idiopathic group. A DVT history was recorded in 2 (100%) patients with HSS, 1 (25%) with BD. None of the patients in the idiopathic group had a DVT history. The only rupture was observed in the HSS group.

Conclusion: Vasculitic diseases lead to PPAA, including BD and HSS which are more likely to be associated with complications and additional morbid conditions than idiopathic processes.

Introduction

Pulmonary artery aneurysm (PAA) is a rare life-threatening condition that is defined as a diameter of the main pulmonary artery 29 mm and of interlobular artery 17 mm on computed tomography (CT) images.¹ Besides this, for the description of peripheral aneurysms, focal dilatation of the artery is used instead of the measurement of the diameter. Most of the PAAs are associated with trauma, infection, and vasculitis, while some cases may have an iatrogenic origin.² Hughes Stovin syndrome (HSS) and Behcet's disease (BD) are two important vasculitic diseases characterized by PAAs.³ HSS was first described in two patients presented with deep venous thrombosis (DVT) and segmental PAAs by English physicians; John Patterson Hughes and Peter George Ingle Stovin in 1959.⁴ The diagnosis is usually made based on CT, which also provides the sizes, number, location, and thrombosis/rupture features of the lesions.² The most common complaints are cough and hemoptysis. Massive hemoptysis with a mortality rate of more than 50% can occur after the rupture of the aneurysm.⁵ There are studies in the

literature on PAAs and their etiology^{2,3,5,6}; however, we could not find any studies discussing isolated peripheral pulmonary artery aneurysms (PPAA) with their etiologic causes. Except for a few studies published as case reports, we did not find any studies on HSS.⁷⁻¹¹ In this study, we aimed to present CT findings and etiological causes of patients with isolated PPAA.

Methods

Patients

In this single-centered retrospective study, images of the patients who underwent a contrast-enhanced thoracic CT scan between January 2013 and 2020 were reviewed on the hospital database. PPAA was defined as a focal dilatation of the lobar pulmonary arteries and their branches. Patients with main pulmonary trunk and right-left main PAA or fusiform dilatation of pulmonary arterial tree were excluded from the study. The patients with previous major thoracic trauma or surgery were also excluded from the study. The demographical data including age and gender, clinical symptoms, and medical history of co-morbid

*Corresponding Author: İlyas Dündar, Email: dundarilyas262@hotmail.com

© 2021 The Author(s). This is an open access article distributed under the terms of the Creative Commons Attribution License (<http://creativecommons.org/licenses/by/4.0/>), which permits unrestricted use, distribution, and reproduction in any medium, provided the original work is properly cited.

conditions including pulmonary embolism and DVT were investigated on the hospital database and clinical records. This retrospective observational study was approved by the institutional review board of our institution. No written informed consent could be obtained from reviewed subjects due to the retrospective nature of the investigation.

CT technique

Examinations were acquired using a multislice CT device with 16 detectors (Somatom Emotion 16-slice; CT 2012 E Siemens AG Berlin and Munchen-Germany). 70-100 mL (1-1.5 mL/kg) iodine contrast (omnipaque), was administrated to a preferably antecubital vein via an 18-20 gauge peripheral intravenous catheter by an automatic injector at a speed of 4-5 mL/s. Sections from the lower cervical to the upper abdominal level were obtained with a contrast agent, with the patients in the supine position during CT imaging. A region of interest was placed on the main pulmonary artery for triggering the scan acquisition after reached to the threshold. The CT parameters were 0.6-second gantry rotation, a 40-50 cm field of view, 120-140 kVp, 220-320 mA, and 3 mm slice thickness with 0.777 mm reconstruction.

Interpretation of the images

The features of the aneurysms including number, size, and location level were recorded. The size of the aneurysms was measured as the maximal diameter of

the aneurysmatic segment on axial or coronal/sagittal reformatted contrast-enhanced thorax CT images at mediastinal and lung parenchymal window settings. The images were interpreted by two radiologists with 5 and 8 years of experience in thoracic imaging regarding the presence of PAA. The radiologists were blinded to the clinical findings of the patients. Also, the aneurysms were evaluated for the presence of rupture and thrombosis. The final decision was reached with the consensus of them.

Statistical analysis

Descriptive statistics for studied variables (characteristics) were presented as the mean, standard deviation, minimum and maximum values. Statistical significance was set at 5%. SPSS (version 20) statistical program was used for all statistical computations.

Results

A total of 8432 thorax CT scans were reviewed. Finally, 4391 patients with contrast-enhanced CT whose medical history was available were included in this study. Among them, a total of 30 aneurysms were observed in 10 (0.2%) patients. Of these 10 patients, 7 (70.0%) were male and 3 (30.0%) were female with a mean age of 39.8 ± 21.0 (8-73) years. Four patients were diagnosed as BD (Figure 1), 2 were HSS (Figure 2) with the other clinical findings in our series. In remained four ones, no causative reason was identified, so they were described as idiopathic PPAA (Figure 3). The mean age was 32.75 ± 5.1 (27-39),

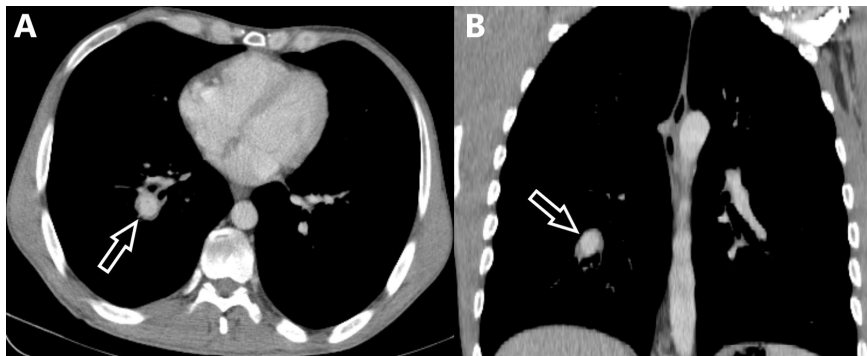


Figure 1. A solitary peripheral pulmonary aneurysm in the lower lobe of the right lung is observed in contrast-enhanced axial (A) and coronal (B) thorax CT in a 39-year-old male patient with a diagnosis of Behçet's disease.

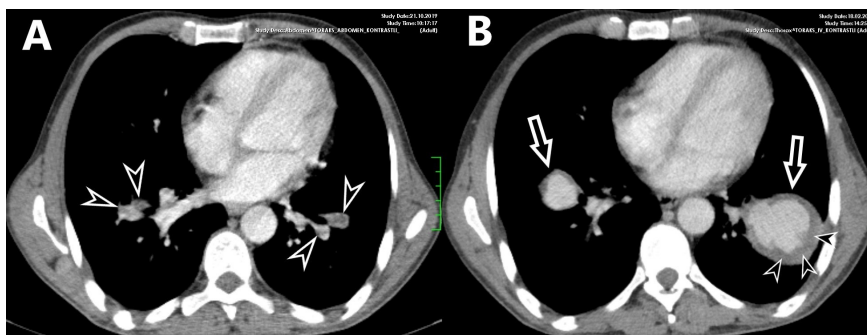


Figure 2. In a 58-year-old male patient diagnosed with Hughes Stovin Syndrome, filling defects (arrowheads) consistent with embolism are observed in the pulmonary artery lumen in both lower lobes of the lung on contrast-enhanced thorax CT (A). On the thorax CT taken approximately 3 months later, aneurysms developing after thrombus including partial thrombus areas (arrowheads) are observed in the same localizations (B).

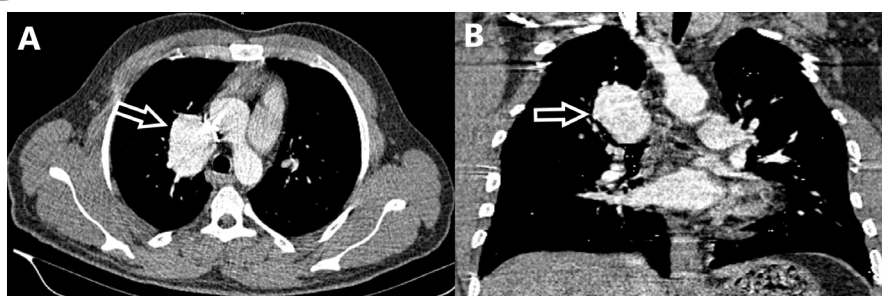


Figure 3. A solitary peripheral pulmonary aneurysm in the upper lobe of the right lung is observed in contrast-enhanced axial (A) and coronal (B) thorax CT in a 32-year-old male patient with idiopathic etiology

41.5 ± 23.3 (25-58), and 46 ± 31.6 (8-73) years in BD, HSS, and the idiopathic groups, respectively.

A solitary aneurysm was observed in 3 (30.0%) patients, 2 aneurysms in 2 patients (20.0%), 3 in 1 (10.0%), 4 in 1 (10.0%), 5 in 2 (20.0%) and 6 in 1 (10.0%) patient. The complaints in presentation were dyspnea (n=5, 50%),

chest pain (n= 3, 30%), cough (n= 1, 10%) and hemoptysis (n= 1, 10%). The demographical features and radiological findings are detailed in [Table 1](#).

The most common involved lobe was the lower lobes (right 8, left 8 aneurysms), while lesions were seen at least in the left upper lobe (4) and right upper lobe (4).

Table 1. Detailed demographic features and radiological findings of the patients

Variables	Behcet disease (n=4)	Hughes Stovin (n=2)	Idiopathic (n=4)	Total (n=10)	
Mean age	32.75 ± 5.1 (27-39)	41.5 ± 23.3 (25-58)	46 ± 31.6 (8-73)	39.8 ± 21.0 (8-73)	
Mean diameters (mm)	23.4 ± 9.9 (14-48)	30.3 ± 20.8 (14-62)	24.4 ± 14.4 (11-47)	25.4 ± 13.4 (11-62)	
Gender					
Female	2	-	1	3	30%
Male	2	2	3	7	70%
Multiplicity of aneurysms					
Solitary	1	-	2	3	30%
Multiple	3	2	2	7	70%
Total no of aneurysms	12	7	11	30	100%
Lobar distribution of the aneurysms					
Left upper lobe	4	-	-	4	13.3%
Left lower lobe	1	4	3	8	26.6%
Right upper lobe	3	-	1	4	13.3%
Right middle lobe	2	1	3	6	20.2%
Right lower lobe	2	2	4	8	26.6%
Side no of aneurysms					
Right	7	3	8	18	60%
Left	5	4	3	12	40%
Thrombus in the lumen					
Partial	7	5	3	15	50%
Subtotal	1	-	-	1	3.4%
Total	2	-	1	3	10%
No thrombus	2	2	7	11	36.6%
Accompanying pulmonary artery embolism					
Present	2	2	1	5	50%
Absent	2	-	3	5	50%
Deep venous thrombosis history					
Yes	1	2	0	3	30%
No	3	-	4	7	70%

Lower lobes involvement (16) was more than upper lobes (8) involvement. Also, right lung involvement (18) was 1.5 times more than left lung (12). The mean diameter of all aneurysms was 25.4 ± 13.4 (11-62) mm. The mean aneurysm diameters and lobar involvement of the groups are summarized in Table 1.

A partial (Figure 2B) or total thrombus (Figure 4E) was detected in 19 aneurysms (63.4%). The distribution of thrombus according to etiologies and type of thrombus is summarized in Table 1. In 5 patients (50%), a pulmonary embolism accompanied the aneurysm. Among 5 subjects with pulmonary embolism, 2 were diagnosed as BD (Figure 4), 2 as HSS, and the remaining one was idiopathic. The only patient in this study with ruptured PAA was a HSS case (Figure 5). In 3 patients (30%), there was a DVT history and the diagnosis in 2 of them was HSS. There was no history of DVT in the idiopathic group.

Discussion

PAA is a rare life-threatening entity that must be recognized promptly to be treated by emergent angiographic intervention or surgical procedures. PAAs may be associated with congenital conditions including heart defects (persistent ductus arteriosus, atrial/septal defects, valvular pathologies), connective tissue disorders (Ehler Danlos, Marfan Syndromes) or acquired disease including bacterial/fungal infections (endocarditis, tuberculosis, septic embolism), vasculitis (BD, HSS) pulmonary arterial hypertension, chronic pulmonary embolism, acute/chronic inflammatory lung diseases, neoplasms, iatrogenic (surgery, biopsy, catheterization) trauma and idiopathic.^{3,5} Most of these PAA causes have been described in the literature as pathologies that lead to aneurysms in the main pulmonary artery. In the literature, the pathologies causing isolated PPAA have not been

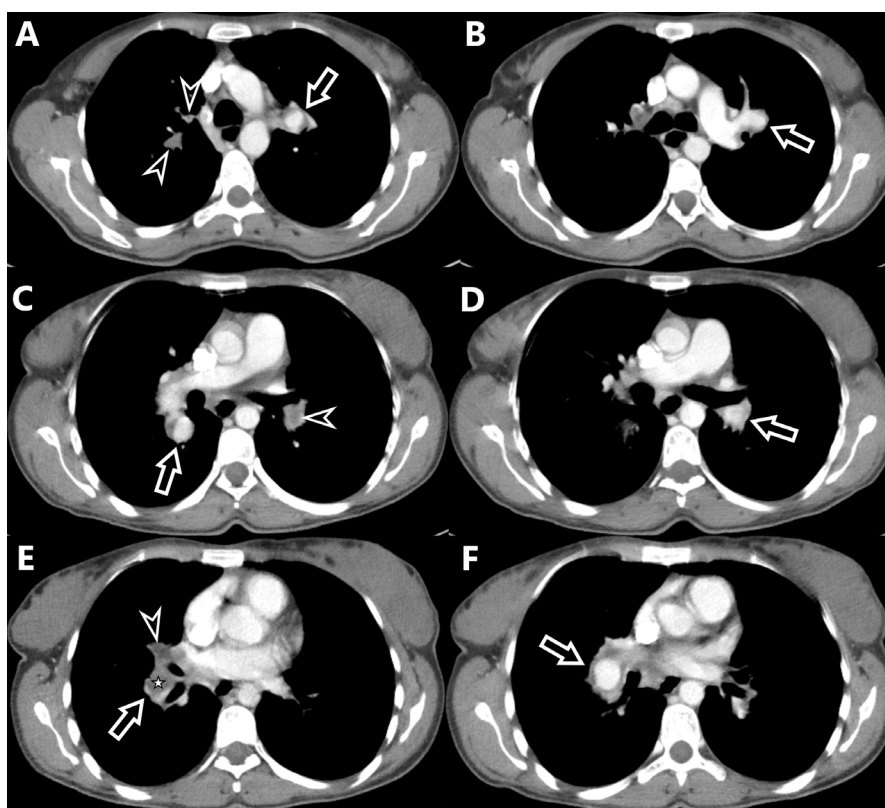


Figure 4. In a 34-year-old female patient diagnosed with Behçet's disease, a total of 6 peripheral pulmonary aneurysms (arrows), two in the upper lobe of the left lung (A,B), one in the left lower lobe (D), and three in the right lower lobe (C,E,F), are observed in contrast-enhanced thorax CT. Accompanying pulmonary embolisms (arrowheads) are seen in the pulmonary arteries in the upper lobe of the right lung (A) and the lower lobe of the left lung (C) and lower lobe of the right lung (E). In addition, a subtotal thrombus (star) is observed in the aneurysm lumen in the lower lobe of the right lung (E).

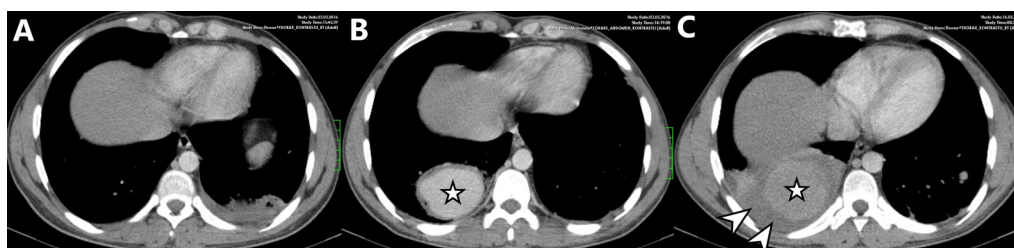


Figure 5. In a 25-year-old male patient diagnosed with Hughes Stovin syndrome, a newly formed aneurysm in the lower lobe of the right lung, which was not previously seen on contrast-enhanced thorax CT (A), is seen on CT taken 1.5 months later (star, B). In the CT taken 2 weeks later due to complaints of hemoptysis, rupture of the aneurysm and fluid densities (arrowheads) extending to the pleural space around the aneurysm are observed (C).

mentioned in detail. In this study, we aimed to discuss the CT findings of patients with isolated PPAA that can be life-threatening.

BD and HSS are the two acquired causes of PAA, which are believed as actually two different variants of a spectrum.^{10,12} BD is characterized by recurrent oral-genital ulcers, ocular lesions (mostly uveitis), cutaneous lesions, and vascular involvement.³ In HSS combination of peripheral venous thrombosis and multiple PAAs are seen. It is suggested that the inflammation begins as thrombophlebitis which progresses to the aneurysmatic dilatation and finally to rupture.¹¹ Consistent with previous data in the literature, BD was detected in 4 patients and HSS in 2 patients in our study. In remained 4 subjects, we could not identify a congenital or acquired etiology, so we stated them as idiopathic origin.³ In this study, the patients were most commonly in the 3-5 decades of life and their mean age was similar among the groups. The male/female ratio was 1 in BD and 3 in the idiopathic group. All two patients were male in the HSS group.

In a large series (n=47) investigating BD, the majority of PAAs were found to be located in the lower lobe.⁶ In our study, unlike the literature, most of the aneurysms we detected in BD were located in the upper lobe. We may have found these results due to the small number of cases. In studies published as case reports in the literature, the majority of aneurysms detected in HSS were located in the lower lobe.⁷⁻¹¹ In our study, consistent with the literature, no upper lobe involvement was detected in the HSS group, while 6 aneurysms in this group were in the lower lobes and the remained one was in the right middle lobe. The middle lob involvement rate was 2/12 in BD, 1/7 in HSS and 3/11 in the idiopathic group as the rates were similar. Right/left lung involvement rate (8/3) was highest in the idiopathic group.

PAAs may be seen in peripheral (subsegmental) areas.³ It was stated that 83.0% of the aneurysmatic dilatation of the pulmonary artery tree was found in the segmental or subsegmental branches. Also, a solitary PAA was identified in 83% of the patients.⁵ In contrast to previous studies, most of the aneurysms were multiple, while single aneurysm was detected in only 30.0% of the patients in our study. In half of our patients in the idiopathic group, a solitary lesion was detected, while multiple lesions were seen in all the patients with HSS.

The incidence of pulmonary thromboembolic events is higher in patients with PAA. The first suggested mechanism for this association is that pulmonary embolism results in pulmonary aneurysms by direct damage to the arterial wall.^{5,13} The second mechanism is the post-stenotic aneurysmal dilatation after and thromboembolic event.⁵ Consistent with these hypotheses, 19 of 30 (63.4%) aneurysm in this study contains various amount of thrombus in their lumen. Thrombus rates in the aneurysm lumen were higher in BD and HSS patients than in the idiopathic group (10/12 in BD, 5/7 in HSS, and 4/11

in the idiopathic group). Also, pulmonary embolism was present in 5 patients (50%) and a DVT history in 3 patients (33.3%). All these findings are frequently associated with vasculitis such as BD and HSS. In this study, in all the patients with HSS, a pulmonary artery embolism (PAE) was also detected. PAE was detected in 50% of the patients in BD and 25% of the patients in the idiopathic group. A DVT history was present in all the patients (100%) in HSS and 1 (25%) in BD. None of the patients in the idiopathic group had such a history. Therefore, in our series, the history of DVT was higher in HSS than in other groups.

The mortality rate of a ruptured PAA was reported between 50.0% and 100%. The death occurs most commonly secondary to aspiration and asphyxia due to bleeding. Also, hypotension and hypovolemic shock are the other mortality causes.¹⁴⁻¹⁶ In our study, there was only one patient (HSS group) with a PAA complicated by a rupture. The patient died because of massive hemoptysis despite aggressive treatment.

The major limitations of our study are retrospective design and relatively small patient numbers. Also, as we excluded the central aneurysms, we could not compare them with peripheral aneurysms.

Conclusion

Patients with PPAA must be further evaluated for the presence of pulmonary artery and DVT, which may be seen in vasculitis including BD and HSS. Furthermore, these patients must be closely followed because of the increased risk of rupture and thrombosis of the aneurysm.

Conflict of Interest

The authors declare that they have no conflict of interest.

Ethics Approval

This retrospective observational study was approved by the institutional review board of our institution with a number of 2020/04-15 on the 10.07.2020.

Authors' Contribution

ID and ET contributed to the design of the study. ID and ET

Study Highlights

What is current knowledge?

- In the literature, the pathologies causing isolated PPAA have not been mentioned together in detail.
- In previous studies, a solitary PAA was identified in most of the patients (80-90%).

What is new here?

- We discussed the CT findings of patients with isolated PPAA that can be life-threatening.
- In contrast to previous studies, most of the aneurysms were multiple, while single aneurysm was detected in only 30.0% of the patients in our study.

contributed to the literature review. ID and ET contributed to data interpretation. ID and ET drafted the first manuscript. All authors reviewed and approved the final version of the article.

Acknowledgements

We want to thank everyone who helped us during this study.

Funding

This research did not receive any specific grant from funding agencies in the public, commercial, or not-for-profit sectors.

References

1. Senbakkavaci O, Kaneko Y, Bartunek A, Brunner C, Kurkciyan E, Wunderbaldinger P, et al. Rupture and dissection in pulmonary artery aneurysms: incidence, cause, and treatment--review and case report. *J Thorac Cardiovasc Surg.* 2001;121(5):1006-8. doi: 10.1067/mtc.2001.112634.
2. Nguyen ET, Silva CI, Seely JM, Chong S, Lee KS, Müller NL. Pulmonary artery aneurysms and pseudoaneurysms in adults: findings at CT and radiography. *AJR Am J Roentgenol.* 2007;188(2):W126-34. doi: 10.2214/ajr.05.1652.
3. Park HS, Chamarthy MR, Lamus D, Saboo SS, Sutphin PD, Kalva SP. Pulmonary artery aneurysms: diagnosis & endovascular therapy. *Cardiovasc Diagn Ther.* 2018;8(3):350-61. doi: 10.21037/cdt.2018.04.01.
4. Hughes JP, Stovin PG. Segmental pulmonary artery aneurysms with peripheral venous thrombosis. *Br J Dis Chest.* 1959;53(1):19-27. doi: 10.1016/s0007-0971(59)80106-6.
5. Chen Y, Gilman MD, Humphrey KL, Salazar GM, Sharma A, Muniappan A, et al. Pulmonary artery pseudoaneurysms: clinical features and CT findings. *AJR Am J Roentgenol.* 2017;208(1):84-91. doi: 10.2214/ajr.16.16312.
6. Seyahi E, Melikoglu M, Akman C, Hamuryudan V, Ozer H, Hatemi G, et al. Pulmonary artery involvement and associated lung disease in Behçet disease: a series of 47 patients. *Medicine (Baltimore).* 2012;91(1):35-48. doi: 10.1097/MD.0b013e318242ff37.
7. Al-Jahdali H. Massive hemoptysis and deep venous thrombosis presenting in a woman with Hughes-Stovin syndrome: a case report. *J Med Case Rep.* 2010;4:109. doi: 10.1186/1752-1947-4-109.
8. Bennji SM, du Preez L, Griffith-Richards S, Smit DP, Rigby J, Koegelenberg CFN, et al. Recurrent pulmonary aneurysms: Hughes-Stovin syndrome on the spectrum of Behçet disease. *Chest.* 2017;152(5):e99-e103. doi: 10.1016/j.chest.2017.07.015.
9. Robinson C, Miller D, Will M, Dhaun N, Walker W. Hughes-Stovin syndrome: the diagnostic and therapeutic challenges of peripheral pulmonary artery aneurysms. *QJM.* 2018;111(10):729-30. doi: 10.1093/qjmed/hcy110.
10. Erkan D, Yazici Y, Sanders A, Trost D, Yazici H. Is Hughes-Stovin syndrome Behçet's disease? *Clin Exp Rheumatol.* 2004;22(4 Suppl 34):S64-8.
11. Ketchum ES, Zamanian RT, Fleischmann D. CT angiography of pulmonary artery aneurysms in Hughes-Stovin syndrome. *AJR Am J Roentgenol.* 2005;185(2):330-2. doi: 10.2214/ajr.185.2.01850330.
12. Uzun O, Erkan L, Akpolat I, Findik S, Atici AG, Akpolat T. Pulmonary involvement in Behçet's disease. *Respiration.* 2008;75(3):310-21. doi: 10.1159/000101954.
13. Sevitt S. Arterial wall lesions after pulmonary embolism, especially ruptures and aneurysms. *J Clin Pathol.* 1976;29(8):665-74. doi: 10.1136/jcp.29.8.665.
14. Poplasky MR, Rozenblit G, Rundback JH, Crea G, Maddineni S, Leonardo R. Swan-Ganz catheter-induced pulmonary artery pseudoaneurysm formation: three case reports and a review of the literature. *Chest.* 2001;120(6):2105-11. doi: 10.1378/chest.120.6.2105.
15. Jean-Baptiste E. Clinical assessment and management of massive hemoptysis. *Crit Care Med.* 2000;28(5):1642-7. doi: 10.1097/00003246-200005000-00066.
16. DeLima LG, Wynands JE, Bourke ME, Walley VM. Catheter-induced pulmonary artery false aneurysm and rupture: case report and review. *J Cardiothorac Vasc Anesth.* 1994;8(1):70-5. doi: 10.1016/1053-0770(94)90016-7.