

## Review



# Treating umbilical granuloma with topical corticosteroid: A systematic review and meta-analysis

 Indra Sandinirwan<sup>1\*</sup>, Henry Leo<sup>2</sup>, Hasanah Hasanah<sup>3</sup>, Permata Putri Karina<sup>4</sup>
<sup>1</sup>Department of Pediatrics, Sagaranten Hospital Sukabumi, West Java, Indonesia

<sup>2</sup>Department of Pediatrics, Bintuni Public Hospital, West Papua, Indonesia

<sup>3</sup>Emergency Department, Sekarwangi Public Hospital, West Java, Indonesia

<sup>4</sup>Infectious Disease Research Center/Pusat Studi Infeksi Klinis (PUSDI) of Universitas Padjadjaran, Bandung, West Java, Indonesia

## Article info

### Article History:

Received: 11 Nov. 2020

Accepted: 17 Jan. 2021

e-Published: 5 Aug. 2021

### Keywords:

- Discharge
- Granuloma
- Infants
- Lump
- Umbilicus

## Abstract

**Introduction:** Umbilical granuloma so far can be treated with surgery or with silver nitrate. In limited facilities, such as remote areas where the surgeons are limited, pharmacological therapy with silver nitrate or topical steroid can be administered. However, treatment with silver nitrate requires medical personnel and has unfavorable adverse effects if performed improperly. This review pointed to evaluate the effectiveness of topical steroids for treating umbilical granulomas, compared to silver nitrate therapy.

**Method:** The literature search was done in databases including PubMed, Embase, and Google Scholar. Literature selection was performed with limitations from 2000 to 2020 to ensure the novelty and limited to articles written in English with a target population of infants younger than 6 months. To retrieve the articles, topical corticosteroids, topical steroids, and umbilical granuloma were used as keywords.

**Results:** The findings from the included studies show similar sample characteristics. The study conducted by Brodsgaard et al. had an older mean sample age than the study of Ogawa et al. (53.4 vs. 31 days). The risk of topical steroid treatment failure on an individual study conducted by Brodsgaard et al. and Ogawa et al. was 3.0 (95%CI: 0.33–27.23) and 0.94 (95%CI: 0.40–2.21), respectively. Overall analysis, the risk of treatment failure was 1.09 (95%CI: 0.49–2.43), and there was no difference between the two interventions.

**Conclusions:** One of the umbilical granuloma treatment options that can be considered is topical steroids, such as clobetasol propionate 0.05% or betamethasone valerate 0.12%. Although topical steroids have a longer therapeutic healing time than silver nitrate, they benefit from a better safety profile. The non-inferiority study of topical steroids to silver nitrate has not been met yet.

## Introduction

Newborns can often present with several umbilical abnormalities, such as benign granulomas or other serious lesions due to persistent remnants with significant morbidities, if left unrecognized and untreated. In normal situations, the umbilical cord detaches within 7–10 days after birth, and the remaining granulation tissue of an umbilical stump typically disappears by the second to third week.<sup>1</sup> The persistence of granulation tissue after this time is common and quite alarming to new parents and often encountered by physicians in outpatient settings.

The number of epidemiological investigations regarding its prevalence and incidence is limited. The prevalence of umbilical granuloma has been accounted for 1 of every 500 infants.<sup>2</sup> Prompt treatment of umbilical granuloma consists of excision and cauterization by a pediatric or

general surgeon. Another method is the double ligation technique which can be done in outpatient settings.<sup>3</sup> In limited facilities, such as in remote areas where the number of surgeons is limited, or the patient's parents prefer more conservative measures, pharmacological therapy with silver nitrate can be given. Treating umbilical granulomas with silver nitrate is not uncommon. The therapeutic function was based on its caustic effects, and could be damaging if the agent contacted adjacent healthy tissues.<sup>2,4</sup> The purposes for seeking these alternative treatments are some inert cases for silver nitrate and the need of medical personnel for its application, the harm of periumbilical burn, the contraindications for ligations, and the silver nitrate unavailability.<sup>3,4</sup> Consequently, the primary goal of this systematic review is to evaluate the effectiveness of topical steroids for treating an umbilical granuloma

\*Corresponding Author: Indra Sandinirwan, Email: [indra14006@mail.unpad.ac.id](mailto:indra14006@mail.unpad.ac.id)

© 2021 The Author(s). This is an open access article distributed under the terms of the Creative Commons Attribution License (<http://creativecommons.org/licenses/by/4.0/>), which permits unrestricted use, distribution, and reproduction in any medium, provided the original work is properly cited.

compared to silver nitrate therapy, and describe the possible adverse reactions.

**Methods**

**Protocol and Registration**

This review was led according to the Preferred Reporting Items for Systematic Review and Meta-Analysis (PRISMA) Statement.<sup>5</sup> The protocol has been registered in The International Prospective Register of Systematic Reviews (PROSPERO) database (CRD42021230225).

**Eligibility Criteria**

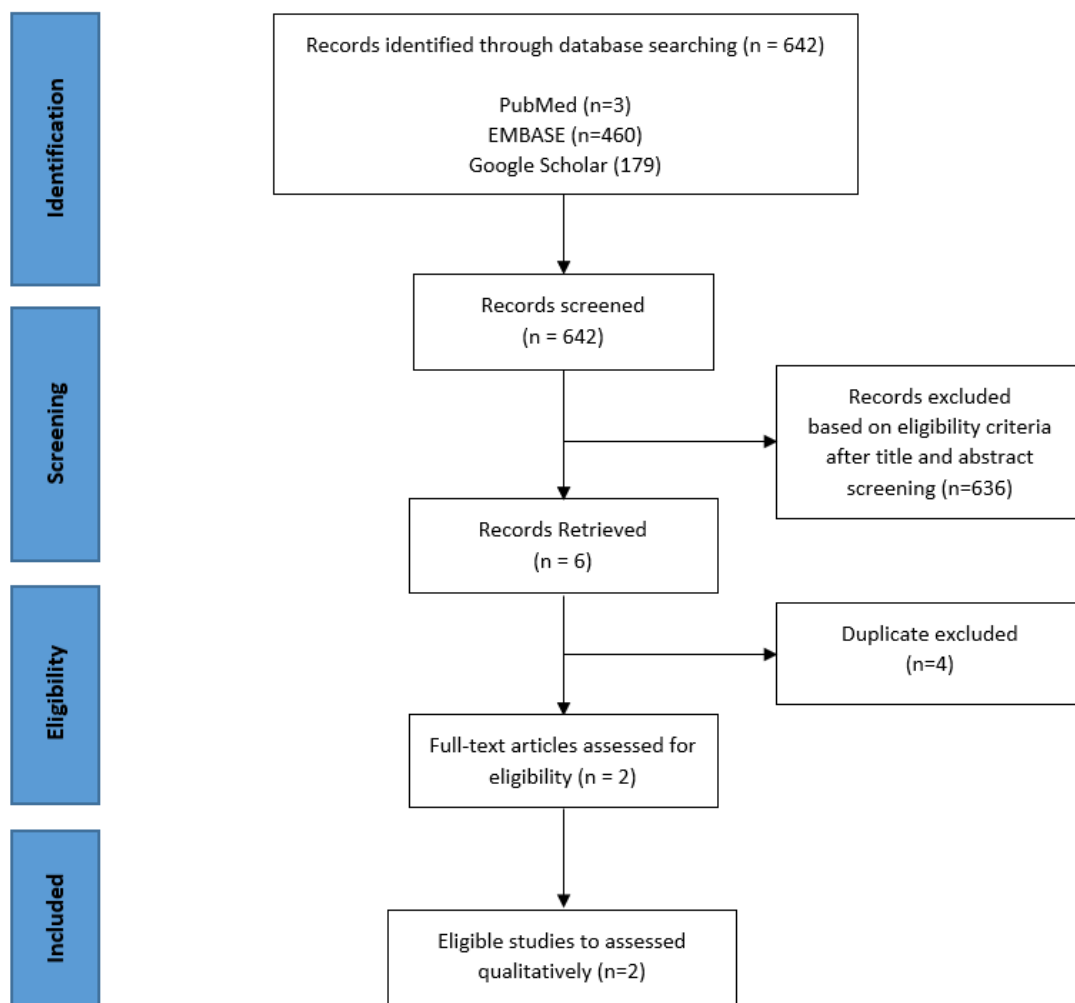
We included randomized controlled trials that evaluated the effectiveness of topical steroids for treating an umbilical granuloma in infants, treated as an inpatient or outpatient. The exclusion criteria were severe infection of the umbilicus or purulent granulomatous lesion.

**Search Strategy**

A literature search was conducted on 2–6 January, 2021, utilizing three databases: PubMed, Embase via Cochrane Library, and Google Scholar, by keywords presented in [Table 1](#). Four reviewers (IS, HL, HH, PPK) independently

**Table 1.** Search queries of the systematic review

Databases	Search Query	Hits
PubMed	((topical corticosteroid) OR (topical steroid)) AND (umbilical granuloma) Filters: Clinical Trial, from 2000/1/1 - 2020/12/31	3
Embase	"topical corticosteroid" OR "topical steroid" AND umbilical granuloma in Title Abstract Keyword; Filters: Trials, from 2000/1/1 - 2020/12/31	460
Google Scholar	Advanced search; with all of the words "topical", with the exact phrase "umbilical granuloma", Return articles dated between 2000–2020	179



**Figure 1.** Systematic flowchart for article selection

assessed the titles and abstracts for selection. The flow of study selection can be seen in Figure 1. Literature selection was performed with limitation in publication time from 2000 to 2020 and restricted to the articles in English. To facilitate article screening, we also used the Rayyan app for systematic review.<sup>6</sup>

### Data Collection

The information from each paper was extracted in a standardized form that consisted of the study setting (time, place, health care facility), study design, study population (patients' clinical characteristics and inclusion-exclusion criteria), and type of intervention (silver nitrate or topical steroid).

### Quality assessment and data synthesis

Four reviewers performed the quality appraisal of the studies (IS, HL, HH, PPK). The included studies were fundamentally evaluated using the Critical Appraisal Skills Programme (CASP) Randomised Controlled Trial Standard Checklist.<sup>7</sup> Any disparities of CASP-RCT score were discussed until it reached a decision. Good-quality studies were defined as studies fulfilling CASP-RCT score of least 9. Disagreements were settled by a third author.

Data were synthesized based on at least two high-quality studies with reliable finding. To be included in meta-analysis, studies had to provide effect measures such as risk ratios and confidence intervals, or provide crude data that allowed the calculation of a measure. The obtained data allow combining the risk ratio of treatment failure using RevMan version 5.4. The fixed-effects model was appropriate if the number of included studies was small, namely less than five. We also assume that all studies have a common effect size and very low heterogeneity. From a clinical perspective, the two studies had identical population characteristics, interventions, comparators, and outcomes. From a methodological point of view, the study design of both studies was also similar.<sup>8</sup>

### Results

The results of the literature search are presented in Table 1. Of 642 identified articles, we obtained 6 articles based

on title and abstract screening. After the duplicates were removed, the two articles carried out a further full-text assessment for eligibility. Two studies remained after full-text eligibility were the studies by Brødsgaard et al<sup>9</sup> and Ogawa et al<sup>10</sup>. The flow of systematic review is presented in Figure 1.

The result of baseline study characteristics is given in Table 2. All studies had level 1 of evidence-based on Oxford 2011 and were considered high-quality based on the CASP-RCT score. The summary of the critical appraisal is presented in Table 3. All studies used randomized controlled trial design to evaluate the effectiveness of topical steroids for treating umbilical granuloma compared with silver nitrate therapy. The study design in the RCT study conducted by Brødsgaard et al<sup>9</sup> and Ogawa et al<sup>10</sup> has been very good, with the latter one in a larger sample size. The RCT was not blinded since the differences in medication and tools could not possibly be hidden from caregivers.

A study by Brødsgaard et al randomized a total of 109 healthy and term newborns with postnatal age older than 3 weeks, no infection at the umbilicus, and no earlier treatment of umbilical granuloma, to one of three groups. Ninety-nine infants finished the allotted treatment. Group one (30) got standard treatment with silver nitrate, which was applied twice a week by a nurse in the outpatient clinic. Group two (30) were treated with clobetasol propionate cream (0.05%), which was applied twice a day at home (by parents). Group three (34) were treated with ethanol wipes by the parents at each nappy change. The latter was not included in the quantitative analysis. The assessed outcomes were the healing rate and complete resolution within one month of treatment. There were significant differences between the mean recuperating times in the three groups:  $12.9 \pm 7.7$  days in the silver nitrate group,  $17.4 \pm 8.7$  days in the clobetasol propionate group, and  $27.0 \pm 11$  days in the ethanol wipes group ( $P < 0.0001$ ). Three newborns developed mild abrasion and redness of the skin after the use of silver nitrate. After 30 days, the granuloma had resolved in 29 of 30 infants treated with silver nitrate, 27 of 30 infants treated with clobetasol propionate (0.05%), and 18 of 34 infants treated with

**Table 2.** The summary of baseline characteristics and outcome of the included studies.

Authors (Year)	Study location (Country)	Age at diagnosis (days, weeks)	Sample size		Findings (RR of the treatment failure)
			Total	M/F	
Brodsgaard et al	Denmark	53.41; 7.63	60	33/27	3.00 (0.33–27.23; $p = 0.33$ )
Ogawa et al	Japan	31.00; 4.42	204	116/88	0.94 (0.40–2.21; $p = 0.33$ )

**Table 3.** Quality assessment of the included studies using Critical Appraisal Skills Programme Randomised Controlled Trial Standard Checklist

Studies	Study Design Validity (3 Point)	Methodological Quality (3 Point)	Result (3 Point)	Applicability (2 Point)	Total Point
Brodsgaard et al	***	**	***	**	10
Ogawa et al	***	**	***	**	10

ethanol wipes ( $P < 0.0001$ ). Six cases treated with clobetasol propionate had mild hypopigmentation and skin atrophy but fully recovered during the follow-up. No side effects were observed among the newborns treated with ethanol wipes. Patients who were not responsive to clobetasol propionate and ethanol wipes for 30 days, underwent silver nitrate therapy, which resulted in resolution after an additional 13.2 days.<sup>9</sup>

A study conducted by Ogawa et al randomized 207 neonates with umbilical granuloma who were followed at 18 hospitals and 2 facilities from 2013 to 2016. Inclusion criteria were defined as 1–5 weeks of age, and a clinical diagnosis of an umbilical granuloma. Exclusion criteria were infection of the umbilicus, earlier treatment of umbilical granuloma, earlier systemic antibiotic treatment within 1 week, and earlier surgical measures. All patients meeting the inclusion criteria were randomized to receive either silver nitrate or topical steroid therapy. In the silver nitrate group (104), infants were treated once a week using silver nitrate, applied by a clean stick applicator (20% concentration) in a hospital or facility (by a pediatrician). Caregivers were encouraged to avoid infant baths for 24 hours in order to prevent the silver nitrate from causing periumbilical burns. In the topical steroid group (100), infants were applied with 0.12% betamethasone valerate cream to the lesion twice a day after bathing (by caregivers). No occlusive dressing was utilized, and no endeavor was made to dry the lesion. Caregivers were disclosed to avoid occlusive dressings to avoid the enhancement of medication absorption. All investigated infants attended the outpatient clinic once a week for a total of 3 weeks of follow-up. Infants were followed up until the lesion was decided to be recuperated. The primary outcome (healing rate after 14 days of therapy) was 87.6% (91/104) in the silver nitrate group and 82% (82/100) in the topical steroid group. Efficacy rates in the silver nitrate and topical steroid group were almost similar after 3 weeks of treatment with a cure rate of 90.4% (94/104) and 91% (91/100), respectively. No major unfavorable events happened during treatment in both groups.<sup>10</sup>

Recent studies showed that topical corticosteroids exert anti-inflammatory effects and reduce the number of fibroblasts. Through this mechanism, the administration

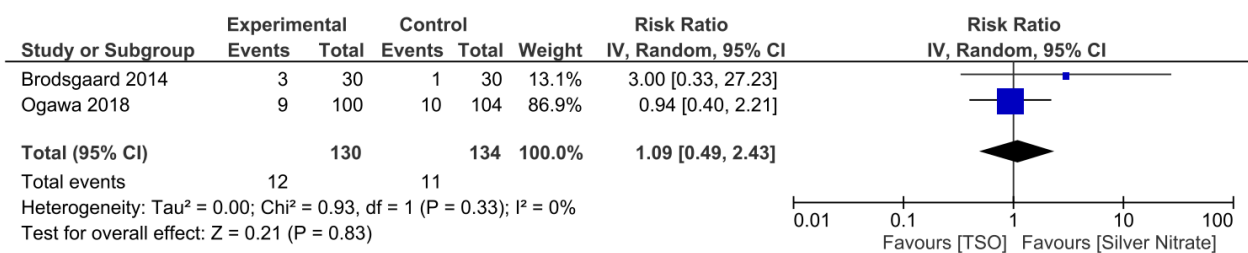
of topical steroids is beneficial for umbilical granuloma.<sup>11,12</sup> The forest plot of the risk of treatment failure among studies with pooled RR showed in Figure 2. Although treatment failure was small and the risk ratio and odds ratio values are quite close or similar, we still use the risk ratio in presenting the statistical analysis.<sup>13</sup> With combined analysis, the risk of treatment failure increased 1.09 (95%CI: 0.49–2.43) times in infants receiving topical steroid therapy – statistically not significant – indicating no difference between the two interventions. There was no evidence of heterogeneity (0%).

**Discussion**

An umbilical granuloma is characterized by a moist and pale red granulation tissue at the center of the umbilicus that occurs after detachment of the umbilical cord. The most common clinical findings are umbilical discharge and a round lump from the umbilicus. If the size of the granuloma is large enough, it can easily be seen from the outside without having to press the area around the umbilicus. The discharge is odorless, and it is not a discharge originating from the digestive or urinary tract. These granulomas do not contain nerve fibers, so they are painless unless complicated by infection.<sup>4,14</sup>

In physical assessment, umbilical granulomas are viewed as delicate, non-tender, and pale red lesions 1–10 mm in size at the base of the umbilicus. The granular surface can be recognized by a careful open eye inspection or using a dermoscopy (magnifier). Gentle pressure on the surrounding area and sometimes a surgical tweezer is required to see a small granuloma hidden in the umbilicus pit to ensure sufficient exposure. An otoscope can also be used to view small sessile umbilical granulomas.<sup>4,15</sup>

Inflammatory pathophysiology is suggested for granuloma formation. The umbilical cord typically dries and detached around one week after birth. The base surface then covered by a thin layer of skin, scar tissue formed, and the wound is healed within 12 to 14 days. The presence of saprophytic microorganisms hampers the separation of the cord and increases the possibility of infection by pathogenic microorganisms. Subclinical infection or incomplete epithelialization may follow in a moist granulating area at the base of the cord with either



**Figure 2.** Forest plot of risk of treatment failure among studies. The pooled RR was 1.09 (95% CI [0.49, 2.43]) and I<sup>2</sup> was 0%.

a mucoid or mucopurulent discharge.<sup>14</sup> A study between two groups of 1000 healthy newborns using different clamping techniques showed that 8% of newborns with conventional clamping techniques had granulomas, whereas in the proximal clamping technique, none of the newborns had granulomas.<sup>16</sup>

The umbilical granuloma is caused by an excessive fibroblast proliferation that surpasses the normal restorative process of the skin after the umbilical cord detachment. Brady et al showed histopathological findings for this lesion in a 2-month-old infant. They noted that umbilical granuloma predominately contains granulation tissue comprising fibroblasts, blood vessels, and inflammatory infiltrate in an edematous stroma.<sup>11</sup> Disruption of the balance between umbilical skin flora and saprophytic microorganisms affected the detachment of the cord by facilitating the invasion of pathologic microorganisms. These subclinical infections may prevent skin epithelization and trigger granuloma formation.<sup>4,15</sup> Umbilical granulomas can be treated surgically or non-surgically. Apart from surgical therapy, silver nitrate can also be given, which has been widely mentioned in the literature. The advantage of surgical therapy is a convenient process with results at speed, but it requires medical equipment, including the availability of a surgeon or pediatric surgeon. Treatment with silver nitrate also gives fast results, but there was an unfavorable adverse reaction in the form of burn if the agent contacted the healthy skin around the umbilicus.<sup>4,17</sup>

Both studies that have been conducted by Brødsgaard et al<sup>9</sup> and Ogawa et al<sup>10</sup> were good with their methodology and findings statistically. Meanwhile, in the sample size aspect, Ogawa et al had a larger sample size.<sup>10</sup> The outcome of the treatment was reported in all the studies. These studies also evaluated the unfavorable effects and the recurrence in the resulting follow-up. All studies evaluated the diagnosis of umbilical granuloma in outpatient settings.

Brødsgaard et al showed that silver nitrate and clobetasol propionate were better than ethanol, with faster healing times and higher cure rates. From the studies conducted, clobetasol propionate is as effective as silver nitrate and can be given by parents at home with minimal adverse effects.<sup>9</sup> The study was non-blinded. Caregivers in the intervention groups two and three were equipped with observation and treatment sheets documenting the time and frequency of home treatment.

Ogawa et al showed that the cure rate in the silver nitrate group was higher than in the betamethasone valerate group at two weeks of follow-up, but both agents gave almost the same cure rates at three weeks of follow-up. From the studies conducted, betamethasone valerate can be considered an alternative therapy to silver nitrate with the same effectiveness but with a better safety profile.<sup>10</sup> This study represents a large study size RCT to compare the effects of silver nitrate and topical corticosteroid for

neonatal umbilical granuloma. The present investigation did not demonstrate the non-inferiority of the topical corticosteroid group relative to the silver nitrate group in terms of the primary endpoint. Hence, the efficacy of topical corticosteroid was that acceptable as that of silver nitrate based on the results of the healing rate after three weeks of treatment, although non-inferiority has not been met.

Generally, the diagnosis of umbilical granuloma in the studies was obtained by clinical assessment and not supported by further investigations such as ultrasound or fistulography. Basically, the diagnosis of umbilical granuloma can be made by a high index of suspicion. However, in a small proportion of patients who did not respond to topical agents, the clinician must consider differential diagnoses such as an umbilical polyp or other omphalomesenteric duct remnants that require surgical measure. Topical agents like silver nitrate are necessarily administered by health professionals (pediatricians or nurses), while topical ointments such as clobetasol propionate or betamethasone valerate can be given by parents at home.

Although the diagnosis of umbilical granuloma is based on a high index of suspicion, the authors strongly recommend that clinicians carry out an in-depth evaluation of patients with umbilical granuloma because of other umbilical disorders that are very similar to umbilical granuloma and are unresponsive to topical treatment mentioned. One of the differential diagnoses that need to be considered is the umbilical polyp, because its manifestations are similar to that of umbilical granuloma. Umbilical polyp does not respond to silver nitrate administration and requires further evaluation such as ultrasonography or fistulography.<sup>1</sup> Fahmy et al recommended bipolar cautery for the management of umbilical granuloma but remain open to conservative management of this lesion.<sup>17</sup> Important note is that before beginning topical steroid therapy, the clinician must ensure that the lesion is truly an umbilical granuloma. An umbilical polyp is one of the differential diagnoses that need to be excluded first because umbilical polyp does not respond to this treatment and requires surgery.<sup>1,4</sup>

From a different perspective, several studies have been conducted to evaluate the effectiveness of table salt for treating umbilical granuloma. The study conducted by several authors<sup>18-22</sup> was a prospective experimental study that observed the effect of table salt on umbilical granuloma. An interesting study as an alternative to silver nitrate was the study conducted by Bagadia et al with a modified technique of holding the agent over the lesions for 24 hours.<sup>21</sup> There has been a systematic review that has been done by Haftu et al regarding the effectiveness of table salt for treating umbilical granulomas.<sup>23</sup> The mechanism of the salt when applied in the umbilical granuloma is thought to its a desiccant effect; the high concentration

of sodium ion in the area pulls water out of the cells and results in shrinkage and necrosis of the granulation tissue. However, this effect is not to cause harm to normal surrounding tissue when applied for a short treatment duration.<sup>18</sup> The thought of using the salt application for this granulomatous lesion was first reported by Schmitt (1972) and by Kesaree (1983).<sup>24,25</sup>

The limitations of this study emerge from the avoidance of non-English articles and unexplored gray literature. In addition, the results of the meta-analysis could provide better statistical significance if more randomized controlled trials were conducted. This gives an insight that future studies on the treatment of umbilical granulomas are still needed. Finally, this is the first systematic review evaluating the effectiveness of topical steroids for umbilical granulomas compared to silver nitrate as standard. The consequences of this investigation are important in the part of managing umbilical granulomas in a more conservative approach, especially in facilities with limited resources.

### Conclusion

The treatment choice for umbilical granuloma in highly equipped health facilities is highly recommended with surgery therapy, such as excision or the electrocautery method, which requires a surgeon or pediatric surgeon. Treatment with silver nitrate application gives excellent results, although it must be done by trained health personnel to avoid unfavorable side effects. Besides, there is also the unavailability issue of silver nitrate in some health centers. A topical treatment that can be administered to this granulomatous lesion is topical steroids. This conservative measure can be carried out when surgical or electrocautery is not available, such as in remote areas where the equipment is limited. Topical steroids ointment that can be used is clobetasol propionate and betamethasone valerate, given twice daily for about 3 to 4 weeks. Appropriate administration techniques are required to get desirable excellent therapeutic results.

### Conflict of Interest

The authors declare no conflict of interest in this study.

### Ethical Approval

Not applicable.

### Author's Contribution

Idea and study design: IS; Data collection and analysis: IS, HL, HH; Article draft writing: IS; Draft revision: PPK; Writing supervision: PPK. All authors have read the manuscript and have approved this submission.

### Acknowledgments

None.

### Funding

None.

### References

1. Muniraman H, Sardesai T, Sardesai S. Disorders of the umbilical cord. *Pediatr Rev.* 2018;39(7):332-41. doi: 10.1542/pir.2017-0202.
2. Assi AN, Kadem MK, Al Rubaee RJ, Atshan FG. Management of umbilical granuloma. *Thi-Qar Med J.* 2010;4(4):82-7.
3. Lotan G, Klin B, Efrati Y. Double-ligature: a treatment for pedunculated umbilical granulomas in children. *Am Fam Physician.* 2002;65(10):2067-8.
4. Karagüzel G, Aldemir H. Umbilical granuloma: modern understanding of etiopathogenesis, diagnosis, and management. *J Pediatr Neonatal Care.* 2016;4(3):00136. doi: 10.15406/jpnc.2016.04.00136.
5. Liberati A, Altman DG, Tetzlaff J, Mulrow C, Gøtzsche PC, Ioannidis JB, et al. The PRISMA statement for reporting systematic reviews and meta-analyses of studies that evaluate health care interventions: explanation and elaboration. *PLoS Med.* 2009;6(7):e1000100. doi: 10.1371/journal.pmed.1000100.
6. Ouzzani M, Hammady H, Fedorowicz Z, Elmagarmid A. Rayyan-a web and mobile app for systematic reviews. *Syst Rev.* 2016;5(1):210. doi: 10.1186/s13643-016-0384-4.
7. CASP. Critical Appraisal Skills Programme (CASP) Randomised Controlled Trial Checklist. 2020 [cited 2021 Jan 6]. Available from: <http://casp-uk.net/casp-tools-checklists>.
8. Tufanaru C, Munn Z, Stephenson M, Aromataris E. Fixed or random effects meta-analysis? common methodological issues in systematic reviews of effectiveness. *Int J Evid Based Healthc.* 2015;13(3):196-207. doi: 10.1097/xe.0000000000000065.
9. Brødsgaard A, Nielsen T, Mølgaard U, Pryds O, Pedersen P. Treating umbilical granuloma with topical clobetasol propionate cream at home is as effective as treating it with topical silver nitrate in the clinic. *Acta Paediatr.* 2015;104(2):174-7. doi: 10.1111/apa.12824.
10. Ogawa C, Sato Y, Suzuki C, Mano A, Tashiro A, Niwa T, et al. Treatment with silver nitrate versus topical steroid treatment for umbilical granuloma: a non-inferiority randomized control trial. *PLoS One.* 2018;13(2):e0192688. doi: 10.1371/journal.pone.0192688.
11. Brady M, Conway AB, Zaenglein AL, Helm KF. Umbilical granuloma in a 2-month-old patient: histopathology of a common clinical entity. *Am J Dermatopathol.* 2016;38(2):133-4. doi: 10.1097/dad.0000000000000429.
12. Ali MA, Thrower SL, Hanna SJ, Coulman SA, Birchall JC, Wong FS, et al. Topical steroid therapy induces pro-tolerogenic changes in Langerhans cells in human skin. *Immunology.* 2015;146(3):411-22. doi: 10.1111/imm.12518.
13. Ranganathan P, Aggarwal R, Pramesh CS. Common pitfalls in statistical analysis: odds versus risk. *Perspect Clin Res.* 2015;6(4):222-4. doi: 10.4103/2229-3485.167092.
14. Carlo WA, Ambalavanan N. The umbilicus. In: Nelson Textbook of Pediatrics. 20th ed. Elsevier; 2015. p. 890-1.
15. Ancer-Arellano J, Argenziano G, Villarreal-Martinez A, Cardenas-de la Garza JA, Villarreal-Villarreal CD, Ocampo-Candiani J. Dermoscopic findings of umbilical granuloma. *Pediatr Dermatol.* 2019;36(3):393-4. doi: 10.1111/pde.13774.
16. Al Siny FI, Al Mansouri NI, Al Zahrani FS. Proximal

- clamping of umbilical cord and prevention of umbilical granuloma (preliminary results). *J King Abdulaziz Univ Med Sci.* 2004;11:3-7. doi: 10.4197/med.11-1.1.
17. Fahmy M. Umbilical Granuloma (UG). In: *Umbilicus and Umbilical Cord.* Cham: Springer International Publishing; 2018. p. 133-43. doi: 10.1007/978-3-319-62383-2\_27.
  18. Hossain AZ, Hasan GZ, Islam KD. Therapeutic effect of common salt (table/cooking salt) on umbilical granuloma in infants. *Bangladesh J Child Health.* 2010;34(3):99-102. doi: 10.3329/bjch.v34i3.10360.
  19. Al Saleh AS. Therapeutic effect of common salt on umbilical granuloma in infants. *Int J Med Sci Public Health.* 2016;5(5):911-4. doi: 10.5455/ijmsph.2016.07012016312.
  20. Tripathi RK, Debnath PR, Shah S, Tripathi D, Debnath E. Therapeutic effect of table salt on umbilical granuloma in infants–North Indian experience. *IP Int J Med Paediatr Oncol.* 2018;4(2):77-9.
  21. Bagadia J, Jaiswal S, Bhalala KB, Poojary S. Pinch of salt: a modified technique to treat umbilical granuloma. *Pediatr Dermatol.* 2019;36(4):561-3. doi: 10.1111/pde.13851.
  22. Sharma CM, Aggarwal B, Chaudhary P. Role of common salt in the treatment of umbilical cord granuloma. *Int J Contemp Pediatrics.* 2020;7(7):1478-80.
  23. Haftu H, Bitew H, Gebrekidan A, Gebrearegay H. The outcome of salt treatment for umbilical granuloma: a systematic review. *Patient Prefer Adherence.* 2020;14:2085-92. doi: 10.2147/ppa.s283011.
  24. Kesaree N, Babu PS, Banapurmath CR, Krishnamurthy SN. Umbilical granuloma. *Indian Pediatr.* 1983;20(9):690-2.
  25. Daruwalla SB, Dhurat RS. A pinch of salt is all it takes! The novel use of table salt for the effective treatment of pyogenic granuloma. *J Am Acad Dermatol.* 2020;83(2):e107-e8. doi: 10.1016/j.jaad.2019.12.013.