

A 5-year-old Male with Fever and Dysuria

A 5-year-old boy was admitted in pediatric nephrology ward with fever and dysuria and vomiting from 3 days ago. He had a positive history of intermittent dribbling from 6 months ago. His laboratory tests revealed leukocyturia, positive urine culture in favor of urinary tract infection and normal renal function. Renal ultrasonography showed bilateral moderate to severe hydroureteronephrosis and mural thickening of bladder. He underwent voiding cystoureterogram (VCUG) (Figure 1).

What is your diagnosis

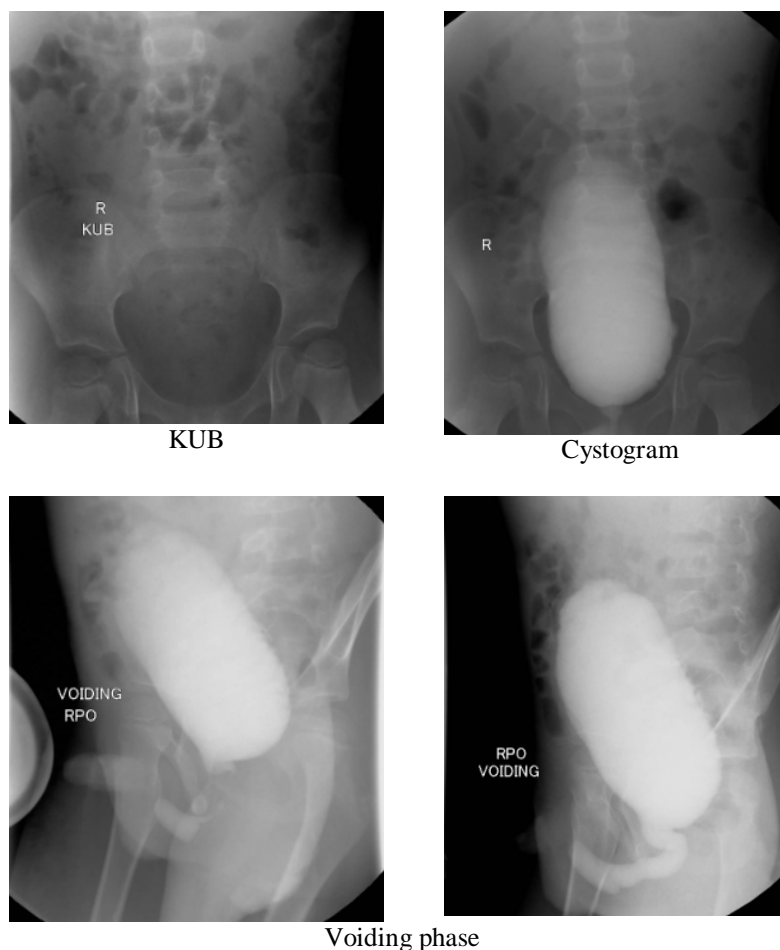


Figure 1. Voiding cystoureterogram of the patient

A 5-year-old Male with Fever and Dysuria

Maral Nikfarjam^{1*}, Mitra Khalili², Alieh Roosta¹, Masoumeh Mohkam¹

¹Pediatric Nephrology Research Center, Research Institute for Children Health, Shahid Beheshti University of Medical Sciences, Tehran, Iran

²Radiology Department, Shahid Beheshti University of Medical Sciences, Tehran, Iran

*Corresponding Author

Dr Maral Nikfarjam

Email: maralnikfarjam@gmail.com

In VCUG Bladder is vertically located with several diverticula and sacculations. Urethral diverticula 27X10 mm is seen in inferior aspect of bulbar urethra with evidence of obstruction which is compatible with anterior urethral valve and urethral diverticula.

The anterior urethral valve (AUV) is a rare congenital anomaly that causes lower urinary tract obstruction in children. It can occur as an isolated entity or in association with a proximal diverticulum. Forty percent of the AUVs are located in the bulbar urethra, 30% at the penoscrotal junction, and 30% in the pendulous urethra. The clinical manifestation is highly variable and depends on age of the patient and degree of obstruction. It may present with severe obstruction and bilateral severe hydrouretero-nephrosis, end-stage renal disease, and even bladder rupture. VCUG is the diagnostic modality of choice in the diagnosis of anterior urethral valve. It can reveal a dilated or elongated posterior urethra, a dilatation of the anterior urethra, a thickened trabeculated bladder, a hypertrophied bladder neck, VUR, and urethral diverticula. The urethra appears dilated proximal to the valve and narrowed distal to it on VCUG. VCUG may also reveal an associated anomaly in addition to demonstrating the valve. One-third of cases have shown VUR and upper tract deterioration was present in one-half of cases.

References:

1. Mali VP, Prabhakaran K, Loh DS. Anterior urethral valves. *Asian J Surg.* 2006;29:165–69
2. Zia-ul-Miraj M. Anterior urethral valves: a rare cause of infravesical obstruction in children. *J Pediatr Surg.* 2000;35:556–58.
3. Firlit CF, King LR. Anterior urethral valves in children. *J Urol.* 1972;108:972–75
4. Burstein JD, Firlit CF. Anterior urethra. In: Kelalis PP, King LR, Belman AB, editors. *Clinical Pediatric Urology.* Philadelphia: PA: WB Saunders; 1985. pp. 558–61