

Histopathological Pattern of Difficult Childhood Nephrotic Syndrome in a Tertiary Care Centre, Bangladesh

Ranjit Ranjan Roy*,
Farhana Rahman,
Jahanara Arju,
Jakia Sultana,
Agomoni Chaki,
Amina Akter,
Abdullah-Al Mamun,
Tahmina Jesmin,
Sayed Saimul Haque,
Afroza Begum,
Golam Muin Uddin,
Habibur Rahman

Department of Pediatric
Nephrology, Bangabandhu
Sheikh Mujib Medical
University, Dhaka.

***Corresponding Author**

Dr. Ranjit Ranjan Roy,
Email:
ranjit.bsmmu@gmail.com

Received: July, 2019

Revised: August, 2019

Accepted: August, 2019

Abstract

Background and Aim: The aim of this study was to explore the spectrum of histopathology in children who underwent a renal biopsy for difficult NS in a tertiary care pediatric nephrology center.

Methods: This prospective observational study was conducted in the Pediatric Nephrology Department of Bangabandhu Sheikh Mujib Medical University, Dhaka, Bangladesh from January 2011 to July 2018. Patients who presented with difficult patterns of nephrotic syndrome and underwent a renal biopsy were enrolled in this study.

Results: A total of 140 patients were recruited in this study. The patients with steroid resistance nephrotic syndrome (SRNS) and nephrotic syndrome with atypical presentation underwent a renal biopsy; a good number of atypical NS cases were steroid dependent nephrotic syndrome (SDNS). They were grouped into Group A (SRNS), Group B (SDNS) and Group C (nephrotic syndrome with atypical presentation). In patients with SDNS, minimal change disease (MCD) (51.3%) was the most common histological pattern followed by mesangioproliferative glomerulonephritis (MesPGN) (33.3%); whereas MesPGN was the commonest histological pattern in SRNS (56.8%) and nephrotic syndrome with atypical presentation (54.7%) followed by MCD and focal segmental glomerulosclerosis (FSGS). Most of the patients responded to immunosuppressive therapy. In SRNS, a partial response was achieved in 18.9% and chronic kidney diseases (CKD) occurred in 16.2% of the cases. In comparison, 10.9% of the patients with nephrotic syndrome with atypical presentation achieved partial response and 7.8% developed CKD, which were not statistically significant. In addition, 5.4% of the patients with SRNS died.

Conclusion: Mesangioproliferative glomerulonephritis was the most common histopathological diagnosis in patients with SRNS and nephrotic syndrome atypical presentation in our population. MCD was predominant in SDNS cases.

Keywords: Nephrotic Syndrome; Focal Segmental Glomerulosclerosis; Chronic kidney disease (CDK); Child.

Conflict of interest: The authors declare no conflict of interest.

Please cite this article as: Roy RR, Rahman F, Arju J, Sultana J, Chaki A, Akter A, Mamun A Al, Jesmin T, Haque SS, Begum A, Uddin GM, Rahman H. Histopathological Pattern of Difficult Childhood Nephrotic Syndrome in a Tertiary Care Centre, Bangladesh. *J Ped Nephrol* 2019;7(3):1-7. <https://doi.org/10.22037/jpn.v7i3.26397>

Introduction

Nephrotic syndrome (NS) is the most common childhood kidney disease. Idiopathic nephrotic syndrome affects 2 to 7 new children per 100,000 per year in Western countries with a prevalence of 15 per 100,000 under 16 years of age (1). In Asia, the prevalence of MS is 9-16 cases in 100,000 children per year (2).

The disease mechanism is poorly understood. It is believed that the mechanisms underlying the disorder include different genetic and pathologic variants with polymorphic podocyte injury as a unifying feature (3-4). Prednisolone is the cornerstone of treatment for INS. However, 10% to 20% of these patients do not respond to steroids

(steroid-resistant) and a significant portion of steroid-sensitive patients are likely to experience frequent relapses or become steroid-dependent. NS patients who are labeled as the frequent relapser, steroid-dependent, or steroid resistant are referred to as difficult nephrotic syndrome. Renal biopsy is an important tool to assess the histological pattern of difficult nephrotic syndrome and thus helps to predict the prognosis, treatment intensification, and treatment outcome.

The histopathological features of NS have been studied in different regions of the world with a wide variation in the histopathological distribution. However, the histological pattern of childhood NS has changed; the incidence of focal segmental glomerulosclerosis seems to be increasing and the incidence of membranoproliferative glomerulonephritis (MPGN) is decreasing (5). Recent recommendations for kidney biopsy in children with NS include cases with a high index of suspicion for an underlying pathology other than minimal change disease (MCD); however, the exact indications are not yet well defined (6). In fact, in a number of case series of children with difficult NS who underwent kidney biopsy, MCD was found to be the most common pathological diagnosis (7). Our previous study (8) found that mesangioproliferative glomerulonephritis (MesPGN) was the most common histopathological variant of difficult NS. However, histopathological patterns are changing with time. Therefore, we prospectively analyzed the spectrum of clinical indications, histopathological patterns, and their clinicopathological associations among children who underwent renal biopsy in our center. The aim of this study was to explore the spectrum of histopathology in children who underwent a renal biopsy in our tertiary care pediatric nephrology center and to correlate their pre-biopsy clinical course with histological findings.

Methods

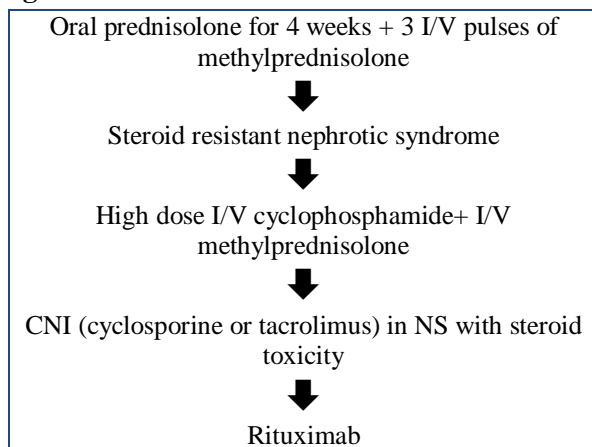
A total of 140 children were included in this prospective observational study conducted in the Department of Pediatric Nephrology, Bangabandhu Sheikh Mujib Medical University (BSMMU), Dhaka, Bangladesh. Children who were admitted between January 2015 and July 2018 with steroid resistant NS (SRNS), NS with atypical presentation and congenital nephrotic syndrome were included in this study before giving the 3rd line drug in NS.

Biopsy was deferred in patients with bleeding diathesis, uncontrolled hypertension, pyelonephritis, and solitary kidney. Patients who had a biopsy for suspected lupus nephritis and other vasculitis were excluded from the study. Patients and parents who refused to participate were excluded from the study.

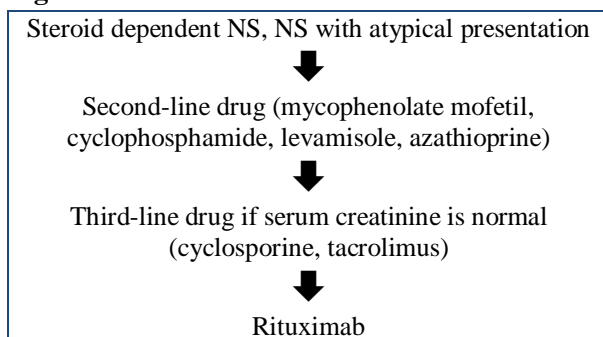
Before renal biopsy, a full blood count, coagulation profile (prothrombin time, activated partial thromboplastin time), blood grouping and cross-matching, HBsAg screening test, and ultrasonography of the kidney, ureter, and bladder (KUB) with surface marking and distance from the skin to lower pole of the left kidney were performed. Written informed consent was obtained from parents. Patients were kept nil per os (nothing by mouth) for 4h, and the bowel and bladder were emptied before biopsy. Biopsies were carried out in a well-equipped procedure room in the department. All patients were sedated with midazolam intravenous injection (0.3 mg/kg/dose) 10 min before the procedure. An IV cannula was inserted for emergency medication. Renal biopsy was done from the lower pole of the left kidney using an appropriate sized spring loaded automated disposable biopsy gun under strict aseptic precaution using local anesthesia by 2% lignocaine. The specimen was visually checked for tissue adequacy. Two tissue cores were obtained: one of them was kept in normal saline for immunofluorescence microscopy and another one in formalin for light microscopy. Pressure dressing was applied with a binder. Tissues were labeled and sent to the Department of Pathology, Bangabandhu Sheikh Mujib Medical University (BSMMU) for histopathological examination. All the specimens were examined by a senior pathologist. After biopsy, all the patients were followed up carefully by pulse, blood pressure, respiratory rate, urine output, hematuria, local bleeding, and features of any other complication such as vasovagal shock and pain for 24 hours. The pathological reports were analyzed and studied, which included gross examination, light microscopic studies, and immunofluorescence studies. Clinical records were studied from the questionnaire regarding clinical, physical examination, pre-biopsy diagnosis, indication for biopsy, tissue adequacy, histopathological diagnosis, treatment alteration according to histopathological diagnosis, biopsy complications, and final outcome.

The patients were treated one of the following treatment algorithms:

Algorithm 1:



Algorithm 2:



Definitions

Difficult nephrotic syndrome: NS associated with frequent relapses, steroid dependence, or steroid resistance.

Steroid resistant nephrotic syndrome: Failure to achieve complete remission after 4 weeks of oral corticosteroid therapy plus three pulses of intravenous methylprednisolone.

Steroid dependent nephrotic syndrome: Two or more relapses within 2 weeks of discontinuation of oral prednisolone or being on an alternate daily prednisolone regimen

Atypical nephrotic syndrome: Nephrotic syndrome manifesting with an age of onset of 3 months to 1 year or >15 years, persistent hematuria, hypertension, renal insufficiency and hypocomplementemia (C3 <0.9 mg/dL).

Response: lack of proteinuria, normal serum albumin (35-45 g/L).

Partial response: Occasional trace /1+ proteinuria with serum albumin between 25-35 g/L.

No response: Continued proteinuria without any remission and serum albumin < 25 g/L.

Statistical analysis:

All values are presented as mean \pm standard deviation. The SPSS 9.0 was used for statistical analysis. The Outcome was evaluated in terms of response, partial response, no response. The results were analyzed for their statistical significance using Students test for continuous variables and chi-square test for discrete variables. Statistical significance was defined as a $p \leq 0.05$.

Results

A total of 140 children were enrolled in this study, of whom 81 were boys and 59 were girls. The male to female ratio was 1.37:1. The mean age at biopsy was 7.0 years, ranging from 7 months to 17 years.

Demographic and laboratory parameters are summarized in Table 1. In the atypical presentation group, about 93.8% of the patient presented with hypertension and 78.1% had hematuria, whereas about 75.7% of the patients had hypertension and 32.4% had hematuria in the SRNS group. About 31.3% and 27% of the patients had low C3 in atypical presentation and SRNS group, respectively. The serum creatinine level was significantly higher in the atypical presentation group (40.6%) compared to the other two groups.

On histopathological findings, the median number of glomeruli per core was 13. In 4 (2.8%) cases, the sample revealed no glomeruli; hence, a histopathological diagnosis could not be made.

In patients with SDNS, MCD (51.3%) was the most common histological pattern followed by MesPGN (33.3%). MesPGN was the commonest histological pattern in SRNS (56.8%) and atypical presentation (54.7%) followed by MCD and FSGS (Table 2).

Figure 1 summarizes the histological pattern in various types of nephrotic syndrome.

Post-biopsy gross hematuria was noted in 78% of the cases, which was mild and resolved within 24 hours. Hematoma developed in 4.8% of the cases, which resolved spontaneously.

One hundred percent of the patients had mild discomfort in the form of local pain. There was no mortality or renal loss.

Table I: Demographic and laboratory parameters of different groups of nephrotic syndrome

Variables	Groups	Group A (n=37)	Group B (n=39)	Group C (n=64)	p-value			
					AvsBvsC	AvsB	BvsC	CvsA
Clinical								
Age at diagnosis (years)		7.8±2.4	4.0±2.0	10.0±3.0	<0.001	<0.001	<0.001	<0.001
Hematuria		12 (32.4)	0 (0.0)	50 (78.1)	<0.001	<0.001	<0.001	<0.001
Hypertension		28 (75.7)	25 (64.1)	60 (93.8)	<0.001	0.273	<0.001	0.013
Laboratory findings								
Low C ₃		10 (27.0)	0 (0.0)	20 (31.3)	<0.001	<0.001	<0.001	0.654
24hr UTP		3.4±0.6	2.3±0.6	1.8±0.5	<0.001	<0.001	<0.001	<0.001
Raised creatinine		6 (16.2)	0 (0.0)	26 (40.6)	<0.001	0.010	<0.001	0.011

Group A: SRNS, Group B: SDNS, Group C: Atypical presentation, SRNS: Steroid Resistant Nephrotic Syndrome, SDNS: Steroid Dependent Nephrotic Syndrome, UTP: Urinary Total Protein, C₃: Complement 3.

Table 2: Histological pattern in different groups of nephrotic syndrome

Variables	Groups	Group A n=37(%)	Group B n=37(%)	Group C n=62(%)
Histological pattern				
Mes PGN		21 (56.8)	13 (33.3)	35 (54.7)
MCD		7 (18.9)	20 (51.3)	16 (25.0)
MPGN		2 (5.4)	2 (5.1)	4 (6.3)
FSGS		6 (16.2)	1 (2.6)	6 (9.4)
Membranous		1 (2.7)	1 (2.6)	1 (1.6)

Group A: SRNS, Group B: SDNS, Group C: Atypical presentation
MCD: Minimal change disease, Mes PGN: Mesangial proliferative glomerulonephritis, MPGN: Membrano proliferative glomerulonephritis, FSGS: Focal segmental glomerulosclerosis, NS: Nephrotic syndrome.

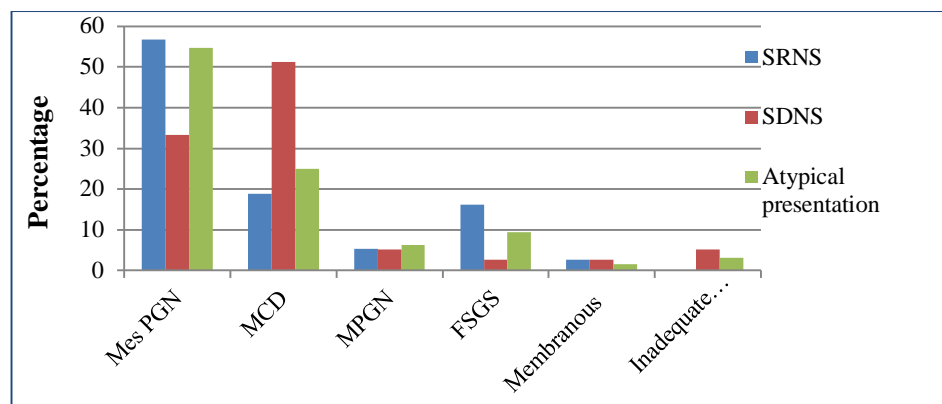


Figure 1. Histopathological pattern in different clinical types of nephrotic syndrome.

The outcome depended on the nature and extent of the disease, time of presentation, and features of presentation. In our study, most of the patients responded to immunosuppressive therapy. In the SRNS group, partial response was achieved in 18.9% and CKD occurred in 16.2% of the cases. In patients suffering from NS with atypical presentation, 10.9% achieved partial response and 7.8% developed CKD, which was not statistically

significant. Furthermore, 5.4% of the patients with SRNS died (Table 3). Overall, 79.2% of the NS patients responded to immunosuppressive therapy, 11.4% achieved partial remission, 7.8% developed CKD, and 1.4% died (Figure 3).

Table 3: Outcome in different groups of nephrotic syndrome

Variables	Groups			p-value			
	Group A (n=37)	Group B (n=39)	Group C (n=64)	AvsBvsC	AvsB	BvsC	CvsA
Outcome							
Response	22 (59.5)	37 (94.9)	52 (81.3)	<0.001	<0.001	0.050	0.017
Partial response	7 (18.9)	2 (5.1)	7 (10.9)	0.165	0.082	0.477	0.263
No response/CKD	6 (16.2)	0 (0.0)	5 (7.8)	0.031	0.010	0.153	0.319
Expired	2 (5.4)	0 (0.0)	0 (0.0)	0.059	0.233	1.000	0.131

Group A: SRNS, Group B: SDNS, Group C: Atypical presentation, CKD: Chronic Kidney Disease.

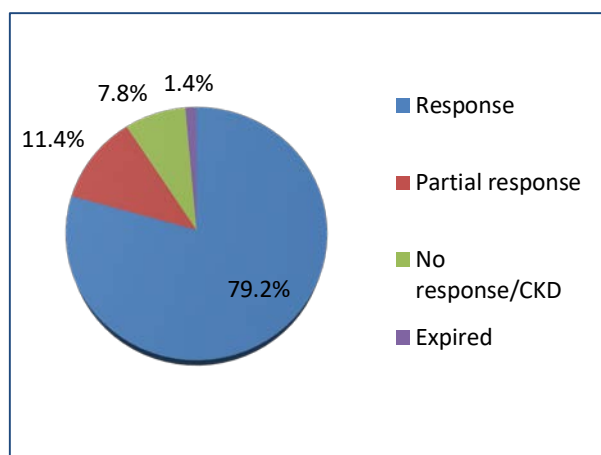


Figure 3. Outcome of nephrotic syndrome.

Discussion

Since the introduction of renal biopsy in 1934 by Ball, it has been widely used throughout the world for diagnostic and prognostic evaluation of various nephropathies, especially since 1950s (9-11). It is mostly necessary to identify various patterns of renal diseases with similar presentations. The presentation, pattern, and prevalence of renal diseases vary in different geographical regions of the world and are also changing in different countries (12).

This study described the underlying histopathological spectrum in children who presented with difficult nephrotic syndrome. There was a male preponderance (1.37:1) and the mean

age at the time of biopsy was seven years, which was similar to studies from Egypt (9.2 years), Jordan (7.5 years), and Sudan (8.7 years) (13-15). In our study, the only presentation in the SDNS group with proteinuria, whereas patients with SRNS and atypical presentation mostly presented with hypertension followed by proteinuria and hematuria. This is in contrast to a study by Gulatai et al. in which only microscopic hematuria was significantly more common in the non-MCD group (16). A significant portion of the patients in the SRNS and atypical presentation groups had low C3 and high creatinine levels in our study.

There may be regional differences in the prevalence of renal histology. Although there is a general presumption that the most common histopathological lesion in children with NS is MCD as reported in the studies performed in the Czech Republic, Spain, Italy, and Korea (17-20), the most frequent diagnosis was MesPGN in our study as well as studies conducted in Turkey and Saudi Arabia (21, 22). One study found that NS was mostly caused by MCD in New Zealand (37%) while the proportion of MesPGN was also high (23%), especially in Maori children (23). MCD was found in 30.7% of the cases in our study. The low incidence can be explained by the low rate of renal biopsy in cases showing a good response to steroid therapy. FSGS has been reported as the most common cause of NS in two different studies conducted in India (24, 25). In our study, MesPGN

was the most common disease in the SRNS (56.8%) and atypical presentation groups (54.7%), while MCD was predominant in patients with SDNS and we did not observe any higher incidence of FSGS as reported in other studies. The rate of biopsy proven FSGS is higher in African – American children (26).

The overall frequency of complications associated with renal biopsy ranges from 5% to 13% (27, 28). The main complications are pain at biopsy site, hematuria (microscopic and gross), and hematoma. In our study, 100% of the patient had mild discomfort in the form of local pain and post-biopsy gross hematuria was noted in 78% and hematoma was seen in 4.8% of the cases, which resolved spontaneously. There was no mortality, renal loss, or other serious complications in our study as reported in a previous study. There was retroperitoneal hemorrhage in 2 patients who both required a single blood transfusion.

The outcome depended on the disease nature and extent, time of presentation, and features of presentation. In our study, most of the patients responded to immunosuppressive therapy. Partial response was achieved in 18.9% and CKD occurred in 16.2% of the cases in the SRNS group. In patients suffering from NS with atypical presentation, 10.9% achieved partial response and 7.8% developed CKD. Furthermore, 5.4% of the patients with SRNS died.

The possible differences between the results of our study and those of other studies do not reflect different renal morbidities. On the contrary, we believe that our different approach in evaluating renal biopsy indications resulted in a different distribution of kidney diseases.

A limitation of our study was the lack of electron microscopy evaluation of biopsies, particularly the subtype of MPGN. Nevertheless, our study provided a picture of prevalent histopathological patterns of NS in our pediatric patients.

Conclusion

It can be concluded that MesPGN constitutes the major share of the histopathological patterns of SRNS and NS with atypical presentation. MCD was predominant in SDNS patients. This report from Bangladesh provides data on the frequency of the histopathological patterns of NS in patient undergoing renal biopsies and intends to serve as a

source of information for pediatric nephrologists in Bangladesh as well as other parts of the world.

Acknowledgements

Not declared.

Conflict of Interest

The authors declare no conflicts of interest.

Financial Support

Not declared.

References

1. McEnery PT, Strife CF. Nephrotic syndrome in childhood. Management and treatment in patients with minimal change disease, mesangial proliferation, or focal glomerulosclerosis. *Pediatr Clin North Am* 1982;29:875-94.
2. Sharples PM, Poulton J, White RHR. Steroid responsive nephritic syndrome is more common in Asia. *Arch Dis Child* 1985;60:1139-48.
3. Korbet SM. Primary focal segmental glomerulosclerosis. *J Am Soc Nephrol* 1998;9:1333-40.
4. McAdams AJ, Valentini RP, Welch TR. The nonspecificity of focal segmental glomerulosclerosis. The defining characteristics of primary focal glomerulosclerosis, mesangial proliferation and minimal change. *Medicine (Baltimore)* 1997;76:42-52.
5. Ibrahim Seif E, Abdel-Salam Ibrahim E, Galal Elhefnawy N, Ibrahim Salman M. Histological patterns of idiopathic steroid resistant nephrotic syndrome in Egyptian children: A single center study. *J Nephropathol* 2013;2:53-60.
6. Kidney Disease (2012) Improving global outcomes (KDIGO) glomerulonephritis work group. KDIGO clinical practice guideline for glomerulonephritis. *Kidney Int Suppl* 2:139–274
7. Kumar J, Gulati S, Sharma AP, Sharma RK, Gupta RK (2003) Histopathological spectrum of childhood nephrotic syndrome in Indian children. *Pediatr Nephrol* 18:657–60.
8. Roy RR, Al Mamun A, Shamsul Haque S M, Muinuddin G, Rahman M. Role of renal biopsy in managing pediatric renal diseases: A midterm analysis of a series at Bangabandhu Sheikh Mujib Medical University, Dhaka, Bangladesh. *Saudi J Kidney Dis Transpl(serial online)*2017;28(1):125-32.
9. Edelmann CM, Churg J, Gerber MA, Travis LB (1992) Renal biopsy indications : technique & interpretation. In : Edelmann CM , (ed) *Pediatric kidney disease*, 2nd edn. Little Brown & Company, Boston, pp.499-527.
10. Rance CP (1990) When should renal biopsy be done ? *Clin Pediatr* 29;653-664.
11. Vassiliades VG, Bernardino ME (1991) Percutaneous renal & adrenal biopsies. *Cardiovasc Intervent Radiol* 14;50-54.
12. Reshi AR, Bhat MA, Najar MS, et al. Etiological profile of nephrotic syndrome in Kashmir. *Indian J Nephrol* 2008;18:9-12.

13. Bakr A, Eid R, Sarhan A, et al. Fifteen years of kidney biopsies in children: A single center in Egypt. *Saudi J Kidney Dis Transpl* 2014;25:1321-7.
14. Hadidi R, Hadidi M, alDabbas M. Spectrum of biopsy-proven kidney disease in children at a Jordanian hospital. *Saudi J Kidney Dis Transpl* 2014;25:680-3.
15. Abdelraheem MB, Ali EM, Mohamed RM, Abdalla OA, Mekki SO, Yousif BM, Watson AR. Pattern of glomerular diseases in Sudanese children: A clinico-pathological study. *Saudi J Kidney Dis Transpl* 2010;21:778-83.
16. Gulati S, Sengupta D, Sharma R, Sharma A, Gupta RK, et al. Steroid resistant nephrotic syndrome: role of histopathology. *Indian Pediatrics*. 2006; 43:55-60.
17. Coppo R, Gianoglio B, Porcellini MG, Maringhini S: Frequency of renal diseases and clinical indications for renal biopsy in children (report of the Italian National Registry of Renal Biopsies in Children). Group of Renal Immunopathology of the Italian Society of Pediatric Nephrology and Group of Renal Immunopathology of the Italian Society of Nephrology. *Nephrol Dial Transplant*, 1998; 13: 293–7.
18. Rychlík I, Jančová E, Tesař V, Kolský A, Lácha J, Stejskal J, Stejskalová A, Dušek J, Herout V. The Czech registry of renal biopsies. Occurrence of renal diseases in the years 1994–2000. *Nephrology Dialysis Transplantation*. 2004 Oct 19;19(12):3040-9.
19. Rivera F, Lopez-Gomez JM, Perez-Garcia R: Clinicopathologic correlations of renal pathology in Spain. *Kidney Int*, 2004;66:898–904.
20. Ko KW, Ha IS, Jin DK et al: Childhood renal diseases in Korea. A clinicopathological study of 657 cases. *Pediatr Nephrol*, 1987;1:664–9.
21. Al-Rasheed SA, al-Mugeiren MM, al-Salloum AA: Childhood renal diseases in Saudi Arabia. A clinicopathological study of 167 cases. *Int Urol Nephrol*, 1996;28:607–13.
22. ZELAL BİRCAN, Yavuz Yilmaz A, Katar S, Vitrinel A, Yildirim M. Childhood idiopathic nephrotic syndrome in Turkey. *Pediatrics international*. 2002 Dec;44(6):608-11.
23. Simpson AK, Wong W, Morris MC: Paediatric nephrotic syndrome in Auckland, New Zealand. *J Paediatr Child Health*, 1998;34: 360–2.
24. Srivastava RN. 50 years of nephrotic syndrome in children, and hereafter. *Indian Pediatr*. 2013;50:107-10.
25. Jennette JC, Olson JL, Schwartz MM, Silva FG (eds): *Heptinstall's Pathology of the kidney*, Volumes 1 and 2, 6th edition: Lippincott Williams and Wilkins, Philadelphia; 2007.p.126-54.
26. Chanchlani R, Parekh RS. Ethnic differences in childhood nephrotic syndrome. *Frontiers in pediatrics*. 2016 Apr 19;4:39.
27. Hu YC, Feng YX, Lv XA, Wang R. A clinical and pathological analysis of 3722 renal biopsy specimens from adults with primary glomerular disease in Shandong province, China. *WIMJ Open* 2014;1:57.
28. Mendelssohn DC, Cole EH. Outcomes of percutaneous kidney biopsy, including those of solitary native kidneys. *Am J Kidney Dis* 1995;26:580-5.