

# Legg–Calvé–Perthes Disease: A Case-Based Resident’s Guide for the Pediatric Rotation

Sadegh Hasani Satehi<sup>1</sup>, Saied Besharatry<sup>1</sup>, Anne-Laure Simon<sup>2</sup>, Soroush Baghdadi<sup>3</sup>,  
 Mohammad Taghi Baghdadi<sup>4</sup>, Mohammad Hossein Nabian<sup>1,5,\*</sup>

<sup>1</sup> Resident, Department of Orthopedic Surgery, Joint Reconstruction Research Center, Imam Khomeini Hospital Complex, School of Medicine, Tehran University of Medical Sciences, Tehran, Iran

<sup>2</sup> Assistant Professor, Department of Pediatric Orthopedic, Robert Debré University Hospital, Paris, France

<sup>3</sup> Research Fellow, Children’s Hospital of Philadelphia, Philadelphia, PA, USA

<sup>4</sup> Professor, Department of Orthopedic Surgery, Imam Khomeini Hospital Complex, School of Medicine, Tehran University of Medical Sciences, Tehran, Iran

<sup>5</sup> Assistant Professor, Department of Orthopedic Surgery, Imam Khomeini Hospital Complex, School of Medicine, Tehran University of Medical Sciences, Tehran, Iran

\*Corresponding author: Mohammad Hossein Nabian; Department of Orthopedic Surgery, Imam Khomeini Hospital Complex, School of Medicine, Tehran University of Medical Sciences, Tehran, Iran. Tel: +98-9126305095, Email: dr.nabian@gmail.com

Received: 27 March 2019; Revised: 17 June 2019; Accepted: 04 August 2019

**Keywords:** Legg Calvé Perthes Disease; Perthes Disease; Hip

**Citation:** Hasani Satehi S, Besharatry S, Simon AL, Baghdadi S, Baghdadi MT, Nabian MH. **Legg–Calvé–Perthes Disease: A Case-Based Resident’s Guide for the Pediatric Rotation.** *J Orthop Spine Trauma* 2019; 5(3): 65-9.



## Background

When a happy six-year-old boy comes to your clinic with complaints of pain in his right hip after activity and his parents say their son has limping, which important disease should not be missed?

The answer is the Legg-Calvé-Perthes disease (LCPD). This pediatric orthopaedic condition corresponds to an avascular necrosis of the proximal capital femoral epiphysis (1). Arthur T. Legg, Jacques Calvé, and Georg Perthes were the first to describe the disease in 1910 (2) and after 110 years, causes of the disease are still unclear.

Furthermore, since a lot of issues and controversies remain, it is essential for any orthopedic surgeon to have a correct understanding of the natural history, as well as the diagnostic and prognostic classifications to decide whether the patient requires referrals and management by an experienced team.

In this article, we tried aim to address the most important points and issues that any orthopedic surgeon should know about the Perthes disease.

### When Must Perthes Disease Be Suspected?

The incidence varies widely across populations and ethnicities, but the global incidence is estimated to be between 0.4 and 29 per 100,000 children under the age of 15 years. The typical age at presentation ranges from 4 to 8 years (average 6.5 years) (3).

Usually at the age of 4 to 7, the first symptoms appear.

Boys are four times more likely to be affected than girls, so about 80% of those affected are boys (4).

Both hip joints are affected simultaneously or sequentially in some children. Studies have reported 8 to 24% of bilateral hip involvement (5).

### Clinical Manifestation

Limping associated with hip or knee pain and limited hip range of motion (ROM) are common manifestations. Hip synovitis after activity, resulting in joint effusion, is the main cause of the symptoms. However, it should be noted that some children may sometimes have no symptoms, but some kind of intermittent pain or limping is frequently found during the past few months (6).

Depending on the nature of the disease, physical examination might be perfectly normal at the time of outpatient clinical visit; therefore, in any case of limping and occasional hip pain history, pelvic X-ray should be considered (Figure 1).

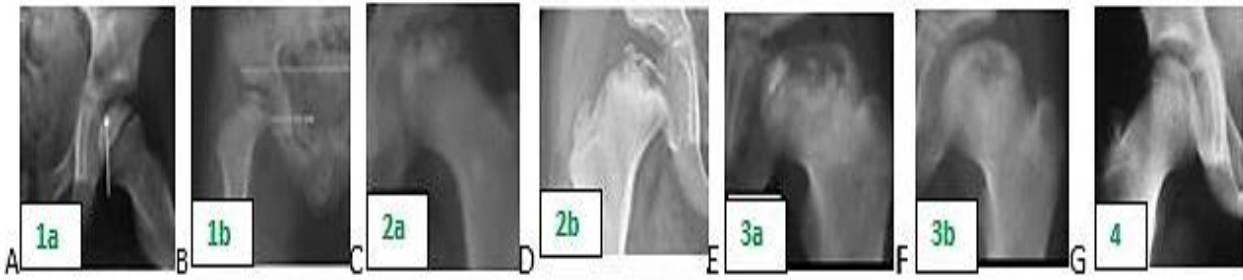### Natural History and Prognosis

A cascade of events involving the disruption of the femoral head blood supply and epiphyseal necrosis occurs before the necrotic bone is resorbed by osteoclasts, followed by epiphyseal collapse and fragmentation. Over time, epiphyseal healing occurs, which takes about 2 years.

Due to hypertrophy of synovium and surrounding tissues and muscle spasm, extrusion of the femoral head occurs (7).



**Figure 1.** (A) A 6-year-old boy with complaint of right hip pain with a normal hip range of motion (ROM) in examination. According to his age, gender and history of occasional limping, anteroposterior (AP) pelvic radiograph was requested (B).



**Figure 2.** Modified Elizabethtown classification: Perthes disease from initial stage (A and B) to fragmentation (C and D), re-ossification (E and F), and remodeling period (G). Each stage is divided into early (a) and late phase (b).

Age at onset, stage of disease, condition of epiphyseal femoral head and extent of involvement, and the extrusion of the femoral head are the most important criteria considered to determine the prognosis of the disease and outcomes. The disease onset after the age of six, female gender, obesity, and hip joint stiffness, especially limited abduction, are associated with poor results (8,9).

**Disease Stages**

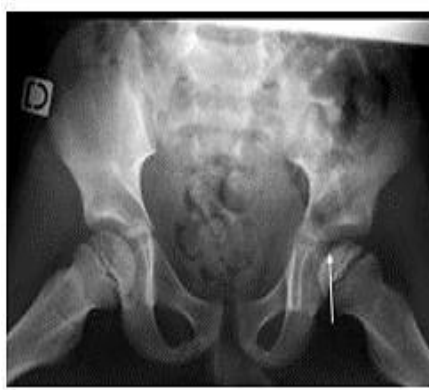Radiographic Waldenström classification (10) (Table 1) describes natural radiographic course of the disease and has been improved over time (modified Elizabethtown classification) (Figure 2) (1).

1	Initial stage/increased density stage
2	Fragmentation stage
3	Healing or reossification period
4	Definite period (healed or remodeling)

**Radiography**

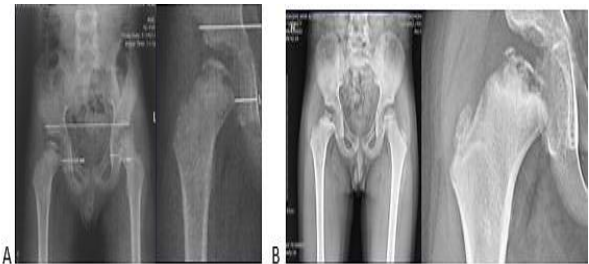The diagnosis, classification, and prognosis were based on pelvic X-ray findings. Usual assessment was made on the anteroposterior (AP), frog-leg, and abduction radiographs.

According to the Waldenström classification (10), in the early stages of the disease: widening of the medial hip joint space, "finger nail hit" sign (Figure 3), reduction in epiphyseal size with condensation and opacity are seen on radiographs (Figure 4-A).



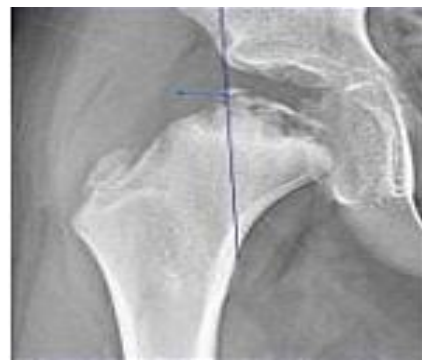**Figure 3.** Frog leg radiograph of a boy with perthes disease in the left hip showing "Finger nail hit" sign

Subsequent fragmentation of femoral head epiphysis (which corresponds to its revascularization and replacement by chondroblasts) happens in late stages (Figure 4-B) (11).



**Figure 4.** (A) Anteroposterior (AP) radiograph of a 6 year-old boy showing widening of the medial part of the right hip joint space and reduction in epiphysis size, (B) AP radiograph of the same patient 6 months later; the disease is in the fragmentation stage, and the extrusion and involvement of more than 50% of the femoral head are obvious.

An important finding to be considered for further treatment decision-making was the extent of the femoral head extrusion (Figure 5). However, it was better detected on the magnetic resonance imaging (MRI) to see cartilaginous under coverage. Therefore, the use of this modality may expand in the future (12,13).



**Figure 5.** Extrusion of the femoral head laterally by a highly big epiphysis measured from the lateral edge of the acetabulum

As the disease progresses through the remodeling period, more or less deformities of the proximal femur occur (coxa vara, coxa magna, coxa breva, femoral neck widening), in addition to the acetabular changes with time (retroversion) (11).

**Long-term Outcomes**

The usually proposed question was what is the probability of early hip osteoarthritis?

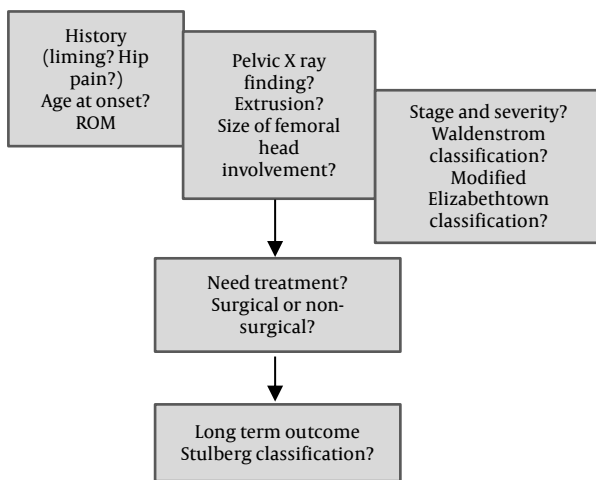
Stulberg classification (Table 2) predicts the long-term outcome judged by the risk of long-term hip osteoarthritis at skeletal maturity, with no, mild-to-moderate, and severe osteoarthritis in respectively group I/II, III/IV, and group V patients before the age of 50 years old (14).

**Table 2.** Stulberg classification

	Condition of the femoral head and joint congruency	Outcome
<b>Class I &amp; II</b>	Spherical congruity	Osteoarthritis is not developed
<b>Class III &amp; IV</b>	Aspherical congruity	Mild-to-moderate osteoarthritis in adulthood
<b>Class V</b>	Aspherical incongruity	Severe osteoarthritis before the age of 50 years old

In summary, our patient was a six-year-old boy that was presented for occasional limping with normal physical examination of the hip. The early X-ray images (Figure 4-A) showed unilateral (right hip) Perthes disease at its initial stage (increased density). 6 months later (Figure 4-B), the patient was in the fragmentation stage (Figure 2a).

Based on the above, the following decision-making and management algorithm was established (Figure 6).



**Figure 6.** Legg-Calvé-Perthes disease: Tips to be carefully observed and answered  
ROM: Range of motion

**Treatment Guidelines**

The aim of the treatment was to adapt the content (the head) to the container (acetabulum) for the best possible configuration at the end of the treatment (healing period) in order to guide the epiphysis reconstruction and avoid/delay early hip osteoarthritis, with the containment theory being either conservative or surgical.

All of the findings in the evaluations mentioned above help us make the best treatment decisions, which included: age at onset, stage of disease, amount of femoral head extrusion, extent of femoral head involvement, and examination of affected hip.

**Surgical or Non-surgical Treatment?**

Based on literature outcomes and our own experience, the results of different treatments at our center were obtained according to the following algorithm of treatment decisions (Figure 7).

In non-surgical treatment, abduction braces are used and mostly recommended under the age of 5. However, their efficiency to rest without weight-bearing has not been demonstrated yet. Nonetheless, an abduction brace does follow the containment theory (9, 11, 12, 14).

Surgical treatments are based on different procedures, either at the femur and/or at the pelvis (Salter osteotomy,

Triple osteotomy, Bernese osteotomy) and depend on surgeon's preference and experience, since there is no definitive evidence for one procedure against others (15). In our center, proximal femur varus osteotomies are preferred as containment surgery.

**Management at Initial and Fragmentation Stages**

For patients under 6 years old, the prognosis is good, and the results of both surgical and conservative treatments are similar. Therefore, in the absence of femoral head extrusion, observation is recommended. Even in cases of extrusion, conservative treatment with brace might still be sufficient (16).

Between the ages of 6 and 8, if there is no extrusion and the femoral head involvement is less than 50%, conservative treatment and monitoring should be provided. Otherwise (extrusion, involvement > 50%) containment surgery should be performed.

Between the ages of 8 and 12, surgery should be considered due to the lack of remodeling potential (14, 17, 18).

After the age of 12, reorientation acetabular osteotomies might be considered, like in adult avascular necrosis (19).

**Management during the Re-ossification Stage**

At this stage, if limitation in hip ROM, especially hinge abduction is present, hip arthrography should be performed. If irreducible "hinge abduction" is confirmed in the arthrogram regardless of other factors, surgical treatment including proximal femur valgus osteotomy with or without acetabular procedure is recommended.

On the other hand, in cases of femoral head extrusion or more than 50% involvement, if there is reducible hinge abduction or no limitation in the hip ROM, containment surgery is recommended (19).

**Management during the Healing period**

Management depends on the shape of the femoral head and the acetabulum, as well as the patients' complaints.

If the patient has no complaints, regular monitoring should be performed once a year until the skeletal maturity.

In case of painful hip or restrictions of movement motion and activities, appropriate evaluations should be taken to identify the type of pathology and appropriate treatment. Otherwise, no action is needed in asymptomatic patients.

The following (Table 3) are the recommended procedures according to the Perthes' disease symptoms and characteristics (20, 21).

**Table 3.** Recommended procedures according to pathology during the healing period

Pathology	Surgical treatment
Coxa brevis with a Trendelenburg gait	Trochanteric advancement with or without lengthening the femoral neck
Femoroacetabular impingement	Repairing the labral pathology and/or correcting impingement
Established degenerative joint disease/ articular surface is severely damaged	Total hip replacement

**Summary and Review of the Case**

In children with hip pain and sudden limping, in addition to differentials such as septic arthritis and slipped capital femoral epiphysis, it is important to consider perthes disease as well. Therefore, accurate

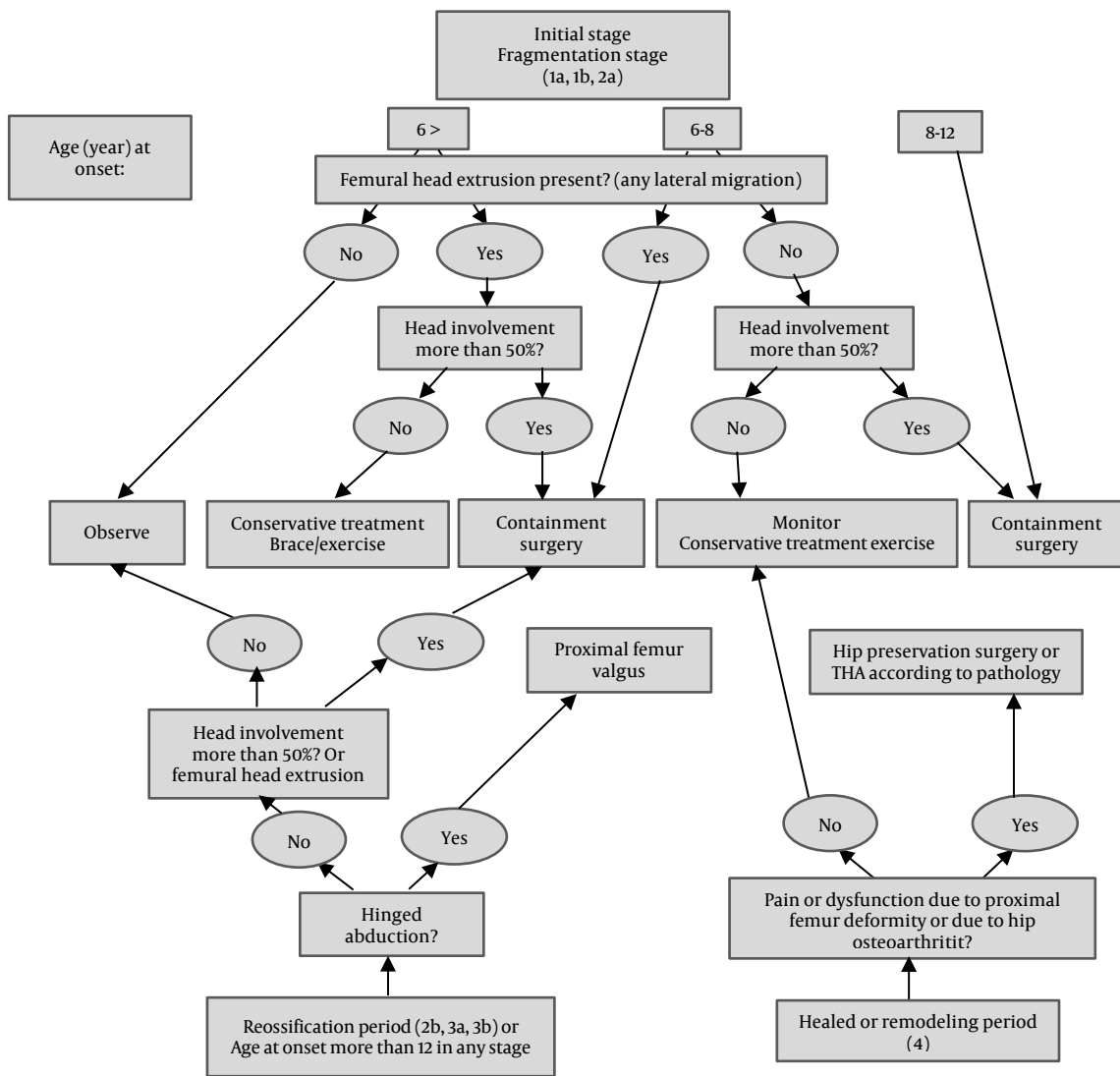


Figure 7. Legg-Calvé-Perthes disease: Treatment guideline

clinical examinations and comprehensive interpretation of pelvic radiography are helpful.

The sooner we can diagnose Perthes disease, the easier it will be for us to prevent the femoral head deformities, which is the ultimate goal of treatment.

We may not play a role in the age of onset of the disease, but our management and treatment will certainly prevent early hip osteoarthritis.

Thus, about the case mentioned in this study, for the six-year-old boy patient with normal ROM of hip, the fragmentation stage of Waldenström's classification, and type 2a of modified Elizabethtown classification on the involved side, the femoral head was extruded.

According to the pelvic radiographs, age, and proposed algorithm, the containment surgery with a proximal femur varus osteotomy was performed (Figure 8).

**Conflict of Interest**

The authors declare no conflict of interest in this study.

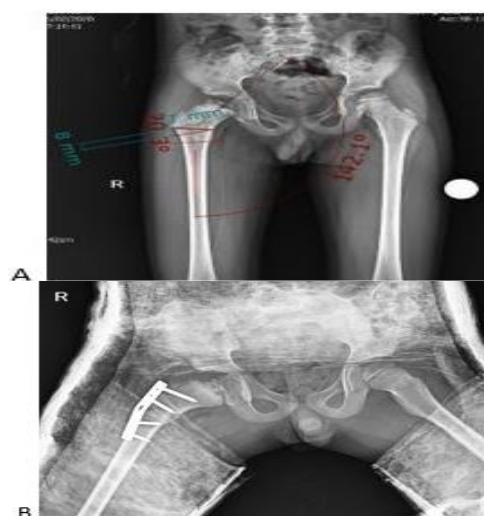

Figure 8. Usually, a 20° varisation is sufficient and should not exceed 110°. In our patient, according to the preoperative calculations made for an open wedge osteotomy technique for 20° of varus, 8 mm should be opened (A). Post-operative result (B)

## Acknowledgments

None.

## References

- Joseph B, Varghese G, Mulpuri K, Narasimha Rao K, Nair NS. Natural evolution of Perthes disease: A study of 610 children under 12 years of age at disease onset. *J Pediatr Orthop*. 2003;23(5):590-600. doi: [10.1097/00004694-200309000-00005](https://doi.org/10.1097/00004694-200309000-00005). [PubMed: [12960621](https://pubmed.ncbi.nlm.nih.gov/12960621/)].
- Perthes G. The classic: On juvenile arthritis deformans. *Clin Orthop Relat Res*. 2012;470(9):2349-68. doi: [10.1007/s11999-012-2433-1](https://doi.org/10.1007/s11999-012-2433-1). [PubMed: [22744201](https://pubmed.ncbi.nlm.nih.gov/22744201/)]. [PubMed Central: [PMC3830075](https://pubmed.ncbi.nlm.nih.gov/PMC3830075/)]
- Loder RT, Skopelja EN. The epidemiology and demographics of legg-calve-perthes' disease. *ISRN Orthop*. 2011;2011:504393. doi: [10.5402/2011/504393](https://doi.org/10.5402/2011/504393). [PubMed: [24977062](https://pubmed.ncbi.nlm.nih.gov/24977062/)]. [PubMed Central: [PMC4063164](https://pubmed.ncbi.nlm.nih.gov/PMC4063164/)].
- Margetts BM, Perry CA, Taylor JF, Dangerfield PH. The incidence and distribution of Legg-Calve-Perthes' disease in Liverpool, 1982-95. *Arch Dis Child*. 2001;84(4):351-4. doi: [10.1136/adc.84.4.351](https://doi.org/10.1136/adc.84.4.351). [PubMed: [11259241](https://pubmed.ncbi.nlm.nih.gov/11259241/)]. [PubMed Central: [PMC1718709](https://pubmed.ncbi.nlm.nih.gov/PMC1718709/)].
- Guille JT, Lipton GE, Tsirikos AI, Bowen JR. Bilateral Legg-Calve-Perthes disease: Presentation and outcome. *J Pediatr Orthop*. 2002;22(4):458-63. [PubMed: [12131441](https://pubmed.ncbi.nlm.nih.gov/12131441/)].
- Wingstrand H. Significance of synovitis in Legg-Calve-Perthes disease. *J Pediatr Orthop B*. 1999;8(3):156-60. doi: [10.1097/01202412-199907000-00002](https://doi.org/10.1097/01202412-199907000-00002). [PubMed: [10399114](https://pubmed.ncbi.nlm.nih.gov/10399114/)].
- Axer A, Schiller MG. The pathogenesis of the early deformity of the capital femoral epiphysis in Legg-Calve-Perthes syndrome (L.C.P.S.). An arthrographic study. *Clin Orthop Relat Res*. 1972;84:106-15. doi: [10.1097/00003086-197205000-00020](https://doi.org/10.1097/00003086-197205000-00020). [PubMed: [5032832](https://pubmed.ncbi.nlm.nih.gov/5032832/)].
- Kamegaya M, Saisu T, Miura Y, Moriya H. A proposed prognostic formula for Perthes' disease. *Clin Orthop Relat Res*. 2005;440:205-8. doi: [10.1097/01.blo.0000180601.23357.d9](https://doi.org/10.1097/01.blo.0000180601.23357.d9). [PubMed: [16239808](https://pubmed.ncbi.nlm.nih.gov/16239808/)].
- Rampal V, Clement JL, Solla F. Legg-Calve-Perthes disease: Classifications and prognostic factors. *Clin Cases Miner Bone Metab*. 2017;14(1):74-82. doi: [10.11138/ccmbm/2017.14.1.074](https://doi.org/10.11138/ccmbm/2017.14.1.074). [PubMed: [28740529](https://pubmed.ncbi.nlm.nih.gov/28740529/)]. [PubMed Central: [PMC5505718](https://pubmed.ncbi.nlm.nih.gov/PMC5505718/)].
- Waldenstrom H. The first stages of coxa plana. *JBJS*. 1938;20(3):559-66.
- Dimeglio A, Canavese F. Imaging in Legg-Calve-Perthes disease. *Orthop Clin North Am*. 2011;42(3):297-302, v. doi: [10.1016/j.ocl.2011.04.003](https://doi.org/10.1016/j.ocl.2011.04.003). [PubMed: [21742141](https://pubmed.ncbi.nlm.nih.gov/21742141/)].
- Green NE, Beauchamp RD, Griffin PP. Epiphyseal extrusion as a prognostic index in Legg-Calve-Perthes disease. *J Bone Joint Surg Am*. 1981;63(6):900-5. [PubMed: [7240330](https://pubmed.ncbi.nlm.nih.gov/7240330/)].
- de Sanctis N., Rondinella F. Prognostic evaluation of Legg-Calve-Perthes disease by MRI. Part II: Pathomorphogenesis and new classification. *J Pediatr Orthop*. 2000;20(4):463-70. [PubMed: [10912601](https://pubmed.ncbi.nlm.nih.gov/10912601/)].
- Stulberg SD, Cooperman DR, Wallensten R. The natural history of Legg-Calve-Perthes disease. *J Bone Joint Surg Am*. 1981;63(7):1095-108. [PubMed: [7276045](https://pubmed.ncbi.nlm.nih.gov/7276045/)].
- Herring JA, Kim HT, Browne R. Legg-Calve-Perthes disease. Part II: Prospective multicenter study of the effect of treatment on outcome. *J Bone Joint Surg Am*. 2004;86(10):2121-34. [PubMed: [15466720](https://pubmed.ncbi.nlm.nih.gov/15466720/)].
- Rosenfeld SB, Herring JA, Chao JC. Legg-calve-perthes disease: A review of cases with onset before six years of age. *J Bone Joint Surg Am*. 2007;89(12):2712-22. doi: [10.2106/JBJS.G.00191](https://doi.org/10.2106/JBJS.G.00191). [PubMed: [18056504](https://pubmed.ncbi.nlm.nih.gov/18056504/)].
- Joseph B. Management of Perthes' disease. *Indian J Orthop*. 2015;49(1):10-6. doi: [10.4103/0019-5413.143906](https://doi.org/10.4103/0019-5413.143906). [PubMed: [25593353](https://pubmed.ncbi.nlm.nih.gov/25593353/)]. [PubMed Central: [PMC4292319](https://pubmed.ncbi.nlm.nih.gov/PMC4292319/)].
- Price CT, Thompson GH, Wenger DR. Containment methods for treatment of Legg-Calve-Perthes disease. *Orthop Clin North Am*. 2011;42(3):329-40, vi. doi: [10.1016/j.ocl.2011.04.008](https://doi.org/10.1016/j.ocl.2011.04.008). [PubMed: [21742144](https://pubmed.ncbi.nlm.nih.gov/21742144/)].
- Choi IH, Yoo WJ, Cho TJ, Moon HJ. Principles of treatment in late stages of Perthes disease. *Orthop Clin North Am*. 2011;42(3):341-8, vi. doi: [10.1016/j.ocl.2011.05.004](https://doi.org/10.1016/j.ocl.2011.05.004). [PubMed: [21742145](https://pubmed.ncbi.nlm.nih.gov/21742145/)].
- Novais EN, Clohisy J, Siebenrock K, Podeszwa D, Sucato D, Kim YJ. Treatment of the symptomatic healed Perthes hip. *Orthop Clin North Am*. 2011;42(3):401-17, viii. doi: [10.1016/j.ocl.2011.05.003](https://doi.org/10.1016/j.ocl.2011.05.003). [PubMed: [21742152](https://pubmed.ncbi.nlm.nih.gov/21742152/)].
- Traina F, De Fine M, Sudanese A, Calderoni PP, Tassinari E, Toni A. Long-term results of total hip replacement in patients with Legg-Calve-Perthes disease. *J Bone Joint Surg Am*. 2011;93(7):e25. doi: [10.2106/JBJS.J.00648](https://doi.org/10.2106/JBJS.J.00648). [PubMed: [21471405](https://pubmed.ncbi.nlm.nih.gov/21471405/)].