

# Cases of Missed Posterior Fracture-Dislocation of the Shoulder

Morteza Nakhaei Amroodi<sup>1</sup>, Farzad Amouzadeh Omrani<sup>2,\*</sup>, Naser Ghanbari<sup>3</sup>, Melika Alaedini<sup>4</sup>

<sup>1</sup> Associate Professor, Department of Orthopedic Surgery, School of Medicine, Iran University of Medical Science, Tehran, Iran

<sup>2</sup> Assistant Professor, Department of Orthopedic Surgery, School of Medicine, Shahid Beheshti University of Medical Sciences, Tehran, Iran

<sup>3</sup> Resident, Department of Orthopedic Surgery, School of Medicine, Shahid Beheshti University of Medical Sciences, Tehran, Iran

<sup>4</sup> Research Assistant, Department of Orthopedic Surgery, Bone Joint and Related Tissue Research Center, School of Medicine, Shahid Beheshti University of Medical Sciences, Tehran, Iran

\*Corresponding author: Farzad Amouzadeh Omrani; Department of Orthopedic Surgery, School of Medicine, Iran University of Medical Science, Tehran, Iran. Tel: +98-9122300360, Email: farzad90am@gmail.com

Received: 02 June 2019; Revised: 14 July 2019; Accepted: 28 August 2019

## Abstract

Proximal humerus fracture-dislocation is a rare condition that occurs mostly in young adults due to high energy trauma and about 60-79 percent of misdiagnosis is occurred in the first diagnosis. In this article, we present two patients with proximal humerus fracture-posterior dislocation the fractures of whom were diagnosed, but after the radiographic studies including x-ray and computer tomography (CT) scan, the posterior dislocation was misdiagnosed. In addition, complications, management, and avoidance of this misdiagnosis were discussed.

**Keywords:** Missed Diagnosis; Fracture Dislocation; Shoulder Dislocation

**Citation:** Nakhaei Amroodi M, Amouzadeh Omrani F, Ghanbari N, Alaedini M. Cases of Missed Posterior Fracture-Dislocation of the Shoulder. *J Orthop Spine Trauma* 2019; 5(3): 75-9.



## Background

Fractures of the proximal humerus mostly occur in females older than 50 years of age with osteoporosis. It is the third most common fracture in this population following the distal radius fractures and vertebral fractures (1).

According to the Neer classification, fractures of proximal humerus are divided into four types: greater tuberosity, lesser tuberosity, anatomical neck, and surgical neck (Figure 1). A fracture part is considered to be displaced if there is an angulation of more than 45 degrees or a displacement more than 1 cm (2, 3).

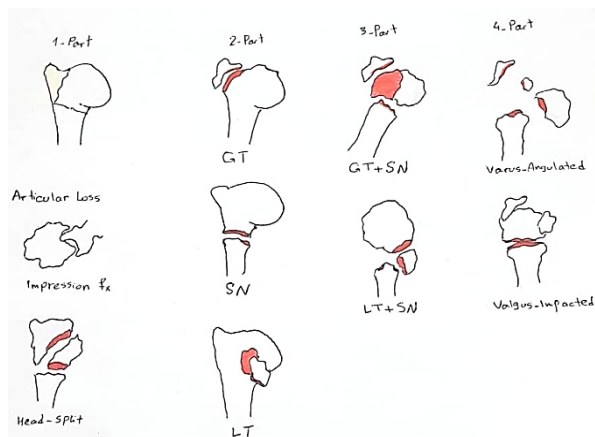


Figure 1. Neer classification

GT: Great tuberosity, LT: lesser tuberosity, SN: Surgical neck

Proximal humerus fractures are associated with posterior shoulder dislocation, especially following high energy trauma. It is a rare condition in young and active population. On the other hand, 4% of posterior dislocations are associated with fractures (4).

There is no specific finding for the diagnosis of dislocation in patients suffering from proximal humerus fractures. Signs and symptoms such as pain and limited range of motion (ROM) are non-specific. It has been speculated that approximately 60-79 percent of posterior shoulder dislocations are missed in the first clinical examination (5).

Here, we present two patients with posterior fracture-dislocation of proximal humerus, in whom fracture was diagnosed but the posterior dislocation was missed even after the imaging.

## First Case

A 31-year-old man was referred to the hospital due to a car accident. In clinical examination, he had pain and ROM limitation in the left shoulder. Imaging evaluations of the shoulder were performed, including x-ray [anteroposterior [AP] and lateral scapula view] and CT scan (Figures 2 and 3).

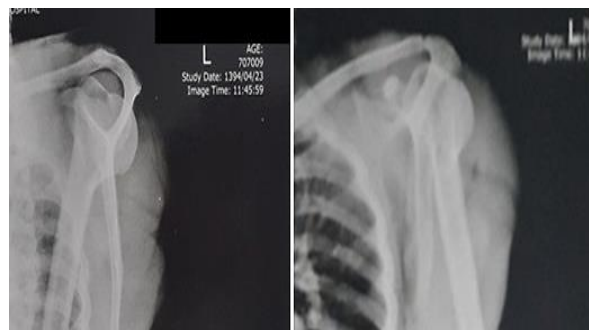
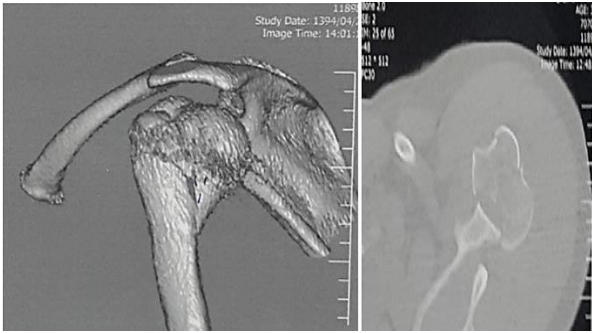
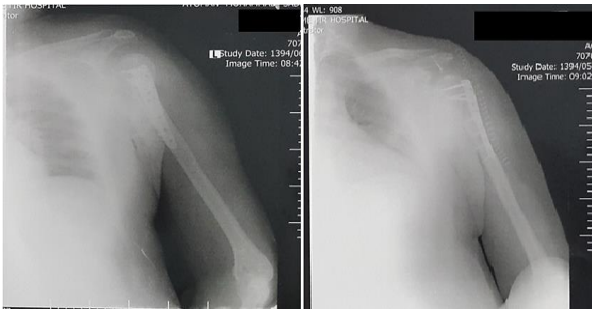
Figure 2. Preoperative X-ray of the left shoulder in the first case

The patient was diagnosed with left proximal humerus fracture (3-part fracture in Neer classification) and was scheduled for surgery.



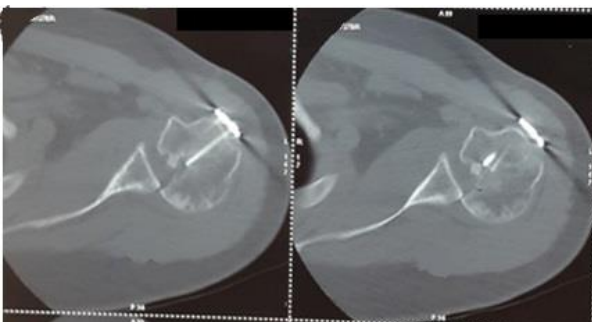
**Figure 3.** Preoperative computer tomography (CT) scan of shoulder in axial, coronal, and sagittal planes and bone 3D reconstruction view in the first case

Open reduction internal fixation (ORIF) by proximal humerus internal locking system (PHILOS) plate was performed through deltopectoral approach in semi-sitting position and under the guidance of the C-arm. **Figure 4** shows the postoperative X-ray image.



**Figure 4.** Shoulder X-ray of the first case after the first surgery

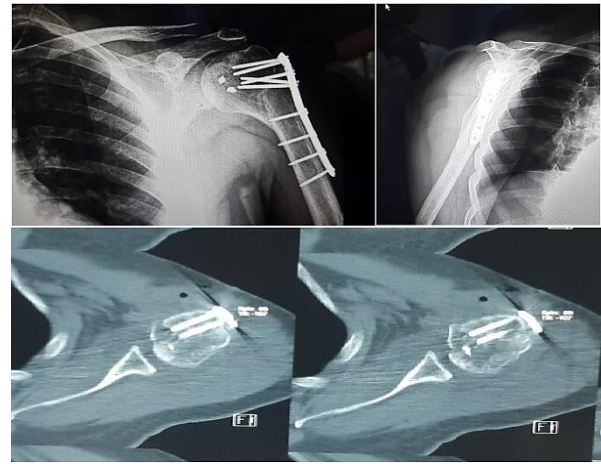
In the two-week-postoperative visit, we inspected the site of surgery and removed the sutures. Surprisingly, the patient complained of a severe pain and limited ROM. Therefore, a CT scan was requested for further evaluation. The CT scan showed a humerus head dislocation and it seemed that ORIF was performed in the dislocated humerus head (**Figure 5**). Due to the chronic dislocation, a reverse Hill-Sachs lesion was developed in the anteromedial portion of the humerus head.



**Figure 5.** Axial computer tomography (CT) of the shoulder in the first case before the revision surgery. A reverse Hill-Sachs lesion and dislocated head are detectable.

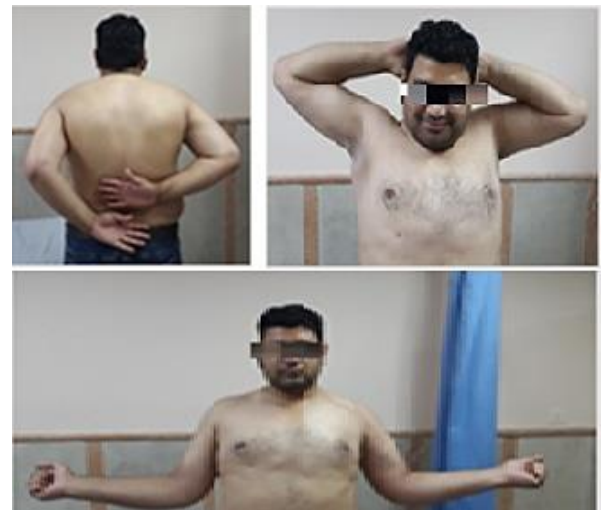We performed one revision surgery through deltopectoral approach and modified McLaughlin technique. Osteotomy of the lesser tuberculum without detaching of the subscapularis tendon from its attachment was performed. The lesser tuberculum was fixed into the defect area with anchor suture and PHILOS plate. We

evaluated the quality of construction and shoulder stability with intraoperative observation and C-arm fluoroscopy. **Figure 6** shows the imaging after the revision surgery.



**Figure 6.** Imaging evaluations after the revision surgery in the first case

One month after the surgery, University of California at Los Angeles (UCLA) Shoulder Score was 28/35 (**Figure 7**).



**Figure 7.** Shoulder range of motion (ROM) examination one month after the revision surgery in the first case

The patient was immobilized with an arm sling for 2 weeks, and then the elbow ROM and shoulder ROM (pendular and circular) were started. He underwent physical therapy and home exercises under medical supervision.

**Second Case**

A 25-year-old man was referred to the hospital due to a motor vehicle accident. The patient was admitted to the orthopedic department due to the left shoulder pain. Physical examination of the shoulder disclosed the restrictions of each active and passive ROM. A complete imaging of the shoulder was performed (**Figure 8**), including X-ray (AP view, lateral scapula view, and axillary view) and CT scan (axial, coronal, and sagittal planes, bone 3D reconstruction view). A 3-part fracture in Neer classification was detected.



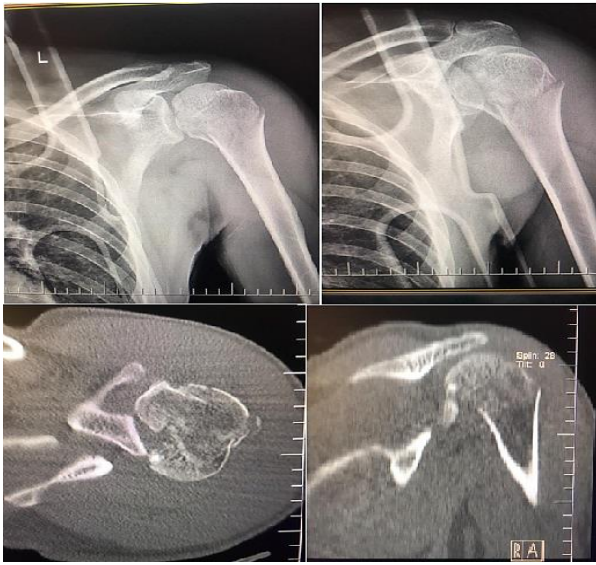


Figure 8. Preoperative imaging evaluations in the second case

ORIF with PHILOS plate was performed in semi-sitting position under the C-arm guide through deltopectoral approach and postoperative X-ray was performed (Figure 9).

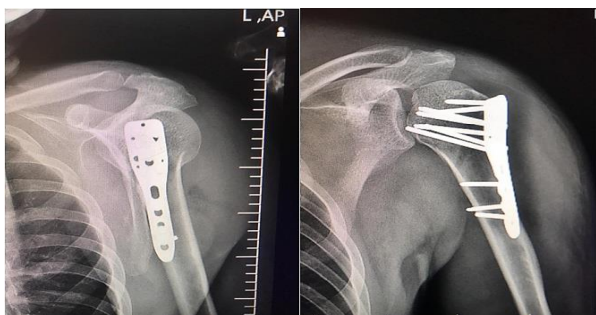


Figure 9. Shoulder X-ray anteroposterior (AP) and lateral x-ray of the left shoulder after the first surgery in the second case

One month after the surgery, the patient was referred by the physiotherapist due to persistent pain and severe ROM limitation. The shoulder X-ray and CT scan revealed a posterior dislocation and reverse Hill-Sachs lesion (Figure 10).

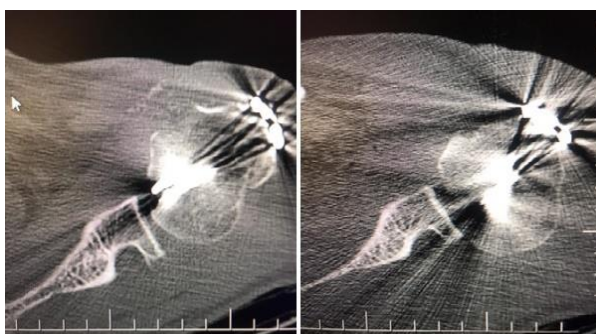

Figure 10. Imaging axial computer tomography (CT) scan views of the left shoulder before the revision surgery in the second case. The posterior dislocation and reverse hill-Sachs lesion are visible.

In the X-ray, joint space asymmetry, increased head to acromion space, and posterior head displacement (in lateral view) were observed (Figure 11).

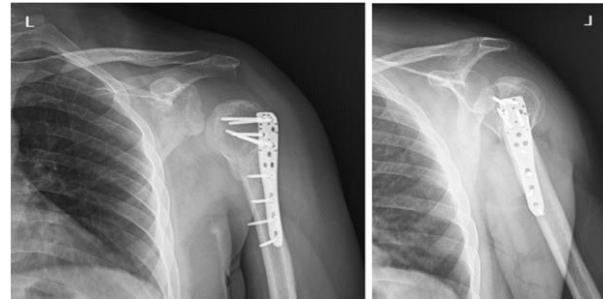


Figure 11. Anteroposterior (AP) and lateral X-ray of the shoulder before the revision surgery in the second case

A tunnel was made from the defected site to the lateral cortex of the humerus. Osteotomy of the lesser tuberculum without detaching of subscapularis tendon from its attachment was conducted. The subscapularis tendon was sutured with high fiber and the free head of fiber was fixed to the PHILOS plate using the tunnel pathway. Using the intraoperative observation and C-arm fluoroscopy, we rechecked the shoulder stability and the quality of construction. Figure 12 shows the postoperative imaging of the shoulder. One month after the revision surgery, UCLA score was 26/35 (Figure 13).

Similar to the previous case, the patient was immobilized with an arm sling for 2 weeks. The elbow ROM and shoulder ROM (pendular and circular) were started afterwards and he benefited from physical therapy and home exercises.

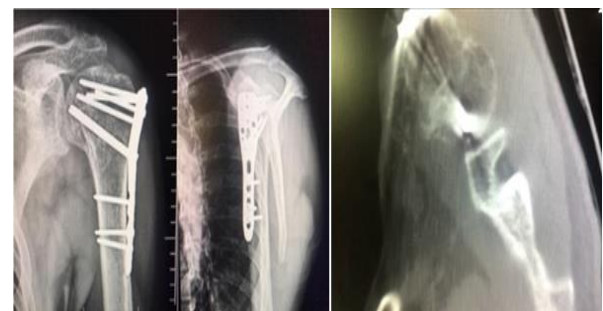

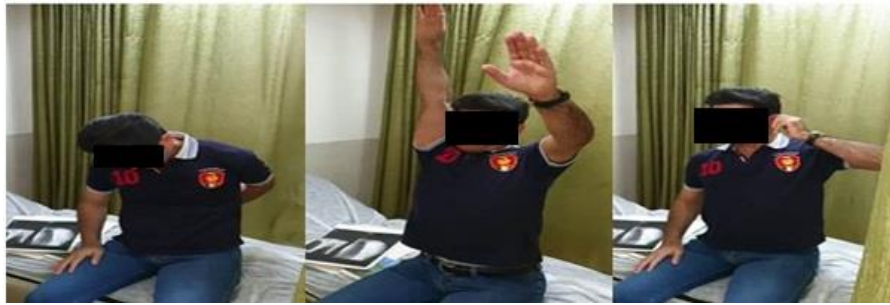Figure 12. Postoperative anteroposterior (AP) and lateral x-ray and computer tomography (CT) scan axial view of the left shoulder after the revision surgery in the second case

Discussion

**Complication:** Diagnosis of the proximal humerus fracture-dislocation had to be made early so that effective therapeutic interventions could be taken to prevent the possible complications and to recover the function of the joint. Moreover, good outcome in this condition depended on early and proper physical therapy, in addition to early diagnosis and treatment (6).

Reverse Hill-Sachs lesion is the most important risk factor for instability of the shoulder after the trauma. These lesions are divided into three types based on the size: small lesion (< 25% of the articular surface of the humeral head is impressed), medium lesion (humeral head is affected 25-50%), large lesion (> 50% of the humeral head is affected) (7).

**Treatment Planning:** There are multiple factors that have an effective role in treatment planning such as dislocation duration, patient's age, level of activity, lesion size, humeral head vascularity, and glenoid erosion degree. As a result of the restricted evidence and complicated



**Figure 13.** Shoulder range of motion (ROM) examination one month after the revision surgery in the second case

nature of this injury, several treatment choices were planned, with none definitive treatment being settled for globally. Patients with persistent dislocation for more than 3-6 weeks would need open reduction. For this purpose, a variety of choices are obtainable, such as the normal deltpectoral approach, the superior deltoid-splitting approach, and also the posterior approach. Although the deltpectoral approach exposes the anterior glenohumeral joint properly, the complete glenoid and humeral head cannot be directly envisioned. For better exposure, the posterior and the superior deltoid-splitting approaches have been developed (5).

For the reverse Hill-Sachs lesion treatment after posterior dislocation of shoulder, conservative treatment is recommended for lesions < 25% in a stable joint. In defects > 40%, hemi-arthroplasty could be applied. For defects within 25-40%, various surgical methods have been proposed, including McLaughlin or Modified McLaughlin, allograft, and rotational osteotomy (7).

The McLaughlin method is commonly used for small and medium reverse Hill-Sachs lesions. In this technique, posterior glenoid rim engagement in internal rotation is prevented which results in increased joint stability. For this purpose, the subscapularis tendon is transferred from the lesser tuberosity to the bony defect. Modified McLaughlin procedure has been popular because it provides good stability and rapid functional recovery (8).

**Prevention:** The main question is "what causes the misdiagnosis?" This is important as the misdiagnosis may increase the rate of complications such as inverted Hill-Sachs injury, instability of the shoulder posterior part, and osteonecrosis which may result in humerus head collapse (9).

In the first patient, the trauma radiography series were incomplete. The axillary view was not taken which is useful for detecting anterior or posterior shoulder dislocations that are not visible in the AP view. Furthermore, the quality of imaging was poor. The resolution was low, the details were not sharp, and one of the images was out of focus. After the first impression, the radiography and physical examination were not re-evaluated. The preoperative shoulder CT scan showed proximal head bone defect which was underrated by the surgeon. In this case, the proximal humerus fracture was detected in the CT scan while important associated conditions were neglected. During the surgery, because of the limitations of the surgical approach and C-arm position, none of the available X-ray views could help the surgeon to determine the position of the proximal humerus head. The surgeon could only check for the proper reduction, as he did. After surgery, only AP and lateral radiography were performed, which could not show the dislocation of proximal humerus. The bilateral shoulder radiography can help in this condition. The only clue in the follow-up was the

limitation of shoulder ROM which is a crucial point that should be emphasized in the physical examination.

**Management:** In this study, two different methods for reversed Hill-Sachs lesion and reduction of dislocated shoulder were performed. The first method comprised using anchor suture of subscapularis tendon and attaching it to the bone defect. In the second method, high fiber and tunnel for fixation of subscapularis tendon and the lesser tubercle in defected head were applied. Both methods showed good outcomes. The difference between the UCLA scores can be related to the delayed revision surgery of the second patient.

For specific injuries, emphasis is placed on useful radiographic signs and necessary further radiographic views to obtain. The main point is that you cannot achieve something if you do not think of it.

For decreasing the risk of misdiagnosis, history taking and observation of patient's paraclinical data must be repeated smartly as much as necessary.

#### Conflict of Interest

The authors declare no conflict of interest in this study.

#### Acknowledgments

None.

#### References

1. Calvo E, Morcillo D, Foruria AM, Redondo-Santamaria E, Osorio-Picorne F, Caeiro JR. Nondisplaced proximal humeral fractures: High incidence among outpatient-treated osteoporotic fractures and severe impact on upper extremity function and patient subjective health perception. *J Shoulder Elbow Surg.* 2011;20(5):795-801. doi: [10.1016/j.jse.2010.09.008](https://doi.org/10.1016/j.jse.2010.09.008). [PubMed: [21195633](https://pubmed.ncbi.nlm.nih.gov/21195633/)].
2. Carofino BC, Leopold SS. Classifications in brief: The Neer classification for proximal humerus fractures. *Clin Orthop Relat Res.* 2013;471(1):39-43. doi: [10.1007/s11999-012-2454-9](https://doi.org/10.1007/s11999-012-2454-9). [PubMed: [22752734](https://pubmed.ncbi.nlm.nih.gov/22752734/)]. [PubMed Central: [PMC3528923](https://pubmed.ncbi.nlm.nih.gov/PMC3528923/)].
3. Singh AP. Proximal humerus fractures [Online]. [cited 2010]; Available from: URL: <https://boneandspine.com/proximal-humerus-fracture>
4. Court-Brown CM, Caesar B. Epidemiology of adult fractures: A review. *Injury.* 2006;37(8):691-7. doi: [10.1016/j.injury.2006.04.130](https://doi.org/10.1016/j.injury.2006.04.130). [PubMed: [16814787](https://pubmed.ncbi.nlm.nih.gov/16814787/)].
5. Kokkalis ZT, Iliopoulos ID, Antoniou G, Antoniadou T, Mavrogenis AF, Panagiotopoulos E. Posterior shoulder fracture-dislocation: An update with treatment algorithm. *Eur J Orthop Surg Traumatol.* 2017;27(3):285-94. doi: [10.1007/s00590-016-1840-5](https://doi.org/10.1007/s00590-016-1840-5). [PubMed: [27562590](https://pubmed.ncbi.nlm.nih.gov/27562590/)].
6. Cooke SJ, Hackney RG. Bilateral posterior four-part fracture dislocations of the shoulders following electric

- shock: A case report and literature review. *Injury Extra*. 2005;36(4):90-5.
7. Guehring M, Lambert S, Stoeckle U, Ziegler P. Posterior shoulder dislocation with associated reverse Hill-Sachs lesion: Treatment options and functional outcome after a 5-year follow up. *BMC Musculoskelet Disord*. 2017;18(1):442. doi: [10.1186/s12891-017-1808-6](https://doi.org/10.1186/s12891-017-1808-6). [PubMed: [29132328](https://pubmed.ncbi.nlm.nih.gov/29132328/)]. [PubMed Central: [PMC5683370](https://pubmed.ncbi.nlm.nih.gov/PMC5683370/)].
  8. Konda SR, Fisher N, Gage M, Egol KA. Posterior fracture dislocation of the shoulder: A Modified McLaughlin Procedure. *J Orthop Trauma*. 2017;31(Suppl 3):S36-S37. doi: [10.1097/BOT.0000000000000900](https://doi.org/10.1097/BOT.0000000000000900). [PubMed: [28697084](https://pubmed.ncbi.nlm.nih.gov/28697084/)].
  9. Tyson S, Hatem SF. Easily missed fractures of the upper extremity. *Radiol Clin North Am*. 2015;53(4):717-36, viii. doi: [10.1016/j.rcl.2015.02.013](https://doi.org/10.1016/j.rcl.2015.02.013). [PubMed: [26046507](https://pubmed.ncbi.nlm.nih.gov/26046507/)].