

Intraosseous Stab Wound of Scapula: A Case Report

Salar Baghbani^{1,*}, Mohsen Rezaei Nosrati¹, Yousef Fallah², Babak Siavashi³, Mohammad Reza Golbakhsh³

¹ Orthopedic Assistant, Department of Orthopaedic Surgery, Sina Hospital, Tehran University of Medical Sciences, Tehran, Iran

² Assistant Professor, Department of Orthopaedic Surgery, Sina Hospital, Tehran University of Medical Sciences, Tehran, Iran

³ Associate Professor, Department of Orthopaedic Surgery, Sina Hospital, Tehran University of Medical Sciences, Tehran, Iran

*Corresponding author: Salar Baghbani; Department of Orthopaedic Surgery, Sina Hospital, Tehran University of Medical Sciences, Tehran, Iran. Tel: +98-9123084519, Email: salar.baghbani@yahoo.com

Received: 23 July 2019; Revised: 02 October 2019; Accepted: 17 November 2019

Abstract

Background: Intraosseous stab wounds are extremely rare. Only a few cases have been reported in the upper extremity.

Case Report: In this report, we presented a case of stab wound to the right shoulder with penetration to the scapula. The patient was successfully managed in a team-based approach. During a 12-month follow-up, he showed no abnormality in passive and active movements or physical examination.

Conclusion: Relying on the physical examinations and paraclinical studies may be an appropriate substitution for exploration surgery when possible iatrogenic injuries may affect the patient's quality of life.

Keywords: Stab Wound; Penetrating Injury; Shoulder; Advance Trauma Life Support

Citation: Baghbani S, Rezaei Nosrati M, Fallah Y, Siavashi B, Golbakhsh MR. **Intraosseous Stab Wound of Scapula: A Case Report.** *J Orthop Spine Trauma* 2019; 5(4): 110-2.



Background

Stab wound to the extremities is a common presentation to the emergency department, comprising 5 to 15 percent of all traumas in the trauma registry systems of developed countries like the United States of America (USA), Germany, and Sweden. This condition results in a significant number of operations for exploration of the possible vascular, nerve, and tendon injuries (1, 2).

Intraosseous stab wounds are extremely rare, and to the best of our knowledge, only 3 cases in the upper extremities have been reported to date (3-5). No agreed-upon protocol has been developed for management of this injury and further reports may shed more light on this topic.

Here, we present a stab wound with the retained knife blade in the scapula which showed no neurovascular damage pre- and postoperatively.

Case Report

A 32-year-old man came to the emergency department with a stab wound to the right shoulder. A knife blade penetrated from the posterolateral border of the right shoulder, medial to the axillary fold, and stuck in his scapula (Figure 1).

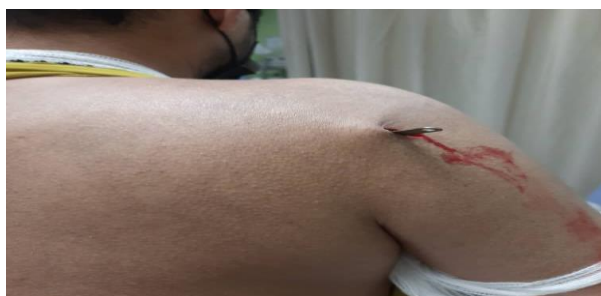

Figure 1. The knife stab wound penetrating from the posterolateral border of the right shoulder

The initial evaluation of the patient was initiated based on the Advanced Trauma Life Support (ATLS) protocols (6).

The patient revealed no obvious neurovascular damage in the physical examination. Emergency consultations (orthopedic surgery and vascular surgery) were requested. Meanwhile, intravenous (IV) cefazolin and gentamicin were started, tetanus booster was administered, and serial neurovascular examinations were performed.

The patient was hemodynamically stable and had no accompanying injuries. Necessary imaging was performed, including anteroposterior (AP) and lateral radiographs of the right shoulder (Figure 2), fine-cut computed tomography (CT) scan of the right shoulder (Figure 3), and CT angiography of the upper limbs.

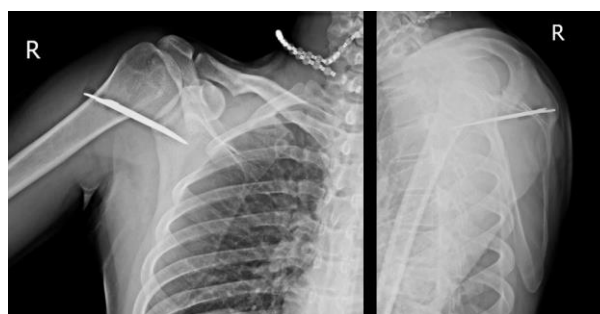

Figure 2. Anteroposterior (AP) and lateral radiographs of the right shoulder

CT angiographic study showed no disruption of the vascular anatomy. Based on the CT scan, the knife blade entered the posterior surface of the scapula, medial to the glenoid fossa, and passed anteriorly through the scapula about 1 centimeter.

The patient was immediately transferred to the operating room to undergo surgical treatment by a team of orthopedic surgeons and a standby vascular surgeon.

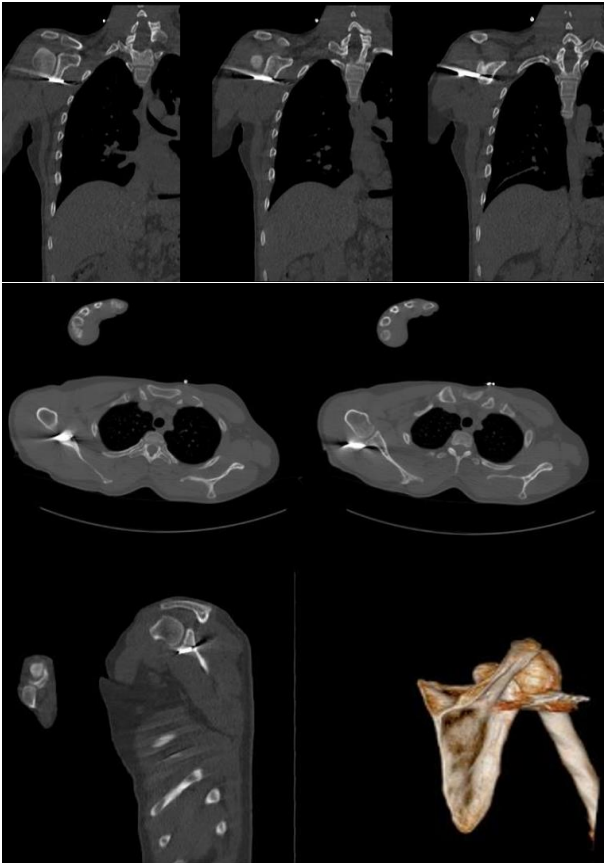


Figure 3. Computed tomography (CT) scan of the right shoulder

In a semi-lateral position, the wound was extended superiorly and inferiorly through a posterior approach. No neurovascular injury was detected. Under hemodynamic monitoring, the blade was carefully drawn out without any vigorous movement to prevent neurovascular injuries (Figure 4). Fluoroscopy was used to make sure of any remaining foreign body (Figure 5). The surgical team decided to postpone exploration of the anterior aspect of the scapula for 24 hours. This decision was made based on the dangerous adjacency of the anterior tip of the blade and vulnerability of the brachial plexus on one hand, and an intact physical examination and CT angiography on the other hand. Therefore, after irrigation and debridement, the skin was loosely closed.



Figure 4. The knife blade after removal from the wound

The patient was closely observed and serial neurovascular examinations were performed. The wound was re-opened after 24 hours, explored, irrigated, and tightly closed after normal exploration.

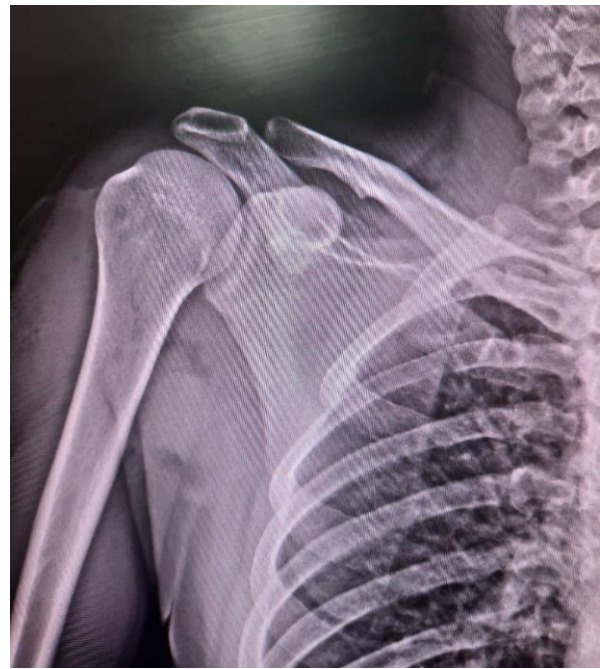

Figure 5. Postoperative radiograph of the right shoulder

During the 12-month follow-up, the patient showed no abnormality in passive and active movements or physical examination. The patient had a zero score in Disabilities of the Arm, Shoulder and Hand (DASH) questionnaire (7). We obtained the patient's informed consent for publishing his medical data.

Discussion

Trauma surgeons should have a good knowledge of the neurovascular anatomy to be able to explore possible injuries. To exclude vascular injuries, we used CT angiography in this patient. This modality could be safely used in stable patients with such injuries (8). In this case, based on the position of the blade in the CT scan, we were concerned with the axillary artery which originates from the lateral border of the first rib and continues to the inferior aspect of the teres minor muscle. Also, the brachial plexus is adjacent to this area which was highly prone to the injury in this case. Although the emergent CT angiography showed an intact axillary artery, a standby vascular surgeon accompanied the surgical team as a precaution.

Biomechanical studies have shown that in a single episode of a stab wound, 115 J of energy is released at most and the knife blade carries 1000 N of load to the contact surface (9, 10). This can damage soft tissue components and should be noted.

Our report is the fourth case of intraosseous stab wound in the upper extremity and the first one in the scapula.

Generally, penetrating injuries passing through the fascia are explored to find out the possible injuries to the tendons and nerves.

In our case, according to intact examinations and paraclinical studies and high risk of iatrogenic injury, we

only explored through the entry point and irrigated the wound although the tip of the knife blade had entered the anterior surface of scapula neighbouring brachial plexus.

We can assume that in such cases, relying on the physical examination and paraclinical studies is an appropriate substitution for exploration surgery imposed to the patient.

Conflict of Interest

The authors declare no conflict of interest in this study.

Acknowledgments

None.

References

1. Wahlgren CM, Riddez L. Penetrating vascular trauma of the upper and lower limbs. *Curr Trauma Rep.* 2016;2:11-20.
2. El-Abdellati E, Messaoudi N, Van Hee R. Assault induced stab injuries: Epidemiology and actual treatment strategy. *Acta Chir Belg.* 2011;111(3):146-54. doi: [10.1080/00015458.2011.11680726](https://doi.org/10.1080/00015458.2011.11680726). [PubMed: [21780521](https://pubmed.ncbi.nlm.nih.gov/21780521/)].
3. VideI J, Ovidiol J, FreitasI T, Ramos A. Remocao de corpo estranho intra-osseo do ombro apos facada. *Rev Port Ortop Traum.* 2014;22(2):41-7. [In Portuguese].
4. Quah C, Whitehouse S, Agrawal Y, Shah N, Phaltankar P. Broken knife blade in proximal humerus: An unusual presentation. *Eur J Orthop Surg Traumatol.* 2009;19:193-6.
5. Abboud JA, Wiesel B, Tomlinson D, Ramsey M. Intraosseous stab wound to the arm. *Am J Orthop (Belle Mead NJ).* 2008;37(3):E52-E54. [PubMed: [18438478](https://pubmed.ncbi.nlm.nih.gov/18438478/)].
6. Collicott PE. Advanced Trauma Life Support (ATLS): Past, present, future-16th Stone Lecture, American Trauma Society. *J Trauma.* 1992;33(5):749-53. [PubMed: [1464926](https://pubmed.ncbi.nlm.nih.gov/1464926/)].
7. Angst F, Schwyzer HK, Aeschlimann A, Simmen BR, Goldhahn J. Measures of adult shoulder function: Disabilities of the Arm, Shoulder, and Hand Questionnaire (DASH) and its short version (QuickDASH), Shoulder Pain and Disability Index (SPADI), American Shoulder and Elbow Surgeons (ASES) Society standardized shoulder assessment form, Constant (Murley) Score (CS), Simple Shoulder Test (SST), Oxford Shoulder Score (OSS), Shoulder Disability Questionnaire (SDQ), and Western Ontario Shoulder Instability Index (WOSI). *Arthritis Care Res (Hoboken).* 2011;63(Suppl 11):S174-S188. doi: [10.1002/acr.20630](https://doi.org/10.1002/acr.20630). [PubMed: [22588743](https://pubmed.ncbi.nlm.nih.gov/22588743/)].
8. Gonzalez-Compta X. Origin of the radial artery from the axillary artery and associated hand vascular anomalies. *J Hand Surg Am.* 1991;16(2):293-6. doi: [10.1016/s0363-5023\(10\)80113-3](https://doi.org/10.1016/s0363-5023(10)80113-3). [PubMed: [2022840](https://pubmed.ncbi.nlm.nih.gov/2022840/)].
9. Chadwick EK, Nicol AC, Lane JV, Gray TG. Biomechanics of knife stab attacks. *Forensic Sci Int.* 1999;105(1):35-44. doi: [10.1016/s0379-0738\(99\)00117-6](https://doi.org/10.1016/s0379-0738(99)00117-6). [PubMed: [10605074](https://pubmed.ncbi.nlm.nih.gov/10605074/)].
10. Horsfall I, Prosser PD, Watson CH, Champion SM. An assessment of human performance in stabbing. *Forensic Sci Int.* 1999;102(2-3):79-89. doi: [10.1016/s0379-0738\(99\)00055-9](https://doi.org/10.1016/s0379-0738(99)00055-9). [PubMed: [10464927](https://pubmed.ncbi.nlm.nih.gov/10464927/)].