

The Importance of the Lateral Femoral Wall Thickness in Intertrochanteric Fracture: Educational Corner

Nima Hoseini Zare¹, Alireza Moharrami¹, Seyed Mohammad Javad Mortazavi^{2,*}

¹ Resident, Department of Orthopedic Surgery, Joint Reconstruction Research Center, Tehran University of Medical Sciences, Tehran, Iran

² Professor, Department of Orthopedic Surgery, Joint Reconstruction Research Center, Imam Khomeini Hospital Complex, Tehran University of Medical Sciences, Tehran, Iran

*Corresponding author: Seyed Mohammad Javad Mortazavi; Department of Orthopedic Surgery, Joint Reconstruction Research Center, Imam Khomeini Hospital Complex, Tehran University of Medical Sciences, Tehran, Iran. Tel: +98-9121776150, Email: smjmort@yahoo.com

Received: 12 November 2019; Revised: 24 December 2019; Accepted: 20 January 2020

Keywords: Femoral Fractures; Intertrochanteric Fractures; Fracture Fixation

Citation: Hoseini Zare N, Moharrami A, Mortazavi SMJ. **The Importance of the Lateral Femoral Wall Thickness in Intertrochanteric Fracture: Educational Corner.** *J Orthop Spine Trauma* 2020; 6(1): 14-5.



Background

An intertrochanteric (IT) fracture is the most common reason for an elderly person to be admitted to an acute orthopedic ward. It continues to cause significant decision-making challenges among orthopedic surgeons. The stability of IT fractures is usually investigated based on the medial and posteromedial fragments (1).

The lateral wall integrity has been proved to be an essential determinant of fracture stability in IT fractures. Recently, there was a view that lateral femoral wall thickness has a significant role in IT fractures, including providing rotational stability, preventing excessive collapse, preventing excess medialization of the shaft, decreasing the reoperation rate, and providing a better functional outcome (2). In general, it can prevent the collapse of the proximal fragment like a lateral buttress.

The lateral wall thickness concept was recently utilized by the AO Foundation/Orthopaedic Trauma Association (AO/OTA) classification of fractures (3). They differentiated stable and unstable IT fractures based on the thickness of the lateral wall. There are few studies which investigated the importance of the lateral wall in IT fractures and their benchmark thickness in the evaluation of fracture stability. In this educational note, we review studies that worked on this concept and the importance of the lateral wall thickness in IT fractures.

The Importance of Lateral Wall Thickness

The most crucial factor in successful outcomes in dynamic hip screw (DHS) fixation was formerly thought to be the integrity of the posteromedial femoral section. Lately, it was shifted to the lateral wall. According to the biomechanical data, there is an increased chance of preserving the structure against negative forces with a higher cortical bone thickness (4-7). An unstable IT fracture happens when the integrity of the lateral wall is violated, as in OTA types A2.2 and A2.3. In other words, when the lateral wall has fracture, a simple IT fracture (OTA 31-A1/A2) will change into a reverse oblique fracture (OTA 31-A3). Therefore, it is a critical factor for decision-making and the successful treatment of unstable IT fractures. Stable IT fractures have a lower incidence of lateral wall fracture when fixing by DHS. These patients often have intact calcar or non-displaced lesser trochanteric fracture (1). Lateral wall thickness is

considered as a predictor of lateral wall fracture after a DHS implantation. Based on the study by Hsu et al., a thickness of < 20.5 mm is a risk factor for the prediction of secondary lateral wall fracture (sensitivity of 82.7%, specificity of 77.8%) and should not be fixed with DHS alone (8). Thus, for a better outcome, it is essential to know the fracture characteristics to predict its behavior after fixation.

Lateral wall measurement method

Hsu et al. analyzed 225 patients with IT fracture and 25 patients who had failed IT fixation by receiver operating characteristic (ROC) curve to estimate a threshold value that could predict lateral wall fracture (8). They defined the lateral wall thickness on anteroposterior (AP) radiograph as the distance between a reference point (3 cm below the vastus ridge of the greater trochanter) to the proximal of the fracture line with a 135° angle (Figure 1).

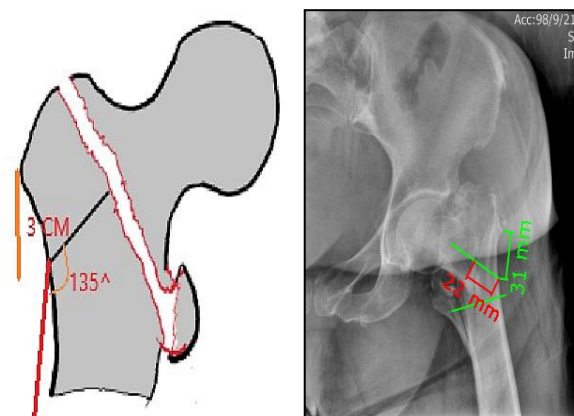


Figure 1. The measurement of lateral wall thickness in intertrochanteric (IT) fractures, 3 cm below the vastus ridge by 135 degree angulation with anatomic axis of femur

Approach to IT Fracture Based on the Lateral Wall Concept

The first step is to differentiate between stable and unstable patterns. The stable fracture resists displacement after adequate reduction and fixation. It generally includes 2-part IT or OTA A1 fractures with intact posteromedial support. For diagnosis, we need radiologic evaluation, including AP, lateral, and internal rotation views.

Iatrogenic lateral wall fractures are more probable when using a DHS in the presence of an unstable IT fracture than in a stable fracture pattern. The 20.5 mm threshold for lateral wall thickness could be used as a predictor for unstable fracture (OTA 31-A2.1) and a thickness of more than 20.5 mm is considered as a stable one (OTA 31-A1.3) (8).

The role of lateral wall thickness in AO/OTA classification of IT fractures

The AO/OTA classifies IT fractures as extra-articular (3). Type A1 is a stable IT fracture. Although the A1.3 type includes lesser trochanteric fracture, it could be fixed by DHS when the lateral wall thickness is more than 20.5 mm. The A1.3 type with a lateral wall thickness of less than 20.5 mm is considered A2.1 (unstable IT fracture), in which DHS fixation cannot be used alone. The AO/OTA classification considered lateral wall thickness as a significant predictor of stability in IT fractures and recommended using a 20.5 mm thickness threshold (Figure 2).

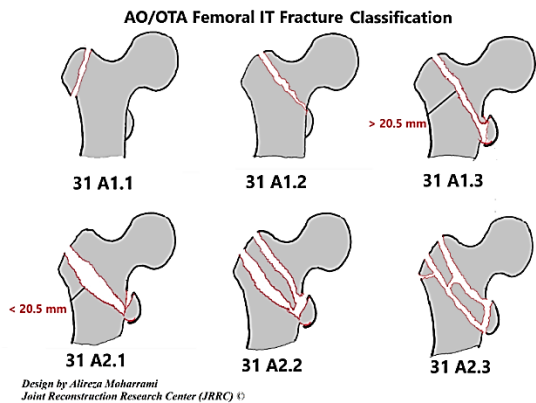


Figure 2. AO Foundation/Orthopaedic Trauma Association (AO/OTA) femoral intertrochanteric (IT) fracture classification, designed in Joint Reconstruction Research Center

Conclusion

The lateral wall thickness plays an important role in the decision-making process about the selection of fixation implants in IT fractures. It is a predictor factor for lateral wall fracture following the fixation and the subsequent outcome. Based on the previous studies, the AO/OTA classification considered the lateral wall thickness

threshold value of 20.5 mm as a predictive factor for the stability of IT fractures. A thickness of more than 20.5 mm is a positive indicator for success in reduction with DHS. IT fractures with a lateral wall thickness of less than 20.5 mm are considered unstable and other implants such as intramedullary nailing or DHS with buttress plate are recommended. However, the current evidence on this issue is limited and further studies are needed to confirm this concept.

Conflict of Interest

The authors declare no conflict of interest in this study.

Acknowledgments

None.

References

- Joshi D, Dhamangaonkar AC, Ramawat S, Goregaonkar AB. Predictors of iatrogenic lateral wall fractures while treating intertrochanteric fracture femur with the dynamic hip screw system in Indian patients. *Eur J Orthop Surg Traumatol.* 2015;25(4):677-82. doi: 10.1007/s00590-014-1566-1. [PubMed: 25417133].
- Gotfried Y. The lateral trochanteric wall: A key element in the reconstruction of unstable pertrochanteric hip fractures. *Clin Orthop Relat Res.* 2004;(425):82-6. [PubMed: 15292791].
- Meinberg EG, Agel J, Roberts CS, Karam MD, Kellam JF. Fracture and dislocation classification compendium-2018. *J Orthop Trauma.* 2018;32(Suppl 1):S1-S170. doi: 10.1097/BOT.0000000000001063. [PubMed: 29256945].
- Haidukewych GJ. Intertrochanteric fractures: Ten tips to improve results. *J Bone Joint Surg Am.* 2009;91(3):712-9. [PubMed: 19255235].
- Haidukewych GJ, Israel TA, Berry DJ. Reverse obliquity fractures of the intertrochanteric region of the femur. *J Bone Joint Surg Am.* 2001;83(5):643-50. doi: 10.2106/00004623-200105000-00001. [PubMed: 11379732].
- Flynn J. Orthopaedic knowledge update 10. Rosemont, IL: American Academy of Orthopaedic Surgeons; 2011.
- Zdero R, Bougherara H, Dubov A, Shah S, Zalzal P, Mahfud A, et al. The effect of cortex thickness on intact femur biomechanics: A comparison of finite element analysis with synthetic femurs. *Proc Inst Mech Eng H.* 2010;224(7):831-40. doi: 10.1243/09544119JHIM702. [PubMed: 20839651].
- Hsu CE, Shih CM, Wang CC, Huang KC. Lateral femoral wall thickness. A reliable predictor of post-operative lateral wall fracture in intertrochanteric fractures. *Bone Joint J.* 2013;95-B(8):1134-8. doi: 10.1302/0301-620X.95B8.31495. [PubMed: 23908432].