

Hydroalcoholic Extract of Iranian Caper Leaves Protects Hepatic Toxicity by Suppressing Oxidative Stress in Mice

Heibatullah Kalantari¹, Anis Alijani², Parvin Kheradmand³, Maedeh Goodarzian³, Leila Zeidooni^{4*}

¹Medicinal Plants Research Center, Ahvaz Jundishapur University of Medical Sciences, Ahvaz, Iran

²Department of Toxicology, School of Pharmacy, Ahvaz Jundishapur University of Medical Sciences, Ahvaz, Iran

³Department of Pathology, School of Medicine, Ahvaz Jundishapur University of Medical Sciences, Ahvaz, Iran

⁴Toxicology Research Center, Ahvaz Jundishapur University of Medical Sciences, Ahvaz, Iran

*Corresponding author: Leila Zeidooni, Ahvaz Jundishapur University of Medical Sciences. Tel: +98-(0)6133742530, Fax: +98-(0)6133332036, Email: leilazeidooni@gmail.com

Received: Jun 17, 2019, Accepted: Aug 21, 2019

Abstract

Capparis spinosa L. (caper) is an aromatic plant, commonly used in the Mediterranean diet, possessing numerous antioxidant compounds, such as phenols, rutin, tocopherols, carotenoids, and vitamin C in its leaves. Thus, the present study investigated the effects of Iranian caper leaves extract on oxidative stress caused by CCl₄ in the mice's liver.

This study was conducted on 42 male mice in seven groups. The control group, the sham group, the CCl₄ group, the Iranian caper leaves extract 100, 200, and 400 mg/kg + CCl₄ groups. Then, Biochemicals, oxidative stress, and hepatic histopathology parameters were evaluated. The co-administration of Iranian caper leaves extract, and CCl₄ significantly decreased the levels of aspartate aminotransferase, alanine aminotransferase, and reactive oxygen species, malondialdehyde ($P < 0.001$) and significantly increased the levels of glutathione and catalase in comparison with the group treated with CCl₄ alone ($P < 0.01$). Furthermore, Iranian caper leaves extract improved histopathological changes such as the inflammation and necrosis of hepatocytes. Iranian caper leaves extract has protective effects on hepatotoxicity induced by CCl₄, mainly through suppressing oxidative stress.

Keywords: Iranian caper, Carbon tetrachloride, Oxidative stress, Liver, Mice

Introduction

Herbal medicines like plant extracts rich in flavonoids and phenolic acids have recently drawn much attention. Moreover, dietary supplements can have protective effects against ROS and consequently enhance the antioxidant system with no side effects (1).

Caper, scientifically named *Capparis spinosa L.*, belongs to the family Capparidaceae. It is a shrub plant easily growing in poor and stony soils as well as various climatic conditions. This plant has a large natural distribution from the Mediterranean Sea to Iran. Caper's fruit, leaves, buds, barks, roots, and seeds have been long used for medicinal purposes. This is due to its pharmacological and therapeutic effects in gout, diuretics, constipation, astringent, and tonic treatments (2-5). Caper can be effective in the treatment of paralysis, toothache (6), and edema (7). Additionally, it has potent anti-hyperglycemic (8), anti-hepatotoxic (9, 10), and anti-inflammatory activities (11). Moreover; the antioxidant, anti-carcinogenic, anti-microbial, and anti-mutagenic properties

of caper can be attributable to its phenolic acids, alkaloids, glucosinolates, and flavonoid compounds (12). In this respect, Kalantari et al. argued that the administration of 100, 200, and 400 mg/kg the hydroalcoholic extract of Iranian caper leaves (Khuzestan Province) had reduced oxidative stress parameters on tetra-butyl hydroperoxide-induced acute liver damage in mice (13). Additionally, Liv-52 was considered as a medication prepared from caper leaves for the treatment of liver diseases (14, 15).

CCl₄ as a solvent induced liver toxicity in experimental animals (16). Hepatotoxicity induced by CCl₄ is thus characterized by hepatocellular necrosis along with fat deposition (17). The first step involves lipid peroxidation of membranes and covalent binds to cell proteins followed by cell death (18). One of the dominant strategies to prevent or treat liver injury is usually antioxidants use (19).

CCl₄ toxicity can be caused by its bioactivation to trichloromethyl free radical (CCl₃•) using cytochrome P₄₅₀ isozymes; the relevant trichloromethyl radical reacts with

oxygen and forms a highly toxic reactive, including trichloromethyl proxy radical.

Consequently, that damages endoplasmic reticulum (ER), mitochondria, cell membrane, and DNA. Eventually, this process leads to the accumulation of lipids, reduced protein synthesis, as well as the depletion of antioxidant status in tissue cells (20). Therefore, our study designed to investigate the hepatoprotective properties of Iranian caper leaves extract on biochemicals, oxidative stress, and histopathology parameters against liver injury induced by CCl₄ in mice.

Materials and methods

Chemicals: Ammonium molybdate, Thiobarbituric Acid (TBA), Trichloroacetic Acid (TCA), and GSH were purchased from Sigma-Aldrich (St Louis, Missouri, USA), 2', 7' -Dichlorofluorescein Diacetate (DCFDA) was obtained from Merck (Darmstadt, Germany). ALT and AST kits were obtained from biochemical assay kits (Pars Azmoon, Iran). CCl₄ was also purchased from Roche chemical company (Germany).

The preparation of herbal extract: The leaves of caper were collected from the Khuzestan Province, Iran. Caper was identified by the central herbarium of Ahvaz Jundishapur University of Medical Sciences, Iran. First, the leaves were dehydrated at ambient temperature (30–40 °C) for 25–30 days; then, they were powdered and soaked (100 g) in ethanol 90% aqueous-ethanol v/v for 72 hours. Consequently, they were filtered and dried (13).

Animals: Forty-two adult, NMRI male mice in the weight range of 25–30 g were achieved from the animal house of Jundishapur University of Medical Science (AJUMS), Iran. The mice were kept in polycarbonate cages under standard conditions at (25 ± 2 °C) with a 12:12 h light-dark cycle along with access to drinking water and diet ad libitum. This study was conducted according to the standard and Ethics Committee of (AJUMS) with (code: IR.AJUMS.REC.1395.02).

Experimental design: The plant extracts were dissolved in normal saline and administered orally for 5 consecutive days; then, CCl₄ was diluted in olive oil and mice received (1 mL/kg, IP). Forty two male mice were divided into six groups. Group 1: control; was administrated normal saline; group 2: sham group; was fed with olive oil; group 3: CCl₄ group; received CCl₄ (1 mL/kg, IP); and groups 4, 5 and 6: received Iranian caper leaves extract (100, 200, and 400 mg/kg, respectively) orally for five days, then received CCl₄ (1 mL/kg, IP) on that day an hour after administration of extract (13).

Sample collection: To this end; 24 h after CCl₄ injection, the mice were anesthetized with ketamine/ xylazine (90/10 mg/kg). Then, livers were removed. The samples' livers were divided into 2 sections. One section was homogenized for tissue oxidative stress biomarkers, and one section of the liver was located in 10% formalin for pathological examination (21).

Serum analysis: The serum was separated by centrifugation at 3000 rpm for 15 min. The activities of serums AST and ALT were also determined using an autoanalyzer machine (BT 3000, Italy) as well as biochemical assay kits (Pars Azmoon, Iran) (21).

Liver homogenization: For this purpose, 100 mg of liver tissue was homogenized, using glass homogenizer in 1 ml of phosphate buffer saline (1 mM) with (pH 7.2). Then, tissue suspension centrifuged at 10,000×g for 20 min at 4 °C. Next, the supernatant was isolated from the pellet and used for oxidative stress tests (22).

The GSH assay: Liver glutathione amount was determined by Ellman's reagent (23, 24). Phosphate buffer saline (2 ml) was added to the liver homogenate (40 µl) and DTNB (40 µl). Then, were mixed and incubated for 10 min at 25 °C. The absorbance of specimens were measured at wavelength 412 nm. Finally, the data were reported as micromoles/g tissue.

The CAT assay: The CAT activity was detected by an adapted procedure developed by Goth (25). First, the liver homogenate (50 µL) along with (0.05 mmol) of tris-HCl (500 µL) and H₂O₂ (1 mL) were mixed and placed at 25°C for 10 min. Then, (500 µL) of ammonium molybdate (4%) was added to mixture. Finally, the absorbance of specimens were determined at wavelength 410 nm. The obtained results were ultimately reported as U/g tissue.

The MDA assay: The lipid peroxidation in liver was determined based on MDA level (26). 2 mL of TBA (0.67%) was also quickly mixed to liver homogenate (1 mL) in one test tube; then, were placed in boiling water for 30 min. After cooling and centrifuging the mixture, the supernatant was isolated. The absorbance of supernatant was read at wavelength 532 nm. In the end, the MDA amount was express as nanomoles/g tissue (27).

The ROS assay: The ROS intensity was determined by DCFDA in liver. In liver, DCFDA by peroxides was converted to form highly fluorescent DCF that comes out of the cell. Briefly, 100 mg of liver tissue was homogenized in 1 ml of in ice-cold tris-HCl buffer (40 mM, pH 7.4). Then, DCFDA 1.25 mM was added to supernatant and incubated for 10 min. Finally, the intensity of fluorescence was measured at 488 nm excitation and 525 nm emission wavelength using a fluorimeter (Perkin-Elmer, LS-50 B, United Kingdom) (28).

Histopathological analysis: The livers after fixation in 10% formalin were embedded in paraffin. For histopathological studies seven slide were prepared from each group and slides were stained with Hematoxylin and Eosin. The slides were then study under a light microscope for observation necrosis and inflammatory cells (26).

Statistical analysis: The obtained data were performed by GraphPad Prism software and expressed as mean±SEM (N=7).

The between-group comparisons were also evaluated using one-way Analysis of Variance (ANOVA) followed by a Tukey's posthoc test. The level of $P < 0.05$ was reflected as significant.

Results

The effects of Iranian caper leaves extract and CCl₄ on serum analysis: The levels of ALT and AST were recognized as the biomarkers for hepatotoxicity studies. Figure 1 shows that 24 hours after CCl₄ administration, a significant increase was observed in the levels of AST, and ALT in the CCl₄ receiving group, in comparison with the control groups ($P < 0.001$). However, treatment with Iranian caper leaves extract at both concentrations of 200, and 400 mg/kg significantly decreased AST and ALT levels, in comparison with the CCl₄ receiving group ($P < 0.001$).

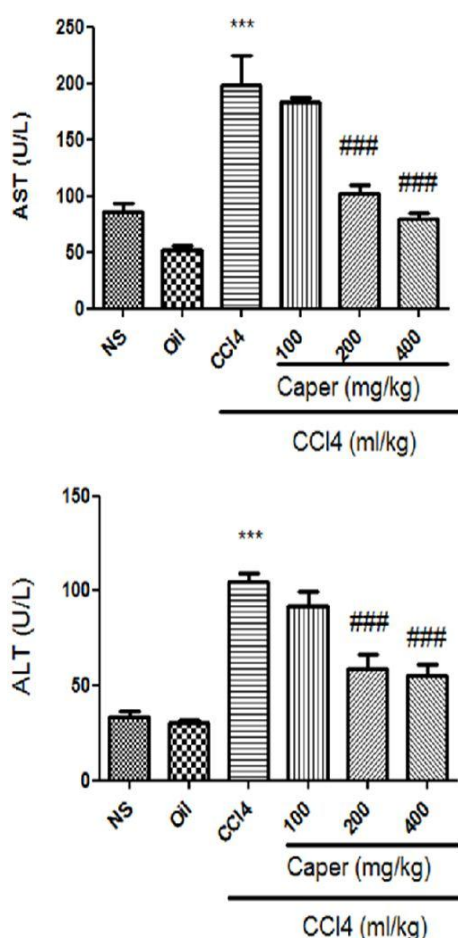


Figure 1 The effects of Iranian caper leaves extract and CCl₄ on ALT and AST activities. The studied mice were orally administrated Iranian caper leaves extract of 100, 200 and 400 mg/kg, per day for five days. On the fifth day, they intraperitoneally received the CCl₄ 1 mL/kg. The obtained results are reported as mean±SEM (n=7). *** $P < 0.001$ versus the control group, ### $P < 0.001$ versus the CCl₄ group.

The effects of Iranian caper leaves extract and CCl₄ on GSH levels: The measurement of GSH level is considered among the best biomarkers for CCl₄ detoxification. As per Figure 2, CCl₄ statically reduced liver GSH amounts in

comparison with the controls ($P < 0.01$). Iranian caper leaves extract pre-treatment also attenuated the depletion of liver GSH levels at 400 mg/kg, in comparison with the CCl₄ receiving group ($P < 0.01$).

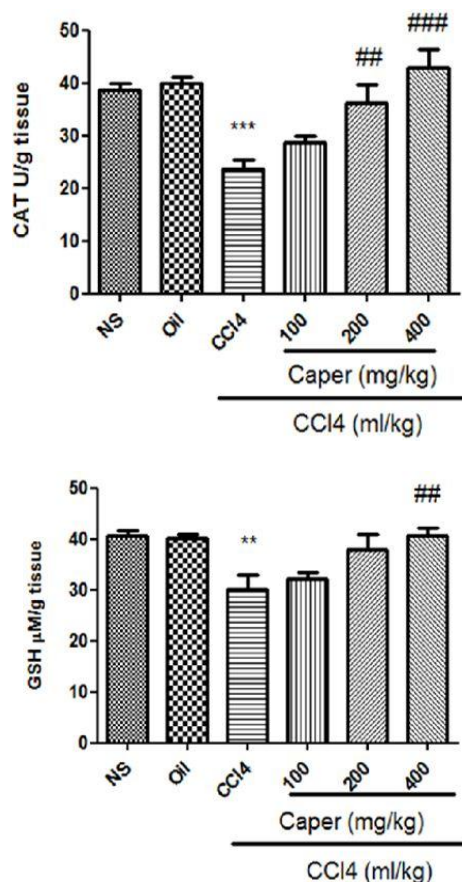


Figure 2 The effects of Iranian caper leaves extract and CCl₄ on the GSH amount and CAT activity. The studied mice were orally administrated by the Iranian caper leaves extracts of 100, 200, and 400 mg/kg per day for five days. On the fifth day, they received a CCl₄ (1 ml/kg, IP). The results are reported as mean±SEM (n=7). ** $P < 0.01$ and *** $P < 0.001$ versus the control group, ## $P < 0.001$ and ### $P < 0.001$ versus the CCl₄ group.

The effects of Iranian caper leaves extract and CCl₄ on CAT activity: As shown in Figure 2, the liver CAT activity showed a significant diminished in the CCl₄ receiving mice, in comparison with the normal mice ($P < 0.001$). Therefore, Iranian caper leaves extract pre-treatment significantly increased this variable at 200 ($P < 0.01$) and 400 mg/kg ($P < 0.001$), in comparison with the CCl₄ receiving mice.

The effects of Iranian caper leaves extract and CCl₄ on MDA and ROS levels: The achieved data showing that the amounts of ROS and MDA significantly increased in the CCl₄ receiving mice in comparison with the controls ($P < 0.001$). According to Figure 3, a significant decrease ($P < 0.001$) in the levels of MDA and ROS in the liver was observed in a dose-dependent manner in the pre-treated mice by Iranian caper leaves extract at all concentrations when compared with the CCl₄ receiving mice ($P < 0.001$).

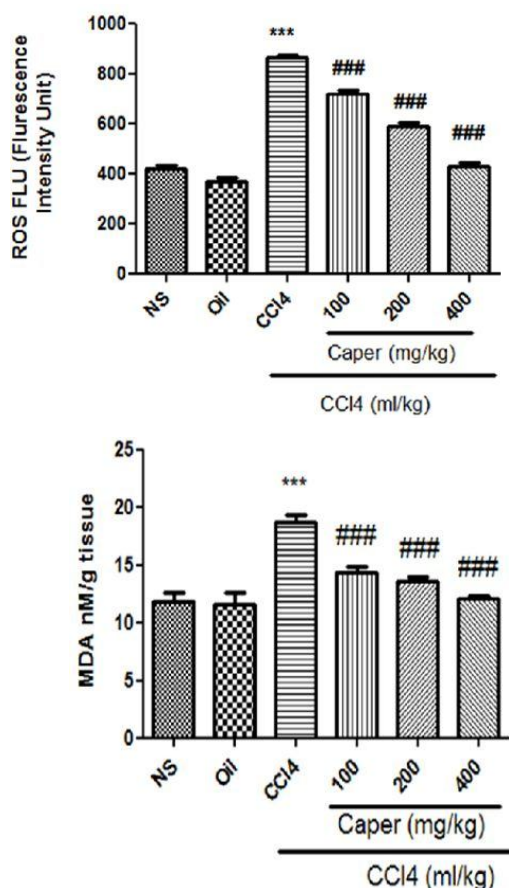


Figure 3 The effects of Iranian Caper leaves extract and CCl₄ on the levels of MDA and ROS. Mice were orally administrated Iranian Caper leaves extract 100, 200 and 400 mg/kg each day for five days and on the fifth day were intraperitoneally received the single dose of CCl₄ 1 ml/kg. Data are expressed as mean \pm SEM (n = 7). ***P < 0.001 versus the control group, ###P < 0.001 versus the CCl₄ group.

The effects of Iranian caper leaves extract and CCl₄ on histopathological findings:

The histopathological findings of the liver tissues revealed that hepatocyte cells, labels, and sinusoid status were healthy and without any pathological changes in the control groups (normal saline and sham) (Figures 4A and 4B). The CCl₄ intoxicated group also exhibited widened sinusoids, deteriorating cells, the necrosis and inflammatory cells (Figure 4F). Pre-treatment with Iranian caper leaves extract at all doses similarly improved histological changes, including inflammation and necrosis in comparison with the CCl₄-treated group (Figures 4C, 4D and 4E).

Discussion

The present study demonstrated that CCl₄ could cause oxidative damages through increasing ROS generation and MDA levels. It also decreased the GSH amount and CAT activity in the liver tissue. Moreover, the serum amounts of AST and ALT increased, as the biomarkers of liver damage. The relevant histopathological findings also supported biochemical and oxidative stress parameters. Moreover, Iranian caper leaves extract had hepatoprotective effects

evidenced through improving biochemical and oxidative stress as well as histological parameters induced by CCl₄.

The administration of Iranian caper leaves extract at the concentrations of 100, 200, and 400 mg/kg for five days also revealed its hepatoprotective effects in a dose-dependent manner. However, the dose of 400 mg/kg against hepatotoxicity induced by CCl₄ was more effective than the other two doses.

The liver is the main site for the detoxification of drugs and toxicants. The metabolic process does not usually damage the liver itself; however, many toxic drugs or chemicals can cause liver injury (29). Additionally, CCl₄ is the best-considered model used for hepatotoxicity induction in animals (30). The collected results suggested a significant greater in the serum amounts of ALT and AST in the CCl₄ receiving mice. This finding can be due to major hepatic injury, because these two variable are main biomarkers of liver injury. They are typically limited in the cytosol and ultimately free into the blood flow after tissue injury (31). Previous studies also supported such findings that CCl₄ causes hepatotoxicity along with increasing ALT and AST amounts (32). The present findings also demonstrated that AST and ALT amounts significantly decreased in the groups treated with the different doses of Iranian caper leaves extract. These results suggested that Iranian caper leaves extract could protect mice liver against CCl₄-induced injury. Furthermore, CCl₄ significantly reduced the GSH levels, as the main non-enzymatic antioxidant, as well as CAT as an enzymatic antioxidant in the mice's liver. This indicates that CCl₄ produced oxidative stress in the liver. The decrease of GSH levels in the present study was in line with previous findings (33, 34). The measurement of the GSH levels as the non-enzymatic antioxidant, and CAT as the enzymatic antioxidant defense were thus considered as appropriate indicators of the amount of antioxidant defense in the liver tissue. It can be supposed that antioxidant defense was reduced by CCl₄ in the mice's liver (35). The reduction of GSH levels might also reflect increased ROS generation stimulated by CCl₄ (36).

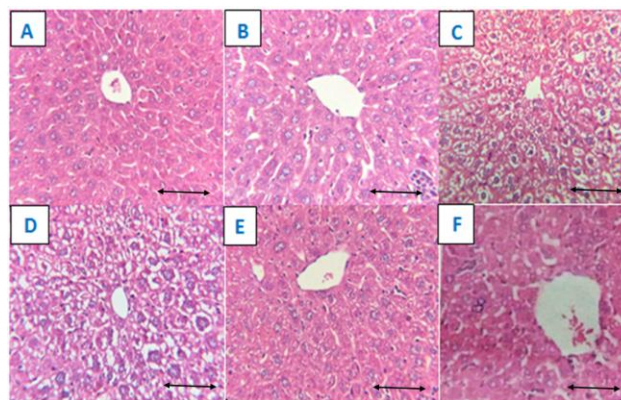


Figure 4 The specimens prepared with hematoxylin and eosin staining of the studied mice's liver by histopathological examination were observed with microscope (magnification 400X). The control group (normal saline) (A); Sham group (olive oil) (B); CCl₄ + Iranian caper leaves extract of 100 mg/kg (C); CCl₄ + Iranian caper leaves extract of 200 mg/kg (D); CCl₄ + Iranian caper leaves extract of 400 mg/kg (E); CCl₄ group (1 mg/kg, i.p.) (F). Scale bars: 250 μ m.

A possible reason for the reduction of GSH levels could be that the metabolites of CCl_4 probably reacted with glutathione. In this respect, previous studies demonstrated that trichloromethyl radical could react with the sulfhydryl groups of glutathione and other protein thiols and consequently change antioxidant/oxidant proportion (37, 38). Along with the declined activity of CAT might be due to the gathering of H_2O_2 , because CAT could convert H_2O_2 into H_2O and oxygen, then neutralize it (39). The inhibition of antioxidant defense system in hepatocytes by the metabolites of CCl_4 was likely to cause the accumulation of H_2O_2 in the liver tissues and be aided by decreased CAT activity. Numerous studies have established that the removal of free radical via antioxidant agents might decrease oxidative damage induced by CCl_4 ; and as a result, protect the liver from further injuries (40, 41).

In our study, the levels of GSH and CAT activity were recovered in treatment with Iranian caper leaves extract and boosted defense beside free radicals. This data suggested that the defensive properties of Iranian caper leaves extract against oxidative stress induced by CCl_4 probably due to the present of phenolic compounds in high amounts (42, 43). The phenolic compounds can counteract the free radicals caused by CCl_4 metabolites in the mice liver. Consistent with the current study, prior research reported that Iranian caper leaves extract augmented the levels of GSH and CAT in hepatotoxicity induced by tert-butyl hydroperoxide in the mouse's liver (13).

Trichloromethyl, which is derived from CCl_4 metabolism, is a highly reactive metabolite that is a major factor in the production of ROS and lipid peroxidation. This can be the main mechanism in the pathogenesis of hepatotoxicity induced by CCl_4 (Figure 5) (44). Therefore, reduced oxidative stress biomarkers like ROS and MDA, and increased antioxidant system can exceptionally protect the liver from oxidative stress caused by CCl_4 (45). The group treated by CCl_4 alone demonstrated high levels of lipid peroxidation and ROS; however, Iranian caper leaves extract could protect the samples against CCl_4 via suppressing lipid peroxidation and decreasing free radical generation evidenced by improving MDA and ROS levels.

The results of the histological analysis showed that CCl_4 treatment augmented the infiltration of inflammatory cells in mice liver. White blood cells respond nonspecifically to stimulants in the immune system and quickly migrate to the sites of damage and initiate inflammatory responses as liver injury happen following excessive ROS generation. Therefore, the infiltration of inflammatory cells can be reflected as an indicator of the inflammatory response (46). However, in this study, Iranian caper leaves extract inhibited inflammation caused by CCl_4 and could relieve hepatotoxicity induced by CCl_4 by overpowering the inflammatory reaction in the mice's liver.

In this study, the liver in the CCl_4 -treated mice demonstrated characteristic morphological findings, such as severe degenerative hepatocytes, widened sinusoids, deteriorating cells, the necrosis and inflammatory cells. Histopathological changes have led to cellular damages, like deterioration in membrane integrity. Furthermore, the CCl_4 administration facilitated the lipid peroxidation of lipid

structures in the liver tissue, resulting in sub-cellular damages as observed in histopathological examinations. However, Iranian caper leaves extract attenuated morphological alterations caused by CCl_4 . Previous studies similar to our study have reported necrosis and inflammation caused by CCl_4 in the mice liver (47, 48).

Conclusion

The present study evaluated the protective role of Iranian caper leaves extracts at different levels. Biochemical, molecular, and pathological findings suggested that Iranian caper leaves extract ameliorated hepatotoxicity induced by CCl_4 in the studied mice (Figure 5). The obtained results supported the pharmacological use of Iranian caper leaves for liver injuries induced by drugs and chemicals. However, more studies are required to analyze the biochemical contents of Iranian caper leaves extract (Khuzestan Province).

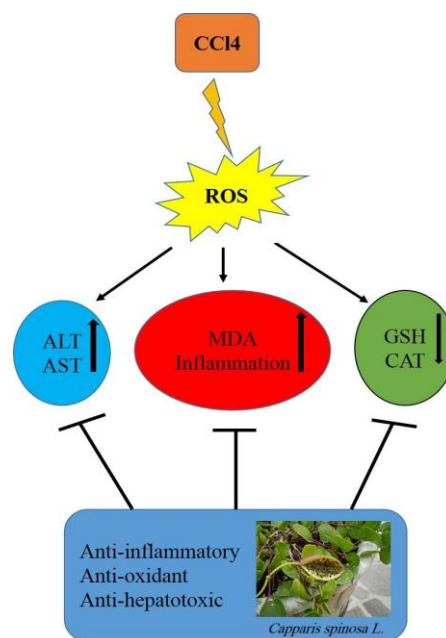


Figure 5 The effects of Iranian caper leaves extract and CCl_4 on the mouse's liver. CCl_4 in the liver metabolizes to trichloromethyl free radical ($\text{CCl}_3\bullet$) by $\text{CYP}_{2\text{E}1}$, then trichloromethyl radical reacts with oxygen and forms a highly toxic reactive trichloromethyl proxy radical ($\text{CCl}_3\text{OO}\bullet$), decreases the levels of GSH and CAT, and consequently increases the levels of MDA that result in a rise in AST, ALT, amounts and inflammation. Iranian caper leaves extract administration also modifies all examined endpoints induced by CCl_4 .

Funding

The authors disclosed receipt of the financial support for the research, from the Medicinal Plants Research Center (Grant number: MPRC-9410), funded by the Vice Chancellor of Research Ahvaz Jundishapur University of Medical Sciences.

Authors' contributions

Heibatullah Kalantari: Participated in research design, Anis Alijani, Parvin Kheradmand, and Maedeh Goodarzian: Conducted experiments, Leila Zeidooni: Performed data

analysis, Heibatullah Kalantari, Leila Zeidooni, and Anis Alijani: Contributed to the writing of the manuscript.

Conflicts of interests

The authors declare no competing interests.

Acknowledgments

This paper was issued from the thesis of Anis Alijani and was supported by Medicinal Plants Research Center, Ahvaz Jundishapur University of Medical Sciences, Ahvaz, Iran.

References

1. Pandey KB, Rizvi SI. Plant polyphenols as dietary antioxidants in human health and disease. *Oxid Med Cell Longev* 2009;2:270-8.
2. Mansour RB, Jilani IBH, Bouaziz M, Gargouri B, Elloumi N, Attia H, Ghrabi-Gammar Z, Lassoued S. Phenolic contents and antioxidant activity of ethanolic extract of *Capparis spinosa*. *Cytotechnol* 2016;68:135-42.
3. Ramezani Z, Aghel N, Keyghobadi H. Rutin from different parts of *Capparis spinosa* growing wild in Khuzestan/Iran. *Pak J Biol Sci* 2008;11:768-72.
4. Inocencio C, Rivera D, Alcaraz F, Tomás-Barberán FA. Flavonoid content of commercial capers (*Capparis spinosa*, *C. sicula* and *C. orientalis*) produced in Mediterranean countries. *Eur Food Res Technol* 2000;212:70-4.
5. Matthäus B, Özcan M. Glucosinolates and fatty acid, sterol, and tocopherol composition of seed oils from *Capparis spinosa* Var. *spinosa* and *Capparis ovata* Desf. Var. *canescens* (Coss.) Heywood. *J Agric Food chem* 2005; 53:7136-41.
6. Caboni P, Sarais G, Aissani N, Tocco G, Sasanelli N, Liori B, et al. Nematicidal activity of 2-thiophenecarboxaldehyde and methylisothiocyanate from caper (*Capparis spinosa*) against *Meloidogyne incognita*. *J Agric Food chem* 2012;60:45-7351.
7. Zhou H, Jian R, Kang J, Huang X, Li Y, Zhuang C, et al. Anti-inflammatory effects of caper (*Capparis spinosa* L.) fruit aqueous extract and the isolation of main phytochemicals. *J Agric Food chem* 2010;58:12717-21.
8. Huseini HF, Hasani-Rnjbart S, Nayebi N, Heshmat R, Sigaroodi FK, Ahvazi M, et al. *Capparis spinosa* L.(Caper) fruit extract in treatment of type 2 diabetic patients: a randomized double-blind placebo-controlled clinical trial. *Complement Ther Med* 2013;21: 447-52.
9. Sandhir R, Gill K. Hepatoprotective effects of Liv-52 on ethanol induced liver damage in rats. *Indian J Exp Biol* 1999;37:762-6.
10. Gadgoli C, Mishra S. Antihepatotoxic activity of p-methoxy benzoic acid from *Capparis spinosa*. *J Ethnopharmacol* 1999;66:187-92.
11. Panico A, Cardile V, Garuffi F, Puglia C, Bonina F, Ronsisvalle G. Protective effect of *Capparis spinosa* on chondrocytes. *Life Sci* 2005;77:2479-88.
12. Rahnnavard R, Razavi N. A review on the medical effects of *Capparis spinosa* L. *Adv Herb Med* 2017;3:44-53.
13. Kalantari H, Foruozandeh H, Khodayar MJ, Siahpoosh A, Saki N, Kheradmand P. Antioxidant and hepatoprotective effects of *Capparis spinosa* L. fractions and Quercetin on tert-butyl hydroperoxide-induced acute liver damage in mice. *J Tradit Complement Med* 2018;8:120-7.
14. Kulisic-Bilusic T, Schmöller I, Schnäbele K, Siracusa L, Ruberto G. The anticarcinogenic potential of essential oil and aqueous infusion from caper (*Capparis spinosa* L.). *Food Chem* 2012;132:261-7.
15. Tlili N, Feriani A, Saadou E, Nasri N, Khaldi A. *Capparis spinosa* leaves extract: Source of bioantioxidants with nephroprotective and hepatoprotective effects. *Biomed Pharmacother* 2017;87:171-9.
16. Qing G, ZHANG QQ, Jia-Qing C, ZHANG W, Hong-Cong Q, ZHANG ZJ, et al. Liver metabolomics study reveals protective function of *Phyllanthus urinaria* against CCl₄-induced liver injury. *Chin J Nat Medicines* 2017;15: 525-33.
17. Adewole S, Salako A, Doherty O, Naicker T. Effect of melatonin on carbon tetrachloride-induced kidney injury in Wistar rats. *Afr J Biomed Res* 2007;10:153-64.
18. Shenoy KA, Somayaji S, Bairy K. Hepatoprotective effects of Ginkgo biloba against carbon tetrachloride induced hepatic injury in rats. *Fitoterapia* 2001; 33:260-6.
19. Ma JQ, Liu CM, Yang W. Protective effect of rutin against carbon tetrachloride-induced oxidative stress, inflammation and apoptosis in mouse kidney associated with the ceramide, MAPKs, p53 and calpain activities. *Chem Biol Interact* 2018;286:26-33.
20. Weber LW, Boll M, Stampfl A. Hepatotoxicity and mechanism of action of haloalkanes: carbon tetrachloride as a toxicological model. *Crit Rev Toxicol* 2003;33:105-36.
21. Mansour M, Ginawi O, El-Hadiyah T, El-Khatib A, Al-Shabanah O, Al-Sawaf H. Effects of volatile oil constituents of *Nigella sativa* on carbon tetrachloride-induced hepatotoxicity in mice: evidence for antioxidant effects of thymoquinone. *Res Commun Mol Pathol Pharmacol* 2001;110:239-52.
22. Ahangarpour A, Zeidooni L, Samimi A, Alboghobeish S, Khorsandi LS, Moradi M. Chronic exposure to arsenic and high fat diet additively induced cardiotoxicity in male mice. *Res Pharm Sci* 2018;13:47-56.
23. Ellman GL. Tissue sulfhydryl groups. *Arch Biochem Biophys* 1959;82:70-7.
24. Thorpe C, Hooper KL, Raje S, Glynn NM, Burnside J, Turi GK, et al. Sulfhydryl oxidases: emerging catalysts of protein disulfide bond formation in eukaryotes. *Arch Biochem Biophys* 2002;405:1-12.
25. Sokolovic D, Djindjic B, Nikolic J, Bjelakovic G, Pavlovic D, Kocic G, et al. Melatonin reduces oxidative stress induced by chronic exposure of microwave radiation from mobile phones in rat brain. *J Radiat Res* 2008;49:579-86.
26. Khodayar MJ, Kalantari H, Khorsandi L, Rashno M, Zeidooni L. Betaine protects mice against acetaminophen hepatotoxicity possibly via mitochondrial complex II and glutathione availability. *Biomed Pharmacother* 2018;103:1436-45.
27. Bhutia Y, Ghosh A, Sherpa ML, Pal R, Mohanta PK. Serum malondialdehyde level: Surrogate stress marker in the Sikkimese diabetics. *J Nat Sci Biol Med* 2011;2:107-12.
28. Socci D, Bjugstad K, Jones H, Pattisapu J, Arendash G. Evidence that oxidative stress is associated with the pathophysiology of inherited hydrocephalus in the H-Tx rat model. *Exp Neurol* 1999;155:109-17.
29. Xie Y, Hao H, Wang H, Guo C, Kang A, Wang G. Reversing effects of lignans on CCl₄-induced hepatic CYP450 down regulation by attenuating oxidative stress. *J Ethnopharmacol* 2014;155:213-21.
30. Tiwari P, Kumar K, Pandey A, Pandey A, Sahu P. Antihypertoxic Activity of *Euphorbia hirta* and *Boerhaavia diffusa* extracts on some experimental models of Liver injury in Rats. *Int J Innovative Pharm Res* 2011;2:126-30.
31. Thapa B, Walia A. Liver function tests and their interpretation. *Indian J Pediatr* 2007;74:663-71.
32. El-Gazayerly O, Makhlof A, Soelm A, Mohmoud M. Antioxidant and hepatoprotective effects of silymarin phytosomes compared to milk thistle extract in CCl₄ induced hepatotoxicity in rats. *J Microencapsul* 2014;31:23-30.
33. Gnanadesigan M, Ravikumar S, Inbaneson SJ. Hepatoprotective and antioxidant properties of marine halophyte *Luminetzera racemosa* bark extract in CCl₄ induced hepatotoxicity. *Asian Pac J Trop Med* 2011;4:462-5.
34. El-Sayed YS, Lebda MA, Hassinin M, Neoman SA. Chicory (*Cichorium intybus* L.) root extract regulates the oxidative status and antioxidant gene transcripts in CCl₄-induced hepatotoxicity. *PLoS One* 2015;10:e0121549.
35. Liu Y, Wen PH, Zhang XX, Dai Y, He Q. Breviscapine ameliorates CCl₄-induced liver injury in mice through inhibiting inflammatory apoptotic response and ROS generation. *Int J Mol Med* 2018;42:755-8.
36. Byun JH, Kim J, Choung SY. Hepatoprotective Effect of Standardized *Ecklonia stolonifera* Formulation on CCl₄-Induced Liver Injury in Sprague-Dawley Rats. *Biomol Ther* 2018;26:218-23.
37. Srivastava A, Shivanandappa T. Hepatoprotective effect of the root extract of *Decalepis hamiltonii* against carbon tetrachloride-induced oxidative stress in rats. *Food Chem* 2010;118:411-7.
38. Huang Q, Zhang S, Zheng L, He M, Huang R, Lin X. Hepatoprotective effects of total saponins isolated from *Taraphochlamys affinis* against

- carbon tetrachloride induced liver injury in rats. *Food Chem Toxicol* 2012;50:713-8.
39. Olatosin TM, Akinduko DS, Uche CZ. Antioxidant capacity of *Moringa oleifera* seed oil against CCl_4 -induced hepatocellular lipid peroxidation in wistar albino rats. *J Exp Biol* 2014;4:514-8.
40. Yang J, Li Y, Wang F, Wu C. Hepatoprotective effects of apple polyphenols on CCl_4 -induced acute liver damage in mice. *J Agric Food Chem* 2010;58:6525-31.
41. Lu Y, Hu D, Ma S, Zhao X, Wang S, Wei G, et al. Protective effect of wedelolactone against CCl_4 -induced acute liver injury in mice. *Int immunopharmacol* 2016;34:44-52.
42. Tlili N, Khaldi A, Triki S, Munné-Bosch S. Phenolic compounds and vitamin antioxidants of caper (*Capparis spinosa*). *Plant Foods Hum Nutr* 2010;65:260-5.
43. Tlili N, Elfalleh W, Saadaoui E, Khaldi A, Triki S, Nasri N. The caper (*Capparis L.*): Ethnopharmacology, phytochemical and pharmacological properties. *Fitoterapia* 2011;82:93-101.
44. Wang BJ, Liu Ct, Tseng CY, Wu CP, Yu ZR. Hepatoprotective and antioxidant effects of *Bupleurum kaoui* Liu (Chao et Chuang) extract and its fractions fractionated using supercritical CO_2 on CCl_4 -induced liver damage. *Food Chem Toxicol* 2004;42:609-17.
45. Dey A, Lakshmanan J. The role of antioxidants and other agents in alleviating hyperglycemia mediated oxidative stress and injury in liver. *Food Funct* 2013;4:1148-84.
46. Li R, Xu L, Liang T, Li Y, Zhang S, Duan X. Puerarin mediates hepatoprotection against CCl_4 -induced hepatic fibrosis rats through attenuation of inflammation response and amelioration of metabolic function. *Food Chem Toxicol* 2013;52:69-75.
47. Ma JQ, Li Z, Xie WR, Liu CM, Liu SS. Quercetin protects mouse liver against CCl_4 -induced inflammation by the TLR2/4 and MAPK/NF- κ B pathway. *Int immunopharmacol* 2015;28:531-9.
48. Yang L, Wang CZ, Ye JZ, Li HT. Hepatoprotective effects of polyphenols from *Ginkgo biloba L.* leaves on CCl_4 -induced hepatotoxicity in rats. *Fitoterapia* 2011;82:834-40.