

Giant solitary fibrous tumor of pleura

Reza Bagheri^{1*}

¹Thoracic Surgeon, Lung Diseases Research Center, Mashhad University of Medical Sciences, Mashhad, Iran

ARTICLE INFO

Article type:
Images in Cardiothoracic Surgery

Article history:
Received: 15 April 2019
Revised: 15 May 2019
Accepted: 30 May 2019

Keywords:
Solitary Fibrous Tumor
Pleura
Diagnose

► Please cite this paper as:

Bagheri R. Giant solitary fibrous tumor of pleura. J Cardiothorac Med. 2019; 7(2):456-457.

ABSTRACT

A 60-year-old male presented with dyspnea and chest pain. He was referred with massive bulky mass. A mass in the left lung was observed using chest X-ray (Figures 1). A computed tomography scan of the chest showed a mass on the left lung with complete lung collapse Figures 2 (A, B). The needle biopsy was performed and the case was diagnosed with solitary fibrous tumor. Subsequently, the patient underwent complete resected open thoracotomy. In our case, the mass dimension was 50 × 35 cm weighting 5.600 gr Figures 3 (A, B).

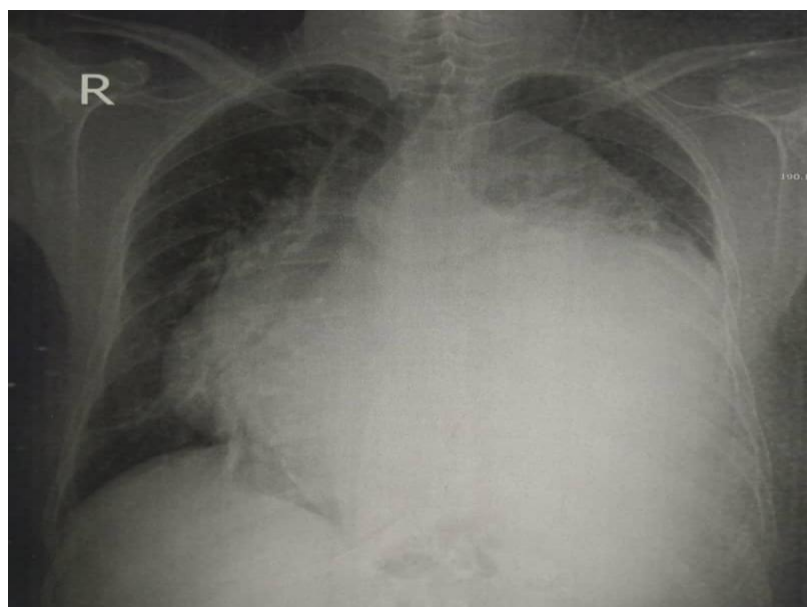
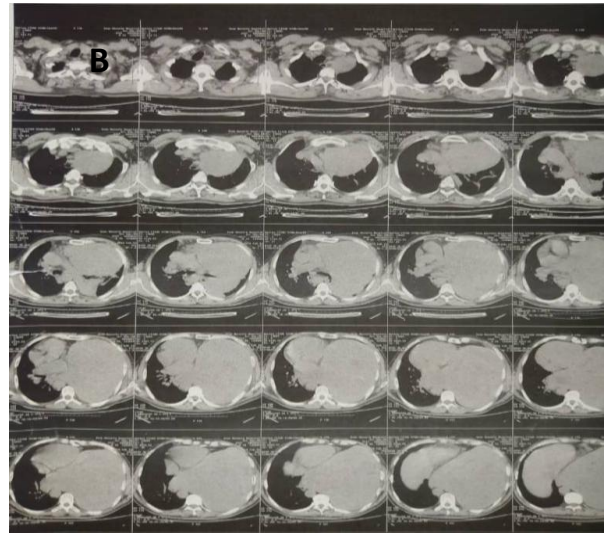
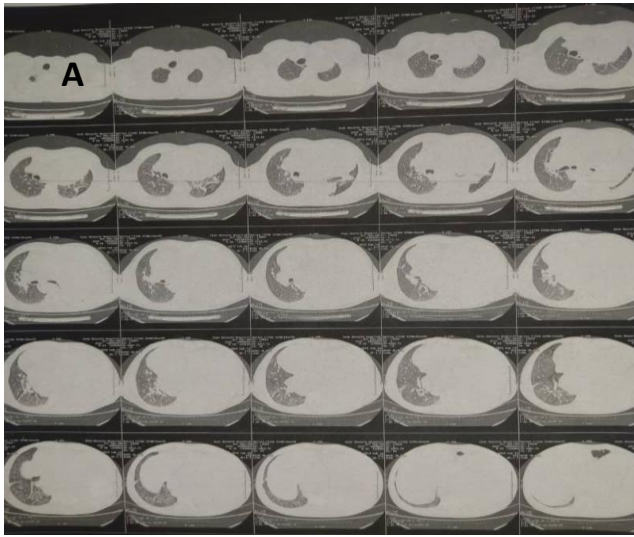


Figure 1. A chest-X-ray showing a mass on the left hemothorax

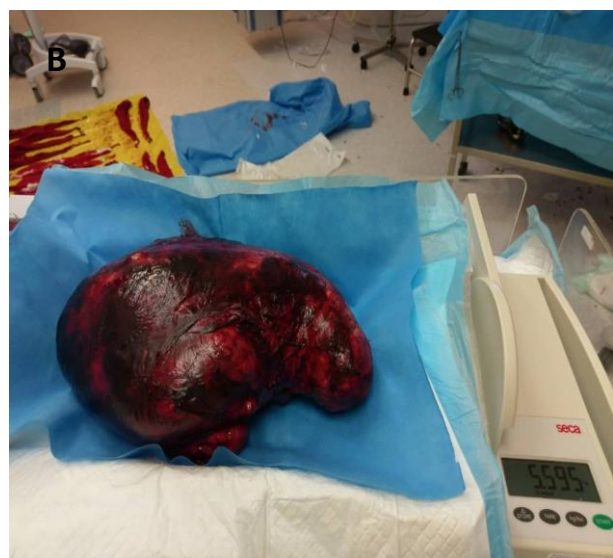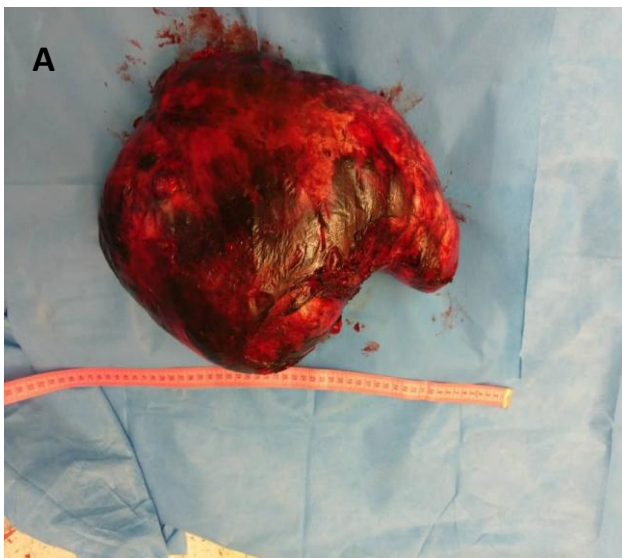*Corresponding author: Reza Bagheri, Lung Diseases Research Center, School of Medicine, Mashhad University of Medical Sciences, Mashhad, Iran. Tel and Fax: +985138402972; Email: Bagherir@mums.ac.ir

© 2015 *mums.ac.ir* All rights reserved.

This is an Open Access article distributed under the terms of the Creative Commons Attribution License (<http://creativecommons.org/licenses/by/3.0>), which permits unrestricted use, distribution, and reproduction in any medium, provided the original work is properly cited.



Figures 2(A,B). The CT scan showing a mass on the left



Figures 3 (A, B). Image of the mass with the ruler and scale

Financial support and sponsorship: The present study received no financial support.

Conflicts of interest: The authors declare that there is no conflict of interest.