

Very large hydatid cyst in a 17-year-old female

Reza Bagheri^{1*}

¹Thoracic Surgeon, Lung Diseases Research Center, Mashhad University of Medical Sciences, Mashhad, Iran.

ARTICLE INFO

Article type:
Images in Cardiothoracic Surgery

Article history:
Received: 15 April 2019
Revised: 15 May 2019
Accepted: 30 May 2019

Keywords:

Hydatid Cyst
Hemithorax
Outcomes

ABSTRACT

Introduction: A 17-year-old female presented with dyspnea, chest pain, and a very large cyst occupying the entire right hemithorax Figure 1(A, B). The patient is under full cyst extending to membrane Figure 2 (A, B).

► Please cite this paper as:

Reza Bagheri. Very large hydatid cyst in a 17-year-old female. J Cardiothorac Med. 2019; 7(2):460-461.

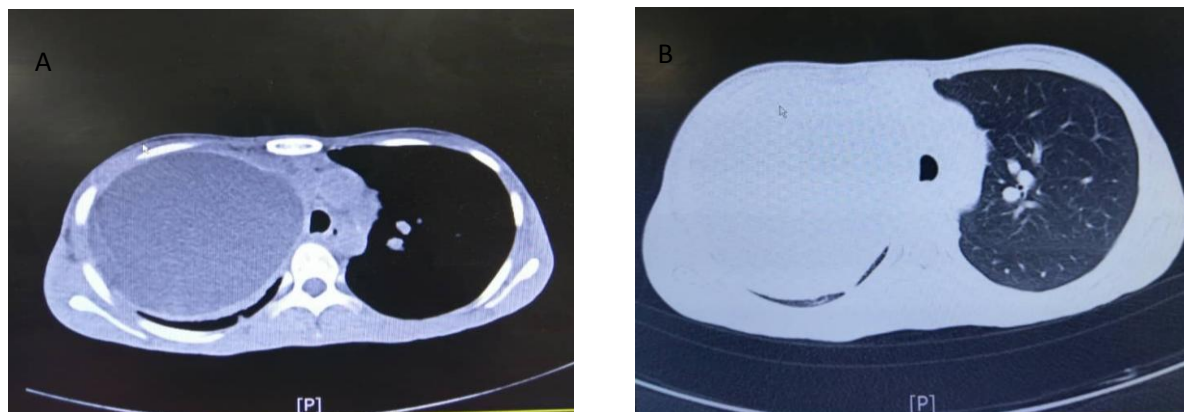


Figure 1 (A, B): Computed tomography scan and chest x-rays showing very large hydatid cyst

*Corresponding author: Reza Bagheri, Lung Diseases Research Center, School of Medicine, Mashhad University of Medical Sciences, Mashhad, Iran. Tel and Fax: +985138402972; Email: Bagherir@mums.ac.ir

© 2019 mums.ac.ir All rights reserved.

This is an Open Access article distributed under the terms of the Creative Commons Attribution License (<http://creativecommons.org/licenses/by/3.0>), which permits unrestricted use, distribution, and reproduction in any medium, provided the original work is properly cited.

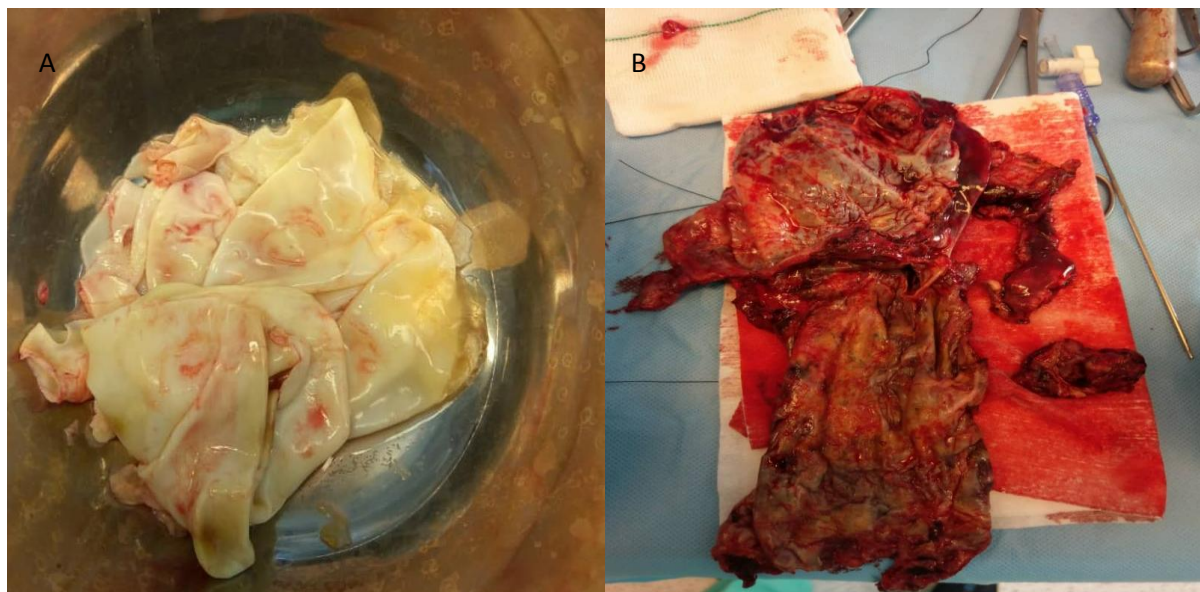


Figure 2 (A, B): Membrane discharged and removed the cystic fibrosis (PRESIS) completely

Financial support and sponsorship

The present study received no financial support.

Conflicts of interest

The authors declare that there is no conflict of interest.