

Mycotic aortic aneurysm as a postsurgical complication: report of a case and review of the literature

Donia Farokh¹, Fatemeh Sadeghi Ardakani*¹, Farhad Yousefi¹, Seyed Hanieh Afzalabadi¹

¹Radiologist, Department of Radiology, Faculty of Medicine, Mashhad University of Medical Sciences, Mashhad, Iran

ARTICLE INFO

Article type:
Case Report

Article history:
Received: 17 June 2019
Revised: 01 August 2019
Accepted: 19 August 2019

Keywords:
Mycotic aneurysms
Post-operative complication
Thoracic Aorta

ABSTRACT

Mycotic aneurysms are localized and irreversible dilatations of the arteries caused by weakening and damaging the arterial wall by an invasive organism establishing infective arteritis. Mycotic aneurysm of the thoracic aorta is a rare event; however, it can be fatal if not diagnosed early or not treated appropriately. Clinical findings are usually nonspecific; however, contrast-enhanced computed tomography (CT) is a common imaging modality of choice for the detection of mycotic aneurysms. Current management consists of antibiotic therapy and surgical treatment or endovascular interventions as early as possible. Herein, we present a case report of mycotic aneurysm of the thoracic aorta as a postoperative complication in a 60-year-old female with a clinical history of the cardia and esophageal carcinoma who underwent thoracic surgery. The presence of mycotic aneurysm was detected after performing a contrast-enhanced thoracic CT scan.

► Please cite this paper as:

Farokh D, Sadeghi Ardakani F, Yousefi F, Afzalabadi SH. Mycotic aortic aneurysm as a postsurgical complication: report of a case and review of the literature. *J Cardiothoracic Med.* 2019; 7(4): 557-562

Introduction

A mycotic aortic aneurysm, which is also known as an infected aortic aneurysm is an aortic aneurysm due to aortic wall infection (1, 2). It is a localized vascular dilatation secondary to inflammation, digestion, and weakening of the aortic wall with bacteria causing a false aneurysm, which is unstable and has a high risk for rupture and massive hemorrhage (2). The mycotic aneurysm is a rare

vascular lesion in clinical practice constituting only 1-3% of all arterial aneurysms (2, 3). It has been ascribed to bacterial endocarditis, and when present in the aorta, it is termed "inevitably fatal" as recently as 1967 (4). The term "mycotic" derives from the mushroom-like appearance of the aneurysms originally described, and not their underlying microbiological etiology (3, 5). The vast majority of mycotic aneurysms are bacterial and

*Corresponding author: Fatemeh Sadeghi Ardakani, Department of Radiology, Faculty of Medicine, Mashhad University of Medical Sciences, Mashhad, Iran, Tel: 0920744524, Email: SadeghiAF961@mums.ac.ir

© 2016 mums.ac.ir All rights reserved.

This is an Open Access article distributed under the terms of the Creative Commons Attribution License (<http://creativecommons.org/licenses/by/3.0>), which permits unrestricted use, distribution, and reproduction in any medium, provided the original work is properly cited.

the most common organisms are staphylococcus aureus and salmonella species (1, 2, 5).

Mycotic aneurysm makes up 0.65-2% of all aortic aneurysms with the thoracic aorta being an uncommon site of involvement (5). Initial symptoms of thoracic aortic involvement are usually non-specific (3, 5, 6). Multi-detector CT is the modality of choice for the detection of mycotic aortic aneurysms with high sensitivity and specificity (7).

It is a life-threatening disease that carries a worse prognosis and very high mortality. The most important complications are rupture with hemorrhage, sepsis, and embolic infection (5, 6, 8). Surgery remains the definitive treatment; however, perioperative mortality can be high in patients with arterial rupture (6). Today, the reported clinical experience in patients with thoracic mycotic aneurysm is limited to case reports and a few small case series in the literature. Moreover, a few cases of mycotic aortic aneurysm have been reported due to thoracic surgery. Herein, we report a case of the mycotic aortic aneurysm as a postoperative complication in a 60-year-old female with a clinical history of esophageal carcinoma which was diagnosed after performing a contrast-enhanced CT scan of the chest

Case presentation

A 60-year-old female with esophageal cancer who had undergone surgery presented to a general hospital with a two-week history of fever, malaise, massive hemoptysis, intolerance to ingestion, and thoracic back pain. She had a clinical history of esophageal cancer and 20 days prior to admission, she underwent esophagostomy and partial gastrectomy due to the presence of a tumoral lesion in the

cardia, which was proved to be a squamous cell carcinoma after performing transesophageal biopsy and esophagogastroscope. Histopathologic results after surgical excision of the tumoral lesion revealed invasive squamous cell carcinoma with moderate differentiation.

She underwent percutaneous endoscopic gastrostomy. Moreover, she received 30 radiation therapy and three chemotherapy treatments. She tried oral intake after two weeks post-operation but she did not tolerate and had nausea and vomiting. Her other past medical history was unremarkable. On admission, she was febrile and cachectic. She had a temperature and blood pressure of 38.5°C and 70/65 mmHg, respectively. Physical examination result was normal, except mild tenderness in per surgical region. Additionally, chest radiography was normal along with unremarkable urinalysis and complete blood count analysis. White blood cell count showed mild leukocytosis. Erythrocyte sedimentation rate (ESR) was 110 mm/h in the first hours followed by elevation. Multiple blood cultures had no growth.

Transthoracic echocardiography and electrocardiography were also normal. She was worked up by a sepsis plan. An abdominal ultrasound demonstrated mild sub hepatic fluid. The CT scan of the thorax, abdomen, and pelvis was performed to identify any occult septic focus and revealed a saccular out pouching with similar density to the aorta in a distal part of descending thoracic aorta with 12*12 mm diameter on the left side. A fluid collection was also observed in the posterior mediastinum around this area. These findings were compatible with mycotic aneurysm of the thoracic aorta (Figure 1).

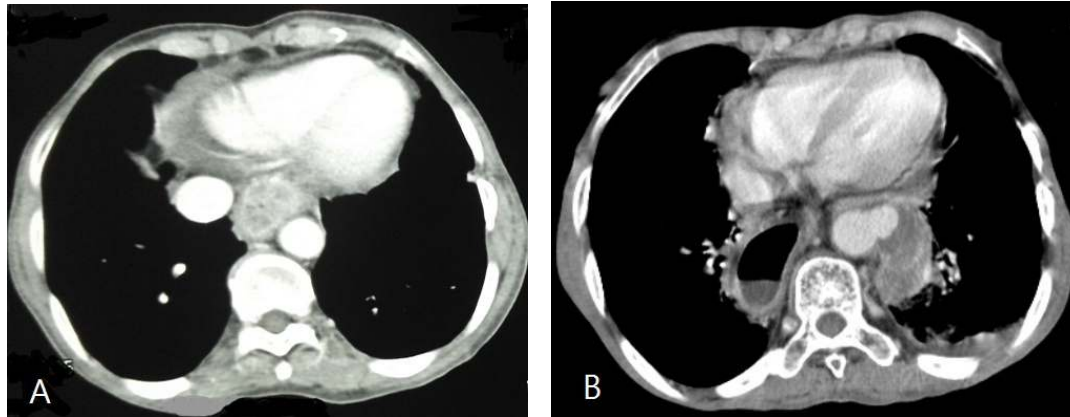


Figure 1. A) Preoperative contrast-enhanced axial CT scan showing esophageal thickening and normal descending thoracic aorta. B) Postoperative contrast-enhanced axial CT scan showing a saccular outpouching with similar density to the aorta in a distal part of descending thoracic aorta with an infective collection around this area

The clinical condition of the patient became worse within 24 h after performing a CT scan and she was transferred to the ICU. In consultation with a thoracic surgeon and an interventional radiologist, the medical team decided to repair the aorta with graft; however, the patient died after three days.

Discussion

Mycotic (or infective) aneurysms are localized and irreversible vascular dilatations caused by weakening and destruction of the vessel wall by an invasive organism establishing infective arteritis (2, 3, 5). The prevalence of mycotic aneurysm has been reported to range from 0.8-3.1% among patients who had a clinical history of reconstruction surgery for aortic aneurysm (3, 5). They are now rare in clinical practice constituting only 1-3% of all arterial aneurysms (5). Mycotic aortic aneurysms most commonly develop through bacterial inoculation of the diseased endothelium during bacteremia. Arterial wall infection usually causes a fast degeneration and destruction of the intima and medial layers with secondary aneurysm formation (3, 5, 9). A mycotic aneurysm can develop

from (a) contiguous spread from an adjacent infection, (b) septic emboli, (c) hematogenous seeding of organisms at the sites of endothelial injury, flow turbulence or existing aneurysm or (d) vascular trauma (5, 8). End arterial infection may arise through hematogenous seeding from distant septic foci (endocardial vegetation, infected thrombi or intravascular devices), lymphatic spread (particularly in patients with tuberculosis), contiguous extension (purulent pericarditis or osteomyelitis) or direct inoculation (iatrogenic during angiography or through intravenous drug misuse) (5).

The most common predisposing factor for mycotic aortic aneurysms was bacterial endocarditis in the pre-antibiotic era; however, this is now only observed in the minority of the cases (1, 3, 5). The principal current risk factors include atherosclerosis, vascular anomalies (i.e., pre-existing aneurysms, aortic coarctation, or patent ductus arteriosus), immune suppression status (i.e., malignancy, diabetes mellitus, alcohol misuse, immunosuppressive drug consumption, and HIV), and

intravenous drug consumption (3, 6, 9).

Pathologically, the vessel wall which becomes infected with bacteria is digested and then causes a false aneurysm which is unstable and prone to rapid expansion and rupture of the artery (2, 5). In most patients, mycotic aneurysms are solitary lesions; however, multiple aneurysms have been reported in some cases.

Initial symptoms of mycotic aneurysms are often non-specific; nonetheless, the most common presentations include a febrile illness with insidious onset, general malaise, weight loss, and gradual deterioration by uncontrolled sepsis (5, 6, 9). Clinical manifestations of mycotic aneurysm of the thoracic aorta are usually non-specific and depend on the site of infection as well as the cause of aneurysm formation. Dorsal pain may be the first clinical manifestation of the disease (5, 8, 9). In patients with a late presentation, the disease may manifest with profound septicemia or with consequences of rapid expansion or rupture of the aneurysm (5). Compressive symptoms, such as dysphagia, dyspnoea, hoarseness of voice, cough, and superior vena cava compression syndrome have been reported in a study (5). Our patient presented with fever, malaise, hemoptysis, and thoracic back pain who had a clinical history of esophageal cancer which was treated by esophagectomy and partial gastrectomy.

Leukocytosis and neutrophilia are present in more than three-quarters of cases. C-reactive protein (CRP) and ESR are almost elevated in all patients (8, 9). Our patient had leukocytosis and an elevated ESR. Blood cultures are positive in 50-85% of patients. Gram-positive bacteria, such as

Staphylococcal species, Enterococcus species, and Streptococcus pneumoniae are the most common culprits and are responsible for nearly two-thirds of cases.

The most common reported organism causing aortic mycotic aneurysm are streptococcus aureus and salmonella species. Aortic infection with Mycobacterium tuberculosis and fungi, especially *Candida albicans* has also been described in developing countries (2, 5, 6).

Mycotic aneurysms carry a very worse prognosis and a high mortality rate. Untreated mycotic aortic aneurysms can be fatal with a high risk of rupture, massive hemorrhage, or fulminant sepsis. Manifestations of aneurysm expansion and rupture correlate with an anatomical location. Thoracic aneurysms may present with tearing chest or interscapular pain (5). Dissections of the ascending thoracic aorta cause severe aortic regurgitation, myocardial ischemia, or even infarction. Cardiac tamponade, rupture of the thoracic aorta with massive hemorrhage, and hypovolemic shock may also happen (5, 6, 8).

Multi-detector CT angiography remains the modality of choice for the detection of aortic mycotic aneurysms, with sensitivity and specificity of 92-96% and 93-100%, respectively (7, 10). Additional advantages include the detection of synchronous or source lesions and three-dimensional reconstruction for the planning of interventional procedures. Suggestive features include new aneurysm formation, rapid expansion, or morphological change of known aneurysms, synchronous lesions, and intramural or perivascular gas, edema, soft tissue mass or stranding. Ring enhancement may also be observed. Disruption or disappearance of aortic

calcification is a late sign and may herald imminent rupture. In contrast, extravasation indicates this has already occurred (7, 10, 11). In our patient, a CT scan revealed secular outpouching in the distal part of descending thoracic aorta associated with a fluid collection in the posterior mediastinum.

Magnetic resonance angiography is an alternative modality but currently restricted by longer examination times and increased susceptibility to motion artifact. On the other hand, magnetic resonance imaging (MRI) is particularly useful for intracranial lesions, with sensitivity and specificity of 95-100% and 82-96%, respectively (12). Aortography only evaluates the vessel lumen, not the extravascular changes, and it increases the risk of distal embolization and rupture of the fragile inflamed arterial wall. Conventional angiography remains the gold standard; however, it is an invasive test and suffers the same limitations as direct aortography (5, 10).

Differentiation between infection and sterile inflammatory lesions requires correlation with the clinical presentation; however, suspicious features include a lobulated vascular mass, an indistinct irregular arterial wall, and perianeurysmal edema or soft tissue mass. There have been interests in using radionuclide-based imaging to identify and monitor inflammatory vascular lesions (5). In recent years, the diagnosis of thoracic mycotic aneurysms has been based on a various combination of the following criteria: (1) clinical presentation (i.e., pain, fever, concomitant infection, elderly patient with cardiovascular diseases, and/or immunosuppressive status), (2) positive laboratory findings (i.e., CRP, leukocytosis, and positive culture), (3) imaging findings

on CT and/MRI (i.e., saccular, eccentric, or multiloculated aneurysm; periaortic gas; periaortic mass; and rapid aortic expansion), and intraoperative findings (10,11).

Medical treatment alone is associated with poor prognosis with in-hospital mortality rate of 50% and event-free 1-year survival of only 32% (5, 6, 13). The gold standard for the treatment of mycotic aneurysm is resection, debridement of infected tissues, and graft replacement. The operative technique depends on aneurysm site, the experience of the surgical team, and the primary source of endovascular infection. On the presentation of a mycotic thoracic aneurysm, the traditional treatment is thoracotomy, partial or full cardiopulmonary bypass, open excision of the aneurysm sac, resection of surrounding infected tissue, and either extra-anatomic or in situ repair with homograft or antibiotic-soaked prosthetic graft (5, 6, 14).

The mortality rate after open surgical repair is reported as high as 40% which may be related to the severe medical comorbidities of the patients (i.e., diabetes, hypertension, coronary artery disease, or long period of steroid therapy), extensive surgeries, and unstable conditions of the patient secondary to aneurysm rupture or severe sepsis. In recent studies, it is recommended to perform endovascular therapy which is a minimally invasive procedure for the treatment of hemodynamically unstable and medically fragile patients (14, 15). Surgical intervention is considered after the completion of primary antibiotic therapy (4 to 6 weeks). Early surgery should be performed on patients with uncontrolled sepsis or when there is evidence of aortic rupture (5, 6, 13).

Intravenous antibiotic therapy is recommended after surgical intervention or endovascular therapy (6, 2, 7). In our case, the patient had a mycotic thoracic aneurysm after esophageal surgery. It was decided to perform in situ graft reconstruction; however, she died before performing any surgical treatment.

Conclusion

Mycotic aneurysms of the aorta are rare but can be universally life-threatening if not diagnosed or left untreated. Today, the gold standard modality of choice is CT angiography. Moreover, surgical or endovascular intervention alongside intensive antibiotic therapy remains the definitive treatment.

Conflicts of interest

None declared.

References

1. Parkhurst GF, Dekcer JP. Bacterial aortitis and mycotic aneurysm of the aorta; a report of twelve cases. *Am J Pathol.* 1955; 31:821-35.
2. Muller BT, Wegener OR, Grabitz K, Pillny M, Thomas L, Sandmann W. Mycotic aneurysms of the thoracic and abdominal aorta and iliac arteries: experience with anatomic and extra-anatomic repair in 33 cases. *J Vasc Surg.* 2001; 33:106-13.
3. Dolapoglu A, de la Cruz KI, Coselli JS. Management of a mycotic thoracoabdominal aortic aneurysm involving the celiac artery. *Texas Heart Inst J.* 2016; 43:528-30.
4. Osler W. The Gulstonian lectures on malignant endocarditis. *Br Med J.* 1885; 1:577-9.
5. Fisk M, Peck LF, Miyagi K, Steward MJ, Lee SF, Macrae MB, et al. Mycotic aneurysms: a case report, clinical review and novel imaging strategy. *QIM.* 2012; 105:182-8.
6. Tsao JW, Marder SR, Goldstone J, Bloom AI. Presentation, diagnosis, and management of arterial mycotic pseudoaneurysms in injection drug users. *Ann Vasc Surg.* 2002; 16:652-62.
7. Lee WK, Mossop PJ, Little AF, Fitt GJ, Vrazas JI, Hoang JK, et al. Infected (mycotic) aneurysms: spectrum of imaging appearances and management. *Radiographics.* 2008; 28:1853-68.
8. Oderich GS, Panneton JM, Bower TC, Cherry KJ Jr, Rowland CM, Noel AA, et al. Infected aortic aneurysms: aggressive presentation, complicated early outcome, but durable results. *J Vasc Surg.* 2001; 34:900-8.
9. Gross C, Harringer W, Mair R, Wimmer-Greinecker G, Klima U, Brucke P. Mycotic aneurysms of the thoracic aorta. *Eur J Cardiothorac Surg.* 1994; 8:135-8.
10. Macedo TA, Stanson AW, Oderich GS, Johnson CM, Panneton JM, Tie ML. Infected aortic aneurysms: imaging findings. *Radiology.* 2004; 231:250-7.
11. Moriarty JA, Edelman RR, Tumei SS. CT and MRI of mycotic aneurysms of the abdominal aorta. *J Comput Assist Tomogr.* 1992; 16:941-3.
12. Sorelius K, di Summa GP. On the diagnosis of mycotic aortic aneurysms. *Clin Med Insights Cardiol.* 2018; 12:117954818759678.
13. Hsu RB, Chang CI, Wu IH, Lin FY. Selective medical treatment of infected aneurysms of the aorta in high risk patients. *J Vasc Surg.* 2009; 49:66-70.
14. Aoki C, Fukuda W, Kondo N, Minakawa M, Taniguchi S, Daitoku K, et al. Surgical management of mycotic aortic aneurysms. *Ann Vasc Dis.* 2017; 10:29-35.
15. Clough RE, Black SA, Lyons OT, Zayed HA, Bell RE, Carrell T, et al. Is endovascular repair of mycotic aortic aneurysms a durable treatment option? *Eur J Vasc Endovasc Surg.* 2009; 37:407-12.