

Save the Children from Gastric and Intestinal Perforation Secondary to Small Magnet Ingestion by Educating Families with the Help of Pediatricians

*Manoochehr Karjoo¹, Alexander Dragnich², Sara Karjoo³, Qurratul Ann Warsi⁴

¹ Professor, Pediatric Gastroenterology, Golisano Childrens Hospital, Upstate Medical University, Syracuse NY 13210 USA.

² 4th Year Medical Student, Upstate Medical University, USA.

³ Assistant Professor, Pediatric Gastroenterology, Johns Hopkins University & Morsani College of Medicine, University of South Florida, USA.

⁴ Department of Epidemiology and Biostatistics, University of California San Francisco, USA.

Abstract

The ingestion of foreign bodies is a comprehensive problem affecting the pediatric population, especially under 5 years of age. The ingestion of 2 or more magnets may lead to their attraction over planes of intervening soft tissue with enough force to cause significant complications including obstruction, fistula formation or even perforation.

This case series report have documented the cases of 4 children age 2-9 years, who have experienced a variety of complications from magnet ingestion. Included are the cases of a 2 years old boy and 9 years old girl with bowel perforation, a 7 years old boy with mucosal erosion, and a 4 years old boy who underwent magnet retrieval before complications arose.

Key words: Children, Intestinal Perforation, Foreign Body Ingestion, Magnet Ingestion.

*Please cite this article as: Karjoo M, Dragnich A, Karjoo S, Warsi AQ. Save the Children from Gastric and Intestinal Perforation Secondary to Small Magnet Ingestion by Educating Families with the Help of Pediatricians. Int J Pediatr 2017; 5(3): 4449-55. DOI: **10.22038/ijp.2017.8263**

Corresponding Author:

Manoochehr Karjoo, M.D., FAGA, Professor, Pediatric Gastroenterology, Hepatology and Nutrition, Golisano Children's Hospital, Upstate Medical University, 725 Irving Avenue, Suite 504, Syracuse NY 13210, USA. Fax # 315 464 8445

Email: Karjoom@upstate.edu

Received date Jan.10, 2017; Accepted date: Jan. 22, 2017

1- INTRODUCTION

While most ingestions of small sized items often resolve without any intervention, cases involving rare earth magnets require unique therapeutic considerations. These magnet ingestions have been documented in the literature to cause a variety of severe complications. These complications have lead the NASPGHAN to create a treatment guideline for these magnet ingestions being much more aggressive than cases of non-magnetized objects. We are reporting a case series of 4 children; we aim to provide more insight into the exposure and risks of gastroesophageal magnetic impaction can pose in pediatric population.

2- CASE SERIES REPORT

2-1. Case. 1

A two years old boy was referred to our facility because of abdominal pain and refusal of feeding for one week. His primary care physician had diagnosed him with a viral gastritis, however with the persistence and exacerbation of his symptoms an abdominal X-ray was done. This revealed 16 adherents yet well demarcated opacities that were presumed to be magnets, which were visualized, in the right upper quadrant to form a long rod (Figures 1, 2).

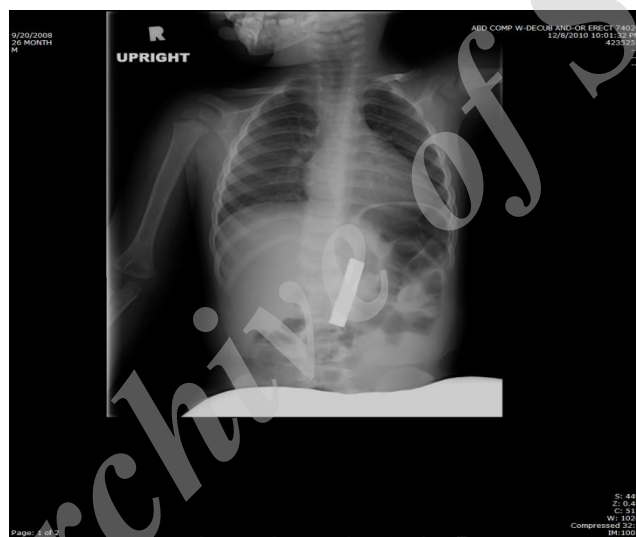


Fig.1: An abdominal X-ray illustrating a 16 magnet ingestion in the GI tract.

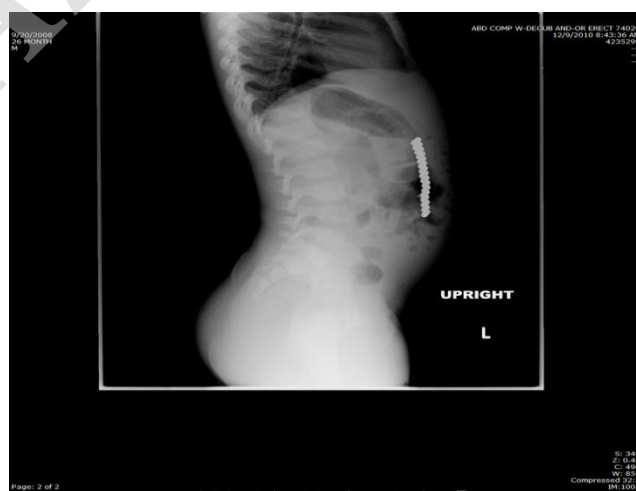

Fig.2: Lateral view.

Further inquiry revealed that the parents were unaware of any recent magnet ingestion, because he was at his grandmother house. His physical examination demonstrated stable vital signs with mild abdominal tenderness. An emergency endoscopy was done. The esophagus was grossly normal however thirteen magnets of one cm diameter each were extracted from the pre pyloric area with a corresponding ulceration where they had embedded in mucosa. On further investigation we could not identify the remaining three magnets in the stomach or

duodenum however repeat abdominal films suggested their location to be in the small bowel. Consequently, surgical consultation was obtained where exploratory laparotomy deemed necessary. Surgical exploration was performed which revealed five discrete areas of small bowel perforation in the distal ileum (**Figures 3, 4**). Three more magnets were removed, the perforated segments were resected and the bowel re-anastomosed. The surgery and remainder of his hospitalization were uneventful and without complication.

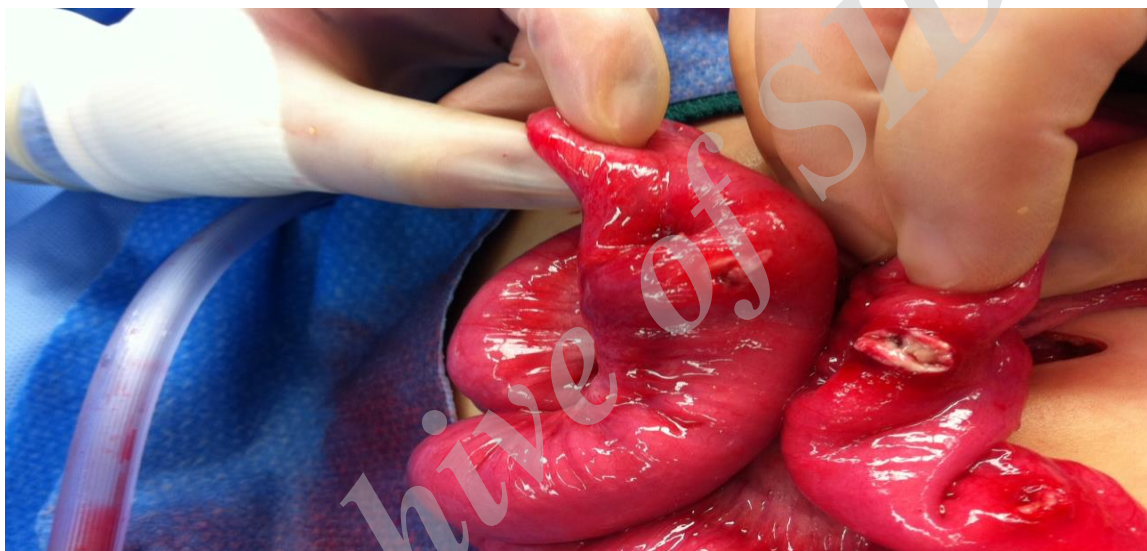


Fig.3: First view of perforation.

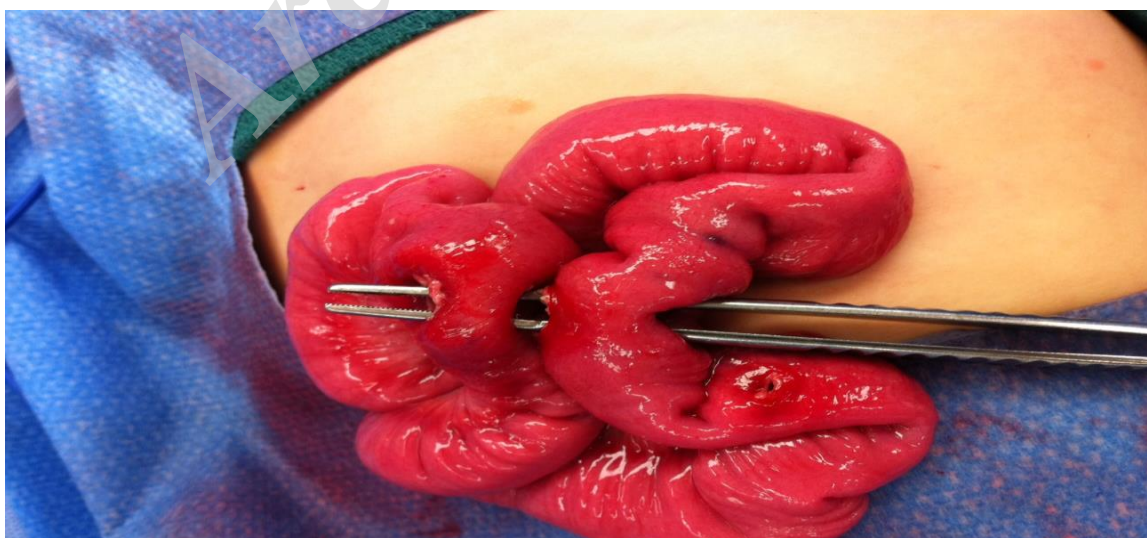


Fig.4: Second view of perforation.

Fig. 3 and 4 show five perforations of small bowel induced by magnet compression.

2-2. Case. 2

A four years old boy was referred to our facility with the history of magnet ingestion. His sister gave the magnets to him a few hours previously, swallowed, and as of that hour he remained asymptomatic. With the provided history an X-rays were obtained, revealing multiple foreign bodies presumed to be magnets at the lower portion of the esophagus and others in the mid-abdomen. On Endoscopic investigation multiple round magnets each of one centimeter

diameter were identified with three residing at the gastroesophageal junction and three more at the fundus. Attempts at endoscopic extraction of the magnets were unsuccessful, as they had become tightly attached to one another with intervening tissue. Accordingly, laparotomy was pursued during which 3 magnets were removed from the gastroesophageal junction and three more from the fundus. The remaining magnets had successfully passed into the colon and required no intervention (**Figures 5, 6**).

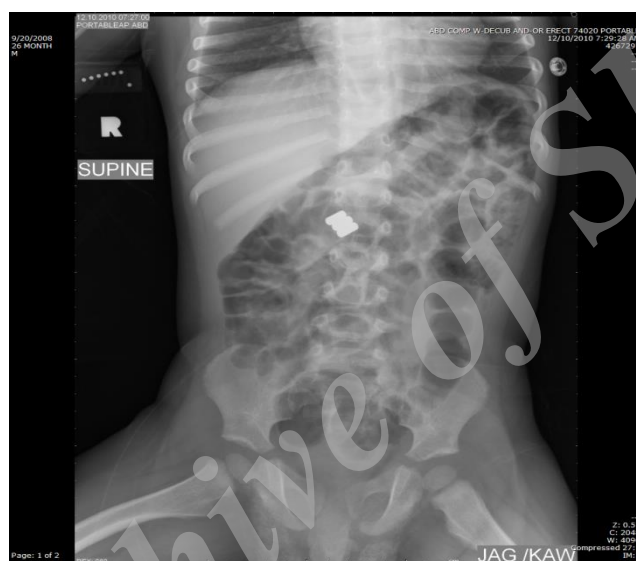

Fig.5: Showing Magnet in the GI system.

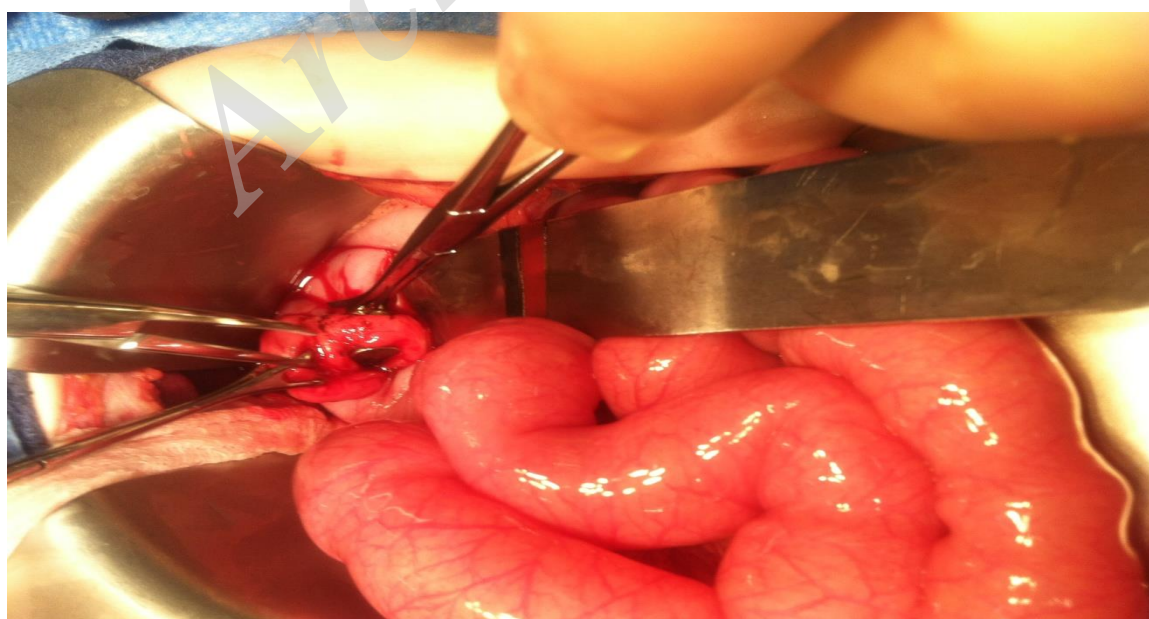


Fig.6: Magnets at lower part of esophagus and fundus of stomach.

2-3. Case. 3

A seven years old boy presented to our facility after several days worsening abdominal pain. On abdominal X-ray one opacity was clearly visualized in the proximal stomach, close to the fundus. On further inquiry the mother reported he had been playing with new magnetized toys for several days with concern that he may have ingested some of their components. With this history, endoscopy was immediately pursued however no foreign bodies on the initial mucosal survey. There was however one focal area of mucosal inflammation in an area roughly corresponding to the radiographic finding. After forceps was placed adjacent to the area of inflamed mucosa, a repeat X-ray was obtained confirming the foreign body presence under that inflamed locus. Two magnets were removed surgically. The stomach was perforated and needed resection of necrotic area.

2-4. Case. 4

A nine years old girl presented to our facility with several days of progressively worsening abdominal pain and lack of stooling. Abdominal X-ray was obtained showing a mid-intestinal small bowel obstruction with corresponding air fluid levels. Further historical investigation revealed that the child had been playing with new toys, among which was a small plastic covered magnet. Her mother expressed concern that she may have been playing with the toys inside her mouth. Patient developed a significant worsening of her abdominal pain within hour. Surgery was consulted and an emergency laparotomy was pursued which confirmed the obstruction and an area of small bowel perforation. The offending magnets were extracted, the necrotic length of small bowel was removed, and the small bowel segments were re-anastomosed.

3- DISCUSSION AND CONCLUSION

The pediatric population has long been identified to be at significant and unique risk for foreign body ingestion and NASPGHAN has created a treatment guideline (1-3), based on the size and location of the object in question. The advent of small-scale high-powered magnetic components has changed the conversation however, leading to the creation of new clinical algorithms (1, 4). This change in management strategies is due to the amazing strength that characterizes certain among these magnets, namely the rare earth magnets which can have substantial attractive forces despite measuring as little as 1 cm. Their use in toys and amateur jewelry has expanded, which concurrently place them within arm's reach of the population most at risk for foreign body ingestion (3). Following this, reports of their accidental ingestion, and their unique complications have arisen, all underpinned by the magnets ability to attract and fixate to one another even across significant planes of soft tissue (1). When one magnet is ingested without any other metallic or magnetic material, it was found that these objects behaved as other foreign bodies might, often passing uneventfully requiring no intervention outside of observation and support.

As has been described in the literature, we hypothesized that problems arise when two magnets are ingested at two discreet time points. With sufficient time separating ingestions, the objects are allowed to pass into two discrete portions of the GI tract. As these objects traverse the gastrointestinal tract GI tract, they will eventually approximate themselves enough to create a magnetic attraction of sufficient force to overwhelm the peristaltic forces of the gut and the elastic forces of the structural connective tissue. These magnetic forces have been documented to approximate even very spatially disparate bowel loops which can lead to obstruction, ulceration, fistula formation, and even

perforation in the most severe cases (5). The cases we document here illustrate a variety of these complications as well as the favorable outcome that can be obtained from early retrieval of the magnets. A failure to retrieve these objects can lead to pressure necrosis and focal ischemia across the tightly approximated bowel, thus leading to the myriad of complications described in the literature. Consideration for these complications must be entertained even with ingestion single magnets, if other metallic objects are subsequently ingested.

The cases chronicled here contain several common features that help characterize their shared clinical presentations. Most noticeably all magnets ingested were of nearly equivalent size, all being of about 1cm diameter, and there were no sharp sides or protrusions from the foreign bodies that might have independently led to perforations or lacerations within the bowel. Additionally, in all cases there was ingestion of at least 2 magnets of presumably equivalent power, without involvement of other magnetically active objects. With that being said, these cases also demonstrate a great deal of variability in respect to the number of magnets ingested, ages of the patients, and severity of their presentation. This variability allows this group of cases to showcase some of the very salient clinical issues regarding diagnosis and treatment of magnet ingestion.

It is important to note that the presentation of these patients can be highly variable, which illustrates the importance of thorough questioning when foreign body ingestion is suspected. Reports have documented not only their many unique clinical complications, but also the varying degrees of clinical severity with which patients present (6-8). The latter observation is of central importance because delays in the diagnosis of these patients may lead to devastating

consequences (8). We demonstrate in this series the favorable outcomes that can be obtained from early identification of at risk children and resultant aggressive intervention. Evidence in the literature of the danger that these powerful rare earth magnets pose has grown over the years; with a 2012 Consumer Product Safety Commission (CPSC) report documenting nearly 80 reported cases with one fatality (9). Concerted efforts of this agency, a CDC (Centers for Disease Control) report in 2006, and by NASPGHAN helped drive the passage of regulations that helped mitigate the danger such magnets pose. These included the Consumer Product Safety Improvement Act whereby the sale of rare earth magnets for the use by children under 14 has been prohibited which took effect in 2009, as well as the current CPSC magnet set rule that limits the maximum strength of small magnets in sets (9,10). The forced recall of these objects was a decisive step in limiting further harm to at risk children, and this case series serves to further document the risks associated with changing that position.

4- CONFLICT OF INTEREST: None.

5- REFERENCES

1. Kramer RE, Lerner DG, Lin T, Manfredi M, Shah M, Stephen TC, Gibbons TE, et al. Management of ingested Foreign Bodies in children: a clinical report of the NASPGHAN endoscopy committee. *JPGN* 2015;60:4
2. Litovitz TL, Klein-Schwartz W, White S, Cobaugh DJ, Youniss J, Omslaer JC, et al. 2000 annual report of the American Association of Poison Control Centers Toxic Exposure Surveillance System. *Am J Emerg Med.* 2001; 19(5):337-95.
3. Hussain SZ, Bousvaros A, Gilger M, Mamula P, Gupta S, Kramer R, et al. Management of ingested magnets in children. *J Pediatr Gastroenterol Nutr* 2012; 55:239-42.

4. Cauchi, JA, Shawis, RN. Multiple magnet ingestions and gastrointestinal morbidity. *Arch Dis Child* 2002; 87: 539-40.
5. Honzumi M, Shigemori C, Ito H, Mohri Y, Urata H, Yamamoto T. An intestinal fistula in a 3-yearold child caused by the ingestion of magnets: report of a case. *Surg Today* 1995; 25: 552-3.
6. Hernández Anselmi E, Gutiérrez San Román C, Barrios Fontoba JE, Ayuso González L, Valdés Dieguez E, Lluna González J, et al. Intestinal perforation caused by magnetic toys. *J Pediatr Surg* 2007; 42: E13-E16.
7. McCormick S, Brennan P, Yassa J, Shawis R. Children and mini-magnets: an almost fatal attraction. *Emerg Med J* 2002; 19:71-3.
8. Butterworth J, Feltis B. Toy magnet ingestion in children: revising the algorithm. *J Pediatr Surg* 2007; 42: E3-E5.
9. Safety Standard for Magnet Sets: A proposed Rule by the Consumer Product Safety Commission. Available at: <https://www.federalregister.gov/documents/2012/09/04/2012-21608/safety-standard-for-magnet-sets>. Accessed February 7, 2017
10. 79 FR 59961 – Final Rule: Safety standard for magnet sets. Available at: <https://www.gpo.gov/fdsys/granule/fr-2014-10-03/2014-23341>. Accessed June 17, 2016.