

# Recurrent Dislocation of The Extensor Carpi Ulnaris Tendon in a Water-Polo Athlete

Ioannis P. Stathopoulos,<sup>1,2,\*</sup> Konstantinos Raptis,<sup>1</sup> Efstathios G. Ballas,<sup>1,3</sup> and Sarantis-Petros G. Spyridonos<sup>1</sup>

<sup>1</sup>Department of Upper Limb and Hand Surgery and Microsurgery, KAT Hospital, Athens, Greece

<sup>2</sup>Third Orthopedic Department, KAT Hospital, University of Athens, Athens, Greece

<sup>3</sup>First Orthopedic Department, Attikon Hospital, University of Athens, Athens, Greece

\*Corresponding author: Ioannis P. Stathopoulos, Third Orthopaedic Department, University of Athens, KAT Hospital, 10 Athinas str., Kifissia, PC: 14561, Athens, Greece. Tel: +30-2108018123, Fax: +30-2108018122, E-mail: ipstathopoulos@gmail.com

Received 2014 April 21; Revised 2014 May 24; Accepted 2014 June 10.

## Abstract

**Introduction:** Dislocation/subluxation of the Extensor Carpi Ulnaris (ECU) tendon is a rare condition in the general population, but is a common problem among athletes that subject their wrists to forceful rotational movements. Pain and snapping sensation at the dorsoulnar aspect of the wrist especially during supination are the predominant symptoms that often necessitate surgical intervention.

**Case Presentation:** We present a case of a professional water-polo athlete with recurrent ECU tendon dislocation, in whom a combination of direct repair of the tendon's subsheath and reinforcement with an extensor retinaculum graft led to definitive resolution of her symptoms and resulted in her uneventful return to high-level sport activities 4 months postoperatively.

**Conclusions:** The treatment of symptomatic ECU instability is still controversial, especially for acute dislocations. Depending on the type of injury many surgical techniques have been proposed. Combination of direct repair of the tendon's subsheath and reinforcement with an extensor retinaculum graft is a reliable option.

**Keywords:** Extensor Carpi Ulnaris, Dislocation, Subluxation

## 1. Introduction

Ulnar-sided wrist pain is a common symptom among athletes resulting from acute or chronic injury. Numerous complex structures can be affected, including the Extensor Carpi Ulnaris (ECU) tendon. The ECU originates from the lateral epicondyle of the humerus (and the dorsal surface of the ulna) and has its tendon's insertion on the base of the fifth metacarpal. At the wrist, the ECU tendon runs through the sixth dorsal compartment within its groove along the distal ulna in its own subsheath that lies beneath the extensor retinaculum (1, 2).

The ECU tendon and its sheath are thought to be important not only in distal radio-ulnar joint stability, but also in the dynamic stabilization of the wrist, through its pronation effect on the distal carpal row (2, 3). Traumatic injuries to the ECU tendon resulting in dislocation or subluxation are rare in the literature (4, 5). However, they may be more common than originally suspected because they are often misdiagnosed, resulting in recurrent dislocation and delayed treatment (6).

We present a case of a professional water-polo athlete with recurrent ECU tendon dislocation along with the diagnostic algorithm and the surgical treatment applied in order to achieve the preinjury sports activity level.

## 2. Case Presentation

A 22-year-old female professional water-polo player presented to our Hand Department complaining of persistent pain on the dorsoulnar aspect of the right wrist (dominant hand) during the last 4 months, aggravated by sport activity, and not responding to medical treatment or rest. The patient did not report any acute trauma at that region and noted that her symptoms worsened while shooting. At that time a painful snapping sensation over the dorsoulnar aspect of the wrist followed the forceful forearm rotation. Physical examination revealed swelling, edema and tenderness over that area. A "clunk" and palpable dislocation of the ECU tendon along the ulna head with active or passive supination and ulnar deviation of the wrist was observed. Hand and finger function was normal, and neurovascular examination showed no abnormality.

The patient underwent radiological investigation with plain radiographs of the wrist, that were negative for any bone pathology (Figure 1A and B), and dynamic Ultrasound (U/S) at rest (with the wrist in 0° of flexion-extension) and during pronation and supination with comparison to the contralateral ECU tendon. During supination, the unstable ECU tendon slid abruptly over the ulnar wall of the distal ulnar groove and dislocated

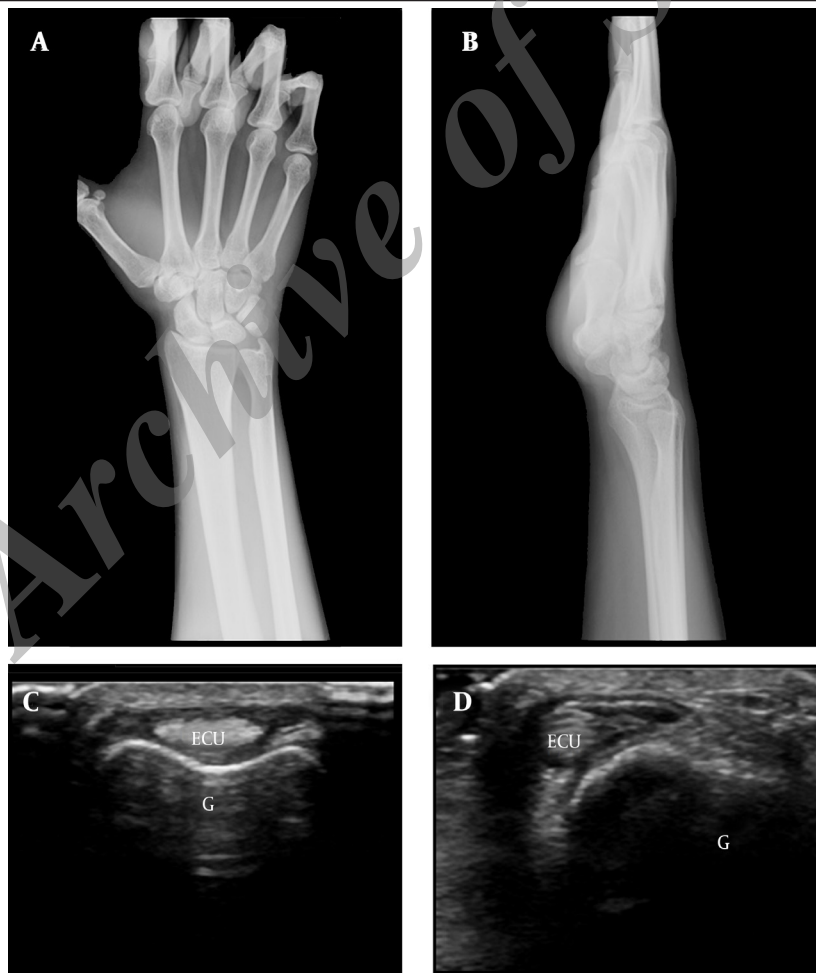volarly, while during pronation the tendon relocated into the groove (Figure 1C and D).

Diagnosis of recurrent ECU tendon dislocation was made on the basis of clinical history, physical examination and imaging findings. As the patient's symptoms had not improved after a 4-month period of conservative management and in conjunction with a highly demanding sport, surgical intervention was opted.

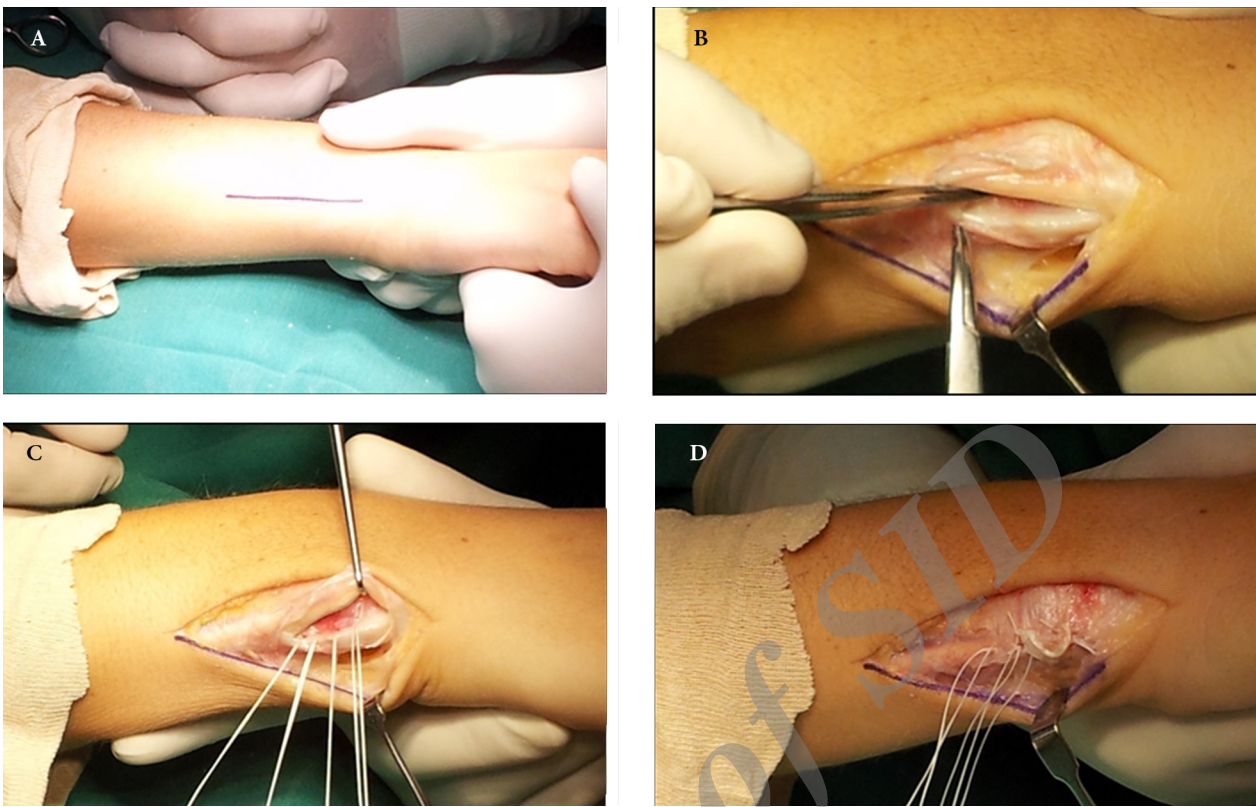
Surgical reconstruction of ECU tendon sheath was carried out under axillary block anesthesia using a high humerus tourniquet. A straight dorsomedial incision was made along the distal ulna starting 5 cm proximal to the wrist and ending 1 cm proximal to the joint (Figure 2A). The extensor retinaculum, found to be intact, was opened longitudinally over the ulnar aspect. Dislocation of the ECU tendon in ulnar-palmar direction was confirmed with the forearm in supination and the wrist in palmar flexion. The fibro-osseous sheath was found to be torn along its entire length from the ulnar retaining wall (Figure 2B). The distal ulnar groove was deep enough to retain the tendon in its normal position and it was not reconstructed. The ECU ten-

don was elevated, reduced into the groove and 4 mini bone suture anchors were placed along the groove's ulnar margin (Figure 2C). The sutures were then passed through the ulnar border of the ECU sheath in horizontal mattress fashion and were tied, securing tendon sheath to bone. A piece of extensor retinaculum was used as a graft, to strengthen the reconstructed sheath (Figure 2D). Splinting of the humerus-forearm with the elbow flexed to 90° and the wrist in approximately 30° of extension, radial deviation, and pronation was applied for 6 weeks. A progressive rehabilitation program was prescribed after cast removal, including active and passive wrist flexion, extension, forearm supination and pronation, and progressive strengthening with gradual return to sport activities. The patient was allowed to fully participate in her team's schedule 4 months postoperatively. Follow-up evaluation 12 months postoperatively revealed no recurrent dislocation of the ECU tendon and normal painless range of motion of the affected wrist.

All procedures concerning the management of the patient were in accordance with the Helsinki Declaration of 1975, as revised in 1983.



**Figure 1.** A) Anteroposterior; B) Lateral plain radiograph of the patient's right wrist demonstrating no pathology; C) Transversal U/S scan at the level of ECU tendon's groove with the forearm in pronation. The ECU tendon is lying in its groove (normal position); D) With the forearm in supination the ECU tendon is dislocated volarly, at the ulnar side of its groove.



**Figure 2.** A) Site of incision; B) The ECU tendon's fibro-osseous sheath is found to be torn along its entire length from the ulnar retaining wall; C) Four mini bone suture anchors were placed along the groove's ulnar margin; D) The sutures were then passed through the ulnar border of the ECU sheath in horizontal mattress fashion and were tied, securing tendon sheath to bone. A piece of extensor retinaculum was used as graft, to strengthen the reconstructed sheath.

### 3. Discussion

Dislocation/subluxation of the ECU tendon is a rare condition first described by Vulpius in 1964 that results from rupture or attenuation of the tendon's fibro-osseous sheath, though a small degree of subluxation might occur in healthy individuals (7, 8). It is usually observed in athletes especially tennis players and golfers at the dominant side (4, 8-10). Some authors believe that there are predisposing factors for the appearance of the condition, namely flattening of the distal ulnar groove (due to congenital variation of ulna's anatomy or due to progressive wear down of the ulnar lip of the groove with repeated subluxation of the tendon) and impaired mechanical properties of the subsheath (due to congenital variation of the connective tissue or due to over-use) that lead to dislocation/subluxation after an injury (9). The mechanism of injury is either direct trauma to the wrist or an acute rotational wrist injury (vigorous supination, flexion and ulnar deviation) or repetitive trauma that assembles the latter. The patient usually appears with ulnar-sided wrist pain and reports a "popping" sensation at that area during supination/pronation and/or flexion/extension of the wrist.

Diagnosis is based on the clinical findings and the history of injury. Reproduction of the dislocation/subluxation of the tendon by passive or/and energetic supination, flex-

ion and ulnar deviation of the wrist provokes the patient's symptoms and can be visible, felt by palpation or even heard. Recently the "ice cream scoop test" was introduced for that purpose (11). When physical examination is inconclusive or when confirmation of the diagnosis is needed, Magnetic Resonance Imaging (MRI) and U/S might be helpful. Magnetic resonance imaging scans can reveal disruption, thickening or induration of the ECU sheath and exclude/reveal other underlying pathology, such as tendonitis or partial rupture of the tendon, but cannot document dynamic instability (8). On the other hand, U/S offers dynamic examination of the wrist and can visualize the abnormal movement of the tendon during flexion/extension and supination/pronation of the wrist (8, 9).

Dislocation of the ECU tendon is classified according to Inoue and Tamura into three types (4). In type A, the fibro-osseous sheath is torn at its ulnar side and the tendon may lie beneath the fibrous sheath. In type B, the sheath is disrupted from the radial wall and lies in the groove beneath the tendon, thus impeding healing. Finally, in type C, there is detachment of the groove's periosteum from the ulnar side in continuity with the sheath, thus forming an expanded and redundant false pouch into which the tendon is dislocated. Allende and

Le Viet modified this classification (five types; A: normal, B: type C of Inoue and Tamura's system, C1: type A of Inoue and Tamura's system, C2: type B of Inoue and Tamura's system, D: preserved but contracted fibro-osseous sheath) (12). Although these classifications are the only ones for such a condition, they are applied only for volar dislocations of ECU and do not include cases with predominantly dorsal instability (8). Our patient was found (intraoperatively) to have a type A lesion according to Inoue and Tamura's classification.

The treatment of symptomatic ECU instability is still controversial, especially for acute dislocations. Conservative treatment includes rest, ice-therapy, non-steroid anti-inflammatory drugs, steroid injections and splinting or casting of the wrist. Steroid injections should be avoided because they add an increased risk of tendon rupture (9). Various casting/splinting techniques have been described with short or long-arm casts/splints that immobilize the wrist in neutral position, supination (up to 45°) or pronation (up to 90°), various degrees of extension, and radial deviation (6, 9, 10, 13-15). The time of cast/splint application is in most cases 2 - 16 weeks (6, 9, 10, 12-15).

Surgical treatment is preferable in chronic instability, because degeneration of fibro-osseous sheath's lesions renders them incurable. It is used also in acute lesions when conservative treatment has failed. A variety of techniques have been introduced (4-6, 9, 12, 16). Many surgeons use different procedures depending on the type of sheath lesions. Direct suture of the torn edges is preferable when they are not contracted or attenuated. In type A, according to Inoue and Tamura's classification, sheath reconstruction can be achieved with the use of strips from the extensor retinaculum (4, 12, 17). In type B, direct reattachment is usually feasible; if not reconstruction with retinacular free flaps can be performed (4, 12). In type C, obliteration of the false pouch can be achieved with periosteum reattachment using transosseous sutures or anchor sutures (4, 9, 12). Deepening of the ulnar groove with special instruments lessen the possibility of relapse (9, 12). Yet, there is no consensus as to the optimal method. In our patient a combination of direct repair of the tendon's subsheath and reinforcement with an extensor retinaculum graft was selected due to the patient's professional demands. There was no need for groove deepening. Following surgery cast/splint immobilization of the limb was applied for a few weeks. Physiotherapy after the removal of the cast/splint (in both conservative and surgical treatment) is of paramount importance and usually accelerates patients' return to their previous activities. In our patient, surgical reconstruction of ECU tendon sheath and the rehabilitation program followed led to definitive resolution of her symptoms and resulted in her uneventful return to high-level sport activities 4 months postoperatively.

## Acknowledgments

We would like to thank Dr. Georgios Delimpasis (MRI department, 251 HAF and VA hospital, Athens, Greece) for the ultrasound imaging.

## Footnote

**Authors' Contribution:** Study concept and design: Sarantis-Petros G. Spyridonos; acquisition of data: Konstantinos Raptis; analysis and interpretation of data: Ioannis P. Stathopoulos, Sarantis-Petros G. Spyridonos; drafting of the manuscript: Ioannis P. Stathopoulos, Konstantinos Raptis, Efstathios G. Ballas; critical revision of the manuscript for important intellectual content: Sarantis-Petros G. Spyridonos; study supervision: Sarantis-Petros G. Spyridonos.

## References

- Inoue G, Tamura Y. Recurrent dislocation of the extensor carpi ulnaris tendon. *Br J Sports Med.* 1998;**32**(2):172-4. [PubMed: 9631228]
- Spinner M, Kaplan EB. Extensor carpi ulnaris. Its relationship to the stability of the distal radio-ulnar joint. *Clin Orthop Relat Res.* 1970;**68**:124-9. [PubMed: 5414710]
- Salva-Coll G, Garcia-Elias M, Leon-Lopez MM, Llusa-Perez M, Rodriguez-Baeza A. Role of the extensor carpi ulnaris and its sheath on dynamic carpal stability. *J Hand Surg Eur Vol.* 2012;**37**(6):544-8. doi: 10.1177/1753193411430921. [PubMed: 22117013]
- Inoue G, Tamura Y. Surgical treatment for recurrent dislocation of the extensor carpi ulnaris tendon. *J Hand Surg Br.* 2001;**26**(6):556-9. doi: 10.1054/jhsb.2001.0615. [PubMed: 11884112]
- Rowland SA. Acute traumatic subluxation of the extensor carpi ulnaris tendon at the wrist. *J Hand Surg.* 1986;**11**(6):809-11. doi: 10.1016/s0363-5023(86)80227-1.
- Burkhart SS, Wood MB, Linscheid RL. Posttraumatic recurrent subluxation of the extensor carpi ulnaris tendon. *J Hand Surg.* 1982;**7**(1):1-3. doi: 10.1016/s0363-5023(82)80002-6.
- Vulpis J. Habitual Dislocation of the Extensor Carpi Ulnaris Tendon. *Acta Orthop Scand.* 1964;**34**:105-8. [PubMed: 14124641]
- Pratt RK, Hoy GA, Bass Franzcr C. Extensor Carpi Ulnaris Subluxation or Dislocation? Ultrasound Measurement of Tendon Excursion and Normal Values. *Hand Surg.* 2004;**09**(02):137-43. doi: 10.1142/s0218810404002212. [PubMed: 15810097]
- MacLennan AJ, Nemecek NM, Waitayawinyu T, Trumble TE. Diagnosis and anatomic reconstruction of extensor carpi ulnaris subluxation. *J Hand Surg Am.* 2008;**33**(1):59-64. doi: 10.1016/j.jhsa.2007.10.002. [PubMed: 18261666]
- Montalvan B, Parier J, Brasseur JL, Le Viet D, Drape JL. Extensor carpi ulnaris injuries in tennis players: a study of 28 cases. *Br J Sports Med.* 2006;**40**(5):424-9. doi: 10.1136/bjism.2005.023275. [PubMed: 16632573]
- Ng CY, Hayton MJ. Ice cream scoop test: a novel clinical test to diagnose extensor carpi ulnaris instability. *J Hand Surg Eur Vol.* 2013;**38**(5):569-70. doi: 10.1177/1753193412460816. [PubMed: 22988025]
- Allende C, Le Viet D. Extensor carpi ulnaris problems at the wrist-classification, surgical treatment and results. *J Hand Surg Br.* 2005;**30**(3):265-72. doi: 10.1016/j.jhsb.2004.12.007. [PubMed: 15862366]
- Patterson SM, Picconatto WJ, Alexander JA, Johnson RL. Conservative treatment of an acute traumatic extensor carpi ulnaris tendon subluxation in a collegiate basketball player: a case report. *J Athl Train.* 2011;**46**(5):574-6. [PubMed: 22488145]
- Rayan GM. Recurrent dislocation of the extensor carpi ulnaris in athletes. *Am J Sports Med.* 1983;**11**(3):183-4. [PubMed: 6869662]
- Beckenbaugh RD. Acute traumatic subluxation. *J Hand Surg.* 1987;**12**(5):810. doi: 10.1016/s0363-5023(87)80082-5.
- Eckhardt WA, Palmer AK. Recurrent dislocation of extensor carpi ulnaris tendon. *J Hand Surg.* 1981;**6**(6):629-31. doi: 10.1016/s0363-5023(81)80151-7.
- Cift H, Ozkan K, Soylemez S, Ozkan FU, Cift HB. Ulnar-sided pain due to extensor carpi ulnaris tendon subluxation: a case report. *J Med Case Rep.* 2012;**6**:394. doi: 10.1186/1752-1947-6-394. [PubMed: 23173564]