

Outcome of Radial Head Arthroplasty in Comminuted Radial Head Fractures: Short and Midterm Results

Arash Moghaddam,^{1,2,*} Tim Friedrich Raven,¹ Eike Dremel,³ Stefan Studier-Fischer,³ Paul Alfred Grutzner,³ and Bahram Biglari³

¹Heidelberg Trauma Research Group (HTRG), Division of Trauma and Reconstructive Surgery, Center for Orthopedics, Trauma Surgery and Spinal Cord Injury, University Hospital Heidelberg, Heidelberg, Germany

²Division of Trauma and Reconstructive Surgery, Center for Orthopedics, Trauma Surgery and Spinal Cord Injury, University Hospital Heidelberg, Heidelberg, Germany

³Trauma and Reconstructive Surgery Unit, BG Trauma Clinic, Ludwigshafen, Germany

*Corresponding author: Arash Moghaddam, Division of Trauma and Reconstructive Surgery, Center for Orthopedics, Trauma Surgery and Spinal Cord Injury, University Hospital Heidelberg, Heidelberg, Germany. Tel: +49-62215626398, Fax: +49-62215626298, E-mail: arashmoghaddam@web.de

Received 2014 June 16; Revised 2014 September 29; Accepted 2014 October 3.

Abstract

Background: Comminuted radial head fractures are often associated with secondary injuries and elbow instability.

Objectives: The aim of this retrospective study was to evaluate how well the modular metallic radial head implant EVOLVE® prosthesis restores functional range of motion (ROM) and stability of the elbow in acute care.

Patients and Methods: Eighty-five patients with comminuted radial head fractures and associated injuries received treatment with an EVOLVE® prosthesis between May 2001 and November 2009. Seventy-five patients were available for follow-up. On average, patients were followed for 41.5 months (33.0: 4.0 - 93.0). Outcome assessment was done on the basis of pain, ROM, strength, radiographic findings, and functional rating scores such as Broberg and Morrey, the Mayo elbow performance index (MEPI), and disabilities of the arm, shoulder and hand (DASH). Our study is currently the largest analysis of clinical outcome of a modular radial head replacement in the literature.

Results: Overall, there were 2 (2.7%) Mason II fractures, 21 (28%) Mason III fractures, and 52 (69.3%) Mason IV fractures. Arbeitsgemeinschaft für osteosynthesefragen (AO) classification was also determined. Of the 85 patients in our study, 75 were available for follow-up. Follow-up averaged 41.5 months (range, 4 - 93 months). Average scores for the cohort were as follows: Morrey, 85.7 (median 90.2; range 44.4 - 100); MEPI, 83.3 (85.0; 40.0 - 100); and DASH 26.1 points (22.5; 0.0 - 75.8). Mean flexion/extension in the affected joint was 125.7°/16.5°/0° in comparison to the noninjured side 138.5°/0°/12°. Mean pronation/supination was 70.5°/0°/67.1° in comparison to the noninjured side 83.6°/0°/84.3°. Handgrip strength of the injured compared to the non-injured arm was 78.8%. The following complications were also documented: 58 patients had periprosthetic radiolucency shown to be neither clinically significant nor relevant according to evaluated scores; 26 patients had moderate or severe periarticular ossification, and scored substantially worse according to MEPI and Morrey. Four patients required revisional surgery due to loosening of the prosthesis and chronic pain. In addition, one patient required a neurolysis of the ulnaris nerve, one developed a neobursa, and one had extensive swelling and blistering. The time interval between injury and treatment appeared to have an effect on results. Thirty-five patients were treated within the first 5 days after accident and showed better results than the 40 patients who were treated after 5 days.

Conclusions: Comminuted radial head fractures with elbow instability can be treated well with a modular radial head prosthesis, which restores stability in acute treatment. The modular radial head arthroplasty used in this study showed promising findings in short to midterm results.

Keywords: Radial Head, Fracture, Prosthesis, Arthroplasty, Elbow Instability

1. Background

The incidence of radial head fractures constitutes about 2% to 5% of all adult fractures (1, 2) and they are responsible for one third of all elbow injuries (3-5). When radial head fractures occur in combination with damage to the collateral ligaments of the elbow, damage to these structures results in gross instability to the elbow joint (6, 7), causing the radial head to become the primary stabilizer (8). Managing the radial head is important in restoring stability to the elbow joint and enabling early mobilization. In general, injuries to the radial head are treated

accordingly: Mason I injuries are treated conservatively; Mason II injuries conservatively or if displaced with open reduction and internal fixation (ORIF) (9-11); and Mason III fractures with ORIF or radial head prosthesis (12). The resection of the radial head has received ever more criticism (9, 10) and is now only recommended for isolated fractures with no ligament injury (13-17). In any case, it is important that the joint is functionally stable following surgery (18) and early mobilization is possible to prevent elbow stiffening.

A controversy exists regarding the treatment of Mason III and IV radial head fractures with some authors recommending ORIF and others the radial head prosthesis (19-26). Authors have expressed some concern over the use of radial head prostheses because of associated complications such as loss of motion, neuropathy of the ulnar nerve or posterior interosseous nerve, radiolucency, and periprosthetic osteolysis (27). In addition, there is concern that younger patients will suffer long-term consequences, which have not yet been adequately documented (23). Nevertheless, the radial head prosthesis has in many ways become increasingly more established as the treatment of choice for comminuted fractures, which often have associated ligament injuries further compromising stability (28).

The first generation of radial head prostheses including Swanson's silicon and the Vitallium prostheses had less than satisfactory results due to implant dislocations and breaks with up to 50% of implantations resulting in an aseptic prosthetic slip (2, 8, 29, 30). In addition, silicon from the implant has been associated with osteoporosis and synovitis (31). Further developments in radial head prostheses have led to improved biomechanical properties.

Modular metallic implants appear to have more free movement and there is reduced strain on the implant, which could decrease implant loosening and wear (32). In this study, we used the EVOLVE® prosthesis, which is a modular metallic system with two variable components, the head and stem joined to one another intraoperatively. Its polished surface replaces the rotating function of the radial head (8, 30) though does not appear to quite achieve complete restoration of the radial head's function (32). Of the few modular models on the market, the EVOLVE® implant (Wright Medical Technology Inc., Arlington, Tennessee, USA) used in this study was shown to have superior valgus stability in cadaver elbows (32). It has remained the standard prosthesis for radial head fractures in our center for over 10 years, showing in our first examination good results despite periprosthetic lucency in some patients (33).

2. Objectives

This study aimed to evaluate the clinical outcomes of patients who received this implant, measured using functional rating scores according to Broberg and Morrey, the Mayo elbow performance index (MEPI), and the DASH-questionnaire. Our study is currently the largest analysis in the literature of clinical outcome of a modular metallic prosthesis for the treatment of radial head fractures.

3. Patients and Methods

3.1. Patient Characteristics

Between 2001 and 2009, 85 patients with a comminuted fracture of the radial head and associated injuries (Table 1) were treated with the EVOLVE® prosthesis. Seventy-five

patients (88.2%) were available for follow-up. The average patient age was 55.9 years (mean: 55; minimum: 26 - maximum: 85), and the ratio of males to females was 35:40 (M:F). The dominant handed side was involved in 38 cases.

Fractures were classified according to the Mason classification system modified by Johnston (34) and the AO classification (35).

Demographic data such as age, occupation, mechanism of injury, localization of injury, and presence of an additional injury were recorded. Associated injuries were also recorded. There was failed internal fixation of the radial head in 7 cases (16 - 154 days), resection or partial resection of the radial head in 5 cases, persistent pain after conservative treatment in 3 cases and swelling of the elbow following late operative care in other cases.

3.2. Surgery

The placement of a radial head prosthesis was determined intraoperatively on the basis of elbow instability. Indications included a comminuted fracture of the radial head with one or more of the following: elbow dislocation, injury to the collateral ligaments, injury to the interosseous membrane (e.g. Essex Lopresti), and an olecranon fracture.

Surgical treatment was performed eight days after injury on average. Thirty-five patients (46.7%) were treated within the first five days after injury, and 40 patients (53.3%) at later time points (mean 30.0; 6 - 265 days). Delayed treatment was mostly because patients came from external hospitals several days after injury. All additional injuries to the collateral ligaments or the ventral capsule were treated. Coronoid fractures were also treated in 84.2%.

3.3. Postoperative Care

Physical therapy involving passive and active assisted movement began on the first postoperative day. Patients with collateral ligament injury were instructed to avoid all varus and valgus stress for six weeks. A dorsal cast was also used to temporarily reduce elbow extension if a coronoid fracture was present. We also used motion limited hinged external fixation in three patients. All patients, unless otherwise indicated, received 75 mg of a NSAID (Voltaren®; Novartis, Basel, Switzerland) per os for 4 weeks as prophylaxis against heterotrophic ossification.

3.4. Follow-up

The average follow-up time was 41.5 months (median 33.0; minimum 4 - maximum 93). Patients were asked to complete standardized questionnaires about their daily activities and capabilities, focusing on strength, coordination, and functionality of the injured extremity. Perceived pain and overall satisfaction of medical care were also assessed. The Morrey score (3), MEPI, and DASH (36) were used

to analyze results. Strength was measured for elbow flexion, extension, pronation, and supination with Primus RS™ (BTE Technologies Inc., Hanover, USA). Handgrip strength was measured with the help of a Jamar® Dynamometer.

3.5. Radiographic Assessment

The elbow was X-rayed in the anterior-posterior, lateral, and Greenspan radial head views (37) (Figure 1A and B, Figure 2A and B). If wrist injury was suspected, additional posterior-anterior wrist stress views were done bilaterally. Radiographs were interpreted by two trauma surgeons. Assessment criteria were the following: correct articulation of the joint components, position of the implant, humeroulnar arthrosis, prosthesis luxation, peri-prosthetic lucency (Figure 3) and heterotrophic ossification. Periarticular ossification was classified according to Brooker (38).

3.6. Statistics

Statistical analysis was done with Excel 2007 (Microsoft®), PASW 18 Statistics, and AMOS 18 (SPSS® IBM).

3.7. Ethical Considerations

The Ethics Committee of the Landesärztekammer Rheinland-Pfalz approved this study (Number 837.322.07(5857)).

4. Results

4.1. Clinical Results

Of the 85 patients in our study, 75 were available for follow-up. Follow-up averaged 41.5 months (mean: 33; range, 4 - 93 months). Average scores for the cohort were as follows: Morrey, 85.7 (median 90.2; range 44.4 - 100); MEPI, 83.3 (85.0; 40.0 - 100); and DASH 26.1 points (22.5; 0.0 - 75.8).

In regards to elbow range of motion (ROM), mean flexion/extension (neutral zero method) in the affected joint was 125.7°/16.5°/0° in comparison to the noninjured side 138.5°/0°/1.2°. Mean pronation/supination was 70.5°/0°/67.1° in comparison to the noninjured side, which was 83.6°/0°/84.3° (Figure 4A and B) (Table 2).

Overall, there were 2 (2.7%) Mason II fractures, 21 (28%) Mason III fractures, and 52 (69.3%) Mason IV fractures. According to the AO classification, there was 1 type-21A3-fracture (1.3%), 44 type-21B2-fractures (58.7%), 2 type-21C1-fractures (2.7%), 13 type-21C2-fractures (17.3%), and 15 type-21C3-fractures (20%).

4.2. Initial Versus Delayed Treatment

Fifty-seven patients were initially treated with the radial head prosthesis; 18 patients were treated after initial osteosynthesis or resection. The 57 patients treated initially with a prosthesis showed: mean flexion/extension (neu-

tral zero method) in the affected joint of 127.6°/15.4°/0°; and a mean pronation/supination of 72.9°/0°/70.2°. The patients had an average of 89.3 points on the Morrey score (median 92.0; range 57.2 - 100). According to the MEPI, patients had on average 88.0 points (95.0; 50.0 - 100). The DASH Score showed an average of 22.3 points (18.3; 0.0 - 75.8) (Table 3).

The other 18 patients showed a mean flexion/extension (neutral zero method) in the affected joint of 119.7°/20.0°/0° and the mean pronation /supination was 62.9°/0°/57.5°. The patients had an average of 75.1 points according to the Morrey score (median 77.9; range of 44.4 - 99.4). Patients had an average of 70.6 points on the MEPI (67.5; 40.0 - 100). The DASH score showed an average of 37.7 points (37.5; 0.0 - 74.2) (Table 3).

4.3. Stable Versus Unstable Injuries

There appeared to be differences in Morrey, MEPI, and DASH between stable and unstable cases. Fifty-two patients with a Mason IV fracture and one patient with an Essex-Lopresti injury were evaluated as unstable and showed an average DASH of 25.85 (22.5; 0.0 - 75.83), a Mayo score of 83.30 (85.0; 40.0 - 100.0), and a Morrey score of 85.05 (88.4; 44.4 - 100.0). The patient with the an Essex-Lopresti injury showed a DASH score of 25.83 points, a Mayo score of 95 points, and a Morrey score of 90.70 points by itself. Two patients with a Mason II injury and 20 patients with a Mason III injury were evaluated as stable and showed a DASH score of 26.59 (21.67; 0.0 - 73.33), a Mayo score of 83.41 (85.0; 50.0 - 100.0), and a Morrey score of 87.12 (91.3; 63.0 - 100.0).

4.4. Wrist Flexibility, Elbow Strength, Handgrip Strength, Arm Diameter, and Cubitus Valgus

Wrist flexibility was mostly the same on the injured as on the non-injured side with some deviation; 8 patients showed mild instability in the elbow to valgus stress (lateral deviation < 5°); 3 patients showed mild instability on the contralateral side. One patient showed moderate instability (5° < lateral deviation < 10°). Mean strength of elbow flexion, extension, pronation, and supination was as follows in the injured arm compared to non-injured extremity: 71.5% for flexion, 79.1% for extension, 79.9% for pronation, and 80.0% for supination. Handgrip strength of the injured compared to the non-injured arm was 78.8%. The ratio of the arm diameter of the injured to non-injured arm was on average without pathological findings.

Cubitus valgus on the affected side measured 7.7° and on the non-affected side 6.9°.

4.5. Occupational Rehabilitation

At the time of accident, 52 patients (69.3%) were employed. Time off work due to injury was on average 138 days (93, 5 - 546 days). Four patients had not yet returned to their jobs at the time of examination, 29 patients

(55.8%) returned to their employment without disability, and 20 patients (38.5%) returned to work with restricted capabilities. Five patients (7.7%) needed to change their workplace. Of the 16 patients with physically strenuous employment, 3 required training for alternative employment, 5 patients could go back to work with light modifications at their working place, and 8 patients returned to work with no restrictions.

4.6. Radiological Finding

Radiographs of 73 patients in follow-up examinations revealed that in all but one case, radial head implants articulated congruently. In the one exception, prosthetic displacement was observed, but there appeared to be not associated pain nor highly impaired ROM.

Fifty-eight patients (80.6%) had radiolucency lines around the stem of the prosthesis with an average width of 1 mm (Figure 3).

Periarticular ossification was classified according to Brooker et al. (38). Twenty patients (27.4%) showed no periprosthetic ossification, 27 patients (52.1%) showed minimal to considerable ossification, 15 patients showed moderate, and 11 patients (15.1%) showed extensive periprosthetic ossification.

Severe humeroulnar arthrosis was diagnosed in 3 patients (4.1%); 23 patients (31.5%) had considerable humeroulnar arthrosis; 21 patients (28.8%) slight; and 26 patients (35.6%) had none.

4.7. Subjective Patient Ratings

Seventy-six percent of patients reported the absence of

pain or only slight pain; 24.0% reported regular and/or constant pain; 77.3% of patients reported a reduction in strength.

Fifty-five patients (73.3%) rated the operative results as good or very good; 14 patients (18.7%) were satisfied with the results; and 6 (8.0%) were dissatisfied. Thirty-three patients reported no restrictions at all in their daily activities; 38 reported resting the affected extremity on a daily basis; and four reported serious restrictions in daily activities.

4.8. Complications

Eleven patients showed extensive periprosthetic ossification. In 3 cases, prosthetic revision was necessary. In one case, a new identical prosthesis was implanted because of disconnection of the head stem interface. In two cases, revisional surgery was necessary because of persistent pain and radiologic findings of loosening of the prosthesis. One of these patients required complete removal of the implant because of persisting pain. In 1 case, the implant was displaced according to radiographs performed during the study. Revisional surgery was offered to the patient; however, the patient refused due to lack of pain and good ROM.

Overall, 4 cases required the removal of the radial head prosthesis. One case was already mentioned above; one case experienced a loosening after falling down on the same arm five months after the first operation; the other two cases showed periprosthetic lucency with persistent pain. No deep infection of the prosthesis or joint was noted.

In addition, one patient required a neurolysis of the ulnar nerve, one developed a neobursa, and one had extensive swelling and blistering.

Table 1. Distribution of Accompanying Injuries in Absolute and Percental Data

Accompanying Injuries	No. (%)
Fracture of Proc.coronoideus^a	38 (59.4)
Regan-Morrey type I	11
Regan-Morrey type II	8
Regan-Morrey type III	19
Avulsion of Lig.coll.radiale	18 (28.1)
Avulsion of Lig.coll.ulnare	13 (20.3)
Capsular avulsion	9 (14.1)
Fracture of the olecranon	5 (7.8)
Fracture of the shaft of ulna	4 (6.3)
Open lesion (Tscherne I°)	5 (7.8)
Open lesion (Tscherne II°)	2 (3.1)
Fracture of capitellum humeri	1 (1.6)
Monteggia lesion	2 (3.1)
Essex-Lopresti lesion	1 (1.6)
Fracture of the scaphoid	1 (1.6)
Fracture of the thumb	1 (1.6)
Total	64 (100)

^aIn 59.4% we had a fracture of Proc.coronoideus.

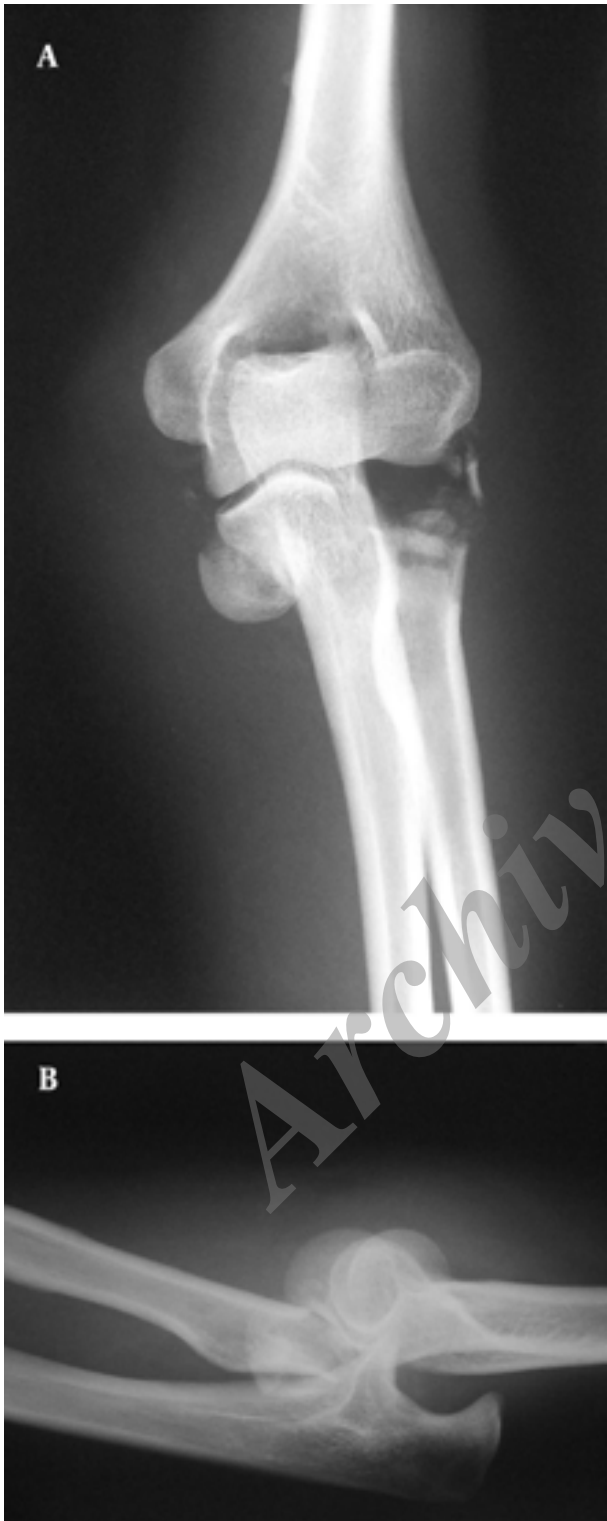

Figure 1. A, Anterior-Posterior (A.p.) Radiograph of the Left Elbow at Trauma Date; B, Lateral Radiograph of the Left Elbow at Trauma Date

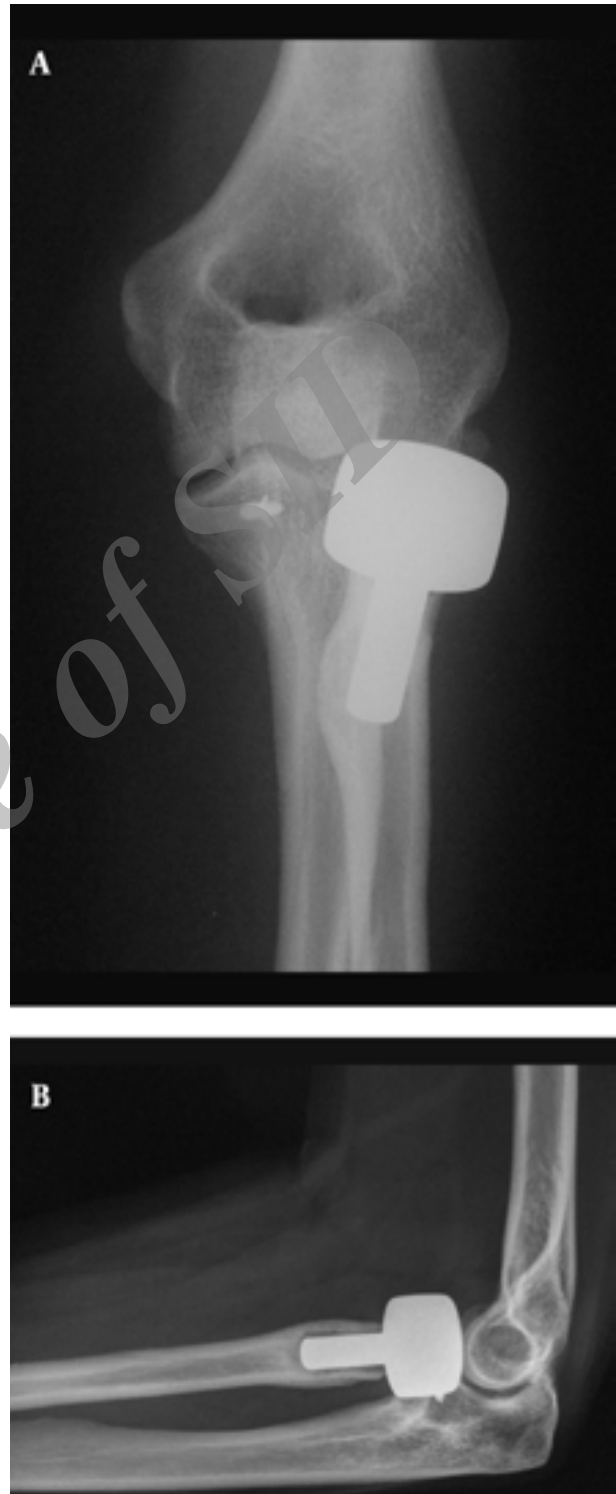

Figure 2. A, Anterior-Posterior (A.P.) Radiograph of the Left Elbow 19 Months After Trauma; B, Lateral Radiograph of the Elbow 19 Months After Trauma With Minor Radiolucency Lines Around the Stem

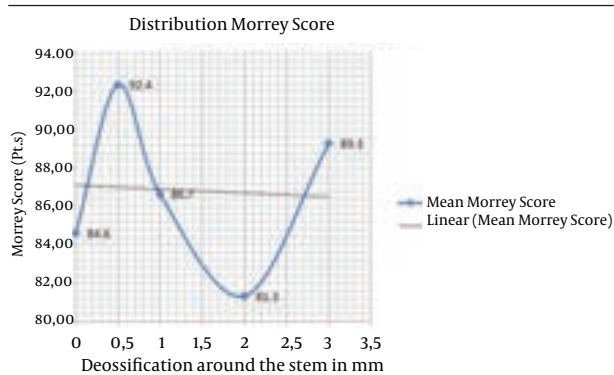


Figure 3. Distribution of Mean Morrey Score (pts.), Depending on Degree of Deossification Around the Stem (mm)

Table 2. Clinical Results Average (Median; Minimum - Maximum)

	Injured Extremity	Non-injured Extremity
Elbow flexion	125.7° (130°; 90 - 150°)	138.5° (140°; 120 - 150°)
Extension deficit	16.5° (15°; 0 bis 50°)	-1.2° (0°; -10 - 30°)
Supination	67.1° (80°; -45 - 90°)	84.3° (85°; 60 - 90°)
Pronation	70.5° (80°; 0 - 90°)	83.6° (80°; 70 - 90°)
Cubitus valgus	7.7° (10°; 0 - 20°)	6.9° (5°; 0 - 20°)
Handgrip strength	25.1 kg (24; 4 - 50 kg)	32.4 kg (32; 10 - 56 kg)
wrist flexion	67.4° (70°; 7 - 90°)	71.6° (70°; 20 - 90°)
Wrist extension	66.1° (70°; 30 - 90°)	69.8° (70°; 40 - 90°)
Radial abduction	8.2° (5°; 0 - 30°)	8.3° (5°; 5 - 30°)
Ulnar abduction	30.4° (30°; 10 - 50°)	31.7° (30°; 15 - 50°)

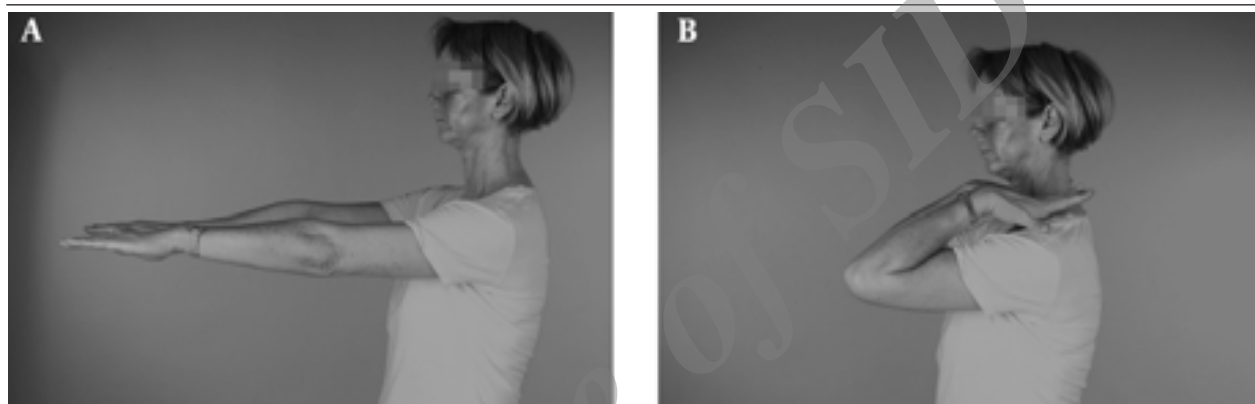


Figure 4. A, Demonstration of ROM (Range of Motion) 24 Months After Radial Head Arthroplasty of the Left Elbow. Maximum Extension of the Elbow Joint; B, Demonstration of ROM (Range of Motion). Maximum Flexion of the Elbow Joint

Table 3. Clinical Results Initial or Later Treatment with Radial Head (RH) Prosthesis Average (Median; Minimum - Maximum)

	Initial Treatment	Later Treatment
Elbow flexion	127.6° (130°; 90 - 150°)	119.7° (122.5°; 90 - 140°)
Extension deficit	15.4° (10°; 0 bis 50°)	20.0° (22.5°; 0° - 45°)
Supination	70.2° (80°; -45 - 90°)	57.5° (60°; -30 - 90°)
Pronation	72.9° (80°; 0 - 90°)	62.8° (65°; 10 - 90°)
Morrey score	89.3 (92; 57.2 - 100)	75.1 (77.9; 44.4 - 99.4°)
MEPI	88.0 (95; 50 - 100)	70.6 (67.5; 40 - 100)
DASH	22.3 (18.3; 0 - 75.8)	37.7° (37.5°; 0 - 74.2°)

Abbreviations: MEPI, Mayo elbow performance index; DASH, disabilities of arm, shoulder and hand.

5. Discussion

To our knowledge, our study is the largest analysis of clinical outcome of a modular radial head replacement in the literature. Our results show that the EVOLVE® prosthesis can restore joint integrity in fractures associated with elbow injuries and clinical outcome is better if implanted directly after injury. As in similar studies, the inclusion of a comparison group was impossible. This was because almost all patients in our center with comminuted fractures were treated with an EVOLVE® prosthesis; nevertheless, our results confirm those of previous studies and contrib-

ute greatly to current research on prosthetic devices or operative methods for radial head fractures.

The older generation of radial head prosthetic devices including the silicone implants and early "mono-block" models did not fulfill the biomechanical requirements of the elbow joint, and therefore did not become established as a standard treatment option (39-41). Because osteosynthesis was not an option for treating comminuted fractures due to its failure to adequately restore stability to the elbow (2, 4, 5, 11, 42), radial head resection

without a replacement arthroplasty of any sort remained the standard operative technique for comminuted fractures for many years (4, 42-44). However, resection involves a loss of stability which carries with it associated complications such as the proximal displacement of the radius and premature humeroulnar osteoarthritis (4, 11, 43-47). The newer radial head prosthetic devices, such as the EVOLVE® prosthesis in this study, were developed to improve upon previous models by maximizing radio-capetalar congruency and contact forces and allow for early mobilization (48).

Indeed, our functional and radiological results for the modular prosthesis showed a good surgical outcome using a modular metallic prosthesis. Average scores for our cohort were as follows: Morrey, 85.7 (median 90.2; range 44.4-100); MEPI, 83.3 (85.0; 40.0-100); and DASH 26.1 points (22.5; 0.0 - 75.8). This is despite having an especially high number of associated injuries; we diagnosed additional injuries to the elbow in 85.3% of case, which is significantly higher than the 30% - 68% reported in the literature (49, 50). The combination of these injuries with radial head resection without an implant would probably have led to instability of the elbow and late complications (3, 6, 32, 42).

Other authors have also described good results in line with our findings. Grewal et al. (8) investigated the use of a modular metallic prosthesis in the treatment of 26 patients with a radial head fracture of the arm. This was the first study documenting short-term results. They reported an average MEPI of 82 and DASH of 24.4 (8), which is very close to our findings. Only two patients in the Grewal et al. (8) study were reported as having poor results based on MEPI. Both had a terrible-triad injury. Other authors have also documented poor results for terrible triad injuries (8, 21, 41, 51, 52). Though we recorded no results for patients with a terrible triad, one patient in our study had an Essex-Lopresti injury and results were surprisingly good; the Morrey score was 90.7, and MEPI was 95.0.

In the largest investigation of a bipolar prosthesis, Zunkiewicz et al. reported a slightly higher MEPI of 92.1 and a lower DASH of 13.8 (48). Authors reported good results with a bipolar prosthesis with a telescoping stem despite a patient pool with many associated injuries. Measurements of elbow flexion/extension and pronation/supination in our patient pool were similar to those reported by Zunkiewicz et al. (48) Our mean flexion/extension (neutral zero method) of the affected joint was 125.7°/16.5°/0° compared to an flexion/extension arc of 126° in an earlier study. Mean pronation/supination was 70.5°/0°/67.1° compared to 69°/0°/74°. In addition, similar to our study, they found that results were better in patients with initial vs. later reconstructive treatment.

Concerning radiological findings, Grewal et al. observed substantially less heterotopic ossification in their cohort with only six of 26 patients showing radiological signs and only one patient showing severe ossification (8). Our data showed that 27 patients had minimal to considerable ossification, 15 patients moderate, and 11 patients

showed extensive ossification. A significant decline in the Morrey score ($P = 0.036$) was correlated with an increase in heterotopic ossification.

A correlation between periprosthetic radiolucency and outcome was not determined in our study and has not been observed by other authors (8, 49, 53, 54). In fact, 58 patients (80.6%) were noted to have a line of deossification around the prosthesis stem in our cohort and patients showing periprosthetic deossification measuring 0.5 - 1 mm had slightly better results than those having no deossification around the stem (Figure 3). Perhaps one explanation for the extensive periprosthetic radiolucency in this study is that the polished surface of the material is not suitable for growth of bone into the prosthesis. Causes of periprosthetic radiolucency, however, are yet to be identified and we assume that these radiological findings are signs of evasive movement of the radial head prosthesis in the proximal radius to prevent transfer of high pressure levels to the capitulum humeri as stated by Harrington et al. (55).

Perhaps an explanation for the good results in our study is that the modular metallic prosthesis functions as an exact fit with the humeroulnar joint, so that neither understuffing nor overstuffing occurs. Understuffing can lead to excessive laxity and overstuffing can cause reposition difficulties such as hyperpressure on the capitulum humeri with a range of tolerance of ± 2 mm (56). In our study we measured the radial head intraoperatively and varied the prosthesis height accordingly. Radiographs confirmed joint congruencies and overstuffing was avoided.

The implantation of a modular prosthesis in combination with ligament reconstruction and early postoperative rehabilitation allows one to avoid the biomechanical disadvantages associated with radial head excision. In conducting this study, we came to the conclusion that the current classification of fractures based on Mason and AO is neither helpful in determining proper treatment nor in judging prognosis for high grade radial head fractures. This is because the role of ligament injury of the elbow is not taken into account. Another classification system is needed. We also believe that long-term results for assessing the relevance of deossification around the stem found in some patients are needed. Overall, we found that comminuted radial head fractures with elbow instability can be treated well with a modular metallic radial head prosthesis, which restores stability and integrity of the joint. The primary therapy with the prosthesis outclasses the secondary treatment.

Acknowledgments

The presented results are part of the doctoral thesis of Eike Dremel.

Footnote

Authors' Contribution: All authors have made substantial contributions to this article; especially to the conception and design of the study, the acquisition of data and

the analysis and interpretation of data. Arash Moghaddam, Bahram Biglari, Stefan Studier Fischer, and Paul Alfred Grutzner: study concept and design; Arash Moghaddam, Stefan Studier-Fischer, Eike Dremel, and Bahram Biglari: acquisition of data; Arash Moghaddam, Bahram Biglari, Eike Dremel, and Tim Friedrich Raven: analysis and interpretation of data; Arash Moghaddam, Eike Dremel, Bahram Biglari, and Tim Friedrich Raven: drafting of the manuscript; Arash Moghaddam, Bahram Biglari, Paul Alfred Grutzner, and Tim Friedrich Raven: critical revision of the manuscript for important intellectual content; Arash Moghaddam, Bahram Biglari, Eike Dremel, Stefan Studier Fischer, and Tim Friedrich Raven: statistical analysis; Arash Moghaddam, Bahram Biglari, Stefan Studier Frischer, Paul Alfred Grutzner, Eike Dremel, Tim Friedrich Raven: administrative, technical, and material support; Arash Moghaddam, and Bahram Biglari: study supervision.

References

- King GJ, Green DP, Hotchkiss RN, Pederson WC, Wolfe SW. *Green's Operative Hand Surgery*. London: Churchill Livingstone; 2005.
- Gebauer M, Rucker AH, Barvencik F, Rueger JM. [Therapy for radial head fractures]. *Unfallchirurg*. 2005;**108**(8):657-67. doi: 10.1007/s00113-005-0979-z. [PubMed: 16078014]
- Morrey BF. *The elbow and its disorders*. 3rd ed. Philadelphia: Saunders; 1993.
- Ambacher T, Maurer F, Weise K. [Treatment results after primary and secondary resection of the radial head]. *Unfallchirurg*. 2000;**103**(6):437-43. [PubMed: 10925645]
- Zimmermann G, Wagner C, Moghaddam A, Studier-Fischer S, Wentzensen A. Radiusköpfchenfraktur und Ellenbogenluxation. *Trauma und Berufskrankheit*. 2004;**6**(4):297-303. doi: 10.1007/s10039-004-0962-x.
- Johnson JA, Beingsneser DM, Gordon KD, Dunning CE, Stacpoole RA, King GJ. Kinematics and stability of the fractured and implant-reconstructed radial head. *J Shoulder Elbow Surg*. 2005;**14**(1 Suppl S):195S-201S. [PubMed: 15726082]
- Beingsneser DM, Dunning CE, Gordon KD, Johnson JA, King GJ. The effect of radial head fracture size on elbow kinematics and stability. *J Orthop Res*. 2005;**23**(1):210-7. doi: 10.1016/j.orthres.2004.06.001. [PubMed: 15607895]
- Grewal R, MacDermid JC, Faber KJ, Drosdowech DS, King GJ. Comminuted radial head fractures treated with a modular metallic radial head arthroplasty. Study of outcomes. *J Bone Joint Surg Am*. 2006;**88**(10):2192-200. doi: 10.2106/JBJS.E.00962. [PubMed: 17015596]
- Gebauer M, Barvencik F, Rucker AH, Rueger JM. Operative Therapie der dislozierten Radiusköpfchenfraktur. *Der Unfallchirurg*. 2005;**108**(8):669-71. doi: 10.1007/s00113-005-0980-6. [PubMed: 16059728]
- Meyer-Marcotty MV, Lahoda LU, Hahn MP, Muhr G. [Differential therapy of radial head fracture: a critical analysis based on outcome of 53 patients]. *Unfallchirurg*. 2002;**105**(6):532-9. [PubMed: 12132193]
- Lindhovius AL, Felsch Q, Doornberg JN, Ring D, Kloen P. Open reduction and internal fixation compared with excision for unstable displaced fractures of the radial head. *J Hand Surg Am*. 2007;**32**(5):630-6. doi: 10.1016/j.jhsa.2007.02.016. [PubMed: 17482000]
- Zwingmann J, Welzel M, Dovi-Akue D, Schmal H, Sudkamp NP, Strohm PC. Clinical results after different operative treatment methods of radial head and neck fractures: a systematic review and meta-analysis of clinical outcome. *Injury*. 2013;**44**(11):1540-50. doi: 10.1016/j.injury.2013.04.003. [PubMed: 23664241]
- Charalambous CP, Stanley JK, Siddique I, Powell E, Ramamurthy C, Gagey O. Radial head fracture in the medial collateral ligament deficient elbow; biomechanical comparison of fixation, replacement and excision in human cadavers. *Injury*. 2006;**37**(9):849-53. doi: 10.1016/j.injury.2006.04.125. [PubMed: 16872610]
- Schiffert A, Bettwieser SP, Porucznik CA, Crim JR, Tashjian RZ. Proximal radial drift following radial head resection. *J Shoulder Elbow Surg*. 2011;**20**(3):426-33. doi: 10.1016/j.jse.2010.11.008. [PubMed: 21324415]
- Pike JM, Athwal GS, Faber KJ, King GJ. Radial head fractures-an update. *J Hand Surg Am*. 2009;**34**(3):557-65. doi: 10.1016/j.jhsa.2008.12.024. [PubMed: 19258159]
- Ikeda M, Oka Y. Function after early radial head resection for fracture: a retrospective evaluation of 15 patients followed for 3-18 years. *Acta Orthop Scand*. 2000;**71**(2):191-4. doi: 10.1080/000164700317413184. [PubMed: 10852327]
- Jensen SL, Olsen BS, Sojbjerg JO. Elbow joint kinematics after excision of the radial head. *J Shoulder Elbow Surg*. 1999;**8**(3):238-41. [PubMed: 10389079]
- Burkhart KJ, Wegmann K, Dargel J, Ries C, Mueller LP. Treatment of radial head and neck fractures: in favor of anatomical reconstruction. *Eur J Trauma and Emerg Surg*. 2012;**38**(6):593-603. doi: 10.1007/s00068-012-0222-x. [PubMed: 26814544]
- van Riet RP, Morrey BF. Documentation of associated injuries occurring with radial head fracture. *Clin Orthop Relat Res*. 2008;**466**(1):130-4. doi: 10.1007/s11999-007-0064-8. [PubMed: 18196384]
- Holmenschlager F, Halm JP, Piatek S, Schubert S, Winckler S. [Comminuted radial head fractures. Initial experiences with a Judet radial head prosthesis]. *Unfallchirurg*. 2002;**105**(4):344-52. [PubMed: 12066473]
- Frosch KH, Knopp W, Dresing K, Langer C, Sturmer KM. [A bipolar radial head prosthesis after comminuted radial head fractures: indications, treatment and outcome after 5 years]. *Unfallchirurg*. 2003;**106**(5):367-73. doi: 10.1007/s00113-003-0573-1. [PubMed: 12750809]
- Muller MC, Burger C, Wirtz DC, Weber O. [Replacement of the comminuted radial head fracture by a bipolar radial head prosthesis]. *Oper Orthop Traumatol*. 2011;**23**(1):37-45. doi: 10.1007/s00064-010-0004-8. [PubMed: 21327953]
- Ring D. Radial head fracture: open reduction-internal fixation or prosthetic replacement. *J Shoulder Elbow Surg*. 2011;**20**(2 Suppl):S107-12. doi: 10.1016/j.jse.2010.11.011. [PubMed: 21281915]
- Ruchelsman DE, Christoforou D, Jupiter JB. Fractures of the radial head and neck. *J Bone Joint Surg Am*. 2013;**95**(5):469-78. doi: 10.2106/JBJS.J.01989. [PubMed: 23467871]
- Struijs PA, Smit G, Steller EP. Radial head fractures: effectiveness of conservative treatment versus surgical intervention. A systematic review. *Arch Orthop Trauma Surg*. 2007;**127**(2):125-30. doi: 10.1007/s00402-006-0240-4. [PubMed: 17066285]
- Kalicke T, Muhr G, Frangen TM. Dislocation of the elbow with fractures of the coronoid process and radial head. *Arch Orthop Trauma Surg*. 2007;**127**(10):925-31. doi: 10.1007/s00402-007-0424-6. [PubMed: 17713772]
- Lapner M, King GJ. Radial head fractures. *J Bone Joint Surg Am*. 2013;**95**(12):1136-43. [PubMed: 23943926]
- Ricon FJ, Sanchez P, Lajara F, Galan A, Lozano JA, Guerado E. Result of a pyrocarbon prosthesis after comminuted and unreconstructable radial head fractures. *J Shoulder Elbow Surg*. 2012;**21**(1):82-91. doi: 10.1016/j.jse.2011.01.032. [PubMed: 21531150]
- Morrey BF, Askew L, Chao EY. Silastic prosthetic replacement for the radial head. *J Bone Joint Surg Am*. 1981;**63**(3):454-8. [PubMed: 7204446]
- Ring D, King G. Radial head arthroplasty with a modular metal spacer to treat acute traumatic elbow instability. Surgical technique. *J Bone Joint Surg Am*. 2008;**90** Suppl 2 Pt 1:63-73. doi: 10.2106/jbjs.g.01248. [PubMed: 18310687]
- Vanderwilde RS, Morrey BF, Melberg MW, Vinh TN. Inflammatory arthritis after failure of silicone rubber replacement of the radial head. *J Bone Joint Surg Br*. 1994;**76**(1):78-81. [PubMed: 8300687]
- Pomianowski S, Morrey BF, Neale PG, Park MJ, O'Driscoll SW, An KN. Contribution of monoblock and bipolar radial head prostheses to valgus stability of the elbow. *J Bone Joint Surg Am*. 2001;**83**-A(12):1829-34. [PubMed: 11741062]
- Moghaddam A, Lennert A, Studier-Fischer S, Wentzensen A, Zimmermann G. [Prosthesis after comminuted radial head fractures: midterm results]. *Unfallchirurg*. 2008;**111**(12):997-1004. doi: 10.1007/s00113-008-1514-9. [PubMed: 19039568]

34. Johnston GW. A follow-up of one hundred cases of fracture of the head of the radius with a review of the literature. *Ulster Med J.* 1962;**31**:51-6. [PubMed: 14452145]
35. Muller ME, Nazarian S, Koch P, Schatzker J. *The Comprehensive Classification of Fractures of Long Bones.* Berlin, Germany: Springer; 1990.
36. Germann G, Wind G, Harth A. [The DASH(Disability of Arm-Shoulder-Hand) Questionnaire—a new instrument for evaluating upper extremity treatment outcome]. *Handchir Mikrochir Plast Chir.* 1999;**31**(3):149-52. doi: 10.1055/s-1999-13902. [PubMed: 10420282]
37. Greenspan A, Norman A. Elbow injury: a new imaging approach. *Bull Hosp Jt Dis Orthop Inst.* 1986;**46**(1):52-9. [PubMed: 3015296]
38. Brooker AF, Bowerman JW, Robinson RA, Riley LH. Ectopic ossification following total hip replacement. Incidence and a method of classification. *J Bone Joint Surg Am.* 1973;**55**(8):1629-32. [PubMed: 4217797]
39. Berlemann U, Barnbeck F. [Surgical therapy of radial head fracture—results of osteosynthesis and resection treatment]. *Unfallchirurg.* 1994;**97**(12):639-44. [PubMed: 7855609]
40. Betz A. [Surgical differential therapy of fracture of the radius head]. *Orthopade.* 1988;**17**(3):320-7. [PubMed: 3043314]
41. Wick M, Lies A, Muller EJ, Hahn MP, Muhr G. [Prostheses of the head of the radius. What outcome can be expected?]. *Unfallchirurg.* 1998;**101**(11):817-21. [PubMed: 9865163]
42. Ikeda M, Sugiyama K, Kang C, Takagaki T, Oka Y. Comminuted fractures of the radial head. Comparison of resection and internal fixation. *J Bone Joint Surg Am.* 2005;**87**(1):76-84. doi: 10.2106/JBJS.C.01323. [PubMed: 15634816]
43. Broberg MA, Morrey BF. Results of delayed excision of the radial head after fracture. *J Bone Joint Surg Am.* 1986;**68**(5):669-74. [PubMed: 3722222]
44. Janssen RP, Vegter J. Resection of the radial head after Mason type-III fractures of the elbow: follow-up at 16 to 30 years. *J Bone Joint Surg Br.* 1998;**80**(2):231-3. [PubMed: 9546450]
45. Keyl W. [Indication of radius head resection with special reference to late results of 251 fractures and luxations of the radius head]. *Arch Orthop Unfallchir.* 1971;**70**(3):243-60. [PubMed: 5088191]
46. Mutschler W, Burri C, Rubenacker S. [Reconstructive surgery of malunited elbow fractures]. *Orthopade.* 1990;**19**(6):324-31. [PubMed: 2277705]
47. Rosenblatt Y, Athwal GS, Faber KJ. Current recommendations for the treatment of radial head fractures. *Orthop Clin North Am.* 2008;**39**(2):173-85. doi:10.1016/j.ocl.2007.12.008. [PubMed: 18374808]
48. Zunkiewicz MR, Clemente JS, Miller MC, Baratz ME, Wysocki RW, Cohen MS. Radial head replacement with a bipolar system: a minimum 2-year follow-up. *J Shoulder Elbow Surg.* 2012;**21**(1):98-104. doi: 10.1016/j.jse.2011.05.012. [PubMed: 21856178]
49. Chien HY, Chen AC, Huang JW, Cheng CY, Hsu KY. Short- to medium-term outcomes of radial head replacement arthroplasty in posttraumatic unstable elbows: 20 to 70 months follow-up. *Chang Gung Med J.* 2010;**33**(6):668-78. [PubMed: 21199612]
50. Burkhart KJ, Mattyasovszky SG, Runkel M, Schwarz C, Kuchle R, Hessmann MH, et al. Mid- to long-term results after bipolar radial head arthroplasty. *J Shoulder Elbow Surg.* 2010;**19**(7):965-72. doi: 10.1016/j.jse.2010.05.022. [PubMed: 20846619]
51. Visna P, Kalvach J, Beitzl E, Pilny J, Cizmar I. [Open posterior dislocation of the elbow with fractures of the radial head and coronoid process and multiple diaphyseal fractures of the ulna]. *Unfallchirurg.* 2008;**111**(3):193-6. doi: 10.1007/s00113-007-1313-8. [PubMed: 17989952]
52. Ring D, Jupiter JB, Zilberfarb J. Posterior dislocation of the elbow with fractures of the radial head and coronoid. *J Bone Joint Surg Am.* 2002;**84-A**(4):547-51. [PubMed: 11940613]
53. Doornberg JN, Parisien R, van Duijn PJ, Ring D. Radial head arthroplasty with a modular metal spacer to treat acute traumatic elbow instability. *J Bone Joint Surg Am.* 2007;**89**(5):1075-80. doi: 10.2106/JBJS.E.01340. [PubMed: 17473146]
54. Muhm M, de Castro R, Winkler H. Radial head arthroplasty with an uncemented modular metallic radial head prosthesis: short- and mid-term results. *Eur J Trauma Emerg Surg.* 2011;**37**(1):85-95. [PubMed: 26814756]
55. Harrington IJ, Sekyi-Otu A, Barrington TW, Evans DC, Tuli V. The functional outcome with metallic radial head implants in the treatment of unstable elbow fractures: a long-term review. *J Trauma.* 2001;**50**(1):46-52. [PubMed: 11231669]
56. Van Glabbeek F, van Riet RP, Baumfeld JA, Neale PG, O'Driscoll SW, Morrey BF, et al. The kinematic importance of radial neck length in radial head replacement. *Med Eng Phys.* 2005;**27**(4):336-42. doi: 10.1016/j.medengphy.2004.04.011. [PubMed: 15823475]